

Evaluation of a Novel Biomaterial in the Suprachoroidal Space of the Rabbit Eye

Suzanne Einmahl,^{1,2} Michelle Savoldelli,³ François D'Hermies,³ Cyrus Tabatabay,¹ Robert Gurny,¹ and Francine Behar-Cohen^{2,3}

PURPOSE. Drug delivery to treat diseases of the posterior segment of the eye, such as choroidal neovascularization and its complications, is hampered by poor intraocular penetration and rapid elimination of the drug from the eye. The purpose of this study was to investigate the feasibility and tolerance of suprachoroidal injections of poly(ortho ester) (POE), a bioerodible and biocompatible polymer, as a biomaterial potentially useful for development of sustained drug delivery systems.

METHODS. After tunnelization of the sclera, different formulations based on POE were injected (100 μ L) into the suprachoroidal space of pigmented rabbits and compared with 1% sodium hyaluronate. Follow-up consisted of fundus observations, echography, fluorescein angiography, and histologic analysis over 3 weeks.

RESULTS. After injection, POE spread in the suprachoroidal space at the posterior pole. It was well tolerated and progressively disappeared from the site of injection without sequelae. No bleeding or retinal detachment occurred. Echographic pictures showed that the material was present in the suprachoroidal space for 3 weeks. Angiography revealed minor pigment irregularities at the site of injection, but no retinal edema or necrosis. Histology showed that POE was well tolerated in the choroid.

CONCLUSIONS. POE suprachoroidal injections, an easy, controllable, and reproducible procedure, were well tolerated in the rabbit eye. POE appears to be a promising biomaterial to deliver drugs focally to the choroid and the retina. (*Invest Ophthalmol Vis Sci.* 2002;43:1533-1539)

The delivery of therapeutic amounts of drugs to the tissues of the posterior segment of the eye with reduced systemic side effects remains a challenge, notably for the treatment of exudative age-related macular degeneration (AMD).¹ Choroidal neovascularization (CNV) occurs at the site of an alteration of the retinal pigment epithelium (RPE) and the Bruch membrane, although the exact pathogenic mechanisms are not yet understood.² These alterations involve migration, proliferation, and differentiation of microvascular endothelial cells and result

in the formation of an abnormal capillary network. A possible approach for treating CNV is the delivery of antiangiogenic drugs, which would specifically target the formation of new vessels in the choroid.³⁻⁷ Another treatment strategy is the administration of a neurotrophic drug that would help RPE migration and proliferation after surgical ablation of CNV membranes, to repopulate the atrophic zones of the retina in the region of the excised neovessel.⁸

Unfortunately, the delivery of drugs to the posterior segment is frequently limited by the difficulty in targeting the choroidal or retinal tissues. Systemic administration often leads to insufficient concentration in tissues and is associated with numerous side effects.⁹ Direct drug injections in the suprachoroidal space would presumably allow therapeutic and nontoxic drug concentrations to be achieved in the choroid and RPE. However, if the drug is injected as a solution, it spreads in the whole area in the suprachoroidal space, possibly resulting in toxicity to surrounding tissues. Moreover, substances are eliminated rapidly through the choroidal blood flow.¹⁰ To circumvent these problems, it would be helpful to administer sustained drug delivery systems locally, to increase site specificity, to reduce side effects in the surrounding tissues, and to prolong delivery time.

Recent advances in biomaterials science has led to the discovery of polymers offering controlled-release characteristics. Among them, poly(ortho esters) (POEs) are a family of hydrophobic, biocompatible,¹¹ and bioerodible polymers. POE's bioresorption represents a significant advantage over other nonbiodegradable drug delivery systems, because there is no need to explant POE once all the drug has been released. This ointmentlike material allows the incorporation of drugs into the polymer by simple mixing at room temperature, without the use of heat or solvents. As a consequence, fragile drugs, such as proteins or oligonucleotides, can be delivered from this polymer.¹² POE is viscous and can be injected with a conventional syringe through an appropriate needle. This nontraumatic procedure is clearly preferable to implantation of solid devices, which requires a trocar or a complex surgical procedure.

Kinetics of drug release from POE are constant and linear, without burst effect, and can be controlled by many factors, such as the polymer's molecular weight or physicochemical characteristics of the substances incorporated in the polymer matrix. Notably, basic products prolong the polymer's lifetime by stabilizing the chemical backbone and slow down polymer degradation¹³ and the drug release rate.^{14,15}

Intraocular biocompatibility of aseptic POE has been assessed in subconjunctival,¹⁶ intracameral,¹¹ and intravitreal¹¹ sites in the eye. In all cases, the polymer is well tolerated, triggering a limited reversible acute inflammatory reaction but no chronic inflammation or fibrotic encapsulation. Recently, POE has also been evaluated as a carrier to deliver 5-fluorouracil in an animal model of filtering surgery. The sustained release of the antiproliferative drug allows significant reduction of intraocular pressure over an extended period, while reducing 5-fluorouracil's corneal toxicity.¹⁷

From the ¹Department of Pharmaceutical Technology and Biopharmaceutics, School of Pharmacy, University of Geneva, Geneva, Switzerland; ²Laboratory U450, National Institute of Health and Medical Research (INSERM), Paris, France; and ³Department of Ophthalmology, Hôtel-Dieu Hospital, Paris, France.

Supported by Swiss National Science Foundation Grant 3200-056750.99/1 and a fellowship for prospective researchers (SE).

Submitted for publication August 7, 2001; revised November 26, 2001; accepted December 13, 2001.

Commercial relationships policy: N.

The publication costs of this article were defrayed in part by page charge payment. This article must therefore be marked "advertisement" in accordance with 18 U.S.C. §1734 solely to indicate this fact.

Corresponding author: Robert Gurny, Department of Pharmaceutical Technology and Biopharmaceutics, School of Pharmacy, University of Geneva, 30 quai Ernest-Ansermet, 1211 Geneva 4, Switzerland; robert.gurny@pharm.unige.ch.

The purpose of this study was to investigate the feasibility and biocompatibility of suprachoroidal injections of POE as a potential drug delivery system for the posterior segment of the eye.

MATERIALS AND METHODS

Polymer Synthesis and Characterization

POE was synthesized by a transesterification reaction between 1,2,6-hexanetriol and trimethyl orthoacetate (Aldrich Chemie, Steinheim, Germany) under anhydrous and aseptic conditions.¹⁸ POE was further purified by a precipitation procedure to remove impurities, such as residual monomers and oligomers.^{19,20}

The polymer has been characterized by infrared spectroscopy, nuclear magnetic resonance, and size-exclusion chromatography.²¹ The average molecular weight of the sterile polymer used in this study was 10,000, with a polydispersity of 1.35. POE is a transparent, viscous material, gel-like in appearance, with a refractive index of 1.47. It shows Newtonian rheological behavior.

Preparation of the Formulations

Different formulations were tested: sodium hyaluronate 1% as a control (Healon; Pharmacia Ophthalmics, Monrovia, CA), POE alone, POE with 1% (wt/wt) magnesium hydroxide (MG; Sigma Chemie AG, Buchs, Switzerland), and POE with 1% (wt/wt) dexamethasone sodium phosphate (DEX; Sigma Chemie). MG was chosen as an excipient modulator of POE degradation, because of its basic characteristics.¹³ DEX was selected as a model anti-inflammatory and antiangiogenic drug.²² Moreover, the sodium phosphate salt of DEX is a basic substance, which also modulates POE's degradation rate and prolongs its lifetime.^{11,15,23}

The formulations were prepared under a laminar air-flow hood. The added substances had been γ -sterilized at 2.0 Mrad and homogeneously dispersed in the aseptically prepared semisolid POE under aseptic conditions at a concentration of 1% (wt/wt). The viscous mixture was then loaded into a 1.0-mL hypodermic syringe, each sample being 100 μ L (120 mg).

Animals

Pigmented Fauve de Bourgogne female rabbits weighing from 2 to 3 kg, 10 to 12 weeks of age, were used in this study (Jean-Pierre Ravaut; Institute of Agricultural Research, Nouzilly, France), and experiments were conducted in accordance with the ARVO Statement for the Use of Animals in Ophthalmic and Vision Research. Six eyes of six animals were studied for each group.

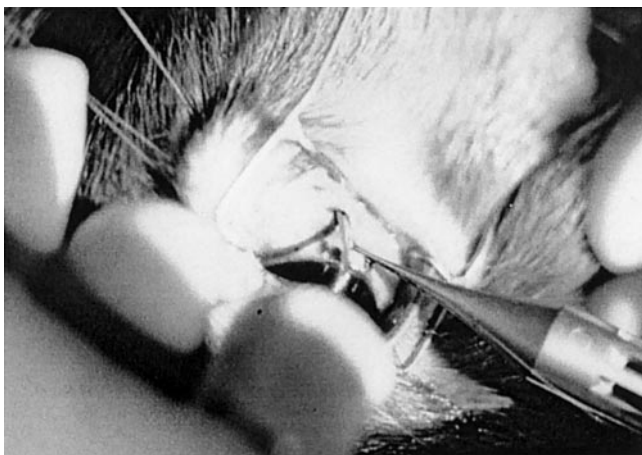


FIGURE 1. Injection of POE into the suprachoroidal space.

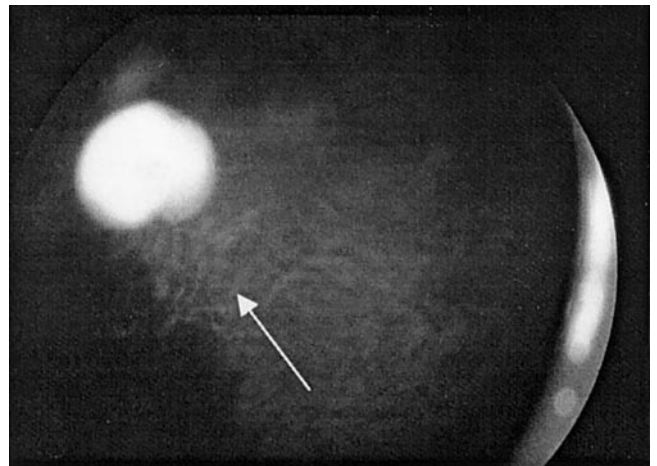


FIGURE 2. Fundus photograph on postoperative day 6, showing alterations in pigmentation after suprachoroidal POE injection (arrow).

Suprachoroidal Injection

The rabbits were sedated with 2 mg/kg intramuscular midazolam, and general anesthesia was induced with intramuscular injection of 50 mg/kg ketamine and 15 mg/kg xylazine. Pupils were dilated with topical 10% phenylephrine and 0.5% tropicamide, instilled every 10 minutes, beginning 1 hour before surgery. With rabbits under local anesthesia with oxybuprocaine 0.4% (Novesine; Ciba Vision, Basel, Switzerland), a lid speculum was placed. The conjunctiva and Tenon capsule were opened in the upper temporal quadrant, as appropriate for the extent of the procedure. A small (2-mm) full-thickness scleral incision was performed parallel to and 5 mm from the limbus. A 5- to 6-mm-long tunnelization of the sclera was made with microsurgical scissors to separate the sclera from the choroid and reveal the suprachoroidal space. A curved cannula with an olivary tip (0.6 mm of internal diameter) was introduced into the suprachoroidal space and advanced toward the posterior pole (Fig. 1). Each formulation was injected with an injection volume of 100 μ L. The needle tip was apposed to the inner wall of the sclera to avoid contact with the choroid. No reflux of material was observed through the sclerotomy. The scleral incision was sutured by 8-0 silk sutures. The conjunctiva was finally closed with 8-0 Vicryl sutures (Ethicon, Piscataway, NJ), and topical neomycin ointment was applied. The entire operation was



FIGURE 3. Macroscopic view of an enucleated eye on postoperative day 7, showing the fundus with pigment alteration (☆) and fragmented POE appearing as whitish spots (arrow).

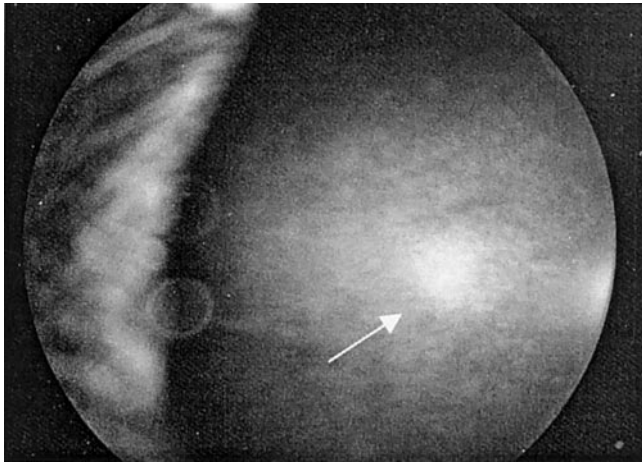


FIGURE 4. Fundus photograph on postoperative day 5, showing local retinal atrophy after suprachoroidal sodium hyaluronate injection (*arrow*).

observed and controlled under an operating microscope. The location of the injection was then noted with indirect ophthalmoscopy.

Clinical Follow-up

Rabbits were examined at regular intervals up to 3 weeks after surgery. Slit lamp observations were performed to assess the inflammatory state of the eye, with particular attention to the conjunctiva, the sclera, and the vitreous. Clinical signs of posterior inflammation were scored as follows: grade 0, clear vitreous cavity; grade 1, vitreous Tyndall, minimal fibrin exudate; grade 2, significant fibrin exudate; and grade 3, opaque vitreous hindering the examination of the fundus. Statistical analysis was performed to compare posterior inflammation between experimental and control eyes, using a nonparametric Mann-Whitney test. $P < 0.05$ was considered significant.

The fundus was regularly observed by indirect ophthalmoscopy. Photographs of the fundus were taken with a retinograph specially designed for small animals (Kowa Genesis; Luneau, Chartres, France). Intraocular pressure was measured by Goldmann applanation tonometry.

Ultrasound echography (Alcon, Fort Worth, TX) was performed at regular intervals to visualize POE localization in the suprachoroidal space. Ultrasonography was repeated until the polymer had totally disappeared.

A 10% fluorescein solution (Faure, Annonay, France) was injected intravenously with an injection volume of 0.5 mL. Fluorescein angiograms were performed with a fundus camera (SL6E; Topcon, Tokyo, Japan). Fluorescein angiography was performed at determined times after surgery to detect any consequence resulting from the presence of the polymer in the suprachoroidal space, such as leakage in the vascular bed of the choroid or the retina.

Histologic Analysis

Rabbits were killed at days 5, 12, and 20 after the procedure by intracardiac injection of a lethal dose of pentobarbital. Their eyes were enucleated, dissected, observed macroscopically, and photographed. Tissues were then fixed to be studied histologically.

The sclera, choroid, and retina were fixed for 2 hours in 2.5% glutaraldehyde in cacodylate buffer after careful orientation of the samples with respect to the polarity (center to periphery). Samples were then further processed in 0.1 M cacodylate buffer (pH 7.3), after fixing in osmium epoxide and embedding in LX 112 resin (Ladd, Burlington, VT). Subsequent semithin sections were obtained using an ultramicrotome and counterstained with toluidine blue. Semithin sections were analyzed using photonic microscopy and polarization.

Transmission Electron Microscopy

Ultrathin sections of the regions of interest were obtained for all samples, by cutting with an ultramicrotome, and counterstained with uranyl acetate and lead citrate. The sections were observed with a transmission electron microscope (CM10; Philips Electronics NV, Eindhoven, The Netherlands).

RESULTS

Clinical Observations

Immediately after injection, the polymer spread in a limited area of the suprachoroidal space at the extremity of the created tunnel, triggering some visible elevation of the retina and choroid on clinical observation. Twenty-four hours after surgery, POE spread in a larger and thinner area in the suprachoroidal space. No subretinal or choroidal hemorrhage or any retinal lesions were caused by the suprachoroidal injection. No vitreal Tyndall or retinal edema was observed at or around the location of polymer nor did any substance enter the subretinal space. All eyes were quiet, with no evidence of immediate or delayed intraocular inflammation. The grade of anterior and posterior inflammation was 0 for all eyes. Slight conjunctival hyperemia was observed, associated with the conjunctival incision. When the sclera was depressed, a depigmented zone of choroid was observed at the site of the scleral incision, as seen at the sclerotomy site during vitrectomy.

The only mild change noted in the appearance of the fundus was a minimal, stripelike alteration of the pigmentation in the region of the injected polymer, noted from postoperative day 1 (Fig. 2). These irregularities seemed to be due to a pigment redistribution in the choroidal melanosomes rather than to an alteration of the RPE cells, as later confirmed by histology. No significant increase in postoperative intraocular pressure or shallowing of the anterior chamber was noted. Macroscopic examination of the dissected eyes showed that polymer was fragmented into small, whitish bubbles (Fig. 3), which may be explained by a random degradation of the

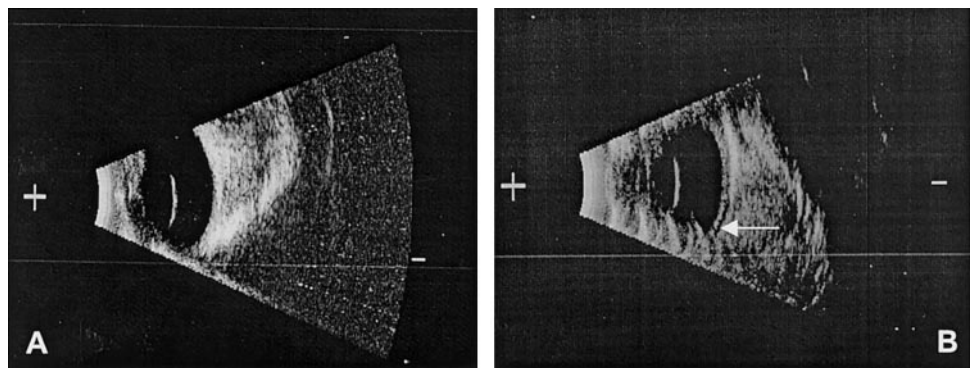


FIGURE 5. Echographic images on postoperative day 5, showing (A) a normal rabbit eye and (B) POE in the suprachoroidal space (hypoechoic zone, *arrow*).

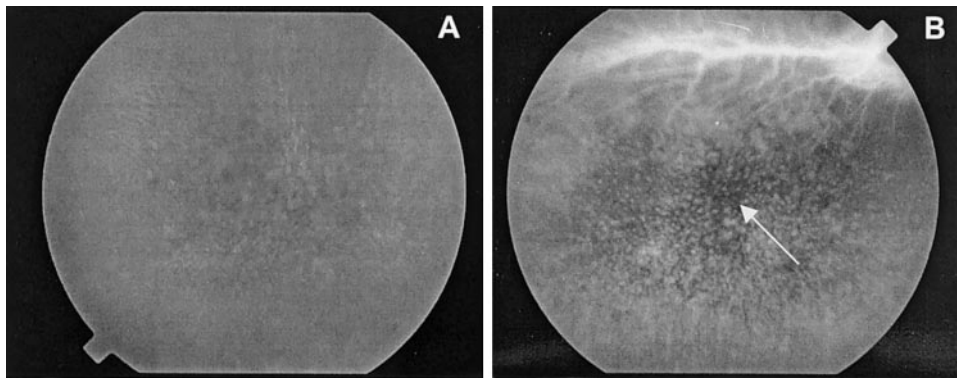


FIGURE 6. Fluorescein angiographic sequence on postoperative day 5, showing (A) a normal rabbit eye and (B) choroidal pigment alterations at the site of polymer injection (*arrow*).

polymer compressed to a thin film between the choroid and the sclera.

POE remained present in the suprachoroidal space for approximately 3 weeks. No significant differences could be noted between various experimental groups of POE, all of which appeared on clinical observation to have tolerated the treatment well. The control group having received sodium hyaluronate (Healon; Pharmacia Ophthalmics) exhibited a limited zone of choroidal atrophy, as shown in Figure 4.

Ultrasonography

Ultrasonography was performed on regular days after surgery to observe POE and its bioresorption from the suprachoroidal site, and results were compared with preoperative echographs (Fig. 5A). POE was clearly observed as a hypoechogenic substance in the suprachoroidal space, without triggering any choroidal detachment or hematoma (Fig. 5B). Indeed, no liquid accumulation was observed around the polymer. No retinal detachment was detected echographically at any place.

By echographic examinations, it was noted that the dark zone corresponding to the polymer in the suprachoroidal space passably thinned with time, with a total resorption at the end of the experiment, 3 weeks after surgery.

Fluorescein Angiography

Angiography was first performed in normal rabbit eyes (Fig. 6A) and then at regular intervals after surgery in experimental eyes. In the prearterial phase of the angiogram, the choroidal filling showed a limited alteration of choroidal coloration with punctuate mask effect, but no destruction or detachment of the RPE, which would have caused a window effect or a

subretinal leakage of the dye. The arterial and venous phases appeared normal and no late hyperfluorescence was observed, showing that the retinal vasculature's permeability was not altered. The choroidal pigment alterations remained stable during the angiographic sequence and were localized at the temporosuperior side of the optic disc, where the polymer had been injected (Fig. 6B). The POE itself was not visible; however, the observed scattered masking effect indicated that POE was partly located in the suprachoroidal space, partly in the choroid.

Angiograms were further performed at 1 and 2 weeks after the injection and did not show any changes with time. These results show that no retinal damage resulted from the suprachoroidal presence of 100 μ L of POE or of its degradation products.

Histology

In the area of injection, histologic examination revealed variable changes, depending on which formulation was introduced within the tissues. Eyes receiving sodium hyaluronate exhibited a marked disorganization of the architecture and pigmentation of the external retinal layers, with a focal loss of RPE, associated with a thickening vacuolization of external articles of the surrounding retina (Fig. 7). After the injection, small and contiguous vacuoles of sodium hyaluronate were observed in the choroid, along with a partial vacuolization of RPE cells, whose shape appeared irregular.

In eyes receiving POE, whether alone or containing MG or DEX, histologic examination of the tissues in the region of the injection showed vacuoles of variable size in the suprachoroi-

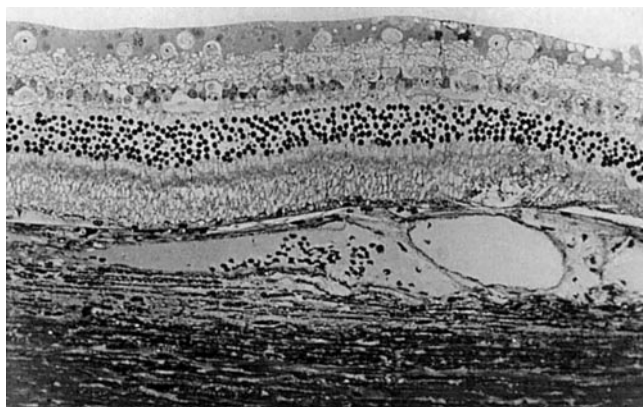


FIGURE 7. Semithin histologic section on postoperative day 5 of an eye injected with sodium hyaluronate in the suprachoroidal space. Toluidine blue; magnification, $\times 250$.



FIGURE 8. Semithin histologic section on postoperative day 19 of an eye injected with POE containing DEX, showing POE-filled vacuoles (*arrows*). Toluidine blue; magnification $\times 150$.

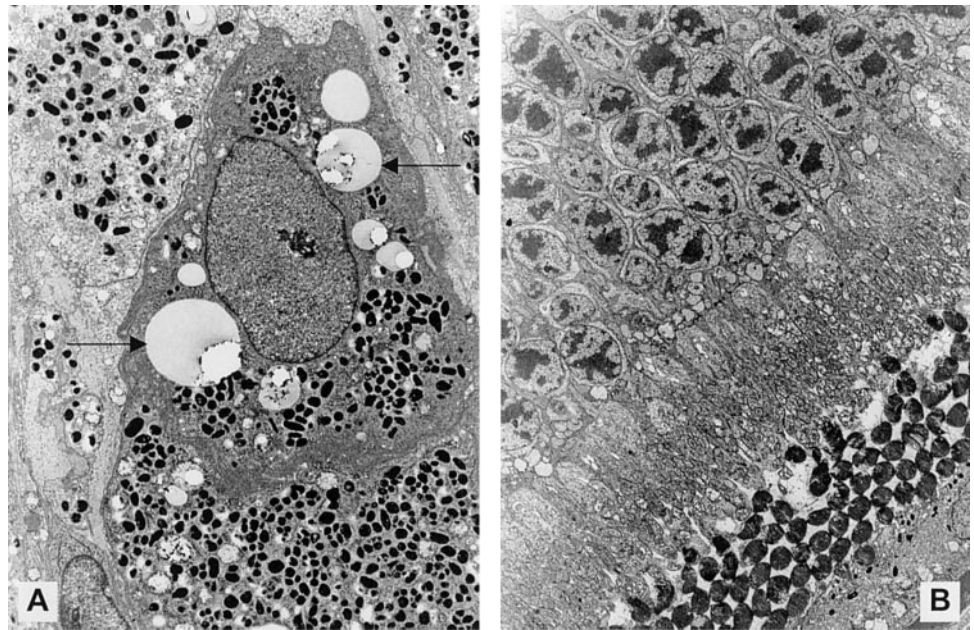


FIGURE 9. Transmission electron micrograph on postoperative day 19 of an eye injected with POE containing DEX. (A) Melanophagocyte with vacuoles containing POE (arrows). (B) Normal retina overlaying the site of POE injection. Magnification: (A) $\times 6600$; (B) $\times 2880$.

dal space and in the choroid, involving the external layers, for larger vacuoles, and the inner layers, for smaller vacuoles, next to the Bruch membrane (Fig. 8).

The vacuoles, empty or apparently filled with some material, possibly POE, mostly appeared in giant choroidal melanophages whose pigment showed a degree of redistribution. The phagocytic nature of these vacuoles was confirmed by transmission electron microscopy (Fig. 9A). No inflammatory cell infiltration was observed in the area of the POE injection at any time. Overlying the region of vacuoles, a thinned choroid and intact neuroretina were observed, without any inflammatory reaction. No major retinal disorganization of the main inner membranes of the eye was observed (Fig. 9B). Some small vacuoles also appeared in the endothelial cells of the choroidal vessels, and some were found in the choriocapillaries.

DISCUSSION

The ideal material for a suprachoroidal implantation should have the following properties: It should be injectable, to simplify the implantation procedure, yet viscous enough to be retained in the suprachoroidal space and deliver drugs locally. It should be immunologically inert and provoke no inflammatory reaction or foreign body response. Eventually, it should be degradable within an appropriate time to release the drug long enough to treat the neovascularization and should disappear from the injection site by complete bioresorption without sequelae. This study reports the suprachoroidal injection of a particularly good candidate that fulfills these conditions—a biocompatible, injectable, and bioerodible material, POE.

No difficulty was experienced in injecting 100 μL POE into the suprachoroidal space, the procedure being controllable by eye, nontraumatic, and reproducible.

Suprachoroidal injections of POE were well tolerated in the rabbit eye and caused no clinical complications; only a slight stripelike anomaly of the choroidal pigmentation was observed. This disturbance of the pigmentation occurs with other biomaterials, as reported after suprachoroidal implantation of a swelling urethane-based hydrophilic polymer.²⁴ In that study, the urethane polymer triggered a total loss of the pigment over the implant, so that a clear view of the sclera could be ob-

tained. Such a complication was not observed in our study, in which the pigment redistribution was minimal. It has also to be emphasized that the control group (i.e., eyes receiving a sodium hyaluronate injection), exhibited some atrophy of the RPE, which was not observed in the experimental POE groups.

The injection of 100 μL POE triggered no visible choroidal detachment. The suprachoroidal space is a virtual space, bounded anteriorly by the scleral spur and posteriorly by the optic nerve, with increased adhesion at the site of vortex veins and posterior ciliary arteries. The choroid is grossly elastic, with a good tensile strength, allowing moderate distension by injection into the suprachoroidal space. By ultrasonography, the polymer was located between the sclera and the choroid, triggering no bulge and limited spreading in the suprachoroidal space. This indicates that a focal drug release can potentially be achieved with this delivery system. Several investigators have reported a sharp, well-defined choroidal elevation after suprachoroidal injection of larger volumes ($>300 \mu\text{L}$) of products such as sodium hyaluronate,^{25,26} but in those studies, choroidal detachment reabsorbed without sequelae, which suggests that localized temporary distension of the suprachoroidal space with a biologically compatible material is a generally benign event.

After angiography, it was possible to conclude that the retinal and choroidal vasculature were not affected by the presence of 100 μL POE. The RPE cells were apparently intact, because no window effect was observed. A scattered masking effect indicated that POE was apparently located both in the suprachoroidal space and in the choroid itself. This was later confirmed by histopathologic analysis. Therefore, angiography allowed indirect confirmation of the localization of POE, at the temporoposterior pole of the median raphe.

Concerning the histologic reactions, no significant disorganization of the retina was observed in the experimental POE groups. Vacuoles were observed in the choroid and in the suprachoroidal space, and were close to the Bruch membrane. A favored hypothesis regarding the presence of these vacuoles consists in the possible phagocytosis of fragmented, randomly degraded POE by melanophages that had fused between each other and presented minor and inconsequential pigment redistribution. Giant, fused melanocytes have been observed in rabbit eyes after the implantation of stainless steel pieces.²⁷

The changes observed in our study were significantly minor compared with those described by Foulds et al.²⁴ after implantation of the urethane-based hydrophilic polymer. In this particular case, a striking mononuclear macrophagic response to the polymer was observed, with adjacent fibrosis in the choroid and chorioretinal fusion. In some specimens, choroidal fibrosis lead to total retinal atrophy, whereas in others there was reactionary proliferation of atrophic RPE cells.

Some vacuoles were also observed in the endothelium of the choroidal vasculature, which appears interesting for treatment of neovascularization. No inflammatory cell infiltration was observed at any time. No significant differences were found between the various POE groups in tissue biocompatibility.

Sodium hyaluronate has been used in the suprachoroidal space as a treatment for internal scleral buckling in cases of retinal detachment, without triggering any toxic or inflammatory reaction.^{25,26} In our experiments, sodium hyaluronate alone was found to cause more retinal atrophy than was observed after POE injection. There is no apparent reason for such toxicity; however, an explanation may be found in the injection procedure. Indeed, sodium hyaluronate is very fluid; the injection flow was rapid and turbulent, which may have disturbed the organization of the retina around the site of injection. POE, on the contrary, is very viscous and therefore it was injected slowly and smoothly, thus preventing any mechanical disturbance of the surrounding tissues.

Today, antiangiogenic molecules have been assayed in cancer therapy.²⁸ Their local delivery at the site of choroidal neovascularization would enable specific control of the growth of new vessels without undesirable systemic side effects. However, targeting the recurrent subretinal vessels remains a major difficulty. Hence, local, direct drug delivery is clearly preferable, through focal suprachoroidal administration, for example, near the macular area. The drug will then diffuse in a controlled and constant manner onto the macula, without triggering toxic effects in surrounding regions of the posterior segment. Because the blood flow in the choroid is particularly high, it would probably remove the drug rapidly from the interstices into the choroidal vascular bed. Therefore, a sustained administration of an accurate amount of antiangiogenic substance in an appropriate carrier in the early stage of CNV would be a major breakthrough. Another application would be the administration of a growth factor, allowing RPE migration and proliferation, after surgical removal of subretinal vascular membranes, to repopulate the excised area. POE was observed in the suprachoroidal space for approximately 3 weeks, which means that therapeutic concentrations can theoretically be maintained in situ during the same period. Indeed, POE undergoes surface erosion, and drug is released as the polymer erodes. In vivo results have demonstrated an effective sustained delivery in a model of filtering surgery in the rabbit,¹⁷ where 5-fluorouracil was released from POE over 2 weeks at nontoxic and therapeutic levels to prevent the failure of the surgery. This 2-week period corresponds to the physical presence of POE under the conjunctiva.

Among suggested therapeutic approaches in the pharmacologic treatment of neovascularization, the focal delivery of antiangiogenic drugs to the choroid represents an attractive possibility. An alternative would be the delivery of drugs that enhance RPE cell migration and proliferation after surgical ablation of choroidal neovascular membranes. Such drugs should be delivered by a sustained-release system, to maintain therapeutic levels over an extended period. A new therapeutic approach, based on viscous POE was investigated in the current study. Suprachoroidal injection of POE in the rabbit eye was a feasible and a reproducible procedure for administration. It was safe and nontraumatic, the risk of infection was limited,

and there was no penetration inside the vitreous cavity or through the retina.

To ensure that this biomaterial is appropriate for prolonged administration, repeated surgeries still must be investigated. The development of POE with a longer lifetime, as well as the pharmacokinetic determination of the release rate of selected drugs onto the choroid and the retina are currently under investigation. These studies also include confirmation of the tolerance of the formulations, because biocompatibility is case specific and therefore susceptible to change, depending on therapeutic entities incorporated in the formulations.

Acknowledgments

The authors thank Marie Marquise and Christian Mandon, animalists at the Hôtel Dieu Hospital, Paris, for assistance and Danièle Pascal for help with angiography.

References

- Ferris FL, Fine SL, Hyman L. Age-related macular degeneration and blindness due to neovascular maculopathy. *Arch Ophthalmol*. 1984;102:1640-1642.
- D'Amore PA. Mechanisms of retinal and choroidal neovascularization. *Invest Ophthalmol Vis Sci*. 1994;35:3974-3979.
- D'Amato RJ, Adamis AP. Angiogenesis inhibition in age-related macular degeneration. *Ophthalmology*. 1995;102:1261-1262.
- Ambati J, Gragoudas ES, Miller JW, et al. Transscleral delivery of bioactive protein to the choroid and retina. *Invest Ophthalmol Vis Sci*. 2000;41:1186-1191.
- Ferrara N, Alitalo K. Clinical applications of angiogenic growth factors and their inhibitors. *Nat Med*. 1999;5:1359-1364.
- Ishida K, Yoshimura N, Mandai M, Honda Y. Inhibitory effect of TNP-470 on experimental choroidal neovascularization in a rat model. *Invest Ophthalmol Vis Sci*. 1999;40:1512-1519.
- Martidis A, Miller DG, Ciulla TA, Danis RP, Moorthy RS. Corticosteroids as an antiangiogenic agent for histoplasmosis-related subfoveal choroidal neovascularization. *J Ocul Pharmacol Ther*. 1999;15:425-428.
- Castellarin AA, Nasir MA, Sugino IK, Zarbin MA. Clinicopathological correlation of primary and recurrent choroidal neovascularisation following surgical excision in age related macular degeneration. *Br J Ophthalmol*. 1998;82:480-487.
- Yasukawa T, Kimura H, Tabata Y, et al. Targeted delivery of anti-angiogenic agent TNP-470 using water-soluble polymer in the treatment of choroidal neovascularization. *Invest Ophthalmol Vis Sci*. 1999;40:2690-2696.
- Guyer DR, Schachat AP, Green WR. The choroid: structural considerations. In: Ryan SJ, ed. *Retina*. St Louis: Mosby; 1989:17-31.
- Einmahl S, Behar-Cohen FF, Tabatabay C, et al. A viscous bioerodible poly(ortho ester) as a new biomaterial for intraocular application. *J Biomed Mater Res*. 2000;50:566-573.
- Rothen-Weinhold A, Schwach-Abdellaoui K, Barr J, et al. Release of BSA from poly(ortho ester) extruded thin strands. *J Control Release*. 2001;71:31-37.
- Zignani M, Le Minh T, Einmahl S, et al. Improved biocompatibility of a viscous bioerodible poly(ortho ester) by controlling the environmental pH during degradation. *Biomaterials*. 2000;21:1773-1778.
- Merkli A, Heller J, Tabatabay C, Gurny R. The use of acidic and basic excipients in the release of 5-fluorouracil and mitomycin c from a semi-solid bioerodible poly (ortho ester). *J Control Release*. 1995;33:415-421.
- Einmahl S, Zignani M, Varesio E, et al. Concomitant and controlled release of dexamethasone and 5-fluorouracil from poly(ortho ester). *Int J Pharm*. 1999;185:189-198.
- Zignani M, Bernatchez SB, Le Minh T, et al. Subconjunctival bio-

- compatibility of a viscous bioerodible poly(ortho ester). *J Biomed Mater Res.* 1998;39:277-285.
17. Einmahl S, Behar-Cohen FF, D'Hermies F, et al. A new poly(ortho ester)-based drug delivery system for the adjunct treatment of filtering surgery. *Invest Ophthalmol Vis Sci.* 2001;42:695-700.
 18. Sintzel MB, Schwach-Abdellaoui K, Mäder K, et al. Influence of irradiation sterilization on a semi-solid poly(ortho ester). *Int J Pharm.* 1998;175:165-176.
 19. Merkli A, Heller J, Tabatabay C, Gurny R. Synthesis and characterization of a new biodegradable semi-solid poly(ortho ester) for drug delivery systems. *J Biomater Sci Polym Ed.* 1993;4:505-516.
 20. Merkli A, Heller J, Tabatabay C, Gurny R. Purity and stability assessment of a semi-solid poly(ortho ester) used in drug delivery system. *Biomaterials.* 1996;17:897-902.
 21. Zignani M, Merkli A, Sintzel MB, et al. New generation of poly(ortho esters): synthesis, characterization, kinetics, sterilization and biocompatibility. *J Control Release.* 1997;48:115-129.
 22. Proia AD, Hirakata A, McInnes JS, Scroggs MW, Parikh I. The effect of angiostatic steroids and beta-cyclodextrin tetradecasulfate on corneal neovascularization in the rat. *Exp Eye Res.* 1993;57:693-698.
 23. Zignani M, Einmahl S, Baeyens V, et al. A poly(ortho ester) designed for combined ocular delivery of dexamethasone sodium phosphate and 5-fluorouracil: subconjunctival tolerance and in vitro release. *Eur J Pharm Biopharm.* 2000;50:251-255.
 24. Foulds WS, Aitken D, Lee WR. Experimental suprachoroidal plom-bage with a urethane based hydrophilic polymer. *Br J Ophthalmol.* 1988;72:278-283.
 25. Mittl RN, Tiwari R. Suprachoroidal injection of sodium hyaluronate as an "internal" buckling procedure. *Ophthalmic Res.* 1987;19:255-260.
 26. Poole TA, Sudarsky RD. Suprachoroidal implantation for the treatment of retinal detachment. *Ophthalmology.* 1986;93:1408-1412.
 27. Ghadially FN, Chisholm IA, Lalonde JM. Giant melanosomes in the eye of the Dutch rabbit. *J Submicrosc Cytol.* 1982;14:63-72.
 28. Keshet E, Ben-Sasson SA. Anticancer drug targets: approaching angiogenesis. *J Clin Invest.* 1999;104:1497-1501.