

Redo-TAVI with SAPIEN 3 in SAPIEN XT or SAPIEN 3 – impact of pre- and post-dilatation on final THV expansion

David Meier^{1,2,3}, MD; Uri Landes^{4,5}, MD; Lars Sondergaard⁶, MD; Ole De Backer⁷, MD, PhD; Georg Lutter^{8,9}, MD; Thomas Puehler^{8,9}, MD; Mariama Akodad¹⁰, MD, PhD; Georgios Tzimas³, MD; Philipp Blanke³, MD; Geoffrey W. Payne¹¹, MSc, PhD; Althea Lai², BSc; Hacina Gill², BSc; David A. Wood^{1,3}, MD; John G. Webb^{1,3}, MD; Stephanie L. Sellers^{1,2,3}, MSc, PhD; Janarthanan Sathanathan^{1,2,3*}, MBChB, MPH

1. Centre for Cardiovascular Innovation, St Paul's Hospital, Vancouver, BC, Canada and Vancouver General Hospital, Vancouver, BC, Canada; 2. Cardiovascular Translational Laboratory, Vancouver, BC, Canada and Providence Research & Centre for Heart Lung Innovation, Vancouver, BC, Canada; 3. Centre for Heart Valve Innovation, St. Paul's Hospital, University of British Columbia, Vancouver, BC, Canada; 4. Edith Wolfson Medical Center, Holon, Israel; 5. Rabin Medical Center, Petah Tikva, Israel and Tel Aviv University, Tel Aviv, Israel; 6. Abbott Structural Heart, Santa Clara, CA, USA; 7. Rigshospitalet, Copenhagen University Hospital, Copenhagen, Denmark; 8. DZHK (German Centre for Cardiovascular Research), partner site Kiel/Hamburg/Lübeck, Kiel Germany; 9. Department of Cardiac and Vascular Surgery, University Medical Center Schleswig-Holstein, Campus Kiel, Kiel, Germany; 10. Institut Cardiovasculaire Paris Sud (ICPS), Hôpital privé Jacques Cartier, Ramsay Santé, Massy, France; 11. University of Northern British Columbia, Prince George, BC, Canada

S.L. Sellers and J. Sathanathan contributed equally to this manuscript.

KEYWORDS

- redo-TAVI
- redo-TAVR
- expansion
- predilatation
- post-dilatation

Abstract

Background: When a balloon-expandable transcatheter heart valve (THV) is chosen to treat a failed balloon-expandable THV, there is a risk of underexpansion with a potential impact on performance.

Aims: We aimed to assess the impact of pre- and post-dilatation on the expansion of balloon-expandable THVs after redo-transcatheter aortic valve implantation (TAVI).

Methods: Redo-TAVI was performed on the bench with a 23 mm SAPIEN 3 (S3) implanted within a 23 mm SAPIEN XT (SXT) or a 23 mm S3, both of which served as the “failed” THVs. Pre- and/or post-dilatation was performed using a 23 mm non-compliant TRUE balloon. Expansion of the index and redo-THVs were assessed before and after pre-/post-dilatation using microcomputed tomography (micro-CT), and THV hydrodynamic testing was conducted.

Results: Without pre- or post-dilatation, the S3 was underexpanded, for all combinations, particularly in the mid-portion of the THV (18.6 mm and 19.7 mm representing 81% and 86% of the nominal diameter inside the SXT and S3, respectively). Pre- and post-dilatation had an additive effect on diameter expansion of the redo-THV, which remained constrained in most combinations. The only combination to achieve nominal expansion was the S3 in S3 when both pre- and post-dilatation were performed. The S3 remained underexpanded inside the SXT despite pre- and post-dilatation (93% in the mid-portion). Improved redo-THV expansion was accompanied by 2.7 mm (12%) overexpansion of the index THV. While all samples had acceptable hydrodynamic performance, the underexpanded samples had worse leaflet pinwheeling.

Conclusions: When performing redo-TAVI with a 23 mm S3 inside a 23 mm SXT or S3, only the S3 in S3 with the use of pre- and post-dilatation reached full expansion. This underlines the importance of CT assessment of THV expansion and the role of pre-/post-dilatation.

*Corresponding author: Centre for Heart Valve Innovation, St. Paul's Hospital, Rm 166, 1081 Burrard Street, Vancouver, BC, V6Z 1Y6, Canada. E-mail: Jsathanathan@providencehealth.bc.ca

Abbreviations

EOA	effective orifice area
MG	mean gradient
TAVI	transcatheter aortic valve implantation
THV	transcatheter heart valve

Introduction

Patients with a transcatheter heart valve (THV) may develop structural valve degeneration, which may require reintervention. Redo-transcatheter aortic valve implantation (TAVI) is a treatment option for patients with failed THVs¹. Early experience with redo-TAVI has shown favourable outcomes in selected patients².

Overall, clinical experience is limited with redo-TAVI, and the optimal THV choice and positioning remain unknown. Some paired configurations of THVs in redo-TAVI may lead to suboptimal expansion or function which may impact THV performance and durability. For example, in the case of a failed short-frame balloon-expandable THV, the index failed valve may be underexpanded as previously reported³, and this might subsequently impact the expansion of the redo-THV following redo-TAVI. Use of a tall-frame valve with supra-annular leaflets may be associated with lower gradients, but this must be balanced against a high neoskirt which may potentially prevent future coronary access. If another short-frame valve is used for redo-TAVI, the redo-THV may be underexpanded and lead to elevated residual gradients⁴. Additionally, recent data have shown that underexpansion of the SAPIEN 3 (S3; Edwards Lifesciences) THV is associated with increased hypoattenuated leaflet thickening (HALT) and possibly an increased risk of mortality³. Post-dilatation of the THV following redo-TAVI, with or without predilatation of the failed THV, can be considered to optimise expansion. The feasibility and efficacy of balloon dilatation to optimise THV expansion following redo-TAVI is, however, unknown. The presence of 2 layers of THV frame may limit the effectiveness of post-dilatation or may require higher pressure and risk damaging the THV leaflets.

The present bench study reports the impact of pre- and/or post-dilatation on THV function and expansion when performing redo-TAVI in SAPIEN XT (SXT; Edwards Lifesciences) and S3 THVs.

Methods

Testing was performed at the Cardiovascular Translational Laboratory (Centre for Heart Lung Innovation, Vancouver, BC, Canada). The present work is a bench study in which no human or animal subjects were included and, thus, did not require ethical approval.

VALVES

SAPIEN XT and S3 THVs were considered the “failed” or “index” THVs in this analysis, and an S3 was always used as the new redo-THV. For all combinations, 23 mm THVs were used. One of the relevant differences between the SXT and the S3 is the frame height when deployed; when nominally deployed, the 23 mm SXT has a height of approximately 14 mm while the height of the 23 mm S3 is 18 mm⁵. Further THV design and features have been previously described in detail⁶.

REDO-TAVI BENCH PROCEDURE

For implantation of an S3 into an SXT, the S3 was positioned with the outflow approximately 20% above the outflow of the SXT, to maximise the effective orifice area (EOA) and reduce the residual transvalvular gradient⁷. Since the S3 is about 20% taller than the SXT, this positioning resulted in an alignment of the inflow of both THVs after deployment. For implantation of an S3 into an S3, the THV was positioned with the 2 outflows aligned.

PRE- AND POST-DILATATION PROCEDURE

Pre- and/or post-dilatation was performed using a 23 mm non-compliant TRUE dilatation balloon valvuloplasty catheter (Bard Peripheral Vascular, Inc.)⁸. Balloons were inflated using a large syringe, indeflator and high-pressure stopcock. The balloon was filled by hand injection with the syringe first, and then, the stopcock was opened to the indeflator to pressurise the balloon. The balloon was pressurised to 6 atmospheres, corresponding to the rated burst pressure of the balloon. The TRUE balloon was selected since it has been previously shown that a reliable over-expansion of the SXT can be achieved at 6 atmospheres with this type of non-compliant balloon but not with a semi-compliant balloon⁹.

In total, 8 configurations were tested and measured once:

- 1) S3 in SXT without predilatation, without post-dilatation.
- 2) S3 in SXT without predilatation, with post-dilatation.
- 3) S3 in SXT with predilatation, without post-dilatation.
- 4) S3 in SXT with predilatation, with post-dilatation.
- 5) S3 in S3 without predilatation, without post-dilatation.
- 6) S3 in S3 without predilatation, with post-dilatation.
- 7) S3 in S3 with predilatation, without post-dilatation.
- 8) S3 in S3 with predilatation, with post-dilatation.

Predilatation was performed on the index THV, before deploying the redo-THV, while post-dilatation was performed with the second THV in place (**Central illustration**).

IMAGING

Multimodality imaging was performed with photography, high-speed video, fluoroscopy and microcomputed tomography (micro-CT); high resolution photography and video were performed at the same magnification and fixed camera height. Photos and high-speed video were taken following redo-TAVI and after post-dilatation. Micro-CT was performed for each sample at baseline and after post-dilatation. All images were taken using the Nikon XT H 225 ST microfocuss X-ray tomography system (Nikon Metrology). A three-dimensional reconstruction of the micro-CT images was obtained using VGSTUDIO MAX software (version 3.5; Volume Graphics GmbH). Fluoroscopy of each sample was performed at baseline and after post-dilatation. Fluoroscopic images were acquired at a standard adult cardiac catheterisation laboratory (GE HealthCare, Chicago, IL, USA).

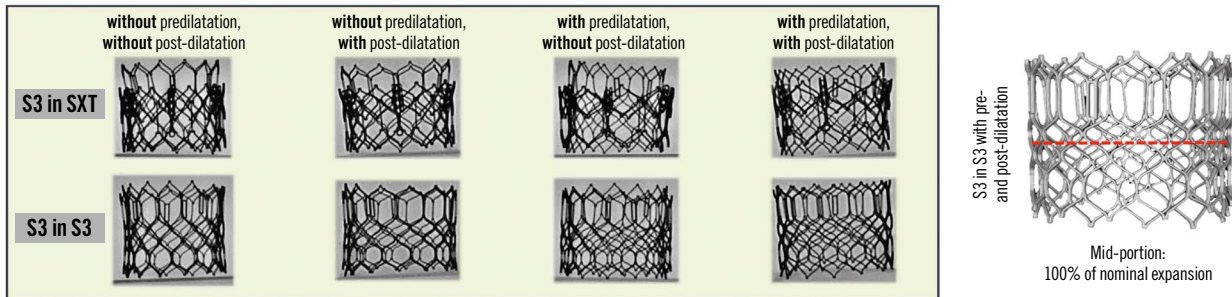
MICRO-CT MEASUREMENTS

Measurements were taken at the inflow, outflow, and mid-portion of the failed THV as well as at the inflow, outflow and mid-portion of

EuroIntervention

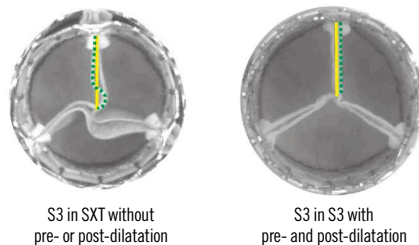
CENTRAL ILLUSTRATION Redo-TAVI with a 23 mm SAPIEN 3 in a 23 mm SAPIEN XT or SAPIEN 3: impact of pre- and post-dilatation using a TRUE dilatation balloon on final THV expansion and performance.

Redo-THV expansion



Redo-TAVI with a 23 mm S3 inside a 23 mm SXT or a 23 mm S3 resulted in underexpansion of the S3 in the absence of pre- or post-dilatation (81-86% of the nominal dimension). With pre- and/or post-dilatation, expansion improved (89-100% of the nominal dimensions). The only configuration to achieve nominal expansion was when pre- and post-dilatation were performed in the S3 in S3.

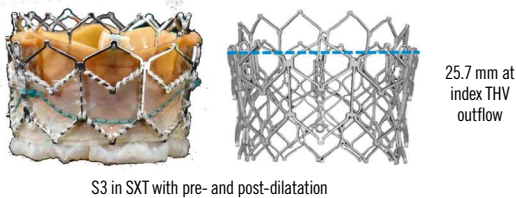
Hydrodynamic function and degree of pinwheeling



All samples had acceptable hydrodynamic performance.

However, samples where the redo-THV was underexpanded had notable leaflet pinwheeling which improved with balloon dilatation but was not fully eliminated, except for the S3 in S3 sample with pre- and post-dilatation.

Index THV expansion with pre- and post-dilatation



Pre- and post-dilatation resulted in an increase of the index THV expansion beyond its nominal size.

This was more evident at the outflow and more marked for the SXT (+2.7 mm) than for the S3 (+1.3 mm).

S3: SAPIEN 3; SXT: SAPIEN XT; TAVI: transcatheter aortic valve implantation; THV: transcatheter heart valve

the redo-THV. The area at each level was measured using Fiji imaging software (version 1.51f53; ImageJ) and compared to the labelled nominal size (23 mm). Measurements were taken at the mid-strut level as previously reported for surgical and transcatheter heart valves^{10,11}. This avoids under- or overestimation of the diameter due to blooming artefact when measuring the outer or inner diameter. Each measurement was repeated 3 times, and the mean value is reported. Of note, no standard deviation is reported for the purposes of simplicity, as the standard deviation was <1% for all samples.

PINWHEELING

Pinwheeling refers to the twisting of the leaflet-free edges, which results from excessive leaflet redundancy¹². Pinwheeling can be quantified using the pinwheeling index but can also be assessed visually as none, mild, moderate, or severe¹³. Here, pinwheeling was visually assessed in the 8 configurations tested using high-speed videos.

HYDRODYNAMIC ASSESSMENT

Hydrodynamic testing was performed before and after post-dilatation, using a commercially available pulse duplicator (ViVITro Labs). Valves were tested in accordance with ISO 5840-3:2021 guidelines¹². THVs were sealed in a holder fabricated from silicone with a Shore A durometer hardness of 40±5. The test fluid used was 0.9±0.2% sodium chloride test solution maintained at 37±2°C containing 1 drop/L of Cosmocil (Arxada), a bactericide. Valves were tested on the aortic side of the pulse duplicator with a spring-loaded disc valve (ViVITro Labs) on the mitral side of the pulse duplicator. Measurements were based on average results taken from 10 consecutive cycles. Pulsatile forward flow performance was tested at a nominal beat rate of 70±1 beats per minute, systolic duration of 35±5%, mean aortic pressure of 100±2 mmHg, and simulated cardiac outputs of 5.0±0.1 L/min. The mean gradient (MG) and EOA were assessed.

STATISTICS

Hydrodynamic variables are reported as mean±standard deviation (SD).

Results

Figure 1 shows photography and fluoroscopy of the different redo-TAVI combinations according to the pre-/post-dilatation strategy.

THV EXPANSION BY MICRO-CT

Detailed dimensions at each level (inflow, outflow, and mid-portion) of the redo and index THVs for the 8 configurations tested can be found in **Table 1** and **Table 2**, respectively. **Figure 2** outlines the relative increase in diameter according to the pre-/post-dilatation strategy in the mid-portion of the valve, which was the most constrained THV segment.

DIMENSIONS OF THE REDO-THV

Redo-TAVI with a 23 mm S3 in a 23 mm SXT

Overall, in the SXT, in the absence of pre- or post-dilatation, the S3 was severely underexpanded in its mid-portion (18.6 mm, 81%

of nominal diameter). Predilatation allowed for an improved S3 frame expansion, and the use of post-dilatation increased expansion only when predilatation was not performed.

In the absence of predilatation, the mean diameters at the inflow, mid-portion and outflow of the S3 were 20.4 mm, 18.6 mm (81% of nominal diameter) and 20.7 mm, respectively. Following post-dilatation, these dimensions increased to 22.1 mm, 21.2 mm (92% of nominal diameter), and 23.8 mm, respectively.

When predilatation was performed, the mean diameters at the inflow, mid-portion and outflow of the S3 were 21.4 mm, 20.1 mm (87% of nominal diameter) and 21.3 mm, respectively. This represents an 8% difference in expansion of the mid-portion compared to the strategy without predilatation. Following post-dilatation, these dimensions increased to 23.0 mm, 21.5 mm (94% of nominal diameter) and 23.3 mm, respectively. Compared to post-dilatation only, the combination of pre- and post-dilatation resulted in a 1% difference in the final expansion.




Figure 1. High-resolution photos and fluoroscopy of the different SAPIEN redo-TAVI combinations. S3: SAPIEN 3; SXT: SAPIEN XT; TAVI: transcatheter aortic valve implantation

Table 1. Micro-CT dimensions of the redo-THV.

Redo-TAVI configuration		Mean diameter (mm)					
		Inflow		Mid-portion		Outflow	
		Without post-dilatation	With post-dilatation	Without post-dilatation	With post-dilatation	Without post-dilatation	With post-dilatation
S3 in SXT	Without predilatation	20.4	22.1	18.6	21.2	20.7	23.8
	With predilatation	21.4	23.0	20.1	21.5	21.3	23.3
S3 in S3	Without predilatation	21.0	22.7	19.7	21.6	21.6	23.3
	With predilatation	21.7	22.8	20.3	23.0	21.5	23.2

CT: computed tomography; S3: SAPIEN 3; SXT: SAPIEN XT; TAVI: transcatheter aortic valve implantation; THV: transcatheter heart valve

Table 2. Micro-CT dimensions of the index THV.

Redo-TAVI configuration		Mean diameter (mm)					
		Inflow		Mid-portion		Outflow	
		Without post-dilatation	With post-dilatation	Without post-dilatation	With post-dilatation	Without post-dilatation	With post-dilatation
S3 in SXT	Without predilatation	22.5	23.4	22.5	23.8	22.8	25.0
	With predilatation	23.4	23.4	24.2	24.3	25.2	25.7
S3 in S3	Without predilatation	22.6	24.1	21.5	23.3	22.7	24.3
	With predilatation	23.6	23.8	23.4	23.6	23.4	24.1

CT: computed tomography; S3: SAPIEN 3; SXT: SAPIEN XT; TAVI: transcatheter aortic valve implantation; THV: transcatheter heart valve

Irrespective of the pre-/post-dilatation strategy, the midpoint of the S3 remained underexpanded when performing redo-TAVI in the SXT, despite improved expansion at the inflow and outflow.

Redo-TAVI with a 23 mm S3 in a 23 mm S3

Similarly to what was observed in the SXT, redo-TAVI in the S3 without pre- or post-dilatation led to underexpansion of the redo-THV (19.7 mm, 86% of nominal diameter). Unlike in the SXT, pre- and post-dilatation had an additive effect on expansion of the redo-THV. In the absence of predilatation, the mean diameter at the inflow, mid-portion and outflow of the S3 were 21.0 mm, 19.7 mm (86% of nominal diameter) and 21.6 mm, respectively. Following post-dilatation these dimensions increased to 22.7 mm, 21.6 mm (94% of nominal diameter), and 23.3 mm, respectively.

When predilatation only was performed, the mean diameters at the inflow, mid-portion and outflow of the S3 were 21.7 mm, 20.3 mm (88% of nominal diameter) and 21.5 mm, respectively. This represents a 2% difference in expansion of the mid-portion compared to the strategy without predilatation. When post-dilatation was added to predilatation, these dimensions increased to 22.8 mm, 23.0 mm (100% of nominal diameter) and 23.2 mm, respectively.

Only the combination of performing both pre- and post-dilatation resulted in full nominal expansion of the mid-portion of the S3.

DIMENSIONS OF THE INDEX THV

The dimensions of the index THV increased beyond nominal values when pre- and/or post-dilatation were performed. This phenomenon was more marked with the SXT than the S3, likely reflecting the increased thickness at the commissural post due to the different frame designs. In consequence, the increase in expansion was more marked at the outflow than at the inflow. Thus, following post-dilatation, the index SXT outflow was overexpanded by almost 3 mm, while the index S3 outflow was overexpanded by only 1 mm. At the level of the inflow and mid-portion, this increase was about 1 mm for with the SXT and less than 0.5 mm with the S3 (**Table 2**).

Redo-TAVI with a 23 mm S3 in a 23 mm SXT

In the absence of predilatation and post-dilatation, the mean diameters at the inflow, mid-portion and outflow of the index SXT were 22.5 mm, 22.5 mm and 22.8 mm, respectively. When both pre- and post-dilatation were performed, these dimensions increased beyond the nominal size to 23.4 mm, 24.3 mm and 25.7 mm, respectively.

Redo-TAVI with a 23 mm S3 in a 23 mm S3

A similar trend was observed when the index THV was the S3. In the absence of pre- and post-dilatation, the index THV was also underexpanded with a mean diameter at the inflow, mid-portion and outflow of 22.6 mm, 21.5 mm and 22.7 mm, respectively. When pre- and

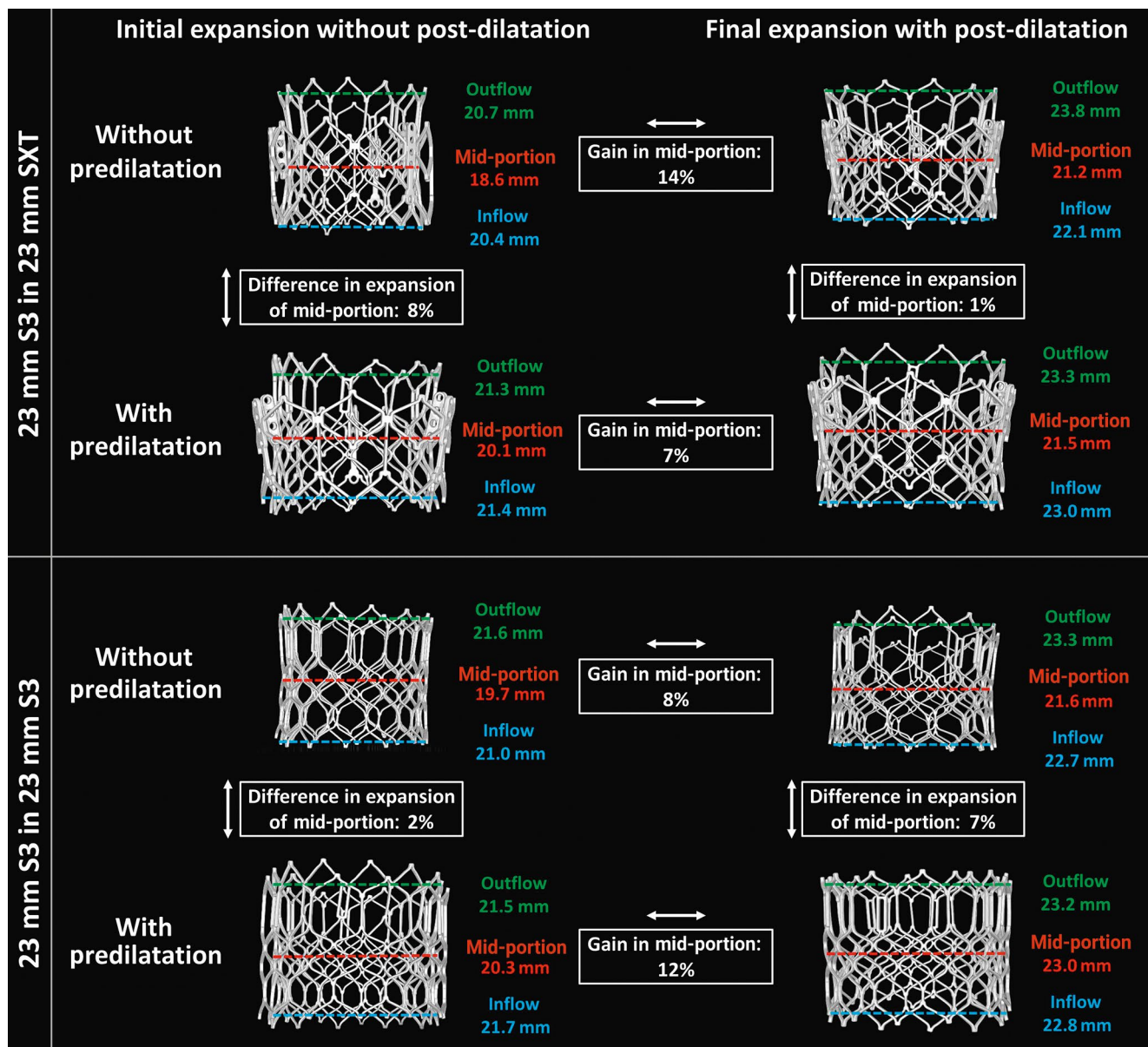


Figure 2. Micro-CT measurements of redo-THV expansion at the inflow, mid-portion and outflow according to procedural scenario. micro-CT: microcomputed tomography; S3: SAPIEN 3; SXT: SAPIEN XT; THV: transcatheter heart valve

post-dilatation where performed, these dimensions increased beyond the nominal size to 23.8 mm, 23.6 mm and 24.1 mm, respectively.

PINWHEELING

In the absence of predilatation, severe pinwheeling was observed in both samples, which was reduced using pre- and post-dilatation. Pinwheeling was improved for the S3 in S3 sample when predilatation was performed, and the only sample where no pinwheeling was observed was the 23 mm S3 in 23 mm S3 when both pre- and post-dilatation were performed (**Figure 3**).

HYDRODYNAMIC PERFORMANCE

Results of the hydrodynamic testing, in terms of the MG and EOA, for the 8 samples are reported in **Table 3**. At baseline, all

combinations resulted in an acceptable performance as per ISO standards.

Redo-TAVI with a 23 mm S3 in a 23 mm SXT

In the absence of predilatation, the MG and EOA of the S3 were 9.8 ± 0.11 mmHg and 1.96 ± 0.01 cm², respectively. Following post-dilatation, minimal changes were observed (MG 7.2 ± 0.50 mmHg, EOA 2.1 ± 0.0 cm²).

When predilatation was performed before redo-TAVI, the MG and EOA of the S3 were 8.0 ± 0.06 mmHg and 2.1 ± 0.01 cm², respectively, with almost no changes following post-dilatation (MG 7.3 ± 0.10 mmHg, EOA 2.1 ± 0.10 cm²).

Redo-TAVI with a 23 mm S3 in a 23 mm S3

In the absence of predilatation, the MG and EOA of the S3 were 7.5 ± 0.09 mmHg and 2.3 ± 0.01 cm², respectively, with almost

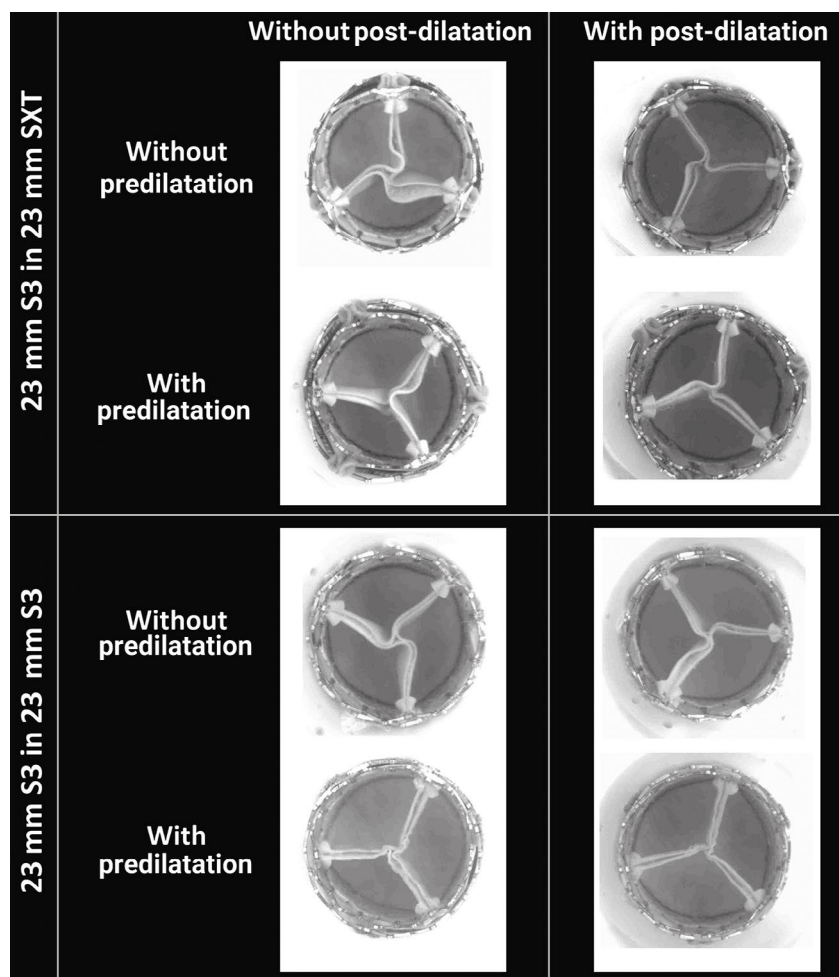


Figure 3. Images from the high-speed video showing the degree of pinwheeling of the SAPIEN XT (SXT) and SAPIEN 3 (S3) according to procedural scenario.

Table 3. Hydrodynamic performances of the THV before and after post-dilatation.

Redo-TAVI configuration		MG (mmHg)		EOA (cm ²)	
		Without post-dilatation	With post-dilatation	Without post-dilatation	With post-dilatation
S3 in SXT	Without predilatation	9.8 ± 0.1	7.2 ± 0.5	2.0 ± 0.0	2.1 ± 0.0
	With predilatation	8.0 ± 0.1	7.3 ± 0.1	2.1 ± 0.0	2.1 ± 0.1
S3 in S3	Without predilatation	7.5 ± 0.1	6.6 ± 0.3	2.3 ± 0.0	2.2 ± 0.1
	With predilatation	9.7 ± 0.1	7.0 ± 0.1	2.0 ± 0.0	2.2 ± 0.0

EOA: effective orifice area; MG: mean gradient; S3: SAPIEN 3; SXT: SAPIEN XT; TAVI: transcatheter aortic valve implantation; THV: transcatheter heart valve

no difference following post-dilatation (MG 6.6±0.30 mmHg, EOA 2.2±0.1 cm²). When predilatation was performed before redo-TAVI, the MG and EOA of the S3 were 9.7±0.13 mmHg and 1.96±0.02 cm², respectively. In this configuration, post-dilatation had the largest impact, since the MG decreased to 7.0±0.10 mmHg and the EOA increased to 2.2±0.0 cm².

Discussion

We demonstrate the following when performing a SAPIEN in SAPIEN redo-TAVI: 1) In the absence of pre- and/or post-dilatation, the redo-THV is significantly underexpanded, and even with

post-dilatation, the mid-portion of the THV remains constrained in most scenarios; 2) only the S3 in S3 redo-TAVI combination achieved uniform expansion when both pre- and post-dilatation were performed; and 3) the use of post-dilatation increases the dimensions of the index THV beyond its nominal size, which may impact procedural planning and risk prediction for annular injury.

In almost all scenarios (except for the S3 in S3 with pre- and post-dilatation), we observed some degree of underexpansion of the redo-THV mid-portion with some flaring at the inflow and outflow. The degree of diameter underexpansion was significant, with an expansion as low as 81% at the mid-portion. This

underexpansion resulted in significant pinwheeling of the leaflets. This would likely be even worse in the case of a degenerated THV where the leaflets may be thickened and calcified. Non-uniform expansion can lead to impaired leaflet kinematics and increased pinwheeling which may impact long-term durability¹⁴. While long-term clinical data are currently lacking, it has been shown that asymmetric expansion is associated with HALT and increased 1-year mortality^{3,15}. Moreover, some limited data have suggested a possible association between HALT and symptomatic valve deterioration¹⁶. These findings have implications for procedural planning and device selection. Procedural strategies that allow optimised expansion may aid both acute- and long-term valve performance. Hence, a self-expanding THV design with supra-annular leaflets where valve function and leaflet kinematics are less dependent on valve expansion may be considered in the case of a failed SAPIEN THV.

Effect of pre- and/or post-dilatation on expansion

Overall, pre- and/or post-dilatation improved expansion and reduced pinwheeling. It appears that the combination of both pre- and post-dilatation had an additive effect on the final expansion but that the magnitude of the effect varied depending on the THV combination. The S3 in S3 combination using pre- and post-dilatation was the only scenario which led to a full expansion of the S3 at the inflow, mid-portion and outflow. All the other scenarios led to residual underexpansion of the redo-THV. These results suggest that, even without considering patient specificity, each THV combination has unique features and that no class effect can be assumed in terms of procedural strategy. Of note, for the S3 in SXT combination, the overexpansion at the outflow of the S3 is likely related to the fact that this area did not have 2 layers of THV stent, since the S3 is taller than the SXT.

Dimensions of the index THV

The present work also offers valuable insights in the understanding of the index THV metamorphism in redo-TAVI. While the use of pre- and/or post-dilatation allows for optimised redo-THV expansion, it also expands the index THV beyond its nominal size. The magnitude of this effect was almost 3 mm at the outflow when the index THV was the SXT, while it was around 1 mm when the index THV was the S3. This difference is likely related to the thickness of the sutures at the level of the commissural post, which is more important for the SXT than for the S3. At the level of the inflow, likely to be situated closer to the annulus, this phenomenon was less marked, not exceeding 1 mm with either index THV. This element should be taken into consideration when planning redo-TAVI given the potential risk for annular damage depending on the extent of calcification and annular dimensions. Additionally, the overexpansion at the outflow might have an unpredictable impact on risk of coronary obstruction, decreasing the valve-to-coronary distance in patients with small sinuses of Valsalva and coronary ostia arising along the THV stent frame. Similarly to the magnitude of underexpansion of the redo-THV, the degree of overexpansion of the index THV is likely to be more important in the presence of leaflet thickening and/or the

presence of pannus. Thus, the decision to pre- and/or postdilate the THV should be based on the patient's annulus size/adverse root features. In cases where anatomical dimensions are borderline, it may be reasonable to avoid dilatation of the valve or to use a smaller balloon to mitigate the risk of the overexpansion of the index THV and damage to the anatomy. Alternatively, redo-TAVI with a self-expanding THV with a supra-annular leaflet position can be considered.

Limitations

The present work has some limitations inherent to bench testing. Indeed, bench testing may not entirely reflect how a THV will expand within a degenerated THV, as many factors such as leaflet calcification and native root anatomy are not represented in this study. Thus, it is likely that more underexpansion of the redo-THV would be observed and that, in the presence of thickened leaflets, the dimensions of the index THV could even increase beyond what was observed in the present study. Nevertheless, the present work suggests that pre- and post-dilatation can have an additive effect in some situations depending on the THV combination. Only one size of THV was tested and one sample was used for each combination. Furthermore, as would be done clinically, commissural alignment was random in the present study, and whether overlap of commissural tabs would increase the degree of underexpansion remains unknown. Finally, given the degree of underexpansion observed, a strategy where the second THV is downsized compared to the index THV warrants further study.

Conclusions

When performing redo-TAVI with an S3 inside an SXT or S3, only the S3 in S3 with the use of pre- and post-dilatation reached full redo-THV expansion. This underlines the importance of assessment of THV expansion with CT and the importance of considering pre- and/or post-dilatation at the time of redo-TAVI.

Further analyses of clinical series are needed to better understand procedural techniques that can lead to optimised expansion and improved long-term performance of THVs in the context of redo-TAVI.

Impact on daily practice

When performing redo-TAVI, there is a risk of underexpansion and a high residual gradient for the redo-THV. The impact of pre- and/or post-dilatation on expansion is unclear. In the present study, redo-TAVI with a SAPIEN 3 implanted within a SAPIEN XT or another SAPIEN 3 almost always resulted in underexpansion of the redo-THV despite the use of pre- and/or post-dilatation. Improved redo-THV expansion was accompanied by an expansion of the index THV beyond its nominal size. This underlines the importance of CT assessment of THV expansion and the role of pre-/post-dilatation. The long-term implications of THV underexpansion following redo-TAVI on performance and durability need to be determined.

Funding

D. Meier is supported by the Swiss National Science Foundation (grant P2LAP3_199561, Bern, Switzerland) and the SICPA foundation (Lausanne, Switzerland). G. Tzimas is supported by the Fondation Vaudoise de Cardiologie (Lausanne, Switzerland) and the SICPA foundation (Lausanne, Switzerland).

Conflict of interest statement

L. Sondergaard is the Chief Medical Officer and Divisional VP for Medical Affairs at Abbott Structural Heart; and has received consultant fees and/or institutional research grants from Abbott, Boston Scientific, Medtronic, and SMT. G. Lutter is a consultant to Edwards Lifesciences, Medtronic, and Abbott. T. Puehler is a consultant to Abbott. P. Blanke provides institutional CT core laboratory services to Edwards Lifesciences, Medtronic, Boston Scientific, Abbott Laboratories, PiCardia, and Neovasc, without direct personal reimbursements; and is a consultant to Edwards Lifesciences. J.G. Webb is a consultant to and has received research funding from Edwards Lifesciences, Abbott, and ViVivo Labs. J. Sathananthan is a consultant to Edwards Lifesciences, Medtronic, and Boston Scientific; and has received research funding from Edwards Lifesciences and Medtronic. D.A. Wood is a consultant to and has received research funding from Edwards Lifesciences and Abbott. S.L. Sellers is a consultant for Edwards Lifesciences and Medtronic. The other authors have no conflicts of interest to declare.

References

- Landes U, Sathananthan J, Witberg G, De Backer O, Sondergaard L, Abdel-Wahab M, Holzhey D, Kim WK, Hamm C, Buzzatti N, Montorfano M, Ludwig S, Conradi L, Seiffert M, Guerrero M, El Sabbagh A, Rodés-Cabau J, Guimaraes L, Codner P, Okuno T, Pilgrim T, Fiorina C, Colombo A, Mangieri A, Eltchaninoff H, Nombela-Franco L, Van Wiechen MPH, Van Mieghem NM, Tchétché D, Schoels WH, Kullmer M, Tamburino C, Sinning JM, Al-Kassou B, Perlman GY, Danenberg H, Ielasi A, Fraccaro C, Tarantini G, De Marco F, Redwood SR, Lisko JC, Babaliarios VC, Laine M, Nerla R, Castriota F, Finkelstein A, Loewenstein I, Eitan A, Jaffe R, Ruile P, Neumann FJ, Piazza N, Alosaimi H, Sievert H, Sievert K, Russo M, Andreas M, Bunc M, Latib A, Godfrey R, Hildick-Smith D, Chuang MA, Blanke P, Leipsic J, Wood DA, Nazif TM, Kodali S, Barbanti M, Kornowski R, Leon MB, Webb JG. Transcatheter Replacement of Transcatheter Versus Surgically Implanted Aortic Valve Bioprostheses. *J Am Coll Cardiol*. 2021;77:1-14.
- Landes U, Webb JG, De Backer O, Sondergaard L, Abdel-Wahab M, Crusius L, Kim WK, Hamm C, Buzzatti N, Montorfano M, Ludwig S, Schofer N, Voigtlaender L, Guerrero M, El Sabbagh A, Rodés-Cabau J, Guimaraes L, Kornowski R, Codner P, Okuno T, Pilgrim T, Fiorina C, Colombo A, Mangieri A, Eltchaninoff H, Nombela-Franco L, Van Wiechen MPH, Van Mieghem NM, Tchétché D, Schoels WH, Kullmer M, Tamburino C, Sinning JM, Al-Kassou B, Perlman GY, Danenberg H, Ielasi A, Fraccaro C, Tarantini G, De Marco F, Witberg G, Redwood SR, Lisko JC, Babaliarios VC, Laine M, Nerla R, Castriota F, Finkelstein A, Loewenstein I, Eitan A, Jaffe R, Ruile P, Neumann FJ, Piazza N, Alosaimi H, Sievert H, Sievert K, Russo M, Andreas M, Bunc M, Latib A, Godfrey R, Hildick-Smith D, Sathananthan J, Hensey M, Alkhourair A, Blanke P, Leipsic J, Wood DA, Nazif TM, Kodali S, Leon MB, Barbanti M. Repeat Transcatheter Aortic Valve Replacement for Transcatheter Prosthesis Dysfunction. *J Am Coll Cardiol*. 2020;75:1882-93.
- Fukui M, Bapat VN, Garcia S, Dworak MW, Hashimoto G, Sato H, Gossli M, Enriquez-Sarano M, Lesser JR, Cavalante JL, Sorajja P. Deformation of Transcatheter Aortic Valve Prostheses: Implications for Hypoattenuating Leaflet Thickening and Clinical Outcomes. *Circulation*. 2022;146:480-93.
- Landes U, Richter I, Danenberg H, Kornowski R, Sathananthan J, De Backer O, Sondergaard L, Abdel-Wahab M, Yoon SH, Makkar RR, Thiele H, Kim WK, Hamm C, Buzzatti N, Montorfano M, Ludwig S, Schofer N, Voigtlaender L, Guerrero M, El Sabbagh A, Rodés-Cabau J, Mesnier J, Okuno T, Pilgrim T, Fiorina C, Colombo A, Mangieri A, Eltchaninoff H, Nombela-Franco L, Van Wiechen MPH, Van Mieghem NM, Tchétché D, Schoels WH, Kullmer M, Barbanti M, Tamburino C, Sinning JM, Al-Kassou B, Perlman GY, Ielasi A, Fraccaro C, Tarantini G, De Marco F, Witberg G, Redwood SR, Lisko JC, Babaliarios VC, Laine M, Nerla R, Finkelstein A, Eitan A, Jaffe R, Ruile P, Neumann FJ, Piazza N, Sievert H, Sievert K, Russo M, Andreas M, Bunc M, Latib A, Bruoha S, Godfrey R, Hildick-Smith D, Barbash I, Segev A, Maurovich-Horvat P, Szilveszter B, Spargias K, Aravadinis D, Nazif TM, Leon MB, Webb JG. Outcomes of Redo Transcatheter Aortic Valve Replacement According to the Initial and Subsequent Valve Type. *JACC Cardiovasc Interv*. 2022;15:1543-54.
- Schymik G, Schröfel H, Heimeshoff M, Luik A, Thoenes M, Mandinov L. How to adapt the implantation technique for the new SAPIEN 3 transcatheter heart valve design. *J Interv Cardiol*. 2015;28:82-9.
- Sathananthan J, Fraser R, Landes U, Rich C, Sellers SL, Leipsic J, Blanke P, Lutter G, Frank D, Puehler T, Wood DA, Sondergaard L, Webb JG. Repeat transcatheter aortic valve implantation and implications for transcatheter heart valve performance: insights from bench testing. *EuroIntervention*. 2021;17:856-64.
- Simonato M, Webb J, Kornowski R, Vahanian A, Frerker C, Nissen H, Bleiziffer S, Duncan A, Rodés-Cabau J, Attizzani GF, Horlick E, Latib A, Bekeredjian R, Barbanti M, Lefevre T, Cerillo A, Hernández JM, Bruschi G, Spargias K, Iadanza A, Brecker S, Palma JH, Finkelstein A, Abdel-Wahab M, Lemos P, Petronio AS, Champagnac D, Sinning JM, Salizzoni S, Napodano M, Fiorina C, Marzocchi A, Leon M, Dvir D. Transcatheter Replacement of Failed Bioprosthetic Valves: Large Multicenter Assessment of the Effect of Implantation Depth on Hemodynamics After Aortic Valve-in-Valve. *Circ Cardiovasc Interv*. 2016;9:e003651.
- Sathananthan J, Fraser R, Hatoum H, Barlow AM, Stanová V, Allen KB, Chhatrivala AK, Rieu R, Pibarot P, Dasi LP, Sondergaard L, Wood DA, Webb JG. A bench test study of bioprosthetic valve fracture performed before versus after transcatheter valve-in-valve intervention. *EuroIntervention*. 2020;15:1409-16.
- Sathananthan J, Sellers S, Barlow A, Hensey M, Landes U, Cheung A, Ye J, Alkhourair A, Blanke P, Sondergaard L, Pibarot P, Wood D, Leipsic J, Webb J. Overexpansion of older generation balloon expandable transcatheter heart valves: An ex-vivo bench study. *Catheter Cardiovasc Interv*. 2019;94:806-11.
- Sathananthan J, Sellers S, Barlow A, Fraser R, Stanová V, Cheung A, Ye J, Alenezi A, Murdoch DJ, Hensey M, Dvir D, Blanke P, Rieu R, Wood K, Pibarot P, Leipsic J, Webb J. Overexpansion of the SAPIEN 3 Transcatheter Heart Valve: An Ex Vivo Bench Study. *JACC Cardiovasc Interv*. 2018;11:1696-705.
- Anastasius M, Godoy M, Weir-McCall JR, Bapat V, Sathananthan J, Hensey M, Sellers SL, Cheung A, Ye J, Wood DA, Leipsic J, Webb J, Blanke P. Reference dimensions of stented surgical aortic bioprostheses for valve size determination. *EuroIntervention*. 2020;16:e502-6.
- ISO 5840-3:2021. Cardiovascular implants - Cardiac valve prostheses - Part 3: Heart valve substitutes implanted by transcatheter techniques. Geneva, Switzerland: International Standards Organization; 2021. <https://www.iso.org/standard/67606.html>. (Last accessed 24 June 2023).
- Sathananthan J, Sellers SL, Fraser R, Dvir D, Hensey M, Murdoch DJ, Blanke P, Pibarot P, Toggweiler S, Wood D, Leipsic J, Webb JG. Impact of implant depth on hydrodynamic function with the ACURATE neo transcatheter heart valve following valve-in-valve transcatheter aortic valve replacement in Mitroflow bioprosthetic valves: an ex vivo bench study. *EuroIntervention*. 2019;15:78-87.
- Sathananthan J, Sellers S, Barlow AM, Stanova V, Fraser R, Toggweiler S, Allen KB, Chhatrivala A, Murdoch DJ, Hensey M, Lau K, Alkhourair A, Dvir D, Asgar AW, Cheung A, Blanke P, Ye J, Rieu R, Pibarot P, Wood D, Leipsic J, Webb JG. Valve-in-Valve Transcatheter Aortic Valve Replacement and Bioprosthetic Valve Fracture Comparing Different Transcatheter Heart Valve Designs: An Ex Vivo Bench Study. *JACC Cardiovasc Interv*. 2019;12:65-75.
- Fuchs A, De Backer O, Brooks M, de Knecht MC, Bieliauskas G, Yamamoto M, Yanagisawa R, Hayashida K, Sondergaard L, Kofeod KF. Subclinical leaflet thickening and stent frame geometry in self-expanding transcatheter heart valves. *EuroIntervention*. 2017;13:e1067-75.
- Hein M, Schoechlin S, Schulz U, Minners J, Breitbart P, Lehane C, Neumann FJ, Ruile P. Long-Term Follow-Up of Hypoattenuated Leaflet Thickening After Transcatheter Aortic Valve Replacement. *JACC Cardiovasc Interv*. 2022;15:1113-22.