

Outcome after proximal femoral fractures during primary total hip replacement by the direct anterior approach

Hannes A. Rüdiger · Michael Betz ·
Patrick O. Zingg · John McManus ·
Claudio F. Dora

Received: 31 May 2011 / Published online: 19 February 2013
© Springer-Verlag Berlin Heidelberg 2013

Abstract

Background The literature suggests that intraoperative fractures of the greater trochanter and the metaphysis are increased with uncemented stems and the direct anterior approach. This study aims to determine the incidence and assess the functional and radiological outcome after such fractures.

Methods 484 consecutive total hip replacements (THR) (64 ± 12 years) were analyzed. We treated trochanteric fractures conservatively without any further denuding, and secured metaphyseal fissures with cerclages. Postoperative X-rays and at the latest follow-up were compared to assess secondary fracture displacement and stem subsidence. Western Ontario and McMaster Universities Arthritis Index (WOMAC) scores after 1 year were analyzed. For each patient sustaining a fracture, two patients without fractures were matched in terms of age, body mass index and gender.

Results 13 (2.7 %, 5 male, 68 ± 9 years) patients with intraoperative fractures of the greater trochanter ($n = 8$) or the metaphysis ($n = 5$) were analyzed. Consolidation was observed in 7/8 patients sustaining a trochanteric fracture

while secondary displacement of the fragment occurred in one case. Stem subsidence was observed in 2/5 cases (5 and 7 mm). Patients who sustained a fracture showed a trend towards poorer WOMAC scores at 1 year postoperatively, compared to patients without fractures. A significantly increased joint stiffness was also observed.

Conclusion The intraoperative fracture risk in this series of THR through a direct anterior approach was 2.7 %. Trochanteric fractures do heal without primary fixation. Metaphyseal fractures heal well if immediately stabilized with a cerclage.

Keywords Total hip arthroplasty · Intraoperative fracture · Anterior approach · Outcome

Introduction

Perioperative fractures during total hip replacement are a known risk [1–6]. Berry [3] reported an incidence 0.3 % with cemented and 5.4 % with uncemented implants, respectively.

Limited exposure due to small incisions or minimally invasive surgery has been claimed to be a relevant risk factor [7]. Whereas different investigations have focused on a broad range of other risk factors, the clinical impact of such fractures is still ill defined.

Using a minimally invasive direct anterior approach [8] for all routine primary THR since 2005 we occasionally encountered intraoperative fractures of the greater trochanter and the metaphyseal region. The purpose of the present study was: (1) to determine the incidence of perioperative greater trochanter and metaphyseal fractures, (2) to assess their early functional outcome, and (3) to analyze the risk for secondary fracture dislocation or stem

The authors confirm that this research has been carried out in full compliance with the current applicable laws of the country in which this research was performed.

H. A. Rüdiger · M. Betz · P. O. Zingg · C. F. Dora
Department of Orthopaedics, University of Zurich,
Balgrist, Zurich, Switzerland

H. A. Rüdiger (✉) · J. McManus
Department of Orthopaedics, Centre Hospitalier Universitaire
Vaudois (CHUV), Site Hôpital Orthopédique,
University of Lausanne, Av. Pierre-Decker 4,
1011 Lausanne, Switzerland
e-mail: ortho@mm.st

subsidence in our consecutive series of the first 484 primary THA performed through a direct anterior approach.

Patients and methods

484 consecutive primary THR (patients) using the minimally invasive direct anterior approach between January 2005 and December 2007 were identified from our computerized institutional database and retrospectively analyzed. All patients were operated on at the University of Zurich, Balgrist, a training center where the surgeries were carried out by the surgical team, including surgeons in training. An uncemented straight Quadra-H[®] stem with a Versafit[®] pressfit cup and metal-on-highly crosslinked polyethylene wear couple (Medacta, Castel San Pietro/Switzerland) was used in all cases. THR was performed with the patient supine on a traction table (Medacta) using regional or general anesthesia. The standard rehabilitation program consisted of weight bearing as tolerated with two crutches starting the day after surgery for 2 weeks.

The institutional database collects data on the intraoperative and postoperative complications. In addition, for the purposes of this study, an exhaustive review of the charts, the postoperative reports and all available imaging was performed retrospectively to identify patients who sustained intraoperative fractures. In case of metaphyseal fractures, double Cerclage wiring was performed through the initial approach, as proposed earlier by Berend et al. [2]. The approach had to be extended distally in some cases. The rehabilitation protocol was left unchanged. In cases suffering a greater trochanteric fracture, it was our practice to treat conservatively to avoid any soft tissue stripping that could impair bony perfusion and healing. The rehabilitation protocol was adapted and all patients were instructed to partially weight bear (i.e., max 15 kg with two crutches) for 6 weeks. Hip flexion was limited to 70° to minimize potential displacing forces on the greater trochanter.

All patients routinely had plain X-rays preoperatively, plain X-rays in recovery and at 3 months, as well as patient-centred self-administered Western Ontario and McMaster Universities Arthritis Index (WOMAC) [9] 1 year after surgery. Clinical examination at 1 year included assessment of gait and Trendelenburg sign as well as plain X-rays (antero-posterior pelvic and cross-table lateral views). Fractures of the greater trochanter were assessed in terms of bony union and secondary displacement, metaphyseal fractures in terms of stem subsidence. For further analysis, patients were separated into groups, those having sustained a perioperative fracture (fracture group) and patients without fracture (control group). In addition, for each patient, who sustained an intraoperative fracture, two

patients without fractures from the control group were matched manually in terms of gender, age (± 5 years), and body mass index (± 5 kg/m²) (matched control group). The fracture group was then separately compared to the control group and the matched controls.

Statistical analysis was performed by a biostatistician consultant using SPSS[®] software package (Version 14.0; Somers/NY). For comparisons of two groups, the Mann–Whitney *U* test was used for continuous variables. Binary parameters were compared using the Fischer's exact test. We performed a power analysis based on the unpaired *t* test for logarithmically transformed WOMAC score with a two tailed alpha of 0.05. To reach a statistical power of 80 %, 35 cases would have been necessary in the fracture group.

Results

Thirteen fractures in 484 THR were recorded (2.7 %): 5 simple metaphyseal (1 %) and 8 greater trochanter (1.7 %) fractures.

Table 1 summarizes patient demographics of the study, control and paired matched control groups. In terms of age, sex, and body mass index no differences are encountered.

Figure 1 summarizes the follow-up WOMAC scores of all three groups after a median follow of 15 months (range 12–29 months), which did not differ significantly between the study and the control group ($p = 0.058$). However, there was a trend towards poorer scores in the fracture group. Further analysis of subsections of the score revealed that there was a significant difference between the fracture group and the paired matched controls in terms of subjective joint stiffness ($p = 0.002$) (Fig. 2). In terms of other score subsets no differences were found among the groups.

In regards to the Trendelenburg sign and limping, the study group and the paired matched controls did not differ significantly. Three/13 in the study group and no patients in the control group had a limp or a positive Trendelenburg sign, respectively. Two of the 24 patients of the matched control group had a limp and a positive Trendelenburg sign.

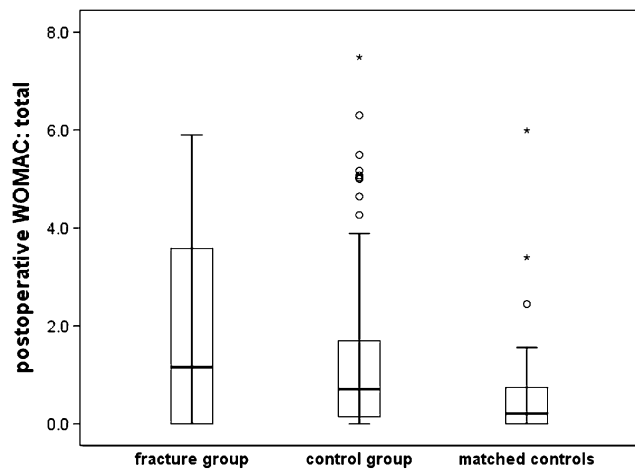
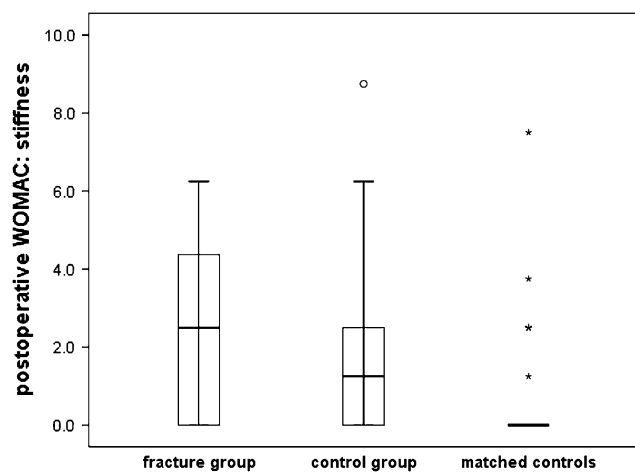
In patients with greater trochanter fractures, comparison of the X-rays immediately after surgery and at 1 year revealed that complete bony consolidation occurred in 7 out of 8 without any secondary displacement (Fig. 3). In one case, proximal and posterior displacement was recognized at 3 months. This patient was unsatisfied and did not continue follow-up at our institution. A telephone interview revealed that open reduction and fixation of the greater trochanter was performed at another institution.

Simple metaphyseal fractures, healed in 3 out of 5 patients without any stem subsidence (Fig. 4). In 2 patients

Table 1 Demographics of the study and the control groups did not differ significantly in regards to age ($p = 0.232$), sex ($p = 0.32$) and body mass index (BMI) ($p = 0.07$)

	Study group ($n = 13$)	Control group ($n = 471$)	Matched ($n = 26$)
Age (years)	68 ± 9	64 ± 12	68 ± 9
Sex (male, %)	38	52	38
BMI	25 ± 4	27 ± 5	26 ± 3

There were no significant differences for the matched control group

**Fig. 1** The overall WOMAC score at 1 year did not differ significantly among the three groups. However, there was a trend towards poorer outcome in the fracture group compared to the matched controls**Fig. 2** In the subsection of the WOMAC, which is related to stiffness, there was a significantly poorer outcome in patients after intraoperative fractures compared to the matched controls ($p = 0.002$)

subsidence of 5 and 7 mm, respectively, was observed. The stem showed complete bony integration and the patients were unaware and asymptomatic of the resulting reduction in leg length.

Discussion

While THR through a minimally invasive anterior approach has many potential advantages, the risks of intraoperative fractures of the greater trochanter or the metaphysis remain an issue. In the present series, the incidence of such complications was 2.7 % and compares with the published rate of 5.4 % by Berry [3]. Berend et al. [1] reported two fractures in 457 hips (0.4 %). However, fracture incidences among series must be interpreted with caution: different risk factors for intraoperative fractures such as osteoporosis, rheumatoid arthritis, stiffness and distorted anatomy play a significant role and the higher incidence of this complication in Berry's series might reflect different population characteristics [3]. Nevertheless, the only exclusion criteria for a minimally invasive direct anterior approach in the present series was a grossly distorted anatomy making formal trochanteric osteotomy necessary. Osteoporosis, severe joint stiffness or ankylosis and inflammatory disease were not considered contraindications for this approach. In addition, being a tertiary referral center, the risk profile of our patients is probably not more favorable than in other series. Finally, we are a teaching institution, in which a significant number of surgeries are performed by trainees.

In our series, none of the patients sustaining an intraoperative metaphyseal fracture had to be revised. This is in line with the report of Berend and colleagues [2], who reported a survivorship of 58 femoral implants after intraoperative calcar fracture of 100 % at up to 16 years of follow-up. THR were implanted using an anterolateral abductor split approach.

The present investigation indicates a trend towards poorer outcome and demonstrates increased subjective stiffness in patients with such complications. Unfortunately, the size of the study group is too small for sufficient statistical power to allow for a definite conclusion concerning the overall WOMAC score. In addition, while a minimal follow-up of 12 months was considered sufficient to assess the risk for secondary displacement, bony union and stem subsidence, we think that patients with subjective stiffness may experience improvement even after the 1-year mark. Nevertheless, we acknowledge that such complications have a negative impact on patient's subjective outcome at least during the first year. Its long-term relevance remains to be determined.

A fracture of the greater trochanter during a surgical approach which strips significant parts of the greater trochanter off surrounding soft tissue (e.g., Hardinge [10]) has to be considered a major complication and needs surgical fixation in most cases. We treated greater trochanter fractures conservatively, because the direct anterior approach preserves the whole soft tissue envelope together with

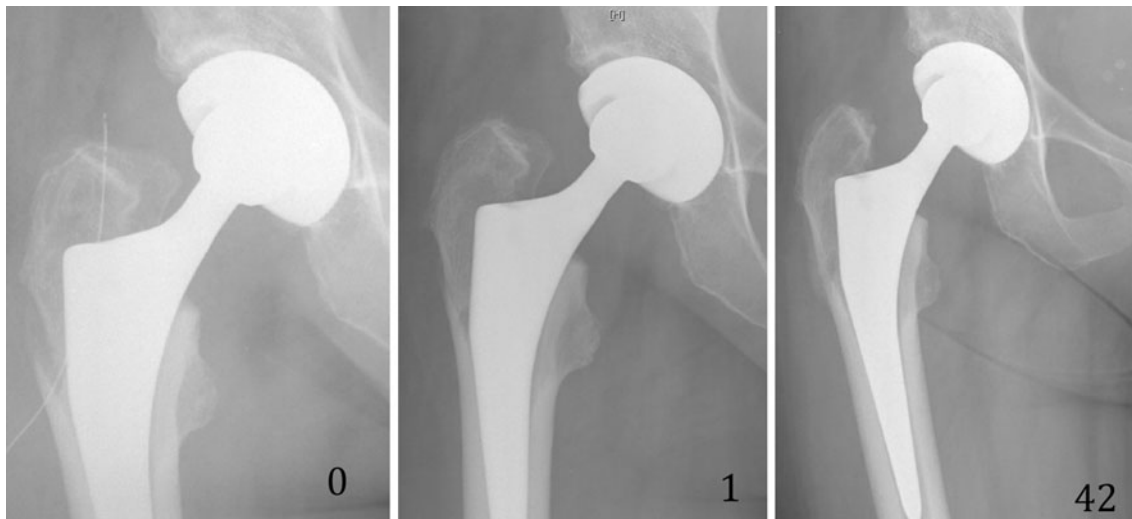


Fig. 3 The radiographic appearance of a greater trochanteric fracture treated conservatively at 0, 1, and 42 weeks

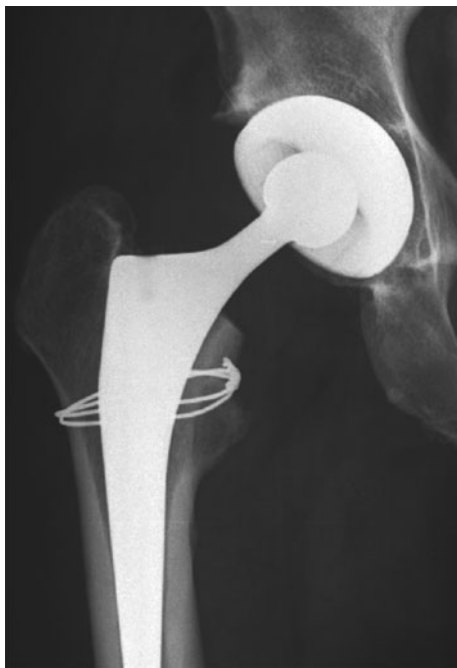

Fig. 4 A metaphyseal fracture treated with simple wiring and protected weight bearing

the vascular supply to the trochanteric area. Avoiding any further soft tissue stripping may explain the good healing rate of these fractures in our series. This is in line with work published by Jewett [11], who analyzed 800 THR performed through the Hueter surgical approach [8] and reported a trochanteric fracture rate of 2.3 %. He also treated these fractures conservatively and reported excellent functional and radiological outcomes. In one case, however, secondary displacement occurred. Therefore, we continue to monitor such patients with plain radiographs at

1 and 6 weeks. This leaves us the option of early surgical intervention before major fragment retraction occurs.

Despite wiring, metaphyseal fractures resulted in moderate stem subsidence in 2 of 5 cases. We are not aware of any reports on the radiological course of such fractures in the literature. Fortunately, subsidence did not result in stem loosening, nor did a clinically relevant leg length discrepancy occur. Nevertheless, we think that subsidence might have been avoided if weight bearing had been restricted for the first 6 weeks. We adapted our rehabilitation protocol accordingly.

Despite thorough efforts to identify all cases of intraoperative fractures, it is possible that some cases remain undiagnosed. One might assume that undisplaced greater trochanteric fractures or fissures in the area of the calcar are not identifiable on conventional X-rays. The fracture rate reported by this study may therefore be an underestimate. To reach a statistical power of 80 %, 35 cases would have been necessary in the fracture group. We consider the small size of the study group to be an important limitation of this study.

In conclusion, the intraoperative fracture risk was 2.7 % in this series of THR performed through a direct anterior approach. Based on our experience, we continue to treat greater trochanter fractures conservatively and metaphyseal fractures by simple wiring and protected weight bearing for 6 weeks in both situations.

Conflict of interest Each author certifies that he has no commercial associations (e.g., consultancies, stock ownership, equity interest, patent/licensing arrangements, etc.) that might pose a conflict of interest in connection with the submitted article.

Ethical review committee Each author certifies that his institution has waived approval for the human protocol for this investigation and that all investigations were conducted in conformity with ethical

principles of research. There was not an animal component to this research.

References

1. Berend KR, Lombardi AV Jr (2010) Intraoperative femur fracture is associated with stem and instrument design in primary total hip arthroplasty. *Clin Orthop Relat Res* 468:2377–2381
2. Berend KR, Lombardi AV Jr, Mallory TH et al (2004) Cerclage wires or cables for the management of intraoperative fracture associated with a cementless, tapered femoral prosthesis: results at 2 to 16 years. *J Arthroplast* 19:17–21
3. Berry DJ (1999) Epidemiology: hip and knee. *Orthop Clin N Am* 30:183–190
4. Davidson D, Pike J, Garbuz D et al (2008) Intraoperative periprosthetic fractures during total hip arthroplasty. Evaluation and management. *J Bone Joint Surg Am* 90:2000–2012
5. Thillemann TM, Pedersen AB, Johnsen SP et al (2008) Inferior outcome after intraoperative femoral fracture in total hip arthroplasty: outcome in 519 patients from the Danish Hip Arthroplasty Registry. *Acta Orthopaedica* 79:327–334
6. Pike J, Davidson D, Garbuz D et al (2009) Principles of treatment for periprosthetic femoral shaft fractures around well-fixed total hip arthroplasty. *J Am Acad Orthop Surg* 17:677–688
7. Asayama I, Kinsey TL, Mahoney OM (2006) Two-year experience using a limited-incision direct lateral approach in total hip arthroplasty. *J Arthroplast* 21:1083–1091
8. Hueter C (1883) *Grundriss der Chirurgie*. F.C.W, Vogel
9. Bellamy N, Buchanan WW, Goldsmith CH et al (1988) Validation study of WOMAC: a health status instrument for measuring clinically important patient relevant outcomes to antirheumatic drug therapy in patients with osteoarthritis of the hip or knee. *J Rheumatol* 15:1833–1840
10. Hardinge K (1982) The direct lateral approach to the hip. *J Bone Joint Surg Br* 64:17–19
11. Jewett BA, Collis DK (2011) High complication rate with anterior total hip arthroplasties on a fracture table. *Clin Orthop Relat Res* 469:503–507