

New Amplatzer Duct Occluder II for antegrade closure of patent ductus arteriosus

Stéphane Cook, Tobias Rutz, Bernhard Meier

University Hospital, Bern, Switzerland, Hôpital Cantonal, Fribourg, Switzerland

Summary

Transcatheter closure of patent ductus arteriosus is a safe and effective technique. The new version of the Amplatzer PDA occluder (Amplatzer Duct Occluder II) permits antegrade delivery and significantly simplifies the procedure.

Key words: Ductus arteriosus; device closure; Amplatzer duct occluder

Introduction

Patent ductus arteriosus (PDA) was one of the first congenital cardiovascular lesions to be treated by nonsurgical catheter intervention. Since the first publication by Porstmann in 1967, nonsurgical transcatheter closure has gained widespread acceptance. Various de-

vices have been used, including Rashkind PDA occluder, Gianturco coils, detachable coils, CardioSEAL, Sideris occluder and other umbrella devices. Since its first implantation in humans in 1998, the Amplatzer PDA occluder (AGA Medical Corporation, MN, USA) [1, 2] has rapidly superseded the previously popular Rashkind PDA occluder. In contrast to coils, it can also be used in large PDAs [3, 4]. The Amplatzer PDA occluder is a self-expanding device made from 144 Nitinol wires in the form of a round mesh with a central waist and two discs on either side. With the original version of the occluder occlusion was achieved via the retrograde, venous access approach. The new version of the device (Amplatzer Duct Occluder II, AGA Medical Corporation, MN, USA) has been improved to permit antegrade arterial access delivery.

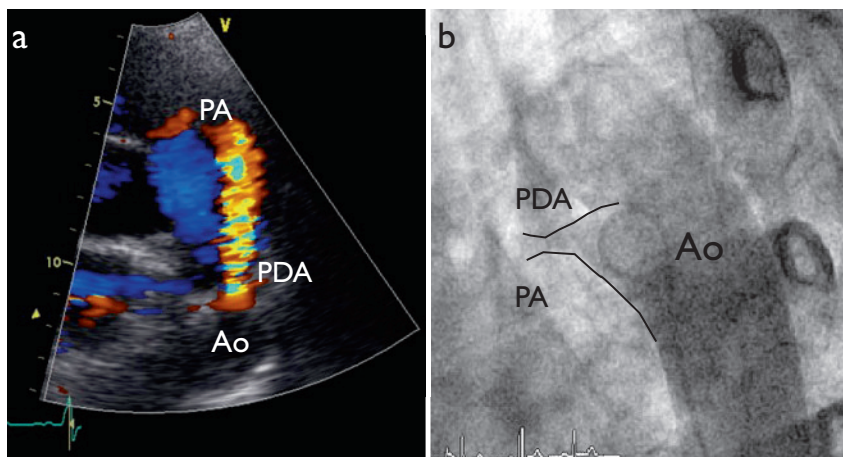
Case report

A 28-year-old female patient presented for investigation of a continuous heart murmur. Echocardiography revealed a left-to-right shunt through a patent ductus arteriosus (fig. 1a) and the patient was referred for outpatient percutaneous closure.

Aortography confirmed the echocardiographic findings (fig. 1b). The 0.035" wire crossed the ductus arteriosus easily. Then the 4 French (F) pigtail catheter was exchanged for the 4 F delivery sheath to allow implantation of a 4×4-mm Amplatzer Duct Occluder II (AGA Medical Corporation, MN, USA). Fluoroscopy time was 5 min. The shunt was completely eliminated, as documented by angiography immediately after device closure (fig. 2) and by echocardiographic follow-up evaluation the same day. The patient was discharged a few hours after the intervention.

Figure 1

a) Parasternal short axis echocardiographic view of the aortic valve showing the right ventricular outflow tract and the pulmonary main artery (PA). Colour flow imaging of systolic left-to-right shunt (red) through the patent ductus arteriosus (PDA), and b) subsequent confirmation of diagnosis by aortography (4 French pigtail catheter in descending aorta, Ao).

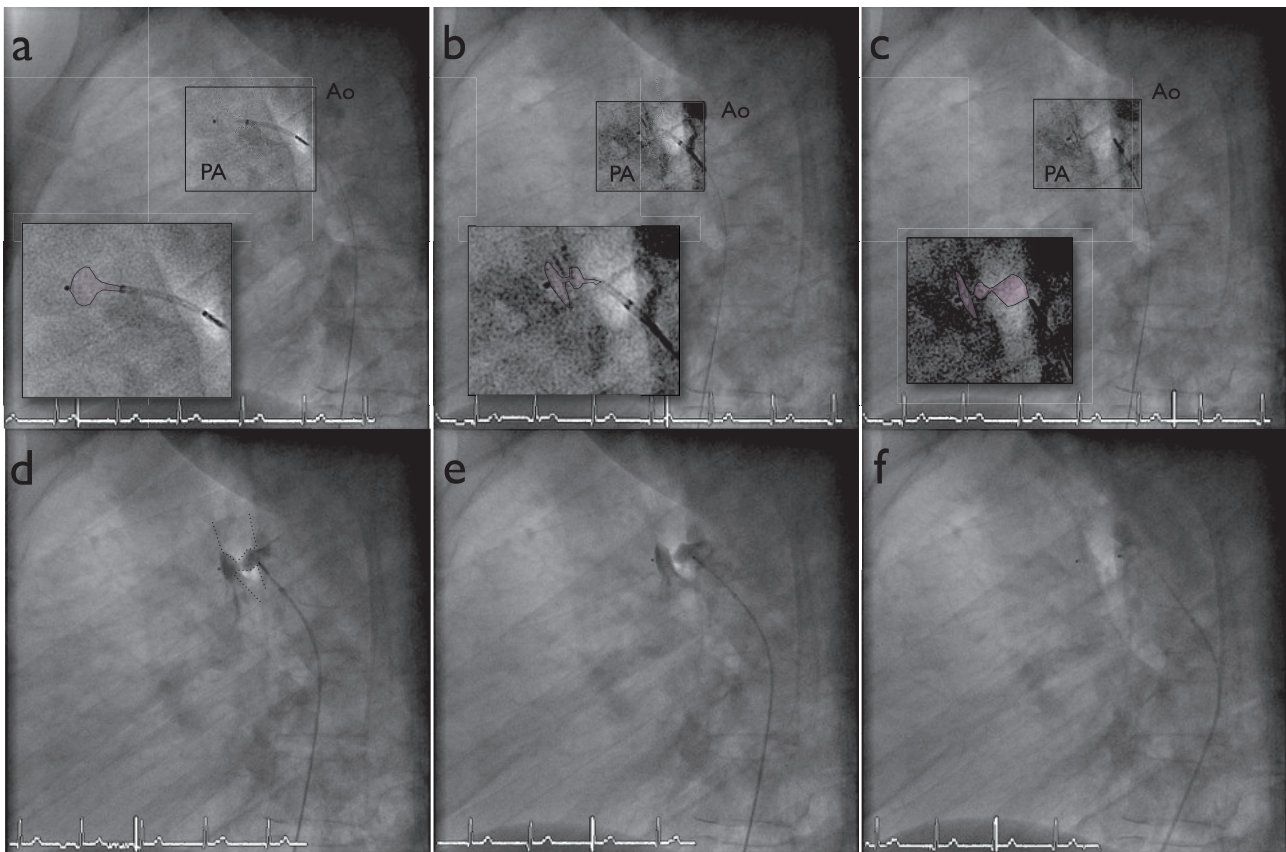


Correspondence:

Prof. B. Meier
Cardiology
University Hospital Bern
CH-3010 Bern
Switzerland
bernhard.meier@insel.ch

Figure 2

a to f: Sequential percutaneous closure of the PDA by delivery of a 4×4-mm Amplatzer Duct Occluder II.



Conclusion

Transcatheter closure of patent ductus arteriosus by the Amplatzer Duct Occluder is an easy, safe and effective technique. The new antegrade (arterial) delivery option of the Duct Occluder II simplifies the procedure significantly.

References

- 1 Masura J, Walsh KP, Thanopoulos B, Chan C, Bass J, et al. Catheter closure of moderate- to large-sized patent ductus arteriosus using the new Amplatzer duct occluder: immediate and short-term results. *J Am Coll Cardiol.* 1998;31:878–82.
- 2 Sharafuddin MJ, Gu X, Titus JL, Sakinis AK, Pozza CH, Coleman CC, et al. Experimental evaluation of a new self-expanding patent ductus arteriosus occluder in a canine model. *J Vasc Interv Radiol.* 1996;7:877–87.
- 3 O'Donnell C, Neutze JM, Skinner JR, Wilson NJ. Transcatheter patent ductus arteriosus occlusion: evolution of techniques and results from the 1990s. *J Paediatr Child Health.* 2001;37:451–5.
- 4 Chatterjee T, Windecker S, Pfammatter JP, Seiler C, Meier B. Non-surgical closure of patent ductus arteriosus: acute and long-term results. *Schweiz Med Wochenschr.* 2000;130:664–70.