

Posterolateral lumbar spine fusion using a novel demineralized bone matrix: a controlled case pilot study

Constantin Schizas · Dimitrios Triantafyllopoulos ·
Victor Kosmopoulos · Nikos Tzinieris · Kosmas Stafylas

Received: 28 June 2007 / Published online: 3 November 2007
© Springer-Verlag 2007

Abstract

Introduction Intertransverse posterolateral fusion along with instrumentation is a common technique used for spinal fusion. Iliac crest bone graft (ICBG) offers good fusion success rates with a low risk for disease transmission but is, however, linked with certain morbidity. In an effort to eliminate or reduce the amount of iliac graft needed, bone substitutes including demineralized bone matrix (DBM) have been developed. This study evaluates a novel DBM (Accell Connexus[®]) used in one or two-level instrumented posterolateral lumbar fusion.

Materials and methods A total of 59 consecutive patients were studied as two groups. Group 1 consisted of 33 patients having Accell Connexus[®] used to augment either ICBG or local decompression material. Group 2 consisted of 26 consecutive patients, operated prior to the introduction of this novel DBM, having either ICBG alone or local decompression material. Fusion was assessed by two independent observers, blinded to graft material, using standardized criteria found in the literature. All adverse events were recorded prospectively.

Results The results show no statistically significant differences between the two groups in fusion rates, complications, surgery duration, ODI, or pain on VAS. Logistical

regression showed no relation between fusion and age, smoking status or comorbidities. Furthermore, no adverse events related to the use of the novel DBM were observed.

Conclusion The results from this study demonstrate that the novel DBM presented performs equally as well as that of autologous bone, be it either ICBG or a local decompression material, and can therefore be used as a graft extender.

Keywords Demineralized bone matrix (DBM) · Spinal fusion · Bone grafting · Safety · Efficacy

Introduction

Spinal fusion is one of the most common procedures performed in spinal surgery, with more than 200,000 annual cases performed in the United States alone [2]. Intertransverse posterolateral fusion (PLF) along with instrumentation is one of the common techniques used in spinal fusion and the osseous repair procedure where the most bone graft material is used. From the many bone-grafting options available, iliac crest bone graft (ICBG) remains the most popular. ICBG offers good success rates and low risk for disease transmission [10]. Harvesting of ICBG is nevertheless linked with certain morbidity. Reported complications include hematoma, false aneurysm, nerve and arterial injuries [5,13,17], gait disturbances, fractures of the iliac wing [7,11,15,16], visceral and ureteral injuries [8,14], peritoneal perforation, infections [13], sacroiliac instability, and pain [13]. In particular, residual pain has been reported to occur in as much as 31% of the cases [9].

In an effort to reduce the amount of iliac graft needed, several bone substitutes have been developed. Demineralized bone matrix (DBM) is one of these because it has been shown that properly demineralized cortical bone

C. Schizas (✉) · D. Triantafyllopoulos ·
V. Kosmopoulos · N. Tzinieris
Hôpital Orthopédique de la Suisse Romande,
Centre Hospitalier Universitaire Vaudois
and The University of Lausanne,
Avenue Pierre-Decker 4, 1005 Lausanne, Switzerland
e-mail: cschizas@hotmail.com

K. Stafylas
Orthopaedic Department,
University Hospital of Ioannina, Ioannina, Greece

preserves the natural capacity of the native bone proteins and growth factors [22]. Although initial DBMs contained glycerol as a carrier for the DBM particles, this substance has been found to be detrimental for host cells and nephrotoxic at high doses [3, 23] and can migrate within the site or upon irrigation due to the water solubility of the carrier. Newer DBMs are therefore being developed with improved carrier composition and increased matrix induction concentration. Studies based on first generation DBMs are available in the literature [4, 19]. To our knowledge however, there are no clinical studies available on the safety and efficacy of these newer generation DBMs for spinal fusion.

The objective of this pilot study was to evaluate the clinical and radiological performance of a novel DBM (Accell Connexus[®]) composed of a DBM-based carrier with a reverse phase copolymer additive (IsoTis OrthoBiologics Inc., Irvine, CA, USA) used as a graft extender in one or two-level instrumented posterolateral lumbar fusion.

Materials and methods

A total of 59 consecutive patients (22 males and 37 females) were included in the study. All the patients underwent one- or two-level instrumented intertransverse fusion. Diagnosis included lumbar spinal stenosis with spondylolisthesis ($n = 37$), degenerative disc disease ($n = 11$), lumbar fractures ($n = 2$), and isthmic spondylolisthesis ($n = 9$); 40 patients had one-level fusion and the remaining 19 had two-level fusion. The patients were organized in two groups. Group 1 comprised 33 consecutively operated patients (average age of 64.6 years) in whom 2.5–10 cm³ of Accell Connexus[®] putty combined with an autologous bone marrow aspirate from the iliac crest was used to augment either ICBG, or a local decompression material, in a standardized ratio as per the manufacturer's recommendations (1:1 with 5 cm³ of bone marrow). This ratio is aimed at obtaining adequate containment of all the autograft particles while maximizing the inductive potential provided as a stimulus to the native osteogenic autograft and is considered as the right balance for this purpose in the absence of studies on the subject. The addition of the reverse phase copolymer to the DBM-based substance allows for composite graft containment and the ability to irrigate once placed. The control group (Group 2) consisted of 26 consecutive patients (average age of 58.3 years) operated on prior to the introduction of Accell Connexus[®] in our institution. ICBG alone, or local decompression material, was used for these patients. In both the groups the grafting material was placed posterolaterally over the transverse processes or lateral mass of the sacrum following decortication. All the patients received rigid titanium 6 mm

polyaxial pedicle screws originating from the same manufacturer (Expedium, DePuy Spine Inc., Raynham, MA, USA). Age, distribution of the type of diagnosis, and the number of two-level fusions performed, were similar for both the groups. All the patients were treated by the same senior surgeon (CS) in one institution. Prophylactic antibiotics and low molecular weight heparin were used by all the patients. Non-steroidal anti-inflammatory drugs (NSAIDs) were proscribed during the first 3 months for both the patient groups. A soft orthosis was used in all patients for the first 6 weeks following surgery. The proportion of smokers was 27 and 34% for groups 1 and 2, respectively. Patients were followed up clinically and radiologically, at 6 weeks, and at 3, 6 and 12 months post surgery. No patient from either group was lost to follow-up. Ethical committee approval was obtained by the institutional review board and all patients gave their informed consent.

Radiographically, the Christensen et al. fusion criteria for union [6] were applied to study plain X-rays taken at 12 months. According to this classification, "fusion" indicates qualitative fusion at all intended levels (Figs. 1, 2). Suboptimal quality or a fusion mass hidden by instrumentation is to be counted as "non-fusion". The clinical outcome measures employed were the Oswestry disability index

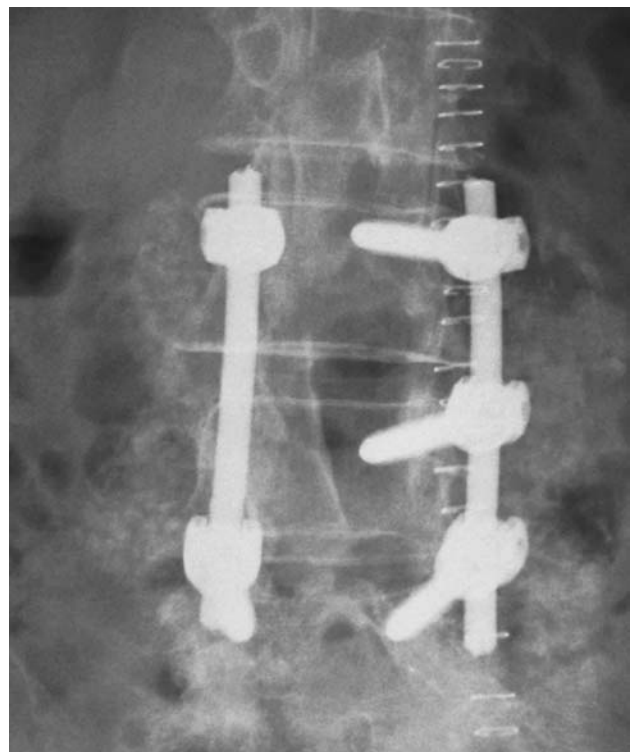


Fig. 1 A radiograph showing an anteroposterior (AP) view of a two-level fusion following decompression taken immediately post-surgery. Grafting consisted of decompression material and DBM. The entire graft mass is not readily observed as the DBM is not radiopaque

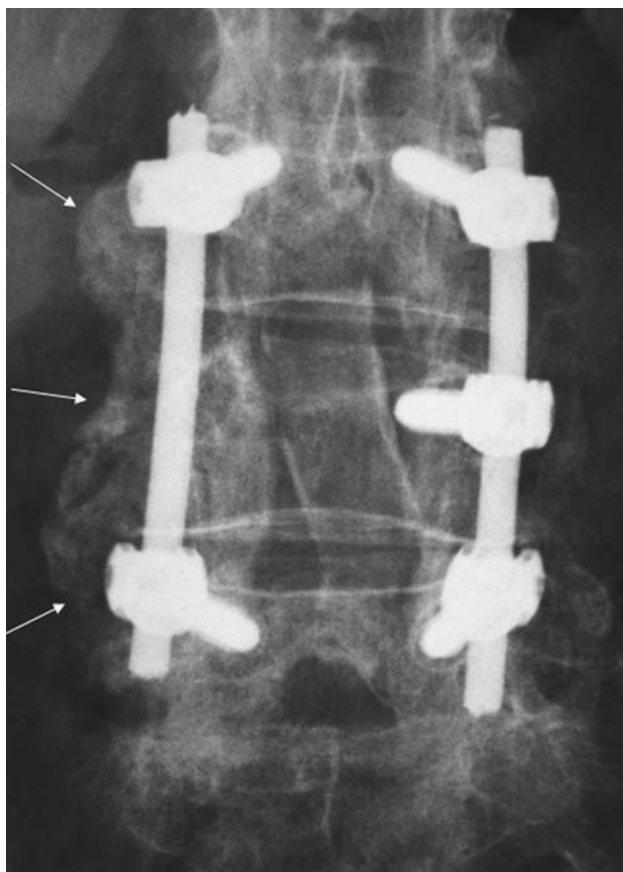


Fig. 2 A follow-up AP radiograph to that shown in Fig. 1 taken 1 year post-surgery demonstrating “fusion” according to the Christensen et al. criteria for all intended fusion levels. The fusion mass is particularly well visible on the patient’s right side (see arrows), demonstrating new bone formation and mineralization

(ODI) and pain assessed using the visual analogue scale (VAS), given preoperatively and one year post-surgery.

Two independent observers, blinded to the type of graft material, assessed the films for the presence of bridging bone between the transverse processes using a consensus interpretation. All adverse events and complications were recorded prospectively for both groups. Statistical analyses

were performed utilizing Fisher’s exact two-tailed test, Student’s unpaired *t* test and a logistic regression.

Results

No significant difference ($P = 0.86$) was found between operating times for group 1 (average = 241 min) and group 2 (average = 244 min). No deep infections occurred in either group. Furthermore, no adverse event related to the use of DBM was noted. In particular, no intraoperative hypotension or allergic reaction was registered. One patient from each group suffered a pulmonary embolus recovering uneventfully following appropriate treatment. There were two dural tears in group 1 and one in group 2, both treated with primary repair, and resulting in no long-term consequences.

Fusion was found in 23 out of the 33 (69.7%) patients from group 1, and 20 out of the 26 (76.9%) patients from group 2. This difference was not statistically significant (Table 1). In addition, subgroup analyses showed no significant difference ($P = 0.77$) in fusion rates between patients receiving decompression material alone or those augmented with ICBG. Furthermore, there was no statistical difference in the preoperative VAS and ODI or in their improvement reported at one year post-surgery between the two groups. Average values and levels of significance can be found in Table 1. No implant failure was observed in either group.

Results from a logistic regression analysis showed no relation between the occurrence of radiological fusion and age, smoking status, comorbidities, length of surgery, volume of DBM, or pain (VAS) and function (ODI) reported at 1 year.

Discussion

This study focuses on the safety and efficacy of a new DBM-based osteoinductive bone graft material used as a

Table 1 Summary of significance findings

	Group 1 (DBM)	Group 2 (control)	Significance test
Operating time (min)	241	244	$P = 0.86$ (<i>t</i> -test)
Fusion rates (%)	69.7	76.9	$P = 0.57$ (Fisher’s)
Average ODI (1 year post-operative)	24.1	28.8	$P = 0.38$ (<i>t</i> -test)
Average ODI improvement (1 year post-operative–pre-operative)	32.7	30.5	$P = 0.70$ (<i>t</i> -test)
Average VAS (1 year post-operative)	3.4	4.2	$P = 0.30$ (<i>t</i> -test)
Average VAS improvement (1 year post-operative–pre-operative)	4.5	4.9	$P = 0.67$ (<i>t</i> -test)

graft extender in one- or two-level posterolateral instrumented lumbar fusion. Several studies, reviewed and summarized by Lee et al. [18], have been carried out using various animal models and DBM preparations to demonstrate differences in fusion rates based on several factors including the DBM formulation, and the animal model used. Fewer studies, however, can be currently found in the literature covering the use of DBM in a human clinical population. Studies have evaluated previous generation DBMs (Grafton) for posterolateral lumbar fusion [4,12,20,21]. From these studies, one showed lower fusion rates using coralline hydroxyapatite with the addition of DBM [21], and the others demonstrated the utility of DBMs as graft extenders but not as fusion enhancers [4,12,20].

The fusion rates in the present study are lower than those commonly cited and tacitly accepted (approaching 90%) for instrumented posterolateral fusion using autologous ICBG. Camissa et al. [4], in their study on the use of Grafton, also noted relatively lower rates (65%) which they ascribed to a very difficult to manage patient population, very strict radiographic criteria and the need to evaluate the graft visible lateral to the instrumentation. The latter in our opinion, may have contributed to some extent in our study as well, with the other two reasons being more difficult to quantify. Indeed evaluating graft visibility lateral to the instrumentation may underestimate the true fusion rates. It could be that if more autologous graft volume is used (e.g., from minced local bone), and if rods are more medially placed, the visibility of the fusion mass would be enhanced without necessarily increasing the fusion rate. It is interesting to note that in our department the revision rate for pseudarthrosis is less than 1% for patients treated in exactly the same manner prior to the beginning of the present study, albeit without the use of DBM.

The use of plain radiographs presents a limitation in assessing fusion when compared to the suggested improved accuracy observed from the use of computed tomography (CT) images. Using CT images however, subjects patients to increased amounts of radiation which we found an unnecessary risk considering the simplicity and good inter- and intra-observer agreement [6] reported for the radiological criteria chosen.

An added caveat to the results presented, is the shorter than 2 years follow-up period as has been previously suggested [1]. We did nevertheless succeed in obtaining a 100% 1 year follow up chiefly through the excellent compliance of our patient population. In addition, this study was not randomized but consisted of a consecutive series of patients before and after the availability of the aforementioned DBM in our institution. The study benefits from being performed at a single institution by the same operating surgeon eliminating possible technical differences such as graft harvesting and preparation of the graft bed.

In summary, the results of this study demonstrate the role of this novel DBM as a safe and effective graft extender in one or two level posterolateral instrumented fusion at 1 year post-surgery. The composition is also effective in containing the graft within the surgical site, resisting irrigation. More clinical studies using recommended designs are needed to further evaluate newer generation DBMs and more discriminating techniques, such as CT scans, should be considered to better assess the progression of fusion.

Acknowledgments This study was supported by IsoTis OrthoBiologics Inc., Irvine, CA, USA, in the form of a nonprofit research fund.

References

1. Boden SD (1998) Bone repair and enhancement clinical trial design. Spine applications. [Review] [48 refs]. *Clin Orthop Relat Res* 355(Suppl):S336–S346
2. Boden SD (2002) Overview of the biology of lumbar spine fusion and principles for selecting a bone graft substitute. [Review] [68 refs]. *Spine* 27:S26–S31
3. Bostrom MP, Yang X, Kennan M, Sandhu H, Dicarlo E, Lane JM (2001) An unexpected outcome during testing of commercially available demineralized bone graft materials: how safe are the nonallograft components? [see comment]. *Spine* 26:1425–1428
4. Cammisa FP Jr, Lowery G, Garfin SR, Geisler FH, Klara PM, McGuire RA, Sassard WR, Stubbs H, Block JE (2004) Two-year fusion rate equivalency between Grafton DBM gel and autograft in posterolateral spine fusion: a prospective controlled trial employing a side-by-side comparison in the same patient. *Spine* 29:660–666
5. Catinella FP, De Laria GA, De Wald RL (1990) False aneurysm of the superior gluteal artery. A complication of iliac crest bone grafting. *Spine* 15:1360–1362
6. Christensen FB, Laursen M, Gelineck J, Eiskjaer SP, Thomsen K, Bunge CE (2001) Interobserver and intraobserver agreement of radiograph interpretation with and without pedicle screw implants: the need for a detailed classification system in posterolateral spinal fusion. *Spine* 26:538–543
7. Cohn BT, Krackow KA (1988) Fracture of the iliac crest following bone grafting. A case report. *Orthopedics* 11:473–474
8. Escalas F, DeWald RL (1977) Combined traumatic arteriovenous fistula and ureteral injury: a complication of iliac bone-grafting. *J Bone Joint Surg Am* 59:270–271
9. Fernyhough JC, Schimandle JJ, Weigel MC, Edwards CC, Levine AM (1992) Chronic donor site pain complicating bone graft harvesting from the posterior iliac crest for spinal fusion. *Spine* 17:1474–1480
10. Finkemeier CG (2002) Bone-grafting and bone-graft substitutes. [Review] [59 refs]. *J Bone Joint Surg Am* 84-A:454–464
11. Friend KD, Koval KJ, Mirovsky Y, Remer SS, Bloom N, Neuwirth MG (1995) Fracture of the iliac crest following bone grafting: a case report and literature review. [Review] [8 refs]. *Bull Hosp Joint Dis* 54:49–51
12. Girardi FP, Cammisa FP Jr (2003) The effect of bone graft extenders to enhance the performance of iliac crest bone grafts in instrumented lumbar spine fusion. *Orthopedics* 26:s545–s548
13. Goulet JA, Senunas LE, DeSilva GL, Greenfield ML (1997) Autogenous iliac crest bone graft. Complications and functional assessment. *Clin Orthop Relat Res* 339:76–81

14. Hamad MM, Majeed SA (1989) Incisional hernia through iliac crest defects. A report of three cases with a review of the literature. [Review] [12 refs]. *Arch Orthop Trauma Surg* 108:383–385
15. Hu RW, Bohlman HH (1994) Fracture at the iliac bone graft harvest site after fusion of the spine. *Clin Orthop Relat Res* 309:208–213
16. Keller EE, Triplett WW (1987) Iliac bone grafting: review of 160 consecutive cases. *J Oral Maxillofac Surg* 45:11–14
17. Kurz LT, Garfin SR, Booth RE Jr (1989) Harvesting autogenous iliac bone grafts. A review of complications and techniques. *Spine* 14:1324–1331
18. Lee KJ, Roper JG, Wang JC (2005) Demineralized bone matrix and spinal arthrodesis. [Review] [65 refs]. *Spine J Off J North Am Spine Soc* 5:217S–223S
19. Sassard WR, Eidman DK, Gray PM, Block JE, Russo R, Russell JL, Taboada EM (2000) Augmenting local bone with Grafton demineralized bone matrix for posterolateral lumbar spine fusion: avoiding second site autologous bone harvest. [see comment]. *Orthopedics* 23:1059–1064
20. Silcox DH III, Boden SD, Schimandle JH, Johnson P, Whitesides TE, Hutton WC (1998) Reversing the inhibitory effect of nicotine on spinal fusion using an osteoinductive protein extract. *Spine* 23:291–296
21. Thalgott JS, Giuffre JM, Fritts K, Timlin M, Klezl Z (2001) Instrumented posterolateral lumbar fusion using coralline hydroxyapatite with or without demineralized bone matrix, as an adjunct to autologous bone. *Spine J Off J North Am Spine Soc* 1:131–137
22. Urist MR (1965) Bone: formation by autoinduction. *Science* 150:893–899
23. Wang JC, Kanim LE, Nagakawa IS, Yamane BH, Vinters HV, Dawson EG (2001) Dose-dependent toxicity of a commercially available demineralized bone matrix material. *Spine* 26:1429–1435