

Updated clinical diagnostic criteria for sporadic Creutzfeldt-Jakob disease

I. Zerr,¹ K. Kallenberg,² D. M. Summers,³ C. Romero,⁴ A. Taratuto,⁴ U. Heinemann,¹ M. Breithaupt,¹ D. Varges,¹ B. Meissner,¹ A. Ladogana,⁵ M. Schuur,⁶ S. Haik,⁷ S. J. Collins,⁸ Gerard H. Jansen,⁹ G. B. Stokin,¹⁰ J. Pimentel,¹¹ E. Hewer,¹² D. Collie,³ P. Smith,¹³ H. Roberts,⁸ J. P. Brandel,⁷ C. van Duijn,⁶ M. Pocchiari,⁵ C. Begue,⁴ P. Cras,¹⁴ R. G. Will³ and P. Sanchez-Juan¹⁵

1 National TSE Reference Center, Department of Neurology, Georg-August University Goettingen, Goettingen, Germany

2 Department of Neuroradiology, Georg-August University Goettingen, Goettingen, Germany

3 CJD Surveillance Unit, Western General Hospital, Edinburgh, UK

4 Departamento de Neuropatologia, Centro de Referencia de Encefalopatías Espongiformes Transmisibles, Instituto de Investigaciones Neurológicas/FLENI Montañeses 2325 C1428AQK, Buenos Aires, Argentina

5 Istituto Superiore di Sanità, Department of Cell Biology and Neurosciences, Roma, Italy

6 Genetic Epidemiology Unit, Department of Epidemiology, Biostatistics and Clinical Genetics, Erasmus Medical Center, Rotterdam, The Netherlands

7 INSERM UMRS 975, Hôpital de la Salpêtrière Cellule Nationale de référence des maladies de Creutzfeldt-Jakob Paris, F-75013, France

8 Australian National Creutzfeldt-Jakob Disease Registry, Department of Pathology, the University of Melbourne, Parkville, Australia 3010

9 Creutzfeldt-Jakob Disease Surveillance System, Prion Diseases Program, Public Health Agency of Canada, Ottawa, Canada

10 Division of Neurology, University Medical Center and Gerontopsychiatric Unit, University Psychiatric Hospital, SI-1000 Ljubljana, Slovenia

11 Department of Neurology, Laboratory of Neuropathology, Institute of Molecular Medicine, Hospital de Santa Maria, Lisbon Faculty of Medicine, Lisbon, Portugal

12 Institute of Neuropathology, University Hospital Zurich, Zurich, Switzerland

13 Clinic Director, Mercy Private Radiology, Grey st, East Melbourne, 3002, Australia

14 Laboratory of Neurobiology, Department of Neurology, Born Bunge Institute, University of Antwerp, Belgium

15 Fundación 'Marqués de Valdecilla' IFIMAV and Centro de Investigación Biomédica en Red sobre Enfermedades Neurodegenerativas (CIBERNED). Santander, Spain

Corresponding author: Inga Zerr, MD,
National TSE Reference Center,
Department of Neurology,
Georg-August University Goettingen,
Robert-Koch-Str. 40,
37075 Goettingen,
Germany
E-mail: epicjd@med.uni-goettingen.de

Several molecular subtypes of sporadic Creutzfeldt-Jakob disease have been identified and electroencephalogram and cerebrospinal fluid biomarkers have been reported to support clinical diagnosis but with variable utility according to subtype. In recent years, a series of publications have demonstrated a potentially important role for magnetic resonance imaging in the pre-mortem diagnosis of sporadic Creutzfeldt-Jakob disease. Magnetic resonance imaging signal alterations correlate with distinct sporadic Creutzfeldt-Jakob disease molecular subtypes and thus might contribute to the earlier identification of the whole spectrum of sporadic Creutzfeldt-Jakob disease cases. This multi-centre international study aimed to provide a rationale for the amendment of the clinical diagnostic criteria for sporadic Creutzfeldt-Jakob disease. Patients with sporadic Creutzfeldt-Jakob disease and fluid attenuated inversion recovery or diffusion-weight imaging were recruited from 12 countries. Patients

Received March 26, 2009. Revised June 12, 2009. Accepted June 14, 2009

© The Author(s) 2009. Published by Oxford University Press on behalf of Brain.

This is an Open Access article distributed under the terms of the Creative Commons Attribution Non-Commercial License (<http://creativecommons.org/licenses/by-nc/2.5/uk/>) which permits unrestricted non-commercial use, distribution, and reproduction in any medium, provided the original work is properly cited.

referred as ‘suspected sporadic Creutzfeldt–Jakob disease’ but with an alternative diagnosis after thorough follow up, were analysed as controls. All magnetic resonance imaging scans were assessed for signal changes according to a standard protocol encompassing seven cortical regions, basal ganglia, thalamus and cerebellum. Magnetic resonance imaging scans were evaluated in 436 sporadic Creutzfeldt–Jakob disease patients and 141 controls. The pattern of high signal intensity with the best sensitivity and specificity in the differential diagnosis of sporadic Creutzfeldt–Jakob disease was identified. The optimum diagnostic accuracy in the differential diagnosis of rapid progressive dementia was obtained when either at least two cortical regions (temporal, parietal or occipital) or both caudate nucleus and putamen displayed a high signal in fluid attenuated inversion recovery or diffusion-weight imaging magnetic resonance imaging. Based on our analyses, magnetic resonance imaging was positive in 83% of cases. In all definite cases, the amended criteria would cover the vast majority of suspected cases, being positive in 98%. Cerebral cortical signal increase and high signal in caudate nucleus and putamen on fluid attenuated inversion recovery or diffusion-weight imaging magnetic resonance imaging are useful in the diagnosis of sporadic Creutzfeldt–Jakob disease. We propose an amendment to the clinical diagnostic criteria for sporadic Creutzfeldt–Jakob disease to include findings from magnetic resonance imaging scans.

Keywords: CJD; MRI; FLAIR; DWI; molecular subtypes; dementia

Abbreviations: CSF = cerebrospinal fluid; DWI = diffusion-weight imaging; EEG = electroencephalography; FLAIR = fluid attenuated inversion recovery; IgG = immunoglobulin G; MRI = magnetic resonance imaging; sCJD = sporadic Creutzfeldt–Jakob disease; PRNP = prion protein gene; PrPSc = pathogenic Prion protein; SREAT = steroid responsive encephalitis associated with autoimmune thyroiditis

Introduction

Sporadic CJD (sCJD) is a transmissible neurodegenerative disorder with a fatal outcome. Clinical diagnostic criteria for sCJD were first formulated 30 years ago, using a combination of distinctive clinical features and best available auxiliary paraclinical investigations, which at that time was electroencephalography (EEG) (Masters *et al.*, 1979). In recent years, there has been progress in developing other specialist investigations, including useful surrogate biomarkers in the cerebrospinal fluid (CSF), and clinical diagnostic criteria have been amended (Zerr *et al.*, 2000a; Collins *et al.*, 2006).

A series of recent publications has dealt with the clinical and pathological phenotypes and heterogeneity in sCJD (Parchi *et al.*, 1999; Gambetti *et al.*, 2003; Castellani *et al.*, 2004; Collins *et al.*, 2006; Sanchez-Juan *et al.*, 2006). It has become apparent that a multimodal approach may be necessary if detection of the entire phenotypic spectrum of sCJD is to be achieved (Zerr *et al.*, 2000b). Whereas some classical molecular subtypes such as the MM1 subtype frequently display periodic sharp and slow wave complexes in the EEG, the other five molecular subtypes are negative with this investigation (Parchi *et al.*, 1999; Castellani *et al.*, 2004; Collins *et al.*, 2006). Utilizing CSF 14-3-3 protein detection provides a higher sensitivity, including less typical subtypes of sCJD such as VV1 and VV2 subtypes (Collins *et al.*, 2006; Sanchez-Juan *et al.*, 2006; Geschwind *et al.*, 2009). However, even for CSF 14-3-3 protein detection with an overall sensitivity of 85%–95%, biological variables modify the test results and cases with longer duration or younger age at onset may be missed by this investigation (Castellani *et al.*, 2004; Sanchez-Juan *et al.*, 2006).

Acknowledging the limitations of the clinical criteria, the search for additional sCJD diagnostic investigations has continued. Magnetic resonance imaging (MRI) has become increasingly important in the clinical diagnosis of sCJD. The use of sensitive

fluid attenuated inversion recovery (FLAIR) and diffusion-weight imaging (DWI) sequences allows the detection of basal ganglia hyperintensity and signal increase in other brain regions (Satoh *et al.*, 2007; Tschampa *et al.*, 2007; Fujita *et al.*, 2008; Galanaud *et al.*, 2008; Meissner *et al.*, 2008). Characteristic MRI lesion patterns corresponding to individual CJD subtypes have been reported (Meissner *et al.*, 2009). As MRI findings, even from early in the illness, are proving valuable in the evaluation of suspected sCJD patients, both by excluding other disorders and by demonstrating features considered typical of human prion disease (Geschwind *et al.*, 2009), we undertook a systematic multi-centre international collaborative study to analyse the value of MRI lesion patterns in comparison to CSF biomarker 14-3-3 and periodic sharp wave complexes in the EEG in terms of test sensitivity and specificity.

Material and Methods

Patients

Cases were included from twelve countries (Argentina, Australia, Belgium, Canada, France, Germany, Italy, Netherlands, Portugal, Slovenia, Switzerland and United Kingdom) according to the following criteria: (i) CJD diagnosis confirmed by brain pathology (definite cases) or fulfilling accepted case definition criteria for ‘probable’ sCJD (data used for a separate set of analyses); (ii) molecular subtype determined by codon 129 genotyping (MM, MV or VV) and western blot analysis of brain pathogenic prion protein (PrPSc) type (1 or 2) (corresponding to MM1, MM2, MV1, MV2, VV1 and VV2 subtype) (Parchi *et al.*, 1996, 1999); and (iii) available FLAIR or DWI MRI of the brain.

Controls

Controls were included according to the following criteria: (i) cases in which the diagnosis of sCJD was suspected (patients classified at least as

probable or possible CJD) but excluded on follow up by clinical investigations (improvement or recovery, inflammatory CSF findings, other diagnosis) or at autopsy; and (ii) available FLAIR or DWI brain MRI.

Codon 129 status was determined either as part of genotyping of the entire prion protein gene (PRNP) open reading frame or by restriction fragment length polymorphism analysis (Collins *et al.*, 2006). Genetic CJD (causal mutations found in prionprotein gene), iatrogenic and variant CJD cases were excluded.

EEG (periodic sharp wave complexes) findings were also ascertained. The CSF 14-3-3 immunoassays were performed using western blotting as previously reported (Zerr *et al.*, 2000a) and the conformity of test methods and interpretation of results was confirmed by a blinded sample exchange programme between laboratories (Sanchez-Juan *et al.*, 2006).

The study comprised 436 sCJD patients who died between April 1998 and March 2007, and 141 controls: 32 (5.5%) from Argentina, 15 (2.6%) from Australia, 35 (6.1%) from Belgium, 9 (1.6%) from Canada, 16 (2.8%) from France, 328 (56.8%) from Germany, 32 (5.5%) from Italy, 17 (2.9%) from Netherlands, 7 (1.2%) from Portugal, 4 (0.7%) from Slovenia, 7 (1.2%) from Switzerland and 75 (13.0%) from UK.

MRI data

The magnetic resonance images were performed as routine clinical diagnostic studies and were collected from various hospitals in the framework of epidemiological studies as reported elsewhere (Meissner *et al.*, 2009).

The majority of the scans were available as hardcopy. If serial MRIs were available, the first examination was used for the analysis. All scans were assessed by at least one neuroradiologist (K.K., D.S., C.R., P.S. or D.C.) aware that sCJD was a differential diagnostic possibility but blinded to the final diagnosis. All neuroradiologists assessed a small MRI series for the estimation of the inter-observer agreement. The intra reader concordance was high: 93.3%, $\kappa = 0.64$ ($P < 0.001$). Inter-rater concordance was 89%, $\kappa = 0.61$ ($P < 0.001$) and 82%, $\kappa = 0.62$ ($P < 0.001$) (which is high agreement) or 75.4%, $\kappa = 0.50$ ($P < 0.001$) and 76%, $\kappa = 0.45$ ($P < 0.001$) (moderate agreement).

A standardized protocol was used which included seven cerebral cortex regions (specifically the cingulate gyri, insular regions and hippocampi, as well as the remaining frontal, parietal and temporal lobes and the occipital lobes), basal ganglia (caudate nucleus, putamen, globus pallidus), thalamus (anterolateral nuclei, mediodorsal nuclei, pulvinar) and cerebellar cortex. For the thalamus, the presence or absence of a 'pulvinar sign' with extension into the antero-medial thalamus underscoring the 'hockey stick sign' was also rated (hyperintensity of the pulvinar relative to the anterior putamen) (Collie *et al.*, 2003). The cerebral regions were assessed as hyperintense in relation to isointense cortex areas. As most MRI data were available as hardcopy only, the grade of hyper-intensity was not quantified. For each MRI examination, T₂-weighted (T₂-w) images were evaluated first, followed by FLAIR and DWI. For further analyses, only FLAIR and DWI were considered e.g. only the most sensitive sequences, FLAIR and DWI (Kallenberg *et al.*, 2006), were considered. Proton-density-weighted scans and apparent diffusion coefficient maps were less commonly used and not included in this study. Areas of hyperintensity were scored separately for each sequence. The quality of the complete MRI examination was graded from 1 to 6 (1=excellent, 2=good, 3=average, 4=sufficient, 5=insufficient, 6=poor). Scans graded higher than 4 were considered as non-diagnostic (mainly due to motion artefacts) and excluded from the study.

Statistical analysis

Descriptive statistics were reported for sCJD and control patients; χ^2 -test and the non-parametric Mann–Whitney test were used to assess differences between categorical and continuous variables.

The goal of our study was to identify the best combination of radiological findings and MRI sequences to discriminate between sCJD and non-sCJD patients. In order to do this we compared the results of visual assessments of brain MRI scans in cases and controls. We considered a brain region as affected when a high signal was found in either FLAIR or DWI MRI sequences. We calculated sensitivity [the percentage of scans considered as characteristic (positive) of sCJD in cases] and specificity [the percentage of scans considered as not characteristic (negative) of sCJD in controls] for several criteria patterns involving different combinations of affected regions and MRI sequences. We also calculated diagnostic odds ratios—the ratio of the odds of positivity in sCJD cases relative to the odds of positivity in the controls—to assess which combinations of criteria patterns yielded better test discriminatory performance; 95% confidence intervals of the diagnostic odds ratios were estimated by the exact method.

Inter-reader agreement for brain MRI scan visual assessment (normal or affected) was calculated, using Cohen's κ coefficient and Concordance Index, for all explored areas included in the standardized protocol. Concordance Index is the percentage of agreement between readers and the κ coefficient shows the difference in agreement, from chance, between them; thus a κ -value of 0 means no different from chance and 1 is perfect agreement.

Ethics

The study was done in accordance with the current revision of the Declaration of Helsinki and the Good Clinical Practice: Consolidated Guideline approved by the International Conference on Harmonization and applicable to national and local laws and regulations. For each participating site, the study protocol and all amendments were approved by an institutional review board or independent ethics committee. All patients and their caregivers gave written informed consent.

Results

Patients

In total, MRI scans were available for 436 patients with sCJD and 141 controls.

FLAIR sequences were available in 379 cases and in 128 controls, DWI in 258 cases and 81 controls. Both sequences were available in 201 cases and 68 controls. The median time from onset to MRI was 2.7 months in sCJD cases and 6.7 months in controls. Patient characteristics are summarized in Table 1.

Definition of the criteria

In the first part of the study, we analysed which FLAIR and/or DWI MRI lesion pattern was characteristic for sCJD, regardless of molecular subtype. To achieve this, a stepwise analysis was performed: (i) selection of the cortical regions; (ii) combination cortical/subcortical areas; and (iii) definition of the best MRI sequence (FLAIR/DWI).

Table 1 Patient characteristics

	n	Autopsy (%)	Female (gender) (%)	Median age (range)	Median duration (range) (months)	Time to MRI (months)	Codon 129 MM n (%)	Codon 129 MV n (%)	Codon 129 VV n (%)	FLAIR MRI (n)	DWI MRI (n)
sCJD	436	60.3	55.6	64.0 (35.3–85.0)	6.4 (1.0–56.3)	2.7	195 (62.7)	58 (18.6)	58 (18.6)	379	258
controls	144	39.1	48.8	65.9 (25.9–91.5)	12.0 (0.0–104.0)	6.7	11 (44.0)	8 (32.0)	6 (24.0)	128	81
P-value			0.27	0.2	0.007						

Table 2 Selection of cortical areas

		Frontal	Cinguli	Parietal	Temporal	Occipital	Insula	Hippocampus
CJD (% positive)	FLAIR	48	52	37	32	17	24	20
Control (% negative)	FLAIR	75	71	89	82	97	89	76
CJD (% positive)	DWI	74	71	65	59	37	52	21
Control (% negative)	DWI	65	61	89	81	90	77	88
Diagnostic odds ratio (95% CI)	FLAIR	2.73 (1.52–3.94)	2.636 (1.51–3.76)	4.986 (2.03–7.94)	2.058 (1.04–3.07)	6.43 (0.2–13.06)	2.382 (0.98–3.78)	0.77 (0.4–1.15)
	DWI	5.21 (2.44–7.98)	3.667 (1.76–5.57)	14.7 (3.85–25.56)	5.92 (2.37–9.46)	5.48 (1.25–9.71)	3.58 (1.55–5.62)	1.89 (0.5–3.28)

CI = confidence interval.

Selection of cortical regions

In this part of the study, we analysed the frequency of high signal detection in each cortical region for cases and controls and stratified the data by the MRI technique used (FLAIR or DWI, Table 2). As the result of this analysis, we selected three regions with the optimum sensitivity and specificity data, irrespective of MRI technique used. The three areas with the highest values for diagnostic accuracy were the parietal, occipital and temporal cortical regions. The other cortical brain regions such as cingulate gyrus, insular cortex or hippocampus were either non-discriminatory between cases and controls, had low specificity and, in addition to this, found low inter reader agreement, as reported before (Krasnianski *et al.*, 2008).

Combination of cortical and subcortical areas

Various combinations of high signal intensity were analysed in the three selected cortical (parietal, occipital and temporal) and subcortical regions. The results are given in Table 3. For FLAIR and DWI, the best results were obtained when two or more regions (either temporal, parietal, occipital) displayed a high signal in the MRI. The poorest specificity was obtained when MRI scans were considered positive when only one or more cerebral cortical region showed a high signal; therefore, those patterns were excluded for further analysis. For subcortical areas, the optimum diagnostic accuracy was obtained when a high signal increase was observed in both the caudate nucleus and putamen simultaneously. DWI was generally more sensitive than FLAIR with a similar specificity for both sequences.

Further analyses determined the best possible combination of various cerebral cortical and subcortical high signal changes. The highest diagnostic accuracy was obtained by accepting

either a combination of at least two cerebral cortical regions (temporal, occipital, parietal) showing increased signal or both the putamen and the caudate nucleus showing high signal intensity (Table 4).

Definition of the MRI sequence

After choosing the combination of either at least two cerebral cortical regions or both the putamen and caudate nucleus showing high signal as the optimal radiological pattern, we analysed which MRI pulse sequence or potential combination of sequences revealed the highest sensitivity and specificity. Both sequences achieved high diagnostic accuracy (Table 5). We calculated the data for other potential combinations, such as FLAIR and DWI positive, but the sensitivity achieved was only 54%.

In order to estimate the sensitivity and specificity of the combination FLAIR or DWI, we considered that patients with both pulse sequences available were most reliable, because including patients with only one sequence would result in a predominance of the 'only FLAIR performed' and a decrease in the sensitivity (Table 5), since FLAIR is less sensitive than DWI.

False-positive findings in the MRI

According to our criteria, 19 controls had positive findings on the MRI. Most of these suffered from an infectious or inflammatory disorder of the central nervous system ($n=9$), like lymphocytic encephalitis, progressive multifocal leucoencephalopathy, steroid responsive encephalitis associated with autoimmune thyroiditis (SREAT) or encephalitis of unknown origin. In other patients with a positive MRI, autopsy confirmed Alzheimer's disease ($n=2$), Dementia with Lewy bodies ($n=2$), epilepsy ($n=2$), intravascular lymphomatosis and mitochondrial cytopathy.

Table 3 Selection of cortical and subcortical areas

	FLAIR			DWI		
	Controls	Total sCJD cases	Definite CJD cases	Controls	Total sCJD cases	Definite sCJD cases
At least one cortical region ^a affected						
No (%)	94 (73.4)	190 (50.1)	111 (48.1)	60 (74.1)	57 (22.1)	29 (19.1)
Yes (%)	34 (26.6)	189 (49.9)	120 (51.9)	21 (25.9)	201 (77.9)	123 (80.9)
Diagnostic odds ratio (95% CI)	2.8 (1.5–4.0)		3.0 (1.6–4.4)	10.1 (4.3–15.9)		12.1 (4.4–19.9)
At least two cortical regions ^a affected						
No (%)	121 (94.5)	278 (73.4)	173 (74.9)	72 (88.9)	115 (44.6)	62 (40.8)
Yes (%)	7 (5.5)	101 (26.6)	58 (25.1)	9 (11.1)	143 (55.4)	90 (59.2)
Diagnostic odds ratio (95% CI)	6.3 (1.3–11.3)		5.8 (1.1–10.5)	10.0 (2.6–17.3)		11.6 (2.7–20.5)
More than three cortical regions affected						
No (%)	115 (89.8)	276 (72.8)	163 (70.6)	68 (84.0)	111 (43.0)	57 (37.5)
Yes (%)	13 (10.2)	103 (27.2)	68 (29.4)	13 (16.0)	147 (57.0)	95 (62.5)
Diagnostic odds ratio (95% CI)	3.3 (1.3–5.3)		3.7 (1.3–6.1)	6.9 (2.5–11.4)		8.7 (2.8–14.6)
Putamen or caudatum affected						
No (%)	104 (81.3)	147 (38.8)	83 (35.9)	67 (82.7)	83 (32.2)	44 (28.9)
Yes (%)	24 (18.8)	232 (61.2)	148 (64.1)	14 (17.3)	175 (67.8)	108 (71.1)
Diagnostic odds ratio (95% CI)	6.8 (3.5–10.2)		7.7 (3.7–11.7)	10.1 (3.7–16.5)		11.8 (3.8–19.7)
Both putamen and caudatum affected						
No (%)	120 (93.8)	223 (58.8)	135 (58.4)	76 (93.8)	133 (51.6)	76 (50.0)
Yes (%)	8 (6.3)	156 (41.2)	96 (41.6)	5 (6.2)	125 (48.4)	76 (50.0)
Diagnostic odds ratio (95% CI)	10.5 (2.7–18.3)		14.3 (0.9–27.7)	15.2 (0.6–29.8)		

a Parietal–temporal–occipital; CI = confidence interval; s = sCJD cases.

Table 4 Selection of cortical and subcortical areas best combination

	FLAIR			DWI		
	Controls	Total sCJD cases	Definite sCJD cases	Controls	Total sCJD cases	Definite sCJD cases
More than three cortical regions OR both Put. and NC affected						
No (%)	110 (85.9)	166 (43.8)	94 (40.7)	66 (81.5)	62 (24.0)	32 (21.1)
Yes (%)	18 (14.1)	213 (56.2)	137 (59.3)	15 (18.5)	196 (76.0)	120 (78.9)
Diagnostic odds ratio (95% CI)	7.8 (3.6–12.1)		8.9 (3.9–13.9)	13.9 (5.2–22.7)		16.5 (5.2–27.8)
More than three cortical regions OR Put. OR NC affected						
No (%)	99 (77.3)	113 (29.8)	60 (26.0)	61 (75.3)	41 (15.9)	19 (12.5)
Yes (%)	29 (22.7)	266 (70.2)	171 (74.0)	20 (24.7)	217 (84.1)	133 (87.5)
Diagnostic odds ratio (95% CI)	8.0 (4.3–11.8)		9.7 (4.8–14.7)	16.1 (6.4–25.9)		21.4 (6.5–36.2)
At least two cortical regions ^a affected OR both Put. and NC affected						
No (%)	116 (90.6)	162 (42.7)	97 (42.0)	70 (86.4)	63 (24.4)	33 (21.7)
Yes (%)	12 (9.4)	217 (57.3)	134 (58.0)	11 (13.6)	195 (75.6)	119 (78.3)
Diagnostic odds ratio (95% CI)	13.0 (4.8–21.1)		13.4 (4.7–22.0)	19.7 (6.0–33.4)		23.0 (5.9–40.0)
At least two cortical regions ^a affected OR Put. OR NC affected						
No (%)	103 (80.5)	106 (28.0)	58 (25.1)	62 (76.5)	42 (16.3)	21 (13.8)
Yes (%)	25 (19.5)	273 (72.0)	173 (74.9)	19 (23.5)	216 (83.7)	131 (86.2)
Diagnostic odds ratio (95% CI)	10.6 (5.4–15.8)		12.3 (5.8–18.8)	16.8 (6.5–27.0)		20.4 (6.3–34.4)

NC = nucleus caudatum; Put. = putamen.

a Parietal–temporal–occipital.

Two patients recovered and the diagnosis is not known. No distinctive MRI pattern could be detected for each disorder and the frequency of high signal abnormalities in cortical and subcortical areas was similar in all the diagnostic groups mentioned above.

Modification of clinical criteria for sCJD

Based on our results, we recommend modifying the current clinical diagnostic criteria for sCJD to include the detection of either

Table 5 Definition of MRI sequences for the pattern at least two cortical regions affected (parietal–temporal–occipital) or both putamen and nucleus caudatum affected

	Controls	Total sCJD cases	Definite sCJD cases
FLAIR AND DWI			
No (%)	64 (94.1)	92 (45.8)	55 (45.8)
Yes (%)	4 (5.9)	109 (54.2)	65 (54.2)
Total (n)	68	201	120
Diagnostic odds ratio (95%CI)	19.0 (0.9–38.8)		18.9 (1.4–39.2)
FLAIR OR DWI			
No (%)	122 (86.5)	133 (30.5)	75 (28.5)
Yes (%)	19 (13.5)	303 (69.5)	188 (71.5)
Total (n)	141	436	263
Diagnostic odds ratio (95%CI)	14.6 (7.0–22.3)		16.1 (7.2–25.0)
FLAIR OR DWI ^a			
No (%)	56 (82.3)	38 (18.9)	21 (17.5)
Yes (%)	12 (17.6)	163 (81.1)	99 (82.5)
Total (n)	68	201	120
Diagnostic odds ratio (95%CI)	20.0 (5.7–34.4)		22.0 (4.8–39.2)

a Only cases with both sequences available.

hyperintensity in the basal ganglia (both caudate nucleus and putamen) or in at least two cortical regions (from either the temporal, parietal or occipital cerebral cortices) (Fig. 1). This implies that the detection of the specified high signal abnormalities in FLAIR or DWI MRI will be considered at the same level of diagnostic importance as periodic sharp wave complexes on the EEG or 14-3-3 protein detection in the CSF.

Comparative analysis of the EEG, CSF and MRI

In a subgroup of 214 definite CJD patients and 77 definite non-cases, we analysed the frequency of true-positive results in cases (sensitivity) and true-negative results in controls (specificity), in relation to the detection of periodic sharp wave complexes in the EEG, elevated CSF levels of 14-3-3 protein or MRI abnormalities. Diagnostic MRI abnormalities for sCJD, as defined by our analyses, were observed in 83% of such patients with a specificity of 83%. For CSF 14-3-3 protein detection, test sensitivity was 86% but specificity was 68%. EEG had the lowest sensitivity (44%) and highest specificity (92%). Details on comparative analyses of current and amended criteria are given in Table 6. The sensitivity of current criteria is 92%, the specificity 71%. Thus, 8% of sCJD patients are not covered by the World Health

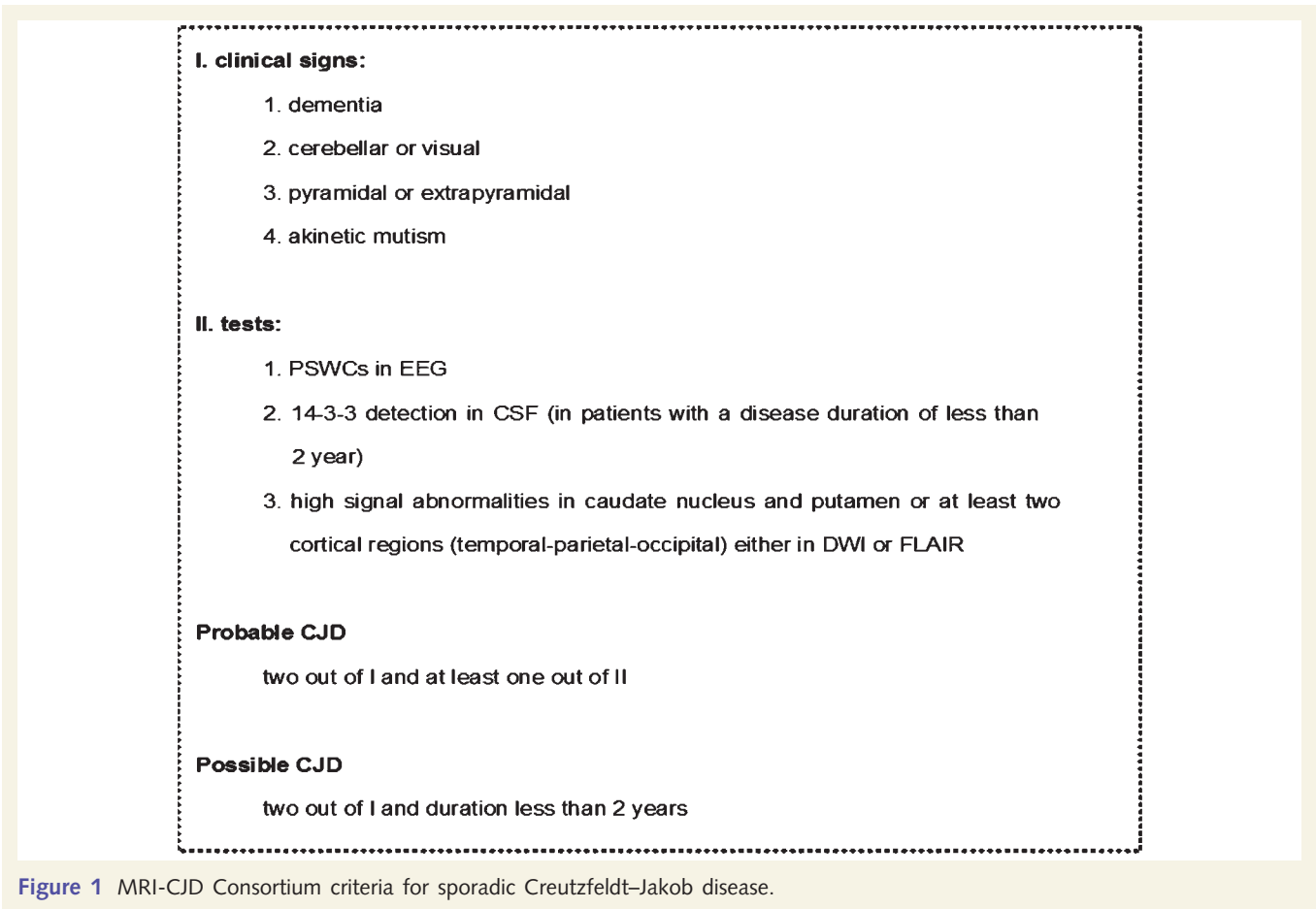


Figure 1 MRI-CJD Consortium criteria for sporadic Creutzfeldt–Jakob disease.

Table 6 Comparison of new and old criteria

	n	%	Sensitivity	Specificity
Current criteria				
Definite sporadic CJD cases with both EEG and 14-3-3 tests performed				
EEG atypical & 14-3-3 test negative	8	7.8	92.2	
EEG typical & 14-3-3 test negative	7	6.8		
EEG atypical & 14-3-3 test positive	49	47.6		
EEG typical & 14-3-3 test positive	39	37.9		
Total	103	100		
Controls with both EEG and 14-3-3 tests performed				
EEG atypical & 14-3-3 test negative	37	71.2		71.2
EEG typical & 14-3-3 test negative	1	1.9		
EEG atypical & 14-3-3 test positive	12	23.1		
EEG typical & 14-3-3 test positive	1	1.9		
Total	52	100		
New criteria				
Definite sporadic CJD cases with all three tests performed (EEG, 14-3-3 tests, and MRI FLAIR and DWI, new criteria)				
Current criteria negative & MRI negative	1	2.0	98	
Current criteria positive & MRI negative	7	14		
Current criteria negative & MRI positive	3	6		
Current criteria positive & MRI positive	39	78		
Total	50	100		
Controls with all three tests performed (EEG, 14-3-3 tests, and MRI FLAIR and DWI)				
Current criteria negative & MRI negative	17	70.8		70.8
Current criteria positive & MRI negative	5	20.8		
Current criteria negative & MRI positive	1	4.2		
Current criteria positive & MRI positive	1	4.2		
Total	24	100		

Table 7 Sensitivity of old and new criteria for each molecular disease subtype

Disease subtype	Positive MRI/total (%)	Positive 14-3-3/total (%)	Positive EEG/total (%)	New criteria positive (%)	Old criteria positive (%)
MM1	33/43 (76.7)	38/42 (90.5)	26/43 (60.5)	100	97.6
MM2	14/15 (93.3)	9/14 (64.3)	3/14 (21.4)	92.3	69.2
MV1	6/6 (100)	5/6 (83.3)	3/6 (50)	100	100
MV2	8/8 (100)	7/8 (87.5)	0/8 (0)	100	87.5
VV1	2/2 (100)	2/2 (100)	1/2 (50)	100	100
VV2	9/15 (60)	14/15 (93.3)	0/15 (0)	100	93.3
All	72/89 (80.9)	75/87 (86.2)	33/88 (37.5)	98.8	91.9

Organization criteria. By inclusion of the MRI as an additional parameter for 'probable' CJD, the sensitivity of clinical criteria rises substantially to 98%, but specificity drops marginally.

an atypical clinical syndrome and thus not be properly diagnosed on clinical grounds (Krasnianski *et al.*, 2006a, b)

Value of MRI in identification of various molecular sCJD subtypes

A comparative analysis of protein 14-3-3, EEG and MRI in a subset of CJD patients with data on pathogenic prion protein type and codon 129 genotype available is shown in Table 7. Currently used criteria improved the recognition of some of the less typical sCJD subtypes such as VV2. Amended criteria, as suggested here, are especially helpful for the rare and atypical subtypes such as MM2, MV1 and MV2. The latter may develop

Discussion

This multi-centre collaborative study analysed findings from MRI scans in a large number of sCJD cases and controls; and has provided evidence that justifies the inclusion of defined MRI pattern in the clinical diagnostic criteria for sCJD. In a previous manuscript, we reported characteristic MRI patterns for each molecular CJD subtype (Meissner *et al.*, 2009) and identified variables which allowed for the best discrimination between those subtypes. We chose the following radiological signs as predictors of sCJD subtypes: high signal in (i) more than three

cerebral cortical regions; (ii) hippocampus; (iii) any basal ganglia; (iv) any thalamic nuclei; and (v) cerebellum. Multivariate analysis, including the five selected regions, was performed in order to allow independent assessment of these parameters and a specific MRI lesion pattern for each molecular disease subtype was identified (Meissner *et al.*, 2009). Specificity of MRI changes was not addressed. Since the information on specificity is essential for an assessment of the true utility of MRI brain scan in the diagnosis of sCJD, we performed the current study.

In order to assess the sensitivity of MRI in the diagnosis of sCJD, we developed a set of variables which allowed the optimum discrimination between CJD and controls. In this analysis, we selected anatomical regions which have been demonstrated to be frequently affected (Meissner *et al.*, 2009). The characteristic MRI lesion pattern, which allowed for the best discrimination between sCJD cases and controls was found to be high signal intensity in FLAIR or DWI in at least two cortical regions, or signal increase in the caudate nucleus and putamen. Based on these findings, we propose that the clinical diagnostic criteria for sCJD are amended to include MRI signal abnormalities as defined above (Fig. 1). The MRI findings will thus be equivalent to elevated levels of 14-3-3 proteins or periodic sharp and slow wave complexes in the EEG for the clinical diagnosis of probable sCJD.

With respect to current clinical tests for sCJD, the EEG was the first *in vivo* test to be used to support the clinical diagnosis of sCJD. However, the EEG has been shown to be positive in only a subset of sCJD patients, usually MM1 or MV1 cases. Typically, periodic sharp wave complexes are detected late in the disease and the median time to positive EEG is around 12 weeks. This corresponds to the terminal stages of the illness (Poser *et al.*, 1999; Zerr *et al.*, 2000a; Collins *et al.*, 2006). A number of CSF biomarkers have been reported in sCJD, including 14-3-3, tau, S100b, neuron-specific enolase, phosphorylated tau and abeta, with the majority of available data relating to 14-3-3 and tau proteins (Sanchez-Juan *et al.*, 2006). Both these biomarkers support the clinical CJD diagnosis with a sensitivity of 92% and specificity of 71% (Sanchez-Juan *et al.*, 2006). However, a number of publications have indicated that low levels of these biomarkers are present in the CSF in some atypical CJD variants (Castellani *et al.*, 2004; Sanchez-Juan *et al.*, 2006; Gmitterová *et al.*, 2008). Biological variables such as long disease duration, young age at onset, type 2 pathogenic prion protein and heterozygosity at codon 129 genotype of the PrP gene are all associated with low biomarker levels (Parchi *et al.*, 1999; Zerr *et al.*, 2000b; Castellani *et al.*, 2004; Sanchez-Juan *et al.*, 2006). This is in contrast with the results of MRI scans in some atypical and rare variants of sCJD, such as VV1 and MV2: in VV1 patients there is high signal in the cortical areas and normal signal in the basal ganglia, while in MV2 patients characteristic abnormalities are seen in the basal ganglia, putamen and thalamus (Meissner *et al.*, 2005; Krasnianski *et al.*, 2006b, 2008). Characteristic lesion patterns have recently been reported for patients with other molecular disease subtypes (Meissner *et al.*, 2009) and the question was raised whether MRI brain scan might contribute to the improved diagnosis across sCJD subtypes (Tschampa *et al.*, 2005; Meissner *et al.*, 2009).

Table 7 shows the data on positive tests in a subgroup of patients with known molecular type. MRI findings are positive in 81% of sCJD patients. Sensitivity of the 14-3-3 test is 86% and significantly less for the EEG. By combination of all parameters, sensitivity is 98% and specificity of the criteria is 71%. Although the frequency and location of high signal intensities vary between subtypes, by amendment of clinical criteria, most molecular disease subtypes will be covered, including rare subtypes VV1 and MV2 (Table 7).

Our results indicate a high rate of agreement between identification of cortical parietal, temporal and occipital signal and basal ganglia involvement between five raters, even in a cohort of patients where MRI scans were acquired at different centres, with some modifications. These results suggest that MRI is a robust investigation in sCJD and qualifies as a potential biomarker for CJD.

A limitation of this study is the high number of sCJD cases as compared to controls. However, the gold standard for the validation of the clinical diagnostic criteria was the analysis of the subset of sCJD cases in which the diagnosis had been confirmed by neuropathology. In controls, only data from patients in which the diagnosis of CJD had been definitely excluded by neuropathology or in which there was a definite alternative clinical diagnosis, were used. This group included cases who recovered, cases with inflammatory CSF findings indicating an alternative diagnosis or a clinical course which excluded CJD as a diagnosis (Heinemann *et al.*, 2007). In the context of a multi-centre MRI study on a rare disorder, achieving a high autopsy rate in non-cases is difficult and it would take many years to obtain a representative autopsy sample of non-cases at a similar rate to the sCJD cases. Epidemiological surveillance studies on rare disorders are person and cost intensive and a study with selected MRI scans on more than 300 cases and controls on a solely autopsic sample is unlikely to be feasible in the near future. However, in this study, we have achieved neuropathology confirmation in 40% of controls and in 60% of CJD patients.

Our analysis has shown that MRI findings may lead to false positive diagnosis in a small number of cases. This is an important issue for the accurate diagnosis of sCJD. Almost 50% of false-positive findings on the MRI were associated with inflammatory conditions; the other diagnoses were Alzheimer's disease and Dementia with Lewy bodies (Haik *et al.*, 2000; Tschampa *et al.*, 2001). Inflammatory conditions of the brain represent the most important differential diagnosis as there may be a possibility for treatment (Chang *et al.*, 2007; Heinemann *et al.*, 2007; Geschwind *et al.*, 2008). In our patients, diagnoses included encephalitis of unknown origin and SREAT (Seipelt *et al.*, 1999). The latter diagnosis has been described previously as an important treatable condition in the differential diagnosis of CJD. The crucial question for the clinician is how to avoid the misinterpretation of tests and how to avoid missing a treatable condition in a patient with a rapid progressive dementia and focal neurological signs (Josephs *et al.*, 2009). Thorough analysis of the cerebrospinal fluid for routine parameters such as cell count, protein and oligoclonal bands (which are often positive in SREAT and other inflammatory conditions, but usually negative in CJD) may be helpful in diagnosis (Jacobi *et al.*, 2005; Green *et al.*, 2007). As other tests,

such as 14-3-3 and EEG, may also show 'false-positive' results in inflammatory conditions of the brain, accurate clinical diagnosis can be a major challenge. Thus, patients with 'inflammatory' abnormalities in the CSF such as pleocytosis, high elevated protein content and oligoclonal immunoglobulin G should enter the diagnostic pathway for potentially treatable conditions (Vernino *et al.*, 2007).

The time point at which the clinical diagnosis of sCJD is made may be very important if treatment strategies become available as any therapy will probably need to be started early if it is to be effective. The EEG has been shown to become positive usually only in the late stages of the disease. CSF biomarkers can become positive in the early disease stages, as shown in a cohort of patients with repeated lumbar punctures and multiple CSF tests (Sanchez-Juan *et al.*, 2007). With MRI the question on when the typical changes appear is still unresolved because of the limited number of patients with multiple scans. However, there is a suggestion from the literature that MRI may become positive early in the disease (Young *et al.*, 2005; Fujita *et al.*, 2008; Galanaud *et al.*, 2008; Hoshino *et al.*, 2008). Further work will be needed to address this question.

In summary, our data show that basal ganglia and cortical hyperintensities represent the most frequent MRI findings in sCJD and are present in most cases. Characteristic brain MRI lesion patterns are helpful in establishing a diagnosis of sCJD and may help to identify atypical sporadic disease forms. This is the most comprehensive study on MRI findings in sCJD to date, and in combination with previous studies, provides firm evidence that brain MRI has a high sensitivity and specificity in the diagnosis of the disease.

Acknowledgements

This study was supported by grants from the German Federal Ministry of Education and Research (Brain imaging as an aid to determine molecular subtype in prion diseases, BMBF ARG07/008 and Forschungsnetz zur Verbesserung der Früh- und Differentialdiagnose der CJK und rasch progressiver Demenzen, BMBF 01 610 301 to I.Z.), by the Robert Koch-Institut through funds of the Federal Ministry of Health (grant no 1369-341), and by the Verein zur Förderung der Wissenschaft und Forschung an der Neurologischen Klinik Göttingen e.V. (to I.Z.)

Grants at national levels are reported below:

Argentina

FLENI-SECYT BID 802-OC-AR PID 98/027/BID 1728; OC-AR PID 2003/351; BMBF-MINCYT-ARG 10/008

We thank all the neurologists who contributed to CJD surveillance in Argentina and especially to Dr E. Meichtry - Moguillansky Clinic- Neuquén-Argentina for his continuous support.

Australia

The Australian National Creutzfeldt-Jakob disease Registry (ANCJDR) thanks Colin Masters, Alison Boyd, Genevieve Klug, Samantha Douglas, Christiane Stehmann and Amelia McGlade for their valuable contributions, as well as the families of CJD

patients and their physicians for their generous support and assistance. The ANCJDR is funded by the Commonwealth Department of Health and Ageing.

Belgium

Fonds voor Wetenschappelijk Onderzoek; Born Bunge Institute.

Canada

The Canadian Creutzfeldt-Jakob Disease Surveillance System thanks the families of CJD patients and their physicians for participation in the study. Canadian Neuropathologists are acknowledged for their valuable contributions. All personnel of the Prion Diseases Program are thanked for their enthusiastic cooperation.

France

We thank all members of the French National Surveillance Network for Creutzfeldt-Jakob disease and all physicians for case notification and provision of clinical and pathological data and MRI scan.

Germany

This study was funded by Robert Koch-Institute through funds of the Federal Ministry of Health (grant no 1369-341). We thank physicians for case notification and provision of clinical and pathological data and MRI scans to the National TSE Surveillance Unit, Göttingen, Germany. We are grateful to Jolanthe Ehrlich for her technical assistance in the data base management.

Italy

We thank neurologists and neurodiologists for case notification and provision of clinical and MRI scans, Dr Piero Parchi, Prof. Salvatore Monaco, Dr. Gianluigi Zanusso and Dr Carlo Buffa for the neuropathological evaluation and PrP western blot typing, Dr Sabina Capellari, Dr Daniele Imperiale, Dr Anna Poleggi, Dr Claudia Giannattasio and Mr Michele Equestre for genetic and CSF 14-3-3 analyses. This work was partially supported by the National Registry of CJD and related disorders of the Istituto Superiore di Sanità, Rome, Italy.

Slovenia

We thank all members of the national CJD surveillance group as well as all physicians involved in case notification and we are especially grateful to neuroradiologists for providing us with the MRI scans.

Spain

Fondo de Investigacion Sanitaria (grant PI080139).

Switzerland

We thank all referring physicians. The national Reference Center for Prion Diseases is funded by the Swiss federal Office of Public Health.

UK

The authors are grateful to neuroradiologists from throughout the UK for access to MRI scans. In part by the Department of Health

(121/7369); European Union (Network of Excellence FOOD CT 2004 056579 and ECDC: grant number ECD 607). The UK National CJD Surveillance Unit is funded by the Department of Health and the Scottish Executive Department of Health.

References

- Castellani RJ, Colucci M, Xie Z, Zou W, Li C, Parchi P, et al. Sensitivity of 14-3-3 protein test varies in subtypes of sporadic Creutzfeldt-Jakob disease. *Neurology* 2004; 63: 436–42.
- Chang CC, Eggers SD, Johnson JK, Haman A, Miller BL, Geschwind MD. Anti-GAD antibody cerebellar ataxia mimicking Creutzfeldt-Jakob disease. *Clin Neurol Neurosurg* 2007; 109: 54–7.
- Collie DA, Summers DM, Sellar RJ, Ironside JW, Cooper S, Zeidler M, et al. Diagnosing variant Creutzfeldt-Jakob disease with the pulvinar sign: MR imaging findings in 86 neuropathologically confirmed cases. *Am J Neuroradiol* 2003; 24: 1560–9.
- Collins SJ, Sanchez-Juan P, Masters CL, Klug GM, van Duijn C, Pileggi A, et al. Determinants of diagnostic investigation sensitivities across the clinical spectrum of sporadic Creutzfeldt-Jakob disease. *Brain* 2006; 129: 2278–87.
- Fujita K, Nakane S, Harada M, Izumi Y, Kaji R. Diffusion tensor imaging in patients with Creutzfeldt-Jakob disease. *J Neurol Neurosurg Psychiatry* 2008; 79: 1304–6.
- Galanaud D, Dormont D, Haik S, Chiras J, Brandel JP, Ranjeva JP. Differences of apparent diffusion coefficient values in patients with Creutzfeldt-Jakob disease according to the codon 129 genotype. *AJNR Am J Neuroradiol* 2008; 29: E57.
- Gambetti P, Kong Q, Zou W, Parchi P, Chen S. Sporadic and familial CJD: classification and characterisation. *Br Med Bull* 2003; 66: 213–39.
- Geschwind MD, Potter CA, Sattavat M, Garcia PA, Rosen HJ, Miller BL, et al. Correlating DWI MRI with pathologic and other features of Jakob-Creutzfeldt disease. *Alzheimer Dis Assoc Disord* 2009; 23: 82.
- Geschwind MD, Tan KM, Lennon VA, Barajas RFJ, Haman A, Klein CJ, et al. Voltage-gated potassium channel autoimmunity mimicking Creutzfeldt-Jakob disease. *Arch Neurol* 2008; 65: 1341–6.
- Gmitterová K, Heinemann U, Bodemer M, Krasnianski A, Meissner B, Kretschmar HA, et al. 14-3-3 CSF levels in sporadic Creutzfeldt-Jakob disease differ across molecular subtypes. *Neurobiol Aging*. epub ahead of print.
- Green A, Sanchez-Juan P, Ladogana A, Cuadrado-Corrales N, Sanchez-Valle R, Mitrova E, et al. CSF analysis in patients with sporadic CJD and other transmissible spongiform encephalopathies. *Eur J Neurol* 2007; 14: 121–4.
- Haik S, Brandel JP, Szadovitch V, Delasnerie-Lauprêtre N, Peoc'h K, Laplanche J-L, et al. Dementia with Lewy bodies in a neuropathologic series of suspected Creutzfeldt-Jakob disease. *Neurology* 2000; 55: 1401–4.
- Heinemann U, Krasnianski A, Meissner B, Varges D, Bartl M, Stoeck K, et al. Creutzfeldt-Jakob disease in Germany: a prospective 12-year surveillance. *Brain* 2007; 130: 1350–9.
- Hoshino A, Iwasaki Y, Izumi M, Kimura S, Ibi T, Kitamoto T, et al. MM1-type sporadic Creutzfeldt-Jakob disease with unusually prolonged disease duration presenting with panencephalopathic-type pathology. *Neuropathology* 2008; 28: 326–32.
- Jacobi C, Arlt S, Reiber H, Westner I, Kretschmar HA, Poser S, et al. Immunoglobulins and virus-specific antibodies in patients with Creutzfeldt-Jakob disease. *Acta Neurol Scand* 2005; 111: 185–90.
- Josephs KA, Ahlskog E, Parisi JE, Boeve BF, Crum BA, Giannini C, et al. Rapidly progressive neurodegenerative dementias. *Arch Neurol* 2009; 66: 201–7.
- Kallenberg K, Schulz-Schaeffer W, Jastrow U, Poser S, Meissner B, Tschampa H, et al. Creutzfeldt-Jakob disease: comparative Analysis of MR Imaging Sequences. *Am J Neuroradiol* 2006; 27: 1459–62.
- Krasnianski A, Kallenberg K, Collie DA, Meissner B, Schulz-Schaeffer WJ, Heinemann U, et al. MRI in the classical MM1 and the atypical MV2 subtypes of sporadic CJD: an inter-observer agreement study. *Eur J Neurol* 2008; 15: 762–71.
- Krasnianski A, Meissner B, Schulz-Schaeffer W, Kallenberg K, Bartl M, Heinemann U, et al. Clinical features and diagnosis of the MM2 cortical subtype of sporadic Creutzfeldt-Jakob disease. *Arch Neurol* 2006a; 63: 876–80.
- Krasnianski A, Schulz-Schaeffer WJ, Kallenberg K, Meissner B, Collie DA, Roeber S, et al. Clinical findings and diagnostic tests in the MV-2 subtype of sporadic CJD. *Brain* 2006b; 129: 2288–96.
- Masters CL, Harris JO, Gajdusek DC, Gibbs CJJ, Bernoulli C, Asher DM. Creutzfeldt-Jakob disease: patterns of worldwide occurrence and the significance of familial and sporadic clustering. *Ann Neurol* 1979; 5: 177–88.
- Meissner B, Kallenberg K, Sanchez-Juan P, Collie DA, Summers DM, Almonti S, et al. MRI lesion profiles in sporadic Creutzfeldt-Jakob disease. *Neurology* 2009; 72: 1994–2001.
- Meissner B, Kallenberg K, Sanchez-Juan P, Krasnianski A, Heinemann U, Varges D, et al. Isolated cortical signal increase on MR imaging as a frequent lesion pattern in sporadic Creutzfeldt-Jakob disease. *Am J Neuroradiol* 2008; 29: 1519–24.
- Meissner B, Westner I, Kallenberg K, Krasnianski A, Bartl M, Varges D, et al. Sporadic Creutzfeldt-Jakob disease: clinical and diagnostic characteristics of the rare VV1 type. *Neurology* 2005; 65: 1544–50.
- Parchi P, Castellani R, Capellari S, Ghetti B, Young K, Chen SG, et al. Molecular basis of phenotypic variability in sporadic Creutzfeldt-Jakob disease. *Ann Neurol* 1996; 39: 767–78.
- Parchi P, Giese A, Capellari S, Brown P, Schulz-Schaeffer W, Windl O, et al. Classification of sporadic Creutzfeldt-Jakob disease based on molecular and phenotypic analysis of 300 subjects. *Ann Neurol* 1999; 46: 224–33.
- Poser S, Mollenhauer B, Krauss A, Zerr I, Steinhoff BJ, Schröter A, et al. How to improve the clinical diagnosis of Creutzfeldt-Jakob disease. *Brain* 1999; 122: 2345–51.
- Sanchez-Juan P, Green A, Ladogana A, Cuadrado-Corrales N, Sanchez-Valle R, Mitrova E, et al. CSF tests in the differential diagnosis of Creutzfeldt-Jakob disease. *Neurology* 2006; 67: 637–43.
- Sanchez-Juan P, Sanchez-Valle R, Green A, Ladogana A, Cuadrado-Corrales N, Mitrova E, et al. Influence of timing on CSF tests value for Creutzfeldt-Jakob disease diagnosis. *J Neurol* 2007; 254: 901–6.
- Satoh K, Shirabe S, Tsujino A, Eguchi H, Motomura M, Honda H, et al. Total tau protein in cerebrospinal fluid and diffusion-weighted MRI as an early diagnostic marker for Creutzfeldt-Jakob disease. *Dement Geriatr Cogn Disord* 2007; 24: 207–12.
- Seipelt M, Zerr I, Nau R, Mollenhauer B, Kropp S, Steinhoff BJ, et al. Hashimoto encephalitis as a differential diagnosis of Creutzfeldt-Jakob disease. *J Neurol Neurosurg Psychiatry* 1999; 66: 172–6.
- Tschampa HJ, Kallenberg K, Meissner B, Kretschmar HA, Knauth M, Urbach H, et al. Pattern of cortical changes in sporadic Creutzfeldt-Jakob disease. *Am J Neurorad* 2007; 28: 1114–8.
- Tschampa HJ, Kallenberg K, Urbach H, Meissner BC, N, Kretschmar HA, et al. MRI in the diagnosis of sporadic Creutzfeldt-Jakob disease: a study on inter-observer agreement. *Brain* 2005; 128: 2026–33.
- Tschampa HJ, Neumann M, Zerr I, Henkel K, Schröter A, Schulz-Schaeffer WJ, et al. Patients with Alzheimer's disease and dementia with Lewy bodies mistaken for Creutzfeldt-Jakob disease. *J Neurol Neurosurg Psychiatry* 2001; 71: 33–9.
- Vernino S, Geschwind MD, Boeve B. Autoimmune encephalopathies. *Neurologist* 2007; 13: 140–7.
- Young GS, Geschwind MD, Fischbein NJ, Martindale JL, Henry RG, Liu S, et al. Diffusion-weighted and fluid-attenuated inversion recovery imaging in Creutzfeldt-Jakob disease: high sensitivity and specificity for diagnosis. *Am J Neuroradiol* 2005; 26: 1551–62.
- Zerr I, Pocchiari M, Collins S, Brandel JP, de Pedro Cuesta J, Knight RSG, et al. Analysis of EEG and CSF 14-3-3 proteins as aids to the diagnosis of Creutzfeldt-Jakob disease. *Neurology* 2000a; 55: 811–5.
- Zerr I, Schulz-Schaeffer WJ, Giese A, Bodemer M, Schröter A, Henkel K, et al. Current clinical diagnosis in CJD: identification of uncommon variants. *Ann Neurol* 2000b; 48: 323–9.