



# Periprosthetic joint infection: current concepts and outlook

Petra Izakovicova<sup>1</sup>  
Olivier Borens<sup>2</sup>  
Andrej Trampuz<sup>3</sup>

- Periprosthetic joint infection (PJI) is a serious complication occurring in 1% to 2% of primary arthroplasties, which is associated with high morbidity and need for complex interdisciplinary treatment strategies.
- The challenge in the management of PJI is the persistence of micro-organisms on the implant surface in the form of biofilm. Understanding this ability, the phases of biofilm formation, antimicrobial susceptibility and the limitations of host local immune response allows an individual choice of the most suitable treatment.
- By using diagnostic methods for biofilm detection such as sonication, the sensitivity for diagnosing PJI is increasing, especially in chronic infections caused by low-virulence pathogens.
- The use of biofilm-active antibiotics enables eradication of micro-organisms in the presence of a foreign body. The total duration of antibiotic treatment following revision surgery should not exceed 12 weeks.

**Keywords:** arthroplasty; biofilm; diagnosis; periprosthetic joint infection; treatment

Cite this article: *EFORT Open Rev* 2019;4:482-494.  
DOI: 10.1302/2058-5241.4.180092

## Introduction

Periprosthetic joint infection (PJI) occurs in 1% to 2% of primary and in 4% of revision arthroplasties.<sup>1-4</sup> Due to higher life expectancy, lifestyle changes in increasingly elderly populations and more expectations for mobility in older age, the number of implanted prosthetic joints continues to rise.<sup>2</sup> With a steadily increasing number of implantations, the number of PJI cases also rises continuously. Longer prosthesis indwelling time is associated with a higher cumulative risk for haematogenous infections during the entire implant lifetime. Development of modern detection methods for microbial biofilms helps to

recognize even chronic infections that would previously have been missed.

Management of PJI requires complex treatment strategies including multiple surgical revisions and long-term antimicrobial treatment. An accurate diagnosis with identification of the infecting micro-organism(s) and its antimicrobial susceptibility is important for choosing the most appropriate treatment strategy to eradicate the infection. When missed or undertreated, PJI leads to persistence of infection and multiple surgical revisions causing poor function or disability, considerably impairing quality of life.<sup>3</sup>

Various specialists with different approaches such as orthopaedic and plastic surgeons, infectious disease physicians and microbiologists are involved in the management of PJI. This interdisciplinary approach is crucial for achieving optimal outcome.<sup>5</sup> In this review article, we provide an outlook on the current concepts in management of PJI including pathogenesis, diagnosis, classification and treatment algorithm.

## Pathogenesis

Around two thirds of PJI cases are caused through intra-operative inoculation of micro-organisms.<sup>3</sup> Depending on microbial virulence, PJI can manifest either early (within the first four weeks after implantation) or with a delay (typically between three months and three years). Early infections manifest with clear local and systemic signs of inflammation and are predominantly caused by high-virulent pathogens (e.g. *Staphylococcus aureus*, streptococci, enterococci). Delayed infections present with more subtle symptoms such as joint pain and early loosening and are caused by low-virulent organisms (e.g. coagulase-negative staphylococci or *Cutibacterium* species).<sup>3</sup>

All prosthetic joints remain susceptible to haematogenous seeding from a distant primary focus during their entire indwelling time. High vascularity of periprosthetic tissue exposes the prosthesis to the highest risk of

haematogenous infection in the first years after implantation. Typically, patients present with acute onset of clinical symptoms after a painless post-operative period.<sup>6</sup> The risk after bacteraemia with *S. aureus* is reported up to 34%.<sup>7</sup> The search for and the elimination of the primary focus is necessary in preventing infection relapse. The most common primary foci are: skin and soft tissue infections (e.g. *Staphylococcus aureus*), respiratory tract infections (e.g. *Streptococcus pneumoniae*), gastrointestinal infections (e.g. *Salmonella*, *Bacteroides*, *Streptococcus gallolyticus*) or urinary tract infections (e.g. *Escherichia coli*, *Klebsiella*, *Enterobacter* spp.). Haematogenous spread of infection may also occur during dental procedures, especially viridans group streptococci. In the case of infected intra-vascular devices, even low-virulent bacteria such as *Staphylococcus epidermidis* can cause haematogenous infections.<sup>6</sup>

Direct spread of infection ('per continuitatem') occurs either through direct contact between the prosthesis and the outer world (open periprosthetic fracture) or as a spread from a nearby infectious focus (soft tissue infection, osteomyelitis).

### Role of microbial biofilm and foreign bodies

The ability to grow and persist on the implant surface and on necrotic tissue in the form of a biofilm represents a basic survival mechanism by which micro-organisms resist environmental factors.<sup>8</sup> After the first contact with the implant, micro-organisms immediately adhere to its surface. In the first hours after the adhesion multilayer cellular proliferation, as well as cell-to-cell adhesion, lead to formation of micro-colonies and to initial growth of biofilm. Mature biofilms take four weeks to develop<sup>9</sup> and represent complex 3D-communities where micro-organisms of one or several species live clustered together in a highly hydrated, self-produced extracellular matrix (slime). Depletion of metabolic substances and waste product accumulation cause micro-organisms to enter a slow- or non-growing (stationary) state.<sup>10</sup> Planktonic bacteria can detach at any time, activating the host immune system, causing inflammation, oedema, pain and early implant loosening.

The presence of a foreign body reduces the minimal infecting dose of *S. aureus* more than 100,000-fold.<sup>11</sup> This is caused by a locally acquired immune defect, as granulocytes show decreased phagocytic activity (the so-called frustrated phagocytosis). Activation of granulocytes on foreign surfaces leads to the release of human neutrophil peptides (defensins) that de-activate the granulocytes.<sup>9,12,13</sup>

Biofilm micro-organisms are up to 1000 times more resistant to growth-dependent antimicrobial agents than

their planktonic counterparts. In vitro susceptibility testing with the determination of minimal inhibitory concentrations (MIC) do not reflect the in vivo situation and in the clinical setup the effective local concentration of many antibiotics cannot be reached by systemic application only.<sup>14–18</sup>

### Definition of PJI

Over the past years, various definition criteria for PJI have been described by several organizations and societies. At the International Consensus Meeting in 2014 and 2018, definition criteria for the diagnosis of PJI were proposed.<sup>19</sup> However, these accepted criteria are missing a considerable number of chronic (low-grade) PJIs. Therefore, new working criteria have been presented at the annual meeting of the European Bone and Joint Infection Society (EBJIS) 2018 in Helsinki, Finland and are currently under revision. Using these proposed criteria various studies showed better sensitivity for diagnosing PJI, especially for chronic PJIs typically caused by low-virulent pathogens (Table 1).<sup>20–23</sup>

### Classification

The most important PJI classification is based on the time since primary onset of the symptoms (Table 2). This directly suggests the maturation stage of the present biofilm and is crucial in choosing the optimal treatment strategy.

### Diagnosis

A combination of laboratory, histopathology, microbiology and imaging studies is required for the most accurate diagnosis of PJI.<sup>24</sup> Ideally, the infection is diagnosed (or excluded) before the surgery, which allows the planning of the most appropriate treatment strategy. However, pre-operative microbial detection is not necessary for the selection of the type of surgical revision, which is based on clinical and radiological signs (Fig. 1).<sup>25</sup>

#### Clinical signs

Leading clinical signs of an acute infection are systemic (fever) and local (pain, erythema, oedema, prolonged post-operative wound effusion or dehiscence and impaired joint function). Many chronic infections are clinically difficult to distinguish from aseptic failure as those signs may be completely lacking. Patients often present with chronic pain or only slight clinical symptoms. The only definitive clinical signs confirming infection are the presence of a sinus tract or visible purulence around the prosthesis (if other causes such as adverse tissue reaction related to a metal-on-metal bearing, crystal arthropathy, reactive arthritis etc. are excluded).

**Table 1.** Definition of periprosthetic joint infection  
Periprosthetic joint infection is diagnosed, if ≥ 1 criterion is fulfilled.

Test	Criteria	Sensitivity	Specificity
<b>Clinical features</b>	Sinus tract (fistula) or purulence around prosthesis <sup>a</sup>	20–30%	100%
<b>Leukocyte count in synovial fluid<sup>b</sup></b>	> 2000/μl leukocytes or > 70% granulocytes (PMN)	≈ 90%	≈ 95%
<b>Periprosthetic tissue histology<sup>c</sup></b>	Inflammation (≥ 23 granulocytes per 10 high-power fields)	73%	95%
<b>Microbiology</b>	Microbial growth in:		
	• Synovial fluid <sup>d</sup> or	45–75%	95%
	• ≥ 2 positive tissue samples (of at least 3 collected) <sup>d</sup> or	60–80%	92%
	• Sonication fluid (> 50 CFU/ml) <sup>e</sup>	80–90%	95%

<sup>a</sup>Metal-on-metal bearing components can simulate pus ('pseudopus'), leukocyte count is usually normal (metal debris is visible). <sup>b</sup>Leukocyte count can be high without infection in the first six weeks after surgery, in rheumatic joint disease (including crystallopathy), periprosthetic fracture or luxation. Leukocyte count should be determined within 24 hours after aspiration using microscopy or automated counter; clotted specimens are treated with 10 μl hyaluronidase. <sup>c</sup>Classification after Krenn and Morawietz<sup>61</sup>: PJI corresponds to type 2 or type 3. <sup>d</sup>For highly virulent organisms (e.g. *S. aureus*, streptococci, *E. coli*) or patients under antibiotics, one positive sample confirms infection. <sup>e</sup>Under antibiotics, for *S. aureus* and anaerobes, < 50 CFU/ml can be significant.

**Table 2.** Classification of periprosthetic joint infection (PJI)

	Acute PJI (immature biofilm)	Chronic PJI (mature biofilm)
<b>Pathogenesis</b>		
• <b>Perioperative</b>	< 4 weeks after surgery (early)	≥ 4 weeks after surgery (delayed/low grade)
• <b>Haematogenous or 'per continuitatem'</b>	< 3 weeks duration of symptoms	≥ 3 weeks of duration of symptoms
<b>Clinical features</b>	Acute pain, fever, red/ swollen joint, prolonged post-operative discharge (>7–10 days)	Chronic pain, loosening of the prosthesis, sinus tract (fistula)
<b>Causative micro-organism</b>	High-virulence: <i>Staphylococcus aureus</i> , gram-negative bacteria (e.g. <i>Escherichia coli</i> , <i>Enterobacter</i> , <i>Klebsiella</i> , <i>Pseudomonas aeruginosa</i> )	Low-virulence: Coagulase-negative staphylococci (e.g. <i>Staphylococcus epidermidis</i> ), <i>Cutibacterium species</i>
<b>Surgical treatment</b>	Debridement and retention of prosthesis (change of mobile parts)	Complete removal of prosthesis (exchange in one or two stages)

*Imaging studies*

Examination of serial conventional radiographs may be helpful to detect early loosening. A rapid development of a continuous radiolucent line of greater than 2 mm or focal osteolysis within the first three years after implantation are very suggestive of an infection but are neither sensitive nor specific enough to distinguish between septic and aseptic failure.<sup>26</sup> Computed tomography (CT) gives good contrast resolution of bone and surrounding soft tissue and can be useful in pre-operative evaluation of excessive bone defects. Magnetic resonance imaging (MRI) displays greater resolution for soft tissue abnormalities than CT. In particular, metal artefact reduction sequence (MARS) MRI is useful for differential diagnosis with metallosis.

Bone scintigraphy with <sup>99m</sup>Tc has an excellent sensitivity, but its specificity to diagnose PJI is low.<sup>27,28</sup> Positive uptake detected by delayed-phase imaging due to increased bone remodelling around the prosthesis is normally present in the first two years after implantation<sup>29</sup> and even later, aseptic loosening cannot be differentiated from infection. The use of anti-granulocyte scintigraphy with <sup>99m</sup>Tc-labelled monoclonal antibodies demonstrates sensitivity of 83% and specificity of 79% to detect PJI.<sup>30</sup> Scintigraphy with Indium-111-labeled leukocytes in combination with marrow imaging shows

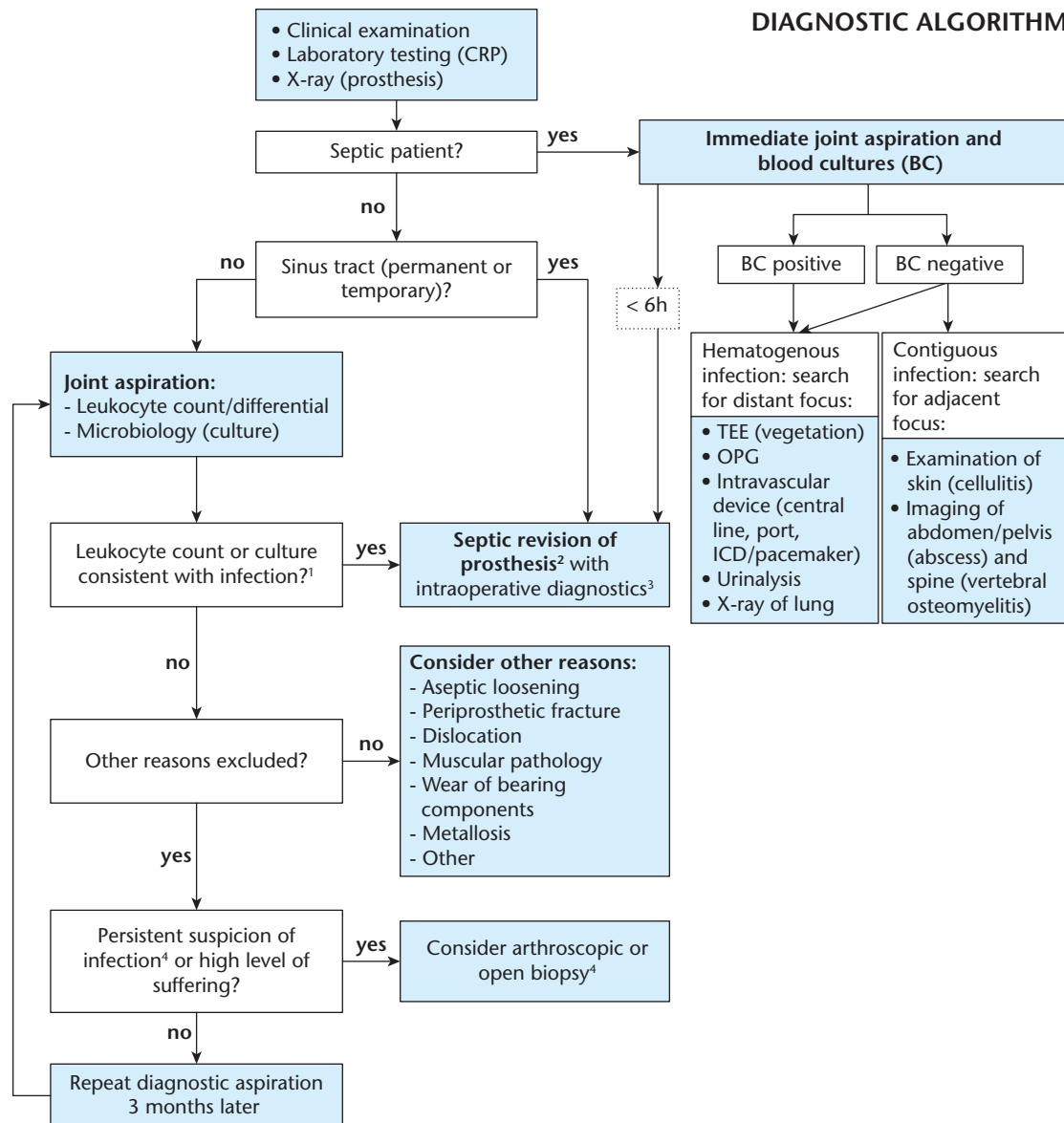
about 90% accuracy for diagnosing PJI. Indium-111-labelled leukocytes do not accumulate in normally healing surgical wounds and preliminary data indicate a comparable accuracy even in the early post-operative period.<sup>31</sup> 18-fluorodeoxyglucose (<sup>18</sup>F-FDG) positron emission tomography (PET) is a fast, safe, high-quality imaging for detection of PJI with reported sensitivity of 82.1% and specificity of 86.6%.<sup>32</sup>

*Laboratory studies*

None of the routine blood tests such as white blood cell count (WBC), erythrocyte sedimentation rate (ESR), C-reactive protein (CRP) or procalcitonin (PCT) have sufficient sensitivity or specificity to diagnose or exclude PJI. In PJI caused by low-virulence pathogens systemic inflammatory markers are often normal.<sup>33–35</sup> CRP is increased after surgery, reflecting post-interventional inflammation. Serial measurements over time are needed for accurate interpretation.<sup>3</sup> ESR is not specific and should no longer be performed as part of the routine laboratory tests.

*Synovial fluid analysis*

Pre-operative joint aspiration is the most valuable diagnostic tool and should be performed for every painful prosthetic joint prior to the surgical revision. Determination of



<sup>1</sup> Leukocyte count: >2000/μl leukocytes or > 70% granulocytes; microbiology: for highly virulent organisms (e.g. *S. aureus*, *E. coli*) already one positive sample confirms infection, for low-virulent organisms (e.g. *S. epidermidis*, *P. acnes*) ≥2 positive samples are required to confirm infection

<sup>2</sup> According to the treatment algorithm for PJI

<sup>3</sup> Leukocyte count/differential, histopathology, microbiology (+/-sonication)

<sup>4</sup> Elevated CRP, risk history (prolonged secretion or revision surgery after primary implantation), early loosening of prosthesis

BC: blood cultures, TEE: transesophageal echocardiography, OPG: orthopantomogram

**Fig. 1** Diagnostic algorithm for PJI. Reproduced with permission from the Pocket Guide to Diagnosis & Treatment of PJI, PRO-IMPLANT Foundation (version 9, October 2019).

Notes. CRP, C-reactive protein.

synovial fluid leukocyte count and percentage of granulocytes represents a simple, rapid and accurate test for differentiating between PJI and aseptic failure. Some recent studies analysing synovial fluid leukocyte count in patients undergoing a revision surgery for susceptible PJI and

using subtle methods of biofilm detection such as sonication showed ideal cut-off at 2000 leukocytes/μl and 70% granulocytes.<sup>36–38</sup>

The sensitivity of synovial fluid culture is 45% to 75% with a specificity of 95%.<sup>38,39</sup> The sensitivity can be

diminished by long transportation time in inadequate transport media. This can be prevented by inoculation of aspirated synovial fluid into paediatric blood culture bottles.<sup>40</sup> An incubation time of 14 days is necessary to detect low-virulent and difficult-to-detect pathogens, such as *Cutibacterium* species.

#### *Alpha defensin*

Alpha defensin is an antimicrobial peptide released by activated neutrophils as a response to bacterial infection that has been used as a biomarker for detection of PJI. The Alpha Defensin Lateral Flow (ADLF) test is a qualitative test that determines the presence of alpha defensin in synovial fluid and can be performed in the operation theatre or immediately after the joint aspiration within 10 minutes. Recent studies comparing different criteria for PJI and determining the sensitivity and specificity of different alpha-defensin tests showed that there was no significant difference in the sensitivity and specificity when using qualitative (ADLF test) and quantitative (enzyme linked immunosorbent assay – ELISA) methods for the detection of alpha defensin in synovial fluid. When using the more sensitive definition criteria for diagnosing PJI, the ADLF test showed a lower sensitivity (54.4%)<sup>23</sup> than previously reported (67% to 77%)<sup>23,41–43</sup> but retained a high specificity of 99.3%.<sup>23,43</sup> Even though this test is, due to its low sensitivity, not suitable for screening, it can still be used as a confirmatory test for a certain group of PJI patients. In the early post-operative period when synovial fluid leukocyte count is not readable (specificity of only 60% in the first six weeks post-operatively), the ADLF test may still be applied with a specificity of 99%.<sup>23,43</sup>

#### *Intra-operative tissue samples*

As a general principal, three to five intra-operative tissue samples should be submitted for the culture. The sensitivity ranges between 65% to 94%.<sup>44–47</sup> It must be noted that sensitivity of intra-operative swabs is low,<sup>48</sup> and that swabs of superficial wounds or sinus tracts can mislead by detecting the colonizing rather than the infecting micro-organisms and should therefore be avoided.

#### *Sonication of removed implants*

Sonication is a method using low-frequency ultrasound waves that pass through a liquid surrounding the prosthesis and detach biofilm micro-organisms from the surface. The sonicate fluid can then be submitted for culture and plated onto aerobic and anaerobic plates. Inoculation in the blood culture bottles improves the sensitivity and may reduce the cultivation time by up to five days.<sup>49</sup> A cut-off of 50 colony-forming units (CFU)/ml of sonication fluid yields a sensitivity of 79% and a specificity of 99% for the diagnosis of PJI.<sup>50</sup> The culture of sonication fluid shows

superior sensitivity compared with the standard culture of the periprosthetic tissue (79% versus 54%),<sup>50–52</sup> and can be especially useful in chronic infections or for patients on previous antimicrobial treatment.

In the operating theatre, the explanted prosthesis must be immediately placed in a sterile, airtight container. Only rigid plastic containers are to be used since transportation in sealable plastic bags relates to high rates of contamination. In acute post-operative infections, sonicating parts of the implants that are covered with antibiotic-loaded bone cement may inhibit bacterial growth and lead to false negative results caused by increased antibiotic elution during sonication.<sup>53</sup>

#### *Molecular methods*

Polymerase chain reaction (PCR) can identify pathogens in synovial fluid with a sensitivity and specificity of 84% and 89%, in sonication fluid of 81% and 96%<sup>54</sup> and also has high sensitivity and specificity in patients on antibiotics.<sup>55</sup> The current limitations of this sensitive technique are its high costs and its susceptibility to contamination leading to false-positive findings.<sup>56</sup>

#### *Histopathological examination*

Histopathology of periprosthetic tissue should be considered a standard procedure in the diagnosis of PJI. Neutrophil granulocytes can be detected through immuno-histochemical techniques and validated using histopathological scores.<sup>57,58</sup> The presence of PJI can be determined by the count of neutrophils per high-power field at a magnification of 400.<sup>59</sup> The definition of acute inflammation has been variable proposed from  $\geq 1$  to  $\geq 10$  neutrophils per high-power field.<sup>39</sup> When using the CD15 focus score, a count of 39 CD15+ neutrophil granulocytes/focal point was identified as the optimum threshold when diagnosing PJI. When compared to microbiological findings, the diagnostic sensitivity of this method is 91%, and the specificity 92%. The exact values can even differentiate between low- and high-virulent pathogens.<sup>60</sup>

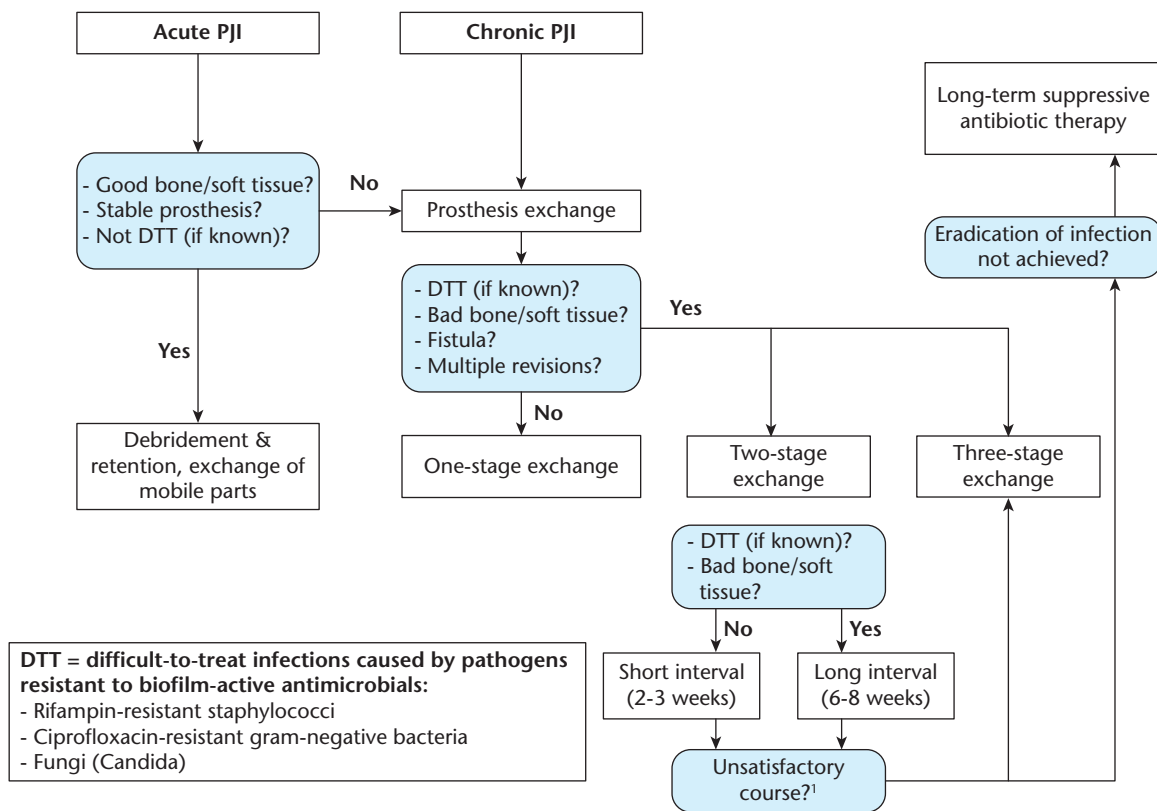
A few years ago, an extended synovial-like interface membrane (SLIM) classification for implant-related diagnosis covering the complete spectrum of histopathology in periprosthetic membrane was introduced. This classification includes: Type I, particle-induced type; Type II, infection type; Type III, combination type; Type IV, indifferent type; Type V, arthrofibrotic type; Type VI, allergic/immunological/toxic adverse reactions; and Type VII, bone pathologies.<sup>61</sup>

## Treatment algorithm

The management of PJI includes surgical treatment based on PJI classification as well as recommendations



## TREATMENT ALGORITHM



<sup>1</sup> Clinical signs of infection, elevated CRP, intra-operative pus, compromised tissue

**Fig. 2** Treatment algorithm for PJI. Reproduced with permission from the Pocket Guide to Diagnosis & Treatment of PJI, PRO-IMPLANT Foundation (version 9, October 2019).

Notes. CRP, C-reactive protein.

for empirical and targeted antimicrobial therapy for various surgical strategies and causative micro-organisms (Fig. 2).<sup>3,62</sup>

### Surgical treatment

In early post-operative infections < 4 weeks or acute haematogenous infections with duration of the symptoms < 3 weeks debridement, antibiotics and implant retention (DAIR) is the treatment of choice. During this procedure radical debridement of all necrotic tissues, synovectomy, excision of sinus tracts and thorough irrigation with copious volumes of sterile saline is performed, combined with replacement of mobile, easily exchangeable prosthetic parts.<sup>63</sup> Arthroscopic debridement and irrigation are not recommended as there the outcome is worse when compared with open surgical revision.<sup>64,65</sup> Its limitations are inability to perform adequate debridement and exchange of the mobile parts of the prosthesis. Not changing the mobile parts during DAIR is associated with high failure rates.<sup>66–69</sup> Local antibiotics can be additionally used during

revision surgery. Antibiotic-loaded polymethylmethacrylate (PMMA) beads, as well as other non-resorbable carriers, become colonized by bacteria due to rapid decrease of local antibiotic concentration, allowing new biofilm formation. Additional surgery for PMMA bead removal is needed. Therefore, bio-absorbable carriers (e.g. calcium sulphate beads or resorbable gentamicin-loaded sponges) are preferred. Methylene blue-guided debridement has been used by many institutions for years and has recently been described in the literature as a staining technique providing good visual control of surgical debridement.<sup>70</sup> The trials qualifying and treating patients with DAIR according to the above described treatment algorithm and using biofilm-active antibiotics show high success rates.<sup>71–76</sup>

In cases with longer duration of symptoms where mature biofilm is present, a complete removal of the prosthesis is necessary. Two-stage revision surgery has for several decades been presumed to be the 'gold standard'.<sup>77</sup> However, with current literature data reporting

**Table 3. Local antimicrobials in bone cement (PMMA) (additionally to systemic antimicrobial treatment)**

Situation	Antimicrobial	Fixation cement (prophylactic dose: per 40 g PMMA cement)	Spacer cement (therapeutic dose: per 40 g PMMA cement)
<b>Standard situation</b>			
• Susceptible or unknown pathogen(s)	Gentamicin + Clindamycin	1 g 1 g	1 g 1 g (+2 g vancomycin)
<b>Special situations</b>			
• <i>Staphylococcus</i> spp. (oxacillin-/methicillin-resistant) or <i>Enterococcus</i> spp.	Gentamicin + Vancomycin or Daptomycin	0.5 g 2 g –	0.5 g 2 g (+2 g <sup>d</sup> ) 2 g
• Vancomycin-resistant enterococci (VRE)	Gentamicin + Linezolid or Daptomycin or Fosfomycin-sodium <sup>a</sup>	0.5 g 1 g 2 g 2 g	0.5–1 g 2 g 3 g 2–4 g
• Resistant gram-negative pathogens (e.g. <i>E. coli</i> , <i>Klebsiella</i> , <i>Enterobacter</i> , <i>Pseudomonas</i> spp.)	Gentamicin + Colistin <sup>b</sup> or Fosfomycin-sodium <sup>a</sup> or Meropenem or Ciprofloxacin	0.5 g 5–10 Mio I.E. 2 g 2 g 2 g	0.5–1 g 10–20 Mio I.E. 2–4 g 3 g <sup>c</sup> 3 g
• Yeasts ( <i>Candida</i> spp.) or molds (e.g. <i>Aspergillus</i> spp.)	Gentamicin + Amphotericin B liposomal (Ambisome <sup>®</sup> ) or Voriconazol	0.5 g 0.2 g <sup>e</sup> 0.2 g	0.5–1 g 0.4 g <sup>d,e</sup> 0.4 g <sup>d</sup>

<sup>a</sup>Fosfomycin-sodium is preferred over fosfomycin-calcium due to better mechanical properties of PMMA. <sup>b</sup>Available as colistin-sodium or colistin-sulfate (equal efficacy). <sup>c</sup>Improved efficacy and antimicrobial release in combination with gentamicin 1 g and clindamycin 1 g. <sup>d</sup>These antimicrobial concentrations do not fulfil the mechanical ISO requirements for fixation cement. <sup>e</sup>Literature regarding the minimal effective concentrations is controversial.

**General considerations:**

- When additional antimicrobials are admixed, industrially impregnated cements are preferred over plain cements (better mechanical properties and elution due to synergistic release).
- Antimicrobial susceptibility testing results are applicable for systemic antimicrobial application and might not be valid for local antimicrobial application due to high local concentrations and synergistic activity.
- Side effects and interactions of local antimicrobials are rare. However, serum concentrations of vancomycin and gentamicin should be monitored in patients with kidney insufficiency and/or intravenous application.
- Only use sterile antimicrobials in powder form. Liquid antimicrobials are not recommended due to inhomogeneous distribution in PMMA. Antibiotics that interfere with the polymerization process (rifampin or metronidazol) or which are thermolabile or sensitive to oxidation (e.g. some beta lactams) should not be used.
- Data on mechanical stability are not available for combinations of more than two antimicrobials. If possible, the total amount of antimicrobials should not exceed 10% of the PMMA powder weight (= 4 g per 40 g).
- Recommendations are based on studies with PALACOS<sup>®</sup>/COPAL<sup>®</sup> PMMA cements and literature data. Elution data depend on the PMMA cement basis used.
- Do not use vacuum mixing for preparation of spacer cement (higher porosity → better antimicrobial elution).

similar re-infection rates after one- and two-stage procedures,<sup>78</sup> two-stage revision can be considered overtreatment for a large number of PJI patients and relates to higher morbidity, longer hospital stays and time of immobilization, worse functional outcome and higher health care costs.<sup>79,80</sup>

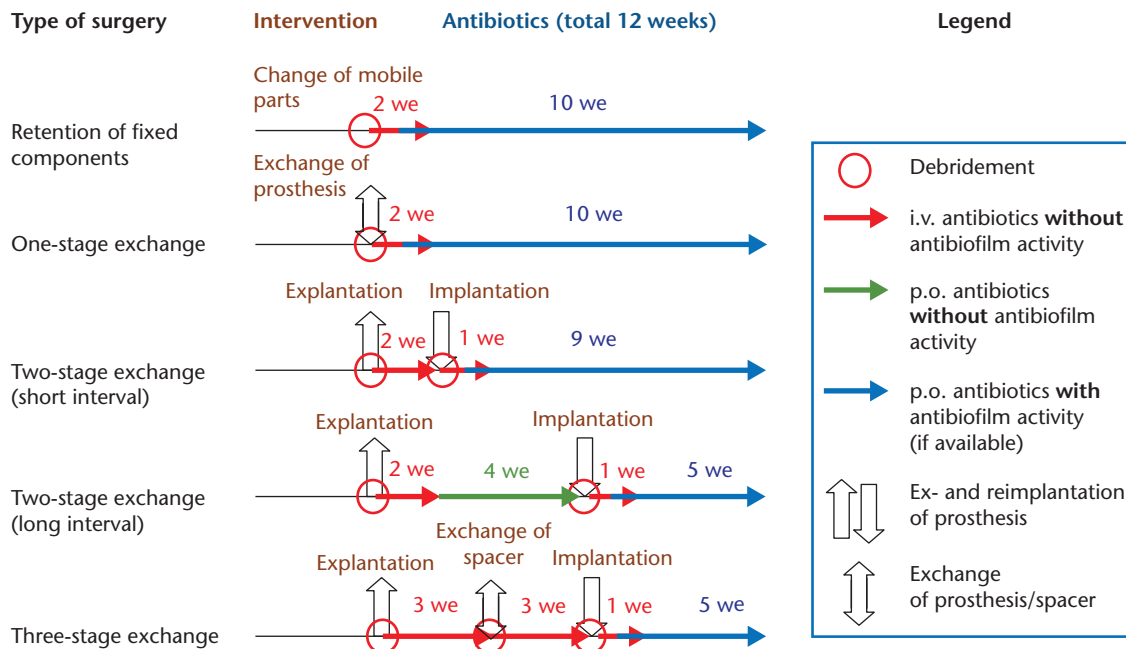
For patients with intact or only slightly compromised bone and soft tissue, lack of previous revision surgeries or treatment with biofilm-active antibiotics (difficult-to-treat micro-organism are unlikely), one-stage exchange is the treatment of choice. In patients with numerous previous revisions or those where the local tissue conditions require time for improvement a two-stage exchange with short interval of two to four weeks can be performed.<sup>3</sup> When a difficult-to-treat (DTT) pathogen is isolated in the first stage, a prolonged interval of four to six weeks allows the application of enhanced antimicrobial treatment in the prosthesis-free interval. Longer intervals (> 8 weeks) should be avoided especially if spacers are in situ, as the antibiotic concentration in bone cement decreases and by this time falls below the minimal inhibitory concentrations. During the prosthesis-free interval, antibiotic-loaded

spacers are used for dead-space management, stability, some degree of mobility and local antibiotic treatment. Not all antibiotics can be manually admixed in the PMMA cement. They must be thermostable and hydrophilic (Table 3).

In some cases, with prolonged wound discharge after the initial debridement and explantation, as well as in cases with persistent signs of infection despite sufficient local and systemic antimicrobial treatment, a multi-stage procedure is required. Additional debridement and exchange of the spacer after two to four weeks can further reduce the microbial load and is recommended in, for example, fungal PJI.

If primary skin closure is impossible due to compromised soft tissue, an early co-operation with plastic surgeons to perform a soft tissue and skin coverage procedure is necessary. Negative-pressure wound therapy is not recommended in PJI as the sponge becomes colonized with micro-organisms within days and is associated with the risk of acquisition of additional micro-organisms, predominantly multidrug resistant gram-negative organisms and *Candida* spp.<sup>81</sup>

## SURGICAL PROCEDURES



**Fig. 3** Overview of surgical procedures for PJI. Reproduced with permission from the Pocket Guide to Diagnosis & Treatment of PJI, PRO-IMPLANT Foundation (version 9, October 2019).

In rare cases where the cure of an infection is not achievable, permanent removal of the prosthesis or creation of an iatrogenic stable sinus tract are applicable. In the latter situation, there is no need for antibiotics as the emergence of resistance is a serious risk.<sup>82</sup> These options are reserved for multimorbid, inoperable patients with no requirement for an intact joint function, but only to suppress the symptoms without curing the underlying infection (Fig. 3).

#### Antimicrobial treatment

Starting empirical, broad-spectrum antimicrobial treatment only after the reduction of bacterial load by surgical debridement and the initial intravenous application improve the treatment effectivity and reduce the development of antimicrobial resistance. De-escalation to targeted therapy should follow as soon as the causative agent is identified. Switch to oral treatment may be performed 14 days after surgery if an oral substance with good bone penetration is available, wounds are dry, local conditions satisfactory and systemic inflammatory markers (e.g. CRP) have returned to normal or almost normal values. For streptococci, potentially longer intravenous therapy is necessary (typically three to four weeks), as oral amoxicillin may not reach sufficient tissue concentrations.

In multistage procedures, the goal during the prosthesis-free interval is maximal reduction (instead of

eradication) of the pathogen, as well as treatment of soft tissue infection and osteomyelitis. Antibiotic treatment is continued seamlessly until the re-implantation. ‘Drug holidays’ and joint aspiration prior to re-implantation are no longer recommended. The biopsies might be false-negative (due to antibiotic treatment) or false-positive (due to contamination). In addition, during the antibiotic-free period bacteria may replicate and cause a relapse after re-implantation.<sup>83</sup> Knowing that the new prosthesis is being implanted into a potentially infected area, the antibiotic treatment is continued after re-implantation for additional 6 weeks (i.e. a total time of 12 weeks after explantation), despite negative intra-operative cultures. If the causative agent grows in the microbiological specimens taken during re-implantation, the antibiotic treatment is extended to 12 weeks from the date of re-implantation (equivalent to one-stage revision).

Several trials<sup>84–86</sup> have shown no negative influence of pre-operative antibiotic prophylaxis on the sensitivity of microbiological biopsies. Especially in cases of exchange of mobile parts, one-stage exchange or re-implantation surgery, antibiotic treatment should be started 30–60 minutes prior to the skin incision or tourniquet closure to protect the new implant from intra-operative colonization.

Long-term antibiotic suppression with implant retention may be considered for multimorbid elderly patients with contraindications for further surgical treatment and



**Table 4. Recommended antimicrobial treatment**

**Empirical antibiotic therapy:**

- Ampicillin/sulbactam 3 x 3 g IV or amoxicillin/clavulanic acid 3 x 1.2 g IV (+/- vancomycin 2 x 1 g IV in septic patients, known MRSA carriers, multiple previous surgeries, suspected low-grade infection)

**Interval/suppressive therapy**

Micro-organism	Antibiotic (according to susceptibility, dose see table below)
<i>Staphylococcus spp.</i>	Cotrimoxazole, doxycyclin, clindamycin
<i>Streptococcus spp.</i>	Amoxicillin, clindamycin, levofloxacin
<i>Enterococcus spp.</i>	Amoxicillin, (linezolid)
Anaerobes (gram-positive)	Clindamycin, amoxicillin, doxycycline
Anaerobes (gram-negative)	Metronidazole, clindamycin
Gram-negative organisms	Ciprofloxacin, cotrimoxazole
Fungi ( <i>Candida spp.</i> )	Fluconazole

**Targeted eradication therapy (de-escalate as soon as the pathogen is known)**

Micro-organism (red: difficult-to-treat)	Antibiotic <sup>a</sup> (check pathogen susceptibility before)	Dose <sup>b</sup>	Route
<b>Staphylococcus spp.</b>			
- Oxacillin-/methicillin-susceptible	Flucloxacillin <sup>c</sup> (+/- Fosfomycin <sup>d</sup> ) for 2 weeks, followed by (according to susceptibility) Rifampin <sup>e</sup> + - Levofloxacin or - Cotrimoxazole or - Doxycyclin or - Fusidic acid	4 x 2 g (3 x 5 g)  2 x 450 mg 2 x 500 mg 3 x 960 mg 2 x 100 mg 3 x 500 mg	IV IV  p.o. p.o. p.o. p.o.
- Oxacillin-/methicillin-resistant	Daptomycin or Vancomycin <sup>f</sup> (+/- Fosfomycin <sup>d</sup> ) for 2 weeks, followed by an oral rifampin combination as above	1 x 8 mg/kg 2 x 1 g (3 x 5 g)	IV IV IV
- Rifampin-resistant	Intravenous treatment according susceptibility for 2 weeks (as above), followed by long-term suppression for ≥ 1 year		
<b>Streptococcus spp.</b>			
	Penicillin G <sup>c</sup> or Ceftriaxon for 2–3 weeks, followed by: Amoxicillin or Levofloxacin (consider suppression for ≥1 year)	4 x 5 million U 1 x 2 g  3 x 1000 mg 2 x 500 mg	IV IV  p.o. p.o.
<b>Enterococcus spp.</b>			
- Penicillin-susceptible	Ampicillin+ Gentamicin <sup>g</sup> (+/- Fosfomycin <sup>d</sup> ) for 2–3 weeks, followed by: Amoxicillin	4 x 2 g 1 x 120 mg (3 x 5 g)  3 x 1000 mg	IV IV IV  p.o.
- Penicillin-resistant	Vancomycin <sup>f</sup> or Daptomycin + Gentamicin <sup>g</sup> (+/- Fosfomycin <sup>d</sup> ) 2–4 weeks, followed by Linezolid (max. 4 weeks)	2 x 1 g 1 x 10 mg/kg  1 x 120 mg (3 x 5 g)  2 x 600 mg	IV IV  IV IV  p.o.
- Vancomycin-resistant (VRE)	Individual; removal of the implant or life-long suppression necessary		

Micro-organism (red: difficult-to-treat)	Antibiotic <sup>a</sup> (check susceptibility before)	Dose <sup>b</sup>	Route
<b>Gram-negative</b>			
- Enterobacteriaceae ( <i>E. coli</i> , <i>Klebsiella</i> , <i>Enterobacter</i> etc.)	Ciprofloxacin <sup>h</sup>	2 x 750 mg	p.o.
- Non-fermenters ( <i>Pseudomonas aeruginosa</i> , <i>Acinetobacter</i> spp.)	Piperacillin/tazobactam or Meropenem or Ceftazidim + Tobramycin (or gentamicin) for 2–3 weeks, followed by: Ciprofloxacin	3 x 4.5 g 3 x 1 g 3 x 2 g 1 x 300 mg 1 x 240 mg  2 x 750 mg	IV IV IV IV IV  p.o.
- Ciprofloxacin-resistant	Depending on susceptibility: meropenem 3 x 1 g, colistin 3 x 3 million U and/or fosfomycin <sup>d</sup> 3 x 5 g IV, followed by oral suppression.		

(continued)

Table 4. (Continued)

Micro-organism (red: difficult-to-treat)	Antibiotic <sup>a</sup> (check susceptibility before)	Dose <sup>b</sup>	Route
<b>Anaerobes</b>			
- Gram-positive ( <i>Cutibacterium</i> , <i>Peptostreptococcus</i> , <i>Fingoldia magna</i> )	Penicillin G <sup>c</sup> or Ceftriaxon for 2 weeks, followed by: Rifampin <sup>e</sup> + - Levofloxacin or - Amoxicillin	4 x 5 million U 1 x 2 g  2 x 450 mg 2 x 500 mg 3 x 1000 mg	IV IV  p.o. p.o. p.o.
- Gram-negative ( <i>Bacteroides</i> , <i>Fusobacterium</i> )	Ampicillin/sulbactam <sup>c</sup> for 2 weeks, followed by Metronidazol	3 x 3 g  3 x 400 mg or 500 mg	IV  p.o.
<b>Candida spp.</b>			
- Fluconazole-susceptible	Caspofungin <sup>i</sup> or Anidulafungin for 1–2 weeks, followed by: Fluconazole (suppression for ≥ 1 year)	1 x 70 mg 1 x 100 mg (1 <sup>st</sup> day: 200 mg)  1 x 400 mg	IV IV  p.o.
- Fluconazole-resistant	Individual (e.g. with voriconazole 2 x 200 mg p.o.); removal of the implant or long-term suppression		
<b>Culture-negative</b>			
	Ampicillin/sulbactam <sup>c</sup> for 2 weeks, followed by: Rifampin <sup>e</sup> + Levofloxacin	3 x 3 g  2 x 450 mg 2 x 500 mg	IV  p.o. p.o.

Notes. IV, intravenously; p.o., per os; MRSA, Methicillin-resistant *Staphylococcus aureus*; CRP, C-reactive protein.

<sup>a</sup>Total duration of therapy: 12 weeks, usually 2 weeks intravenously, followed by oral route. <sup>b</sup>Laboratory testing 2 x weekly: leukocytes, CRP, creatinine/eGFR, liver transaminases. Dose-adjustment according to renal function and body weight (< 40 / > 100 kg). <sup>c</sup>Penicillin allergy of NON-type 1 (e.g. skin rash): ceftazidime (3 x 2 g IV). In case of anaphylaxis (= type 1-allergy such as Quincke's edema, bronchospasm, anaphylactic shock) or cephalosporin allergy: vancomycin (2 x 1 g IV) or daptomycin (1 x 8 mg/kg IV) Ampicillin/sulbactam is equivalent to amoxicillin/clavulanic acid (3 x 2.2 g IV). <sup>d</sup>For fosfomycin the 5 g dosage form is only available in Germany. In all other countries 2, 4 and 8 g dosage forms for IV fosfomycin are available. A daily dosage of 12 to 24 g IV fosfomycin is licensed. <sup>e</sup>Rifampin is administered only after the new prosthesis is implanted. Add it to intravenous treatment as soon as wounds are dry and drains removed; in patients aged > 75 years, rifampin is reduced to 2 x 300 mg p.o. <sup>f</sup>Check Vancomycin through concentration (take blood before next dose) at least 1 x weekly; therapeutic range: 15–20 µg/ml. <sup>g</sup>Give only if gentamicin high-level (HL) is tested susceptible (consult the microbiologist). In gentamicin HL-resistant *E. faecalis* gentamicin is exchanged with ceftriaxone (1 x 2 g IV). <sup>h</sup>Add IV treatment (piperacillin/tazobactam 3 x 4.5 g or ceftriaxon 1 x 2 g or meropenem 3 x 1 g IV) in the first post-operative days (until wound is dry). <sup>i</sup>After a loading dose of 70 mg on day 1, reduce dose to 50 mg in patients weighing < 80 kg from day 2.

in those with technical limitations for limb preservation due to loss of bone and soft tissue. The causative micro-organism(s) must be known and patients must not present radiological signs of implant loosening. Relapses occur in > 80% when antimicrobials are discontinued.<sup>87</sup>

To prevent emergence of rifampin resistance it should never be given as a monotherapy<sup>88</sup> and is always to be combined with another susceptible drug such as quinolones, cotrimoxazole, doxycycline or fusidic acid.<sup>3</sup> Biofilm-active antibiotics must not be used in the presence of spacer but introduced only after the definitive prosthesis is implanted, wounds are dry, and drains are removed (Table 4).

## Outlook

To successfully treat the underlying infection while preserving joint function, PJI management must contain effective patient-adapted diagnosis and treatment based on algorithm and interdisciplinary collaboration.<sup>89</sup> Clinical, laboratory and standard radiological examination have low sensitivity for the diagnosis of PJI. Joint aspiration with determination of synovial fluid leukocyte count and percentage of granulocytes must be performed for every painful, or loose prosthetic joint prior to the revision surgery. Three to five intra-operative

tissue samples harvested close to the implant, including the explanted prosthesis should be submitted for cultivation, histopathology and sonication.

The cornerstone of optimal surgical treatment is a precise debridement with removal of all devitalized material and foreign bodies that contain mature biofilm (> 4 weeks). Standard procedure in acute infection is debridement, irrigation, change of mobile parts and retention of the prosthesis. Outcome of this less invasive procedure is described controversially. However, trials qualifying and treating the patients according to the proposed algorithm show very good outcome. In chronic infections, patients with intact or slightly compromised soft tissue and easy-to-treat micro-organism, a complete exchange of the prosthesis in one stage is the treatment of choice. This procedure is associated with lower morbidity and better functional outcome without significant difference regarding the cure rate when compared to multiple-stage revisions.

The current antimicrobial treatment concept includes 12 weeks of therapy. Addition of biofilm-active antibiotics is necessary for achieving the best possible outcome. To prevent the emergence of antimicrobial resistance, these antibiotics should be used as a targeted treatment and only added after re-implantation of the prosthesis, when post-operative wounds are dry and drains are removed.

Research and development of new diagnostic methods with more accuracy, simplicity, and convenience are required. Pathogen-specific markers in synovial fluid such as D-Lactate (product of bacterial fermentation), are being currently tested for early and quick detection of PJI.<sup>90</sup> Further options to prevent or treat biofilm-related infections include active or passive implant coating, controlled local antibiotic application (such as hydrogels), as well as use of bacteriophages for eradication of bacterial biofilms.

#### AUTHOR INFORMATION

<sup>1</sup>HELIOS Klinik Zerbst/Anhalt, Germany.

<sup>2</sup>Service of Orthopaedics and Traumatology, Lausanne University Hospital, University of Lausanne, Lausanne, Switzerland.

<sup>3</sup>Charité – Universitätsmedizin Berlin, Corporate Member of Universität Berlin, Humboldt-Universität zu Berlin, and Berlin Institute of Health, Center for Musculoskeletal Surgery (CMSC), Berlin, Germany.

Correspondence should be sent to: Andrej Trampuz, Charité – Universitätsmedizin Berlin, Corporate Member of Freie Universität Berlin, Humboldt-Universität zu Berlin, and Berlin Institute of Health, Center for Musculoskeletal Surgery (CMSC), Berlin, Germany.

Email: [andrej.trampuz@charite.de](mailto:andrej.trampuz@charite.de)

#### FUNDING STATEMENT

No benefits in any form have been received or will be received from a commercial party related directly or indirectly to the subject of this article.

#### ICMJE CONFLICT OF INTEREST STATEMENT

OB reports board membership as the incoming president of Swiss Orthopaedics, consultancy for Medacta, Heraeus, Stryker and Orthofix, receiving grants or grants pending from Orthofix, Lima, Medacta and Matthys, payment for lectures including service on speakers bureaus from Lima, Medacta, Orthofix and Stryker, all outside the published work.

AT reports board membership of and a research grant from Heraeus Medical, grants or grants pending from Zimmer Biomet, payment for lectures including service on speakers bureaus from InfectoPharm and providing educational material to PRO-IMPLANT Foundation, all outside the published work.

#### LICENCE

© 2019 The author(s)

This article is distributed under the terms of the Creative Commons Attribution-Non Commercial 4.0 International (CC BY-NC 4.0) licence (<https://creativecommons.org/licenses/by-nc/4.0/>) which permits non-commercial use, reproduction and distribution of the work without further permission provided the original work is attributed.

#### REFERENCES

1. Corvec S, Portillo ME, Pasticci BM, Borens O, Trampuz A. Epidemiology and new developments in the diagnosis of prosthetic joint infection. *Int J Artif Organs* 2012;35:923–934.

2. Kurtz S, Ong K, Lau E, Mowat F, Halpern M. Projections of primary and revision hip and knee arthroplasty in the United States from 2005 to 2030. *J Bone Joint Surg Am* 2007;89:780–785.

3. Zimmerli W, Trampuz A, Ochsner PE. Prosthetic-joint infections. *N Engl J Med* 2004;351:1645–1654.

4. Ong KL, Kurtz SM, Lau E, Bozic KJ, Berry DJ, Parvizi J. Prosthetic joint infection risk after total hip arthroplasty in the Medicare population. *J Arthroplasty* 2009;24:105–109.

5. Karczewski D, Winkler T, Renz N, Trampuz A, Lieb E, Perka C, Müller M. A standardized interdisciplinary algorithm for the treatment of prosthetic joint infections. *Bone Joint J* 2019;101-B(2):132–139.

6. Rakow A, Perka C, Trampuz A, Renz N. Origin and characteristics of haematogenous periprosthetic joint infection. *Clin Microbiol Infect* 2019;25:845–850.

7. Murdoch DR, Roberts SA, Fowler VG Jr, et al. Infection of orthopedic prostheses after *Staphylococcus aureus* bacteremia. *Clin Infect Dis* 2001;32:647–649.

8. Costerton JW, Stewart PS, Greenberg EP. Bacterial biofilms: a common cause of persistent infections. *Science* 1999;284:1318–1322.

9. Zimmerli W, Waldvogel FA, Vaudaux P, Nydegger UE. Pathogenesis of foreign body infection: description and characteristics of an animal model. *J Infect Dis* 1982;146:487–497.

10. Anderl JN, Zahler J, Roe F, Stewart PS. Role of nutrient limitation and stationary-phase existence in *Klebsiella pneumoniae* biofilm resistance to ampicillin and ciprofloxacin. *Antimicrob Agents Chemother* 2003;47:1251–1256.

11. Gbejuade HO, Lovering AM, Webb JC. The role of microbial biofilms in prosthetic joint infections. *Acta Orthop* 2015;86:147–158.

12. Zimmerli W, Lew PD, Waldvogel FA. Pathogenesis of foreign body infection. Evidence for a local granulocyte defect. *J Clin Invest* 1984;73:1191–1200.

13. Kaplan SS, Heine RP, Simmons RL. Defensins impair phagocytic killing by neutrophils in biomaterial-related infection. *Infect Immun* 1999;67:1640–1645.

14. Stewart PS, Costerton JW. Antibiotic resistance of bacteria in biofilms. *Lancet* 2001;358:135–138.

15. Donlan RM. Biofilms: microbial life on surfaces. *Emerg Infect Dis* 2002;8:881–890.

16. Høiby N, Bjarnsholt T, Givskov M, Molin S, Ciofu O. Antibiotic resistance of bacterial biofilms. *Int J Antimicrob Agents* 2010;35:322–332.

17. Molina-Manso D, del Prado G, Ortiz-Pérez A, et al. In vitro susceptibility to antibiotics of staphylococci in biofilms isolated from orthopaedic infections. *Int J Antimicrob Agents* 2013;41:521–523.

18. Moreno MG, Trampuz A, Di Luca M. Synergistic antibiotic activity against planktonic and biofilm-embedded *Streptococcus agalactiae*, *Streptococcus pyogenes* and *Streptococcus oralis*. *J Antimicrob Chemother* 2017;72:3085–3092.

19. Parvizi J, Gehrke T; International Consensus Group on Periprosthetic Joint Infection. Definition of periprosthetic joint infection. *J Arthroplasty* 2014;29:1331.

20. Winkler T, Trampuz A, Hardt S, Janz V, Kleber C, Perka C. Periprosthetic infection after hip arthroplasty. *Orthopade* 2014;43:70–78.

21. Akgün D, Trampuz A, Perka C, Renz N. High failure rates in treatment of streptococcal periprosthetic joint infection: results from a seven-year retrospective cohort study. *Bone Joint J* 2017;99-B:653–659.

22. Akgün D, Perka C, Trampuz A, Renz N. Outcome of hip and knee periprosthetic joint infections caused by pathogens resistant to biofilm-active antibiotics: results from a prospective cohort study. *Arch Orthop Trauma Surg* 2018;138:635–642.

23. **Renz N, Yermak K, Perka C, Trampuz A.** Alpha defensin lateral flow test for diagnosis of periprosthetic joint infection: not a screening but a confirmatory test. *J Bone Joint Surg Am* 2018;100:742–750.
24. **Trampuz A, Steckelberg JM, Osmon DR, Cockerill FR III, Hanssen AD, Patel R.** Advances in the laboratory diagnosis of prosthetic joint infection. *Rev Med Microbiol* 2003;14:1–14.
25. **Karczewski D, Winkler T, Perka C, Müller M.** The preoperative microbial detection is no prerequisite for the indication of septic revision in cases of suspected periprosthetic joint infection. *BioMed Res Int* 2018;2018:1729605.
26. **Tigges S, Stiles RG, Roberson JR.** Appearance of septic hip prostheses on plain radiographs. *AJR Am J Roentgenol* 1994;163:377–380.
27. **Corstens FH, van der Meer JW.** Nuclear medicine's role in infection and inflammation. *Lancet* 1999;354:765–770.
28. **Smith SL, Wastie ML, Forster I.** Radionuclide bone scintigraphy in the detection of significant complications after total knee joint replacement. *Clin Radiol* 2001;56:221–224.
29. **Rosenthal L, Lepanto L, Raymond F.** Radiophosphate uptake in asymptomatic knee arthroplasty. *J Nucl Med* 1987;28:1546–1549.
30. **Xing D, Ma X, Ma J, Wang J, Chen Y, Yang Y.** Use of anti-granulocyte scintigraphy with <sup>99m</sup>Tc-labeled monoclonal antibodies for the diagnosis of periprosthetic infection in patients after total joint arthroplasty: a diagnostic meta-analysis. *PLoS One* 2013;8:e69857.
31. **Palestro CJ, Love C.** Role of nuclear medicine for diagnosing infection of recently implanted lower extremity arthroplasties. *Semin Nucl Med* 2017;47:630–638.
32. **Kwee TC, Kwee RM, Alavi A.** FDG-PET for diagnosing prosthetic joint infection: systematic review and metaanalysis. *Eur J Nucl Med Mol Imaging* 2008;35:2122–2132.
33. **Piper KE, Fernandez-Sampedro M, Steckelberg KE, et al.** C-reactive protein, erythrocyte sedimentation rate and orthopedic implant infection. *PLoS One* 2010;5:e9358.
34. **Dodson CC, Craig EV, Cordasco FA, et al.** Propionibacterium acnes infection after shoulder arthroplasty: a diagnostic challenge. *J Shoulder Elbow Surg* 2010;19:303–307.
35. **Pérez-Prieto D, Portillo ME, Puig-Verdié L, et al.** C-reactive protein may misdiagnose prosthetic joint infections, particularly chronic and low-grade infections. *Int Orthop* 2017;41:1315–1319.
36. **Dinneen A, Guyot A, Clements J, Bradley N.** Synovial fluid white cell and differential count in the diagnosis or exclusion of prosthetic joint infection. *Bone Joint J* 2013;95-B:554–557.
37. **Schinsky MF, Della Valle CJ, Sporer SM, Pappas WG.** Perioperative testing for joint infection in patients undergoing revision total hip arthroplasty. *J Bone Joint Surg Am* 2008;90:1869–1875.
38. **Trampuz A, Hanssen AD, Osmon DR, Mandrekar J, Steckelberg JM, Patel R.** Synovial fluid leukocyte count and differential for the diagnosis of prosthetic knee infection. *Am J Med* 2004;117:556–562.
39. **Tande AJ, Patel R.** Prosthetic joint infection. *Clin Microbiol Rev* 2014;27:302–345.
40. **Hughes JG, Vetter EA, Patel R, et al.** Culture with BACTEC Peds Plus/F bottle compared with conventional methods for detection of bacteria in synovial fluid. *J Clin Microbiol* 2001;39:4468–4471.
41. **Frangiamore SJ, Gajewski ND, Saleh A, Farias-Kovac M, Barsoum WK, Higuera CA.**  $\alpha$ -defensin accuracy to diagnose periprosthetic joint infection—best available test? *J Arthroplasty* 2016;31:456–460.
42. **Kasperek MF, Kasperek M, Boettner F, Faschingbauer M, Hahne J, Dominkus M.** Intraoperative diagnosis of periprosthetic joint infection using a novel alpha-defensin lateral flow assay. *J Arthroplasty* 2016;31:2871–2874.
43. **Sigmund IK, Holinka J, Gamper J, Staats K, Böhler C, Kubista B, Windhager R.** Qualitative  $\alpha$ -defensin test (Synovasure) for the diagnosis of periprosthetic infection in revision total joint arthroplasty. *Bone Joint J* 2017;99-B:66–72.
44. **Pandey R, Berendt AR, Athanasou NA; The OSIRIS Collaborative Study Group.** Oxford Skeletal Infection Research and Intervention Service. Histological and microbiological findings in non-infected and infected revision arthroplasty tissues. *Arch Orthop Trauma Surg* 2000;120:570–574.
45. **Kheir MM, Tan TL, Ackerman CT, Modi R, Foltz C, Parvizi J.** Culturing periprosthetic joint infection: number of samples, growth duration, and organisms. *J Arthroplasty* 2018;33:3531–3536.
46. **Atkins BL, Athanasou N, Deeks JJ, et al; The OSIRIS Collaborative Study Group.** Prospective evaluation of criteria for microbiological diagnosis of prosthetic-joint infection at revision arthroplasty. *J Clin Microbiol* 1998;36:2932–2939.
47. **Spangehl MJ, Masri BA, O'Connell JX, Duncan CP.** Prospective analysis of preoperative and intraoperative investigations for the diagnosis of infection at the sites of two hundred and two revision total hip arthroplasties. *J Bone Joint Surg Am* 1999;81:672–683.
48. **Aggarwal VK, Higuera C, Deirmengian G, Parvizi J, Matthew S.** Austin swab cultures are not as effective as tissue cultures for diagnosis of periprosthetic joint infection. *Clin Orthop Relat Res* 2013;471:3196–3203.
49. **Portillo ME, Salvadó M, Trampuz A, et al.** Improved diagnosis of orthopedic implant-associated infection by inoculation of sonication fluid into blood culture bottles. *J Clin Microbiol* 2015;53:1622–1627.
50. **Trampuz A, Piper KE, Jacobson MJ, et al.** Sonication of removed hip and knee prostheses for diagnosis of infection. *N Engl J Med* 2007;357:654–663.
51. **Puig-Verdié L, Alentorn-Geli E, González-Cuevas A, et al.** Implant sonication increases the diagnostic accuracy of infection in patients with delayed, but not early, orthopaedic implant failure. *Bone Joint J* 2013;95-B:244–249.
52. **Portillo ME, Salvadó M, Alier A, et al.** Advantages of sonication fluid culture for the diagnosis of prosthetic joint infection. *J Infect* 2014;69:35–41.
53. **Kummer A, Tabin UF, Borens O.** Effect of sonication on the elution of antibiotics from polymethyl methacrylate (PMMA). *J Bone Jt Infect* 2017;2:208–212.
54. **Qu X, Zhai Z, Li H, et al.** PCR-based diagnosis of prosthetic joint infection. *J Clin Microbiol* 2013;51:2742–2746.
55. **Portillo ME, Salvadó M, Sorli L, et al.** Multiplex PCR of sonication fluid accurately differentiates between prosthetic joint infection and aseptic failure. *J Infect* 2012;65:541–548.
56. **Achermann Y, Vogt M, Leunig M, Wüst J, Trampuz A.** Improved diagnosis of periprosthetic joint infection by multiplex PCR of sonication fluid from removed implants. *J Clin Microbiol* 2010;48:1208–1214.
57. **Gontarewicz A, Niggemeyer O, Tharun L, Grancicova L, Rütther W, Zustin J.** Morphological study of synovial changes in two-stage reconstructions of the infected hip and knee arthroplasties. *BMJ Open* 2012;2:e001467.
58. **Zmistowski B, Della Valle C, Bauer TW, et al.** Diagnosis of periprosthetic joint infection. *J Orthop Res* 2014;32(S1):S98–S107.
59. **Tsaras G, Maduka-Ezeh A, Inwards CY, et al.** Utility of intraoperative frozen section histopathology in the diagnosis of periprosthetic joint infection: a systematic review and meta-analysis. *J Bone Joint Surg Am* 2012;94:1700–1711.

- 60. Krenn VT, Liebisch M, Kölbel B, et al.** CD15 focus score: infection diagnosis and stratification into low-virulence and high-virulence microbial pathogens in periprosthetic joint infection. *Pathol Res Pract* 2017;213:541–547.
- 61. Krenn V, Morawietz L, Perino G, et al.** Revised histopathological consensus classification of joint implant related pathology. *Pathol Res Pract* 2014;210:779–786.
- 62. Trampuz A, Zimmerli W.** New strategies for the treatment of infections associated with prosthetic joints. *Curr Opin Investig Drugs* 2005;6:185–190.
- 63. Zaruta DA, Qiu B, Liu AY, Ricciardi BF.** Functional outcome of debridement, antibiotics and implant retention in periprosthetic joint infection involving the hip: a case-control study. *Bone Joint J* 2017;99-B:614–622.
- 64. Ilahi OA, Al-Habbal GA, Bocell JR, Tullos HS, Huo MH.** Arthroscopic debridement of acute periprosthetic septic arthritis of the knee. *Arthroscopy* 2005;21:303–306.
- 65. Liu CW, Kuo CL, Chuang SY, et al.** Results of infected total knee arthroplasty treated with arthroscopic debridement and continuous antibiotic irrigation system. *Indian J Orthop* 2013;47:93–97.
- 66. Zaruta DA, Qiu B, Liu AY, Ricciardi BF.** Indications and guidelines for debridement and implant retention for periprosthetic hip and knee infection. *Curr Rev Musculoskelet Med* 2018;11:347–356.
- 67. Tsang SJ, Ting J, Simpson AHRW, Gaston P.** Outcomes following debridement, antibiotics and implant retention in the management of periprosthetic infections of the hip: a review of cohort studies. *Bone Joint J* 2017;99-B:1458–1466.
- 68. Lora-Tamayo J, Murillo O, Iribarren JA, et al; REIPI Group for the Study of Prosthetic Infection.** A large multicenter study of methicillin-susceptible and methicillin-resistant *Staphylococcus aureus* prosthetic joint infections managed with implant retention. *Clin Infect Dis* 2013;56:182–194.
- 69. Choi HR, von Knoch F, Zurakowski D, Nelson SB, Malchau H.** Can implant retention be recommended for treatment of infected TKA? *Clin Orthop Relat Res* 2011;469:961–969.
- 70. Shaw JD, Miller S, Plourde A, Shaw DL, Wustrack R, Hansen EN.** Methylene blue-guided debridement as an intraoperative adjunct for the surgical treatment of periprosthetic joint infection. *J Arthroplasty* 2017;32:3718–3723.
- 71. Grammatopoulos G, Kendrick B, McNally M, et al.** Outcome following debridement, antibiotics, and implant retention in hip periprosthetic joint infection: an 18-year experience. *J Arthroplasty* 2017;32:2248–2255.
- 72. Kunutsor SK, Beswick AD, Whitehouse MR, Wylde V, Blom AW.** Debridement, antibiotics and implant retention for periprosthetic joint infections: a systematic review and meta-analysis of treatment outcomes. *J Infect* 2018;77:479–488.
- 73. Tsang SJ, Ting J, Simpson AHRW, Gaston P.** Outcomes following debridement, antibiotics and implant retention in the management of periprosthetic infections of the hip: a review of cohort studies. *Bone Joint J* 2017;99-B:1458–1466.
- 74. Achermann Y, Stasch P, Preiss S, Lucke K, Vogt M.** Characteristics and treatment outcomes of 69 cases with early prosthetic joint infections of the hip and knee. *Infection* 2014;42:511–519.
- 75. Mellner C, Eisler T, Knutsson B, Mukka S.** Early periprosthetic joint infection and debridement, antibiotics and implant retention in arthroplasty for femoral neck fracture. *Hip Int* 2017;27:349–353.
- 76. Sendi P, Lötscher PO, Kessler B, Graber P, Zimmerli W, Clauss M.** Debridement and implant retention in the management of hip periprosthetic joint infection: outcomes following guided and rapid treatment at a single centre. *Bone Joint J* 2017;99-B:330–336.
- 77. Matthews PC, Berendt AR, McNally MA, Byren I.** Diagnosis and management of prosthetic joint infection. *BMJ* 2009;338:b1773.
- 78. Beswick AD, Elvers KT, Smith AJ, Goberman-Hill R, Lovering A, Blom AW.** What is the evidence base to guide surgical treatment of infected hip prostheses? systematic review of longitudinal studies in unselected patients. *BMC Med* 2012;10:18.
- 79. Klouche S, Sariali E, Mamoudy P.** Total hip arthroplasty revision due to infection: a cost analysis approach. *Orthop Traumatol Surg Res* 2010;96:124–132.
- 80. Matthews PC, Berendt AR, McNally MA, Byren I.** Diagnosis and management of prosthetic joint infection. *BMJ* 2009;338:b1773.
- 81. Yusuf E, Jordan X, Clauss M, et al.** High bacterial load in negative pressure wound therapy (NPWT) foams used in the treatment of chronic wounds. *Wound Repair Regen* 2013;21:677–681.
- 82. Trampuz A, Zimmerli W.** Prosthetic joint infections: update in diagnosis and treatment. *Swiss Med Wkly* 2005;135:243–251.
- 83. Tan TL, Kheir MM, Rondon AJ, et al.** Determining the role and duration of the ‘antibiotic holiday’ period in periprosthetic joint infection. *J Arthroplasty* 2018;33:2976–2980.
- 84. Hansen E, Tetreault M, Zmistowski B, et al.** Outcome of one-stage cementless exchange for acute postoperative periprosthetic hip infection. *Clin Orthop Relat Res* 2013;471:3214–3222.
- 85. Burnett RS, Aggarwal A, Givens SA, McClure JT, Morgan PM, Barrack RL.** Prophylactic antibiotics do not affect cultures in the treatment of an infected TKA: a prospective trial. *Clin Orthop Relat Res* 2010;468:127–134.
- 86. Bedenčič K, Kavčič M, Faganeli N, et al.** Does preoperative antimicrobial prophylaxis influence the diagnostic potential of periprosthetic tissues in hip or knee infections? *Clin Orthop Relat Res* 2016;474:258–264.
- 87. Della Valle C, Parvizi J, Bauer TW, et al; American Academy of Orthopaedic Surgeons.** American Academy of Orthopaedic Surgeons clinical practice guideline on the diagnosis of periprosthetic joint infections of the hip and knee. *J Bone Joint Surg Am* 2011;93:1355–1357.
- 88. Achermann Y, Eigenmann K, Ledergerber B, et al.** Factors associated with rifampin resistance in staphylococcal periprosthetic joint infections (PJI): a matched case-control study. *Infection* 2013;41:431–437.
- 89. Li C, Renz N, Trampuz A.** Management of Periprosthetic Joint Infection. *Hip Pelvis* 2018;30:138–146.
- 90. Yermak K, Karbysheva S, Perka C, Trampuz A, Renz N.** Performance of synovial fluid D-lactate for the diagnosis of periprosthetic joint infection: A prospective observational study. *J Infect* 2019;79:123–129.