

Primary Invasive Aspergillosis of the Digestive Tract: Report of Two Cases and Review of the Literature

P. Eggimann, J.-C. Chevrolet, M. Starobinski, P. Majno, M. Totsch, B. Chapuis, D. Pittet

Abstract

Background: Disseminated aspergillosis is thought to occur as a result of vascular invasion from the lungs with subsequent bloodstream dissemination, and portals of entry other than sinuses and/or the respiratory tract remain speculative.

Methods: We report two cases of primary aspergillosis in the digestive tract and present a detailed review of eight of the 23 previously-published cases for which detailed data are available.

Results and Conclusion: These ten cases presented with symptoms suggestive of typhlitis, with further peritonitis requiring laparotomy and small bowel segmental resection. All cases were characterized by the absence of pulmonary disease at the time of histologically-confirmed gastrointestinal involvement with vascular invasion by branched *Aspergillus* hyphae. These cases suggest that the digestive tract may represent a portal of entry for *Aspergillus* species in immunocompromised patients.

Infection 2006; 34: 333–338
DOI 10.1007/s15010-006-5660-0

Introduction

Aspergillus spores are ubiquitous, and once aerosolized, they may colonize the airways and related structures, such as the nose and facial sinuses [1]. Further immunosuppression, such as severe and prolonged neutropenia, markedly increases the risk for invasive disease characterized by tissue invasion and secondary bloodstream dissemination [1]. *Aspergillus fumigatus*, *Aspergillus flavus* and *Aspergillus niger* are responsible for the majority of invasive diseases [2–4]. Invasive aspergillosis is reported to occur in fewer than 1% of patients infected by human immunodeficiency virus (HIV), in 1–5% of liver transplant recipients, in 3–7% of allogeneic bone marrow transplant recipients, but in up to 10% of patients with hematological malignancies or lung transplants, and as high as 14% of heart transplant recipients [2–7].

Invasive pulmonary aspergillosis accounts for 90–98% of invasive infections. Extra-pulmonary aspergillosis may be present in 25–60% of cases and is almost universally described in the context of disseminated diseases [2, 8–15].

Although rarely documented before autopsy, these conditions usually result from bloodstream dissemination secondary to vascular invasion at the primary site of infection [16]. Isolated extra-pulmonary aspergillosis located in the central nervous system, the skin, the liver, the urinary tract and the digestive tract has only been mentioned in case reports, but potential portals of entry other than the respiratory tract are speculative [2, 3, 17]. We report two cases of primary invasive aspergillosis of the digestive tract and review the literature on *Aspergillus* spp. gastrointestinal involvement.

Methods

Our objective was to identify lower digestive tract involvement reported in series of invasive aspergillosis and secondly, to identify previously-published cases with a possible diagnosis of aspergillosis at this site. We searched the English-language literature from 1960 to 2005, December, for reports of aspergillosis with digestive tract involvement through an electronic search of the MEDLINE (National Library of Medicine, Bethesda, MD, USA) database using key words “aspergillosis”, “invasive aspergillosis”, “disseminated disease”, “extra-pulmonary aspergillosis” and “digestive tract aspergillosis” and the reference lists of retrieved articles, including reviews. Cases were included if the diagnosis of primary invasive aspergillosis of the bowel was defined as histologic evidence of *Aspergillus* hyphae in a segment of the bowel biopsy with mucosal alteration and tissue destruction and/or tissue invasion

P. Eggimann (corresponding author)

Dept. of Intensive Care Medicine and Burn Center, Centre Hospitalier Universitaire Vaudois, Bugnon 46, CH -1011 Lausanne, Switzerland;
Phone: (+41/21) 314-2923, Fax: -3045, e-mail: philippe.eggimann@chuv.ch

P. Eggimann, J.-C. Chevrolet

Division of Medical Intensive Care, Dept. of Internal Medicine, University of Geneva Hospitals, Geneva, Switzerland

P. Eggimann, D. Pittet

Infection Control Program, Dept. of Internal Medicine, University of Geneva Hospitals, Geneva, Switzerland

M. Starobinski, B. Chapuis

Division of Oncology and Hematology, Dept. of Internal Medicine, University of Geneva Hospitals, Geneva, Switzerland

P. Majno

Division of Digestive and General Surgery, Dept. of Surgery, University of Geneva Hospitals, Geneva, Switzerland

M. Totsch

Division of Clinical Pathology, Dept. of Pathology, University of Geneva Hospitals, Geneva, Switzerland

Received: November 20, 2005 • Revision accepted: June 29, 2006

with microvascular involvement. Cases with isolated involvement of the upper digestive tract were excluded.

Case Reports

Case 1

A 65-year-old man presented with septic shock attributed to *Proteus vulgaris* primary bacteremia without clinical focus of infection. It occurred on day 6 after admission for transformation of a myelodysplastic syndrome into acute myeloid leukemia for which he received high-dose cytarabine with idarubicin as induction therapy. He responded to empirical broad spectrum antibiotics within 48 h. Fever recurred on day 10 with abdominal pain, and septic shock developed the following day. On day 12, emergency laparotomy showed a necrotic mass of the jejunum which was resected. Direct histologic examination showed branched hyphae with transmural involvement and vascular invasion. After transient improvement for 48 h, multiple organ failure developed. Macroscopic *Aspergillus* colonies appeared on the surgical stomach at day 14 and the patient died on day 16 despite intensive support and amphotericin B therapy. Autopsy showed disseminated aspergillosis with several new segmental necroses of the small bowel and multiple emboli of fungal material in several organs including the lungs. A detailed examination of the lungs did not show any consolidated aera. *A. fumigatus* was isolated from peroperative and autopsy cultures.

Case 2

A 52-year-old man presented with septic shock due to *Pseudomonas aeruginosa* primary bacteremia without clinical focus of infection. The symptoms occurred on day 14 after admission for transformation of a myelodysplastic syndrome into acute myelocytic leukemia for which he received high-dose cytarabine with idarubicin as induction therapy. He responded to empirical broad spectrum antibiotics within 48 h. Fever relapsed on day 25 with abdominal pain. A CT scan excluded lung infiltrates and confirmed the diagnostic of typhlitis. On day 30, a laparotomy performed for acute peritonitis revealed four masses in the ileon. Histology showed branched hyphae (*A. fumigatus* by culture) with transmural involvement and vascular invasion (Figure 1). A second CT scan excluded lung involvement. Therapy with amphotericin B (2 g over 28 days) was initiated and the patient made a full recovery on day 45. Two months later he died from hemorrhage during induction therapy for autologous bone marrow transplantation. Autopsy showed no recurrence of aspergillosis.

Results

Of 23 cases of possible primary invasive aspergillosis of the digestive tract identified in the literature [5, 12–14, 18–22], details were available for only eight of them [23–30] (Table 1).

Nine of ten patients presented with acute hematologic malignancy, and eight received high-dose cytarabine known to be associated with diffuse mucositis. Six presented a prior episode of bacteremia during neutropenia. All ten received a combination of antibiotics with broad spectrum coverage within the 2 weeks before the onset of the abdominal complication, and all presented with abdominal symptoms suggestive of typhlitis, with digestive hemorrhage in three. Laparotomy was performed for acute peritonitis and showed transmural necrosis of the

small bowel requiring segmental resection in all cases. Histology consisted in multiple lesions from superficial ulceration to transmural necrosis and vascular thrombosis with tissue invasion by branched hyphae of *Aspergillus* spp. were present in all cases (Figure 1). All cases were characterized by the absence of pulmonary disease at time of histologically-confirmed digestive aspergillosis. Serology and antigenemia was either not available or not performed in all but one cases and death occurred in six of ten patients (60%).

Of 155 clinical studies retrieved from our review of the literature, 25 included more than 25 cases of invasive aspergillosis in non-HIV infected adult patients with details on the distribution of organs involved (Table 2). There were 6 autopsy series [11–13, 18, 31, 32], 11 retrospective series [5, 14, 15, 19, 33–39] and 8 prospective series [20–22, 40–44].

The proportion of cases with a definite diagnosis was 100% in autopsy series and 73% (60–92%) and 65% (31–88%) in retrospective, and prospective series, respectively. The number of cases where the diagnosis was made before death increased from 23% (14–56%) in autopsy series, 76% (28–100%) in retrospective and 99.9% (99–100%) in prospective series. Mortality averaged 60% (27–88%) in retrospective and 47% (32–64%) in prospective series. This may indicate that patients included in prospective studies were less critically ill, or may have benefited from early presumptive antifungal therapy. Case-fatality rate was recently confirmed to be highest in bone marrow transplant recipients (87%) and among patients with central nervous system involvement (88%) [45]. A large number of patients with solid organ transplant may have contributed to the higher survival rate reported in prospective series.

Invasive pulmonary aspergillosis accounted for a majority of cases. Bowel involvement during disseminated disease was not reported in prospective series and in only 2% of cases in retrospective series (0–28%). However, it was reported in 17% (2–53%) of cases included in the

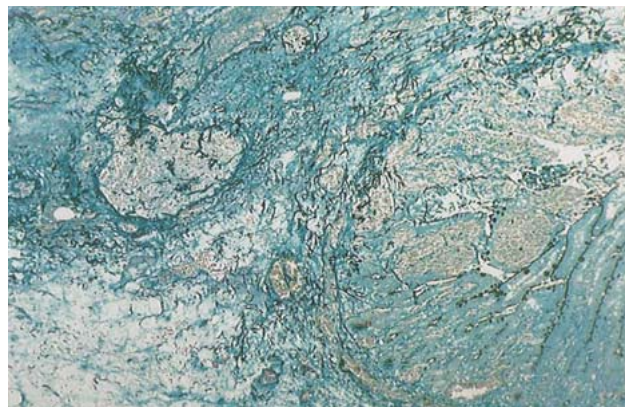


Figure 1. Giemsa-Silver coloration (original magnification, $\times 200$). Diffuse hemorrhagic necrosis surrounding an ulceration of the wall of a surgically-resected segment of jejunum with loss of the architectural organization of the layers. Vascular occlusion by branched *A. fumigatus* hyphae (black structures).

Table 1
Selected characteristics of ten patients with primary digestive invasive aspergillosis.

	Case report 1	Case report 2	Case 37-1976 [23]	Weingard [24]	Cohen [25]	Marterre [26]	Catalano [27]	Shah [28]	Sousa [29]	Trésallet [30]
Age (years)	63	52	4 weeks	38	33	8	58	68	21	57
Underlying disease	AML	AML	AML	ALL	AML	AML	AML	AML	Aplastic anemia	Lymphoma
Documentation	Histology + culture	Histology + culture	Histology + culture	Histology + culture	Histology + culture	Histology + culture	Histology + culture	Histology + culture	Histology + culture	Histology + culture
Previous infection	Bacteremia	Bacteremia	Bacteremia	Bacteremia	Fever of unknown origin	Bacteremia	Fever of unknown origin	Suspected line infection	Fever of unknown origin	Fever of unknown origin
Microorganisms	<i>Proteus vulgaris</i>	<i>Pseudomonas aeruginosa</i>	<i>Staphylococcus aureus</i>	<i>Klebsiella oxytoca</i> ; <i>Enterococcus faecalis</i>	-	<i>Pseudomonas aeruginosa</i>	-	-	-	-
Chemotherapy	Cytarabine, idarubicin	Cytarabine, idarubicin	Cytarabine, daunorubicin	Cytarabine, adriamycin	Cytarabine, daunorubicin	Vincristin	Cytarabine, daunorubicin	Cytarabine, idarubicin	Cyclosporin A	Cytarabine, etoposide
Days after chemotherapy	13	14	8 (second cycle)	19 (second cycle)	24	23	15	11	28	Not specified (induction)
Neutropenia at diagnosis	Yes	Yes	Yes	Yes	Yes	No	Yes	Yes	Yes	Yes
Antifungal prophylaxis	No	No	No	Not specified	Not specified	Not specified	Yes	Not specified	Not specified	Not specified
Number of previous antibiotics	3	3	3	2	5	3	Several	4	Several	3
Antimicrobial agents	Ciprofloxacin, gentamicin, metronidazole	Meropenem, amikacin, teicoplanin	Carbencillin, gentamicin, oxacillin	Ceftazidime, amikacin	Ceftazidime, amikacin	Ceftazidime, tobramycin, ticarcillin	Not specified	Cefepime, metronidazole, gentamicin, vancomycin	Not specified	Imipenem, gentamicin, metronidazole
Prior exposure to amphotericin B	No	Yes	No	No	Yes	No	No	No	No	No
Clinical presentation	Relapsing fever, ileus, peritonitis	Relapsing fever, ileus, bloody diarrhea, peritonitis	Relapsing fever, peritonitis	Relapsing fever, ileus, bloody diarrhea, peritonitis	Relapsing fever, watery diarrhea, peritonitis	Relapsing fever, ileus, peritonitis	Relapsing fever, digestive hemorrhage, peritonitis	Persisting fever, peritonitis	Persisting fever, peritonitis	Persisting fever, peritonitis
Serology	-	-	-	-	-	-	-	-	-	-
Antigenemia	-	-	-	-	-	-	-	-	-	6.2 ng/ml (ELISA) No
Secondary dissemination	Lung	No	Lung, liver	Lung	Lung, liver	No	Not specified	Not specified	Not specified	No
No. of surgical interventions	1	2	1	1	2	5	1	1	1	1
Days after chemotherapy	12	13	8	19	24	23	15	14	28	Not specified
Bowel excision	Yes	Yes	Yes	Yes	Yes	Yes	Yes	Yes	Yes	Yes
Antifungal treatment	Amphotericin B	Amphotericin B	-	-	-	-	Not specified	Not specified	Not specified	Voriconazole
Outcome at 28 days	Death	Survival	Death	Survival	Death	Survival	Death	Death	Death	Survival

AML: acute myeloid leukemia; ALL: acute lymphoid leukemia

autopsy series. Apart from 14 cases for which no details were available, invasion of the digestive tract was always reported in the context of disseminated disease [11–14, 18, 20, 21, 34, 40, 46]. A mixed infection with *Candida* species was reported in series where more details were available [12, 47]. A digestive hemorrhage was reported in most cases, but was not considered specific.

Comment

Invasive aspergillosis is almost exclusively considered as a pulmonary disease with secondary hematogenous dissemination [1, 5]. Fungal infections of the small and large

intestine are rare [47]. However, *Aspergillus* spores are not only inhaled but also ingested, and isolated aspergillosis of the upper digestive tract has been described [48]. In two reviews covering more than 3,000 cases collected from several hundreds of articles over three decades, Denning suggested that, although never demonstrated, the gastrointestinal tract may be considered as a potential portal of entry for *Aspergillus* spp. [2, 3].

In contrast to *Candida* spp., *Aspergillus* spores may not survive or meet favorable conditions to develop on the mucosal surfaces of the digestive tract. However, large ulcers, such as those described as occurring after high-

Table 2
Invasive aspergillosis: organ distribution and mortality; 1960–2005. Studies including more than 25 adult patients.

Type of study Authors	N	Mortality	Organ distribution				
			Lung	Disseminated	CNS	Digestive	Primary digestive
<i>Autopsy</i>							
Young et al. [12]	98	100%	92 (94%)	34 (35%)	13 (13%)	21 (21%)	3 (3%)
Meyer et al. [13]	93	100%	90 (98%)	23 (35%)	9 (10%)	9 (10%)	1 (1%)
Boon et al. [11]	32	100%	32 (100%)	20 (63%)	16 (50%)	15 (53%)	0
Vogeser et al. [18]	27	100%	23 (85%)	16 (59%)	12 (44%)	7 (26%)	1 (4%)
Vogeser et al. [31]	48	100%	41 (85%)	28 (58%)	21 (44%)	1 (2%)	0
Hori et al. [56]	107	100%	105 (98%)	52 (52%)	22 (21%)	12 (11%)	0
Total	405	100%	383 (95%)	176 (43%)	93 (23%)	67 (17%)	5 (1%)
<i>Retrospective</i>							
Fisher et al. [14]	91	88%	83 (91%)	20 (22%)	13 (14%)	5 (5%)	1 (1%)
Albelda et al. [15]	26	62%	26 (100%)	NS	NS	NS	NS
Morrison et al. [5]	93	62%	87 (95%)	43 (47%)	21 (23%)	NS	1 (1%)
Horvath and Dummer [33]	69	52%	49 (71%)	NS	NS	NS	NS
Janssen et al. [34]	25	92%	25 (100%)	8 (32%)	3 (12%)	4 (28%)	0
Caillot et al. [35]	37	27%	37 (100%)	8 (22%)	0	0	0
Kaiser et al. [36]	35	97%	33 (94%)	8 (23%)	1 (3%)	0	0
Abbasi et al. [37]	66	85%	46 (70%)	23 (35%)	9 (14%)	0	0
Lortholary et al. [38]	31	45%	28 (90%)	7 (23%)	4 (13%)	0	0
Nosari et al. [39]	61	48%	56 (92%)	20 (33%)	5 (8%)	0	0
Pagano et al. [19]	391	51%	332 (85%)	NS	37 (9%)	9 (2%)	4 (1%)
Total	925	60%	802 (87%)	137/438 (31%)	92/829 (11%)	18/737 (2%)	6/829 (0.7%)
		555/925					
<i>Prospective</i>							
Ringden et al. [40]	32	34%	29 (91%)	NS	NS	0	NS
Denning et al. [20]	76	32%	51 (67%)	NS	8 (11%)	NS	1 (1.3%)
Stevens et al. [21]	125	34%	90 (72%)	24 (19%)	8 (6%)	0	1 (0.8%)
Denning et al. [22]	123	64%	106 (87%)	33 (27%)	10 (8%)	0	1 (0.8%)
Patterson et al. [41]	595	51%	330 (56%)	148 (25%)	34 (6%)	NS	NS
Denning et al. [42]	116	58%	81 (70%)	6 (5%)	19 (16%)	0	0
Bowden et al. [44]	174	53%	107 (62%)	NS	12 (7%)	NS	NS
Herbrecht et al. [43]	277	35%	240 (87%)	15 (5%)	10 (4%)	NS	NS
Total	1,518	47%	1,034 (64%)	226/1,236 (18%)	101/1,486 (7%)	0/396 (0%)	3/440 (0.7%)
		716/1518					
<i>All studies</i>	2,848	59%	2,219 (78%)	539/2,079 (26%)	296/2,720 (11%)	85/1,538 (5.5%)	14/1,674 (0.8%)
		1676/2848					

NS: not specified

dose cytarabine-related mucositis, may be colonized by *Aspergillus* spores [48]. This may also be the case for patients developing a neutropenic or necrotizing enterocolitis, also referred to as typhilitis. This defines an abdominal complication occurring in neutropenia and induced by chemotherapy [49]. It complicates 5–30% of treatments, including those with high-dose cytarabine, with variable clinical manifestations ranging from mild gastrointestinal symptoms to life-threatening intestinal necrosis with perforation and secondary peritonitis [50, 51]. The latter condition mandates a surgical approach and has been associated with mortality rates of over 50% [52, 53]. Although not specific, abdominal CT scan may be suggestive. The eventual value of *Aspergillus* serology and antigenemia has not been studied in this context. Diffuse dilatation with edema of the bowel walls, predominantly located in the caecum, with some degree of hemorrhage and necrosis are common pathological findings [54]. As described in the ten above-mentioned cases, bowel necrosis is associated with the invasion of a poorly vascularized wall by gram-negative bacilli and yeast after breakdown of the normal flora [52, 55].

In conclusion, we report two cases of possible primary digestive aspergillosis. These two cases and the eight previously published suggest that the digestive tract may represent a portal of entry for *Aspergillus* species in immunocompromised patients.

Acknowledgments

The authors are indebted to the team of the Medical Intensive Care Unit, and the members of the Bone Marrow Transplant Unit, University of Geneva Hospitals. We thank also Rosemary Sudan for providing editorial assistance.

References

- Bartlett JG: Aspergillosis update. *Medicine (Baltimore)* 2000; 79: 281–302.
- Denning DW, Stevens DA: Antifungal and surgical treatment of invasive aspergillosis: review of 2,121 published cases. *Rev Infect Dis* 1990; 12: 1147–1201.
- Denning DW: Therapeutic outcome in invasive aspergillosis. *Clin Infect Dis* 1996; 23: 608–615.
- Marr KA, Patterson T, Denning D: Aspergillosis. Pathogenesis, clinical manifestations, and therapy. *Infect Dis Clin North Am* 2002; 16: 875–894.
- Morrison VA, Haake RJ, Weisdorf DJ: The spectrum of non-candida fungal infections following bone marrow transplantation. *Medicine (Baltimore)* 1993; 72: 78–89.
- Cahill BC, Hibbs JR, Savic K, Juni BA, Dosland BM, Edin-Stibbe C, Hertz MI: *Aspergillus* airway colonization and invasive disease after lung transplantation. *Chest* 1997; 112: 1160–1164.
- Libanore M, Prini E, Mazzetti M, Barchi E, Raise E, Gritti FM, Bonazzi L, Ghinelli F: Invasive Aspergillosis in Italian AIDS patients. *Infection* 2002; 30: 341–345.
- Wiley JM, Smith N, Leventhal BG, Graham ML, Strauss LC, Hurwitz CA, Modlin J, Mellits D, Baumgardner R, Corden BJ: Invasive fungal disease in pediatric acute leukemia patients with fever and neutropenia during induction chemotherapy: a multivariate analysis of risk factors. *J Clin Oncol* 1990; 8: 280–286.
- Winston DJ, Chandrasekar PH, Lazarus HM, Goodman JL, Silber JL, Horowitz H, Shadduck RK, Rosenfeld CS, Ho WG, Islam MZ: Fluconazole prophylaxis of fungal infections in patients with acute leukemia. Results of a randomized placebo-controlled, double-blind, multicenter trial. *Ann Intern Med* 1993; 118: 495–503.
- Goodman JL, Winston DJ, Greenfield RA, Chandrasekar PH, Fox B, Kaizer H, Shadduck RK, Shea TC, Stiff P, Friedman DJ: A controlled trial of fluconazole to prevent fungal infections in patients undergoing bone marrow transplantation. *N Engl J Med* 1992; 326: 845–851.
- Boon AP, O'Brien D, Adams DH: 10 year review of invasive aspergillosis detected at necropsy. *J Clin Pathol* 1991; 44: 452–454.
- Young RC, Bennett JE, Vogel CL, Carbone PP, De Vita VT: Aspergillosis. The spectrum of the disease in 98 patients. *Medicine (Baltimore)* 1970; 49: 147–173.
- Meyer RD, Young LS, Armstrong D, Yu B: Aspergillosis complicating neoplastic disease. *Am J Med* 1973; 54: 6–15.
- Fisher BD, Armstrong D, Yu B, Gold JW: Invasive aspergillosis. Progress in early diagnosis and treatment. *Am J Med* 1981; 71: 571–577.
- Albelda SM, Talbot GH, Gerson SL, Miller WT, Cassileth PA: Pulmonary cavitation and massive hemoptysis in invasive pulmonary aspergillosis. Influence of bone marrow recovery in patients with acute leukemia. *Am Rev Respir Dis* 1985; 131: 115–120.
- Duthie R, Denning DW: *Aspergillus* fungemia: report of two cases and review. *Clin Infect Dis* 1995; 20: 598–605.
- Ludwig M, Schneider H, Lohmeyer J, Ermert L, Sziegoleit A, Lommel D, Weidner W: Systemic aspergillosis with predominant genitourinary manifestations in an immunocompetent man: what we can learn from a disastrous follow-up. *Infection* 2005; 33: 90–92.
- Vogeser M, Haas A, Aust D, Ruckdeschel G: Postmortem analysis of invasive aspergillosis in a tertiary care hospital. *Eur J Clin Microbiol Infect Dis* 1997; 16: 1–6.
- Pagano L, Girmenia C, Mele L, Ricci P, Tosti ME, Nosari A, Buelli M, Picardi M, Allione B, Corvatta L, D'Antonio D, Montillo M, Melillo L, Chierichini A, Cenacchi A, Tonso A, Cudillo L, Candoni A, Savignano C, Bonini A, Martino P, Del Favero A: Infections caused by filamentous fungi in patients with hematologic malignancies. A report of 391 cases by GIMEMA Infection Program. *Haematologica* 2001; 86: 862–870.
- Denning DW, Lee JY, Hostetler JS, Pappas P, Kauffman CA, Dewnup DH, Galgiani JN, Graybill JR, Sugar AM, Catanzaro A: NIAID mycoses study group multicenter trial of oral itraconazole therapy for invasive aspergillosis. *Am J Med* 1994; 97: 135–144.
- Stevens DA, Lee JY: Analysis of compassionate use itraconazole therapy for invasive aspergillosis by the NIAID mycoses study group criteria. *Arch Intern Med* 1997; 157: 1857–1862.
- Denning DW, Marinus A, Cohen J, Spence D, Herbrecht R, Pagano L, Kibbler C, Krcmery V, Offner F, Cordonnier C, Jehn U, Ellis M, Collette L, Sylvester R: An EORTC multicentre prospective survey of invasive aspergillosis in haematological patients: diagnosis and therapeutic outcome. EORTC Invasive Fungal Infections Cooperative Group. *J Infect* 1998; 37: 173–180.
- Case records of the Massachusetts general hospital. Weekly clinicopathological exercises. Case 37-1976. *N Engl J Med* 1976; 295: 608–614.
- Weingrad DN, Knapper WH, Gold J, Mertelsmann R: *Aspergillus* peritonitis complicating perforated appendicitis in adult acute leukemia. *J Surg Oncol* 1982; 19: 5–8.

25. Cohen R, Heffner JE: Bowel infarction as the initial manifestation of disseminated aspergillosis. *Chest* 1992; 101: 877–879.
26. Marterre WF Jr, Mong AT, Pulito AR: Locally invasive aspergillosis of the bowel. *J Pediatr Surg* 1992; 27: 1611–1613.
27. Catalano L, Picardi M, Anzivino D, Insabato L, Notaro R, Rotoli B: Small bowel infarction by aspergillus. *Haematologica* 1997; 82: 182–183.
28. Shah SS, Birnbaum BA, Jacobs JE: Disseminated aspergillosis inciting intestinal ischaemia and obstruction. *Br J Radiol* 2001; 74: 1145–1147.
29. Sousa AB, Ferreira G, Veiga J, Carvalho A: Clinical picture: bowel infarction due to aspergillosis. *Lancet* 2002; 359: 210.
30. Tresallet C, Nguyen-Thanh Q, Aubriot-Lorton MH, Spence D, Herbrecht R, Pagano L, Kibbler C, Kcrrmery V, Offner F, Cordonnier C, Jehn U, Ellis M, Collette L, Sylvester R: Small-bowel infarction from disseminated aspergillosis. *Dis Colon Rectum* 2004; 47: 1515–1518.
31. Vogeser M, Wanders A, Haas A, Ruckdeschel G: A four-year review of fatal Aspergillosis. *Eur J Clin Microbiol Infect Dis* 1999; 18: 42–45.
32. Kami M, Hori A, Takaue Y, Mutou Y: The gastrointestinal tract is a common target of invasive aspergillosis in patients receiving cytotoxic chemotherapy for hematological malignancy. *Clin Infect Dis* 2002; 35: 105–106.
33. Horvath JA, Dummer S: The use of respiratory-tract cultures in the diagnosis of invasive pulmonary aspergillosis. *Am J Med* 1996; 100: 171–178.
34. Janssen JJ, Strack van Schijndel RJ, van der Poest Clement EH, Ossenkoppele GJ, Thijs LG, Huijgens PC: Outcome of icu treatment in invasive aspergillosis. *Intensive Care Med* 1996; 22: 1315–1322.
35. Caillot D, Casasnovas O, Bernard A, Couaillier JF, Durand C, Cuise-nier B, Solary E, Piard F, Petrella T, Bonnin A, Couillaud G, Dumas M, Guy H: Improved management of invasive pulmonary aspergillosis in neutropenic patients using early thoracic computed tomographic scan and surgery. *J Clin Oncol* 1997; 15: 139–147.
36. Kaiser L, Hugenin T, Lew PD, Chapuis B, Pittet D: Invasive aspergillosis. Clinical features of 35 proven cases at a single institution. *Medicine (Baltimore)* 1998; 77: 188–194.
37. Abbasi S, Shenep JL, Hughes WT, Flynn PM: Aspergillosis in children with cancer: a 34-year experience. *Clin Infect Dis* 1999; 29: 1210–1219.
38. Lortholary O, Asciglu S, Moreau P, Herbrecht R, Marinus A, Casassus P, De Pauw B, Denning DW: Invasive aspergillosis as an opportunistic infection in nonallografted patients with multiple myeloma: a European Organization for Research and Treatment of Cancer/Invasive Fungal Infections Cooperative Group and the Intergrroupe Francais du Myelome. *Clin Infect Dis* 2000; 30: 41–46.
39. Nosari A, Oreste P, Cairoli R, Montillo M, Carrafiello G, Astolfi A, Muti G, Marbello L, Tedeschi A, Magliano E, Morra E: Invasive aspergillosis in haematological malignancies: clinical findings and management for intensive chemotherapy completion. *Am J Hematol* 2001; 68: 231–236.
40. Ringden O, Meunier F, Tollemar J, Ricci P, Tura S, Kuse E, Viviani MA, Gorin NC, Klastersky J, Fenau P, Prentice HG, Ksion-ski G: Efficacy of amphotericin B encapsulated in liposomes (AmBisome) in the treatment of invasive fungal infections in immunocompromised patients. *J Antimicrob Chemother* 1991; 28 (Suppl. B): 73–82.
41. Patterson TF, Kirkpatrick WR, White M, Hiemenz JW, Wingard JR, Dupont B, Rinaldi MG, Stevens DA, Graybill JR: Invasive aspergillosis. Disease spectrum, treatment practices, and outcomes. *Aspergillus Study Group. Medicine (Baltimore)* 2000; 79: 250–260.
42. Denning DW, Ribaud P, Milpied N, Caillot D, Herbrecht R, Thiel E, Haas A, Ruhnke M, Lode H: Efficacy and safety of voriconazole in the treatment of acute invasive aspergillosis. *Clin Infect Dis* 2002; 34: 563–571.
43. Herbrecht R, Denning DW, Patterson TF, Bennett JE, Greene RE, Oestmann JW, Kern WV, Marr KA, Ribaud P, Lortholary O, Sylvester R, Rubin RH, Wingard JR, Stark P, Durand C, Caillot D, Thiel E, Chandrasekar PH, Hodges MR, Schlamm HT, Troke PF, De Pauw B: Voriconazole versus amphotericin B for primary therapy of invasive aspergillosis. *N Engl J Med* 2002; 347: 408–415.
44. Bowden R, Chandrasekar P, White MH, Li X, Pietrelli L, Gurwith M, Van Burik JA, Laverdiere M, Safrin S, Wingard JR: A double-blind, randomized, controlled trial of amphotericin B colloidal dispersion versus amphotericin B for treatment of invasive aspergillosis in immunocompromised patients. *Clin Infect Dis* 2002; 35: 359–366.
45. Lin S, Schranz J, Teutsch S: Aspergillosis case-fatality rate: systematic review of the literature. *Clin Infect Dis* 2001; 32: 358–366.
46. Morrison VA, Haake RJ, Weisdorf DJ: Non-candida fungal infections after bone marrow transplantation: risk factors and outcome. *Am J Med* 1994; 96: 497–503.
47. Prescott RJ, Harris M, Banerjee SS: Fungal infections of the small and large intestine. *J Clin Pathol* 1992; 45: 806–811.
48. Myoken Y, Sugata T, Kyo T, Kyo T, Fujihara M, Kohara T, Katsu M, Tamura M, Mikami Y: Invasive Aspergillus stomatitis in patients with acute leukemia: report of 12 cases. *Clin Infect Dis* 2001; 33: 1975–1980.
49. Nylander WA Jr: The acute abdomen in the immunocompromised host. *Surg Clin North Am* 1988; 68: 457–470.
50. Johnson H, Smith TJ, Desforges J: Cytosine-arabioside-induced colitis and peritonitis: nonoperative management. *J Clin Oncol* 1985; 3: 607–612.
51. Vlasveld LT, Zwaan FE, Fibbe WE, Fibbe WE, Tjon RT, Tham TA, Kluin PM, Willemze R: Neutropenic enterocolitis following treatment with cytosine arabinoside-containing regimens for hematological malignancies: a potentiating role for amsacrine. *Ann Hematol* 1991; 62: 129–134.
52. Starnes HF Jr, Moore FD Jr, Mentzer S, Osteen RT, Steele GD Jr, Wilson RE: Abdominal pain in neutropenic cancer patients. *Cancer* 1986; 57: 616–621.
53. Chirletti P, Barillari P, Sammartino P, Cardi M, Caronna R, Arcese W, Petti C, Stipa V: The surgical choice in neutropenic patients with hematological disorders and acute abdominal complications. *Leuk Lymphoma* 1993; 9: 237–241.
54. Gomez L, Martino R, Rolston KV: Neutropenic enterocolitis: spectrum of the disease and comparison of definite and possible cases. *Clin Infect Dis* 1998; 27: 695–699.
55. Weinberger M, Hollingsworth H, Feuerstein IM, Young NS, Pizzo PA: Successful surgical management of neutropenic enterocolitis in two patients with severe aplastic anemia. Case reports and review of the literature. *Arch Intern Med* 1993; 153: 107–113.
56. Hori A, Kami M, Kishi Y, Machida U, Matsumura T, Kashima T: Clinical significance of extra-pulmonary involvement of invasive aspergillosis: a retrospective autopsy-based study of 107 patients. *J Hosp Infect* 2002; 50: 175–182.