



UNIL | Université de Lausanne

Unicentre

CH-1015 Lausanne

<http://serval.unil.ch>

Year : 2017

Extrascial injection for interscalene brachial plexus block reduces respiratory complications compared with a conventional intrascial injection: a randomized, controlled, double-blind trial

Palhais Nuno

Palhais Nuno, 2017, Extrascial injection for interscalene brachial plexus block reduces respiratory complications compared with a conventional intrascial injection: a randomized, controlled, double-blind trial

Originally published at : Thesis, University of Lausanne

Posted at the University of Lausanne Open Archive <http://serval.unil.ch>

Document URN : urn:nbn:ch:serval-BIB_F50BE5FE5EE75

Droits d'auteur

L'Université de Lausanne attire expressément l'attention des utilisateurs sur le fait que tous les documents publiés dans l'Archive SERVAL sont protégés par le droit d'auteur, conformément à la loi fédérale sur le droit d'auteur et les droits voisins (LDA). A ce titre, il est indispensable d'obtenir le consentement préalable de l'auteur et/ou de l'éditeur avant toute utilisation d'une oeuvre ou d'une partie d'une oeuvre ne relevant pas d'une utilisation à des fins personnelles au sens de la LDA (art. 19, al. 1 lettre a). A défaut, tout contrevenant s'expose aux sanctions prévues par cette loi. Nous déclinons toute responsabilité en la matière.

Copyright

The University of Lausanne expressly draws the attention of users to the fact that all documents published in the SERVAL Archive are protected by copyright in accordance with federal law on copyright and similar rights (LDA). Accordingly it is indispensable to obtain prior consent from the author and/or publisher before any use of a work or part of a work for purposes other than personal use within the meaning of LDA (art. 19, para. 1 letter a). Failure to do so will expose offenders to the sanctions laid down by this law. We accept no liability in this respect.

UNIVERSITE DE LAUSANNE - FACULTE DE BIOLOGIE ET DE MEDECINE

Centre hospitalier universitaire vaudois (CHUV)
Service d'anesthésiologie

**Extrafascial injection for interscalene brachial plexus
block reduces respiratory complications compared with
a conventional intrafascial injection: a randomized,
controlled, double-blind trial**

THESE

préparée sous la direction du Docteur Eric Albrecht
(avec la co-direction du Professeur Christian Kern)

et présentée à la Faculté de biologie et de médecine de
l'Université de Lausanne pour l'obtention du grade de

DOCTEUR EN MEDECINE

par

Nuno PALHAIS

Médecin diplômé de la Confédération Suisse
Originaire de Romanel-sur-Lausanne (Vaud)

Lausanne

2017

UNIVERSITE DE LAUSANNE - FACULTE DE BIOLOGIE ET DE MEDECINE

Centre hospitalier universitaire vaudois (CHUV)
Service d'anesthésiologie

**Extrafascial injection for interscalene brachial plexus
block reduces respiratory complications compared with
a conventional intrafascial injection: a randomized,
controlled, double-blind trial**

THESE

préparée sous la direction du Docteur Eric Albrecht
(avec la co-direction du Professeur Christian Kern)

et présentée à la Faculté de biologie et de médecine de
l'Université de Lausanne pour l'obtention du grade de

DOCTEUR EN MEDECINE

par

Nuno PALHAIS

Médecin diplômé de la Confédération Suisse
Originaire de Romanel-sur-Lausanne (Vaud)

Lausanne

2017

Imprimatur

Vu le rapport présenté par le jury d'examen, composé de

Directeur de thèse *Monsieur le Docteur **Eric Albrecht***
Co-Directeur de thèse *Monsieur le Professeur **Christian Kern***
Expert *Monsieur le Professeur **Thierry Kuntzer***
**Vice-Directeur de
l'Ecole doctorale** *Monsieur le Professeur **John Prior***

la Commission MD de l'Ecole doctorale autorise l'impression de la thèse de


Monsieur Nuno PALHAIS

intitulée

***Extrascial injection for interscalene brachial plexus block
reduces respiratory complications compared with a conventional
intrafascial injection: a randomized,
controlled, double-blind trial***

Lausanne, le 23 mai 2017

*pour Le Doyen
de la Faculté de Biologie et de Médecine*



*Monsieur le Professeur John Prior
Vice-Directeur de l'Ecole doctorale*

Le bloc interscalénique du plexus brachial avec injection extrafasciale réduit les complications respiratoires comparé à l'injection intrafasciale conventionnelle: étude randomisée, en double aveugle et contrôlée.

Introduction : Les avantages de l'anesthésie locorégionale ont été bien documentés et incluent une diminution de la morbidité et de la mortalité, une meilleure analgésie postopératoire, une meilleure efficacité des coûts, ainsi qu'un taux réduit de complications graves. En effet, l'anesthésie locorégionale échoguidée par ultrasons permet de procéder à une anesthésie fiable et uniforme autour de la cible nerveuse avec une installation du bloc nerveux plus rapide, de plus longue durée et de meilleure qualité tout en diminuant les risques d'injection intra vasculaire et de traumatisme nerveux. Le bloc interscalénique consiste à placer une aiguille dans le plexus brachial (approche intrafasciale conventionnelle) par le sillon interscalénique, constitué des muscles scalènes antérieur et moyen, afin de permettre la diffusion de l'anesthésique local au sein des racines nerveuses du plexus brachial. Cette technique permet d'assurer une analgésie puissante et localisée durant les jours suivants une chirurgie majeure de l'épaule. Néanmoins, le principal effet secondaire de cette procédure est la parésie de l'hémi diaphragme ipsilatéral, principal muscle respiratoire, qui peut atteindre 90 à 100 % des cas et qui est due à l'extension de l'anesthésique local au nerf phrénique cheminant en avant du plexus brachial. Dès lors, cette procédure devient contre-indiquée chez les patients souffrant d'insuffisance respiratoire sévère et de facto, les excluant des bénéfices liés à cette anesthésie locorégionale. L'hypothèse de cette étude randomisée, en double aveugle et contrôlée sur le bloc interscalénique échoguidé est de démontrer que l'injection extrafasciale (approche latérale, à distance de 4 mm de la gaine du plexus brachial) permet d'obtenir moins de complications respiratoires qu'avec l'injection intrafasciale tout en bénéficiant d'une analgésie équivalente.

Méthode : Quarante patients ASA I-III adressés pour une chirurgie majeure de l'épaule sous anesthésie générale ont été randomisés en deux groupes ; le premier groupe a bénéficié d'une analgésie par un bloc interscalénique échoguidé avec une injection intrafasciale tandis que le second groupe a bénéficié d'un bloc interscalénique échoguidé avec une injection extrafasciale. Tous les patients ont reçu la même dose d'anesthésique local (20 ml de bupivacaine 0.5% avec adrénaline 1:200 000). L'objectif primaire de cette étude est l'incidence de parésie hémi diaphragmatique, définie comme une réduction de > 75% de l'excursion diaphragmatique. Les mouvements diaphragmatiques ont été évalués par échographie en M-mode avant la chirurgie (fonction de base) et 30 minutes après la procédure. Les objectifs secondaires sont la capacité vitale forcée (CVF), le volume expiratoire maximum en 1 seconde (VEMS) et le débit expiratoire de pointe (DEP). Les objectifs additionnels incluent le délai avant la première administration d'opiacé et l'évaluation de la douleur à 24h (échelle numérique de la douleur, de 0 à 10).

Résultats : L'incidence de la parésie hémi diaphragmatique était de 90% (95% CI: 68–99%) pour le groupe ayant bénéficié d'une injection intrafasciale et de 21% (95% CI: 6–46%) pour le groupe ayant bénéficié d'une injection extrafasciale ($P < 0.0001$). De plus, concernant les objectifs secondaires le groupe extrafasciale a montré une meilleure préservation des fonctions respiratoires. Le temps moyen avant l'administration du premier opiacé est similaire dans les deux groupes (intrafasciale: 802 min [95% CI: 620–984 min]; extrafasciale: 973 min [95% CI: 791–1155 min]; $P = 0.19$), de même que le évaluation de la douleur à 24h (intrafasciale: 1.6 [95% CI: 0.9–2.2]; extrafasciale: 1.6 [95% CI: 0.8–2.4]; $P = 0.97$).

Conclusion : Le bloc interscalénique échoguidé du plexus brachial avec une injection extrafasciale réduit l'incidence de la parésie hémi-diaphragmatique et l'impact sur la fonction respiratoire tout en offrant une analgésie similaire par rapport à l'approche conventionnelle.

REGIONAL ANAESTHESIA

Extrascapular injection for interscalene brachial plexus block reduces respiratory complications compared with a conventional intrascapular injection: a randomized, controlled, double-blind trial[†]

N. Palhais¹, R. Brull³, C. Kern¹, A. Jacot-Guillarmod¹, A. Charmoy¹, A. Farron² and E. Albrecht^{1,*}

¹Department of Anaesthesia, ²Department of Orthopaedic, Lausanne University Hospital, Lausanne, Switzerland, and ³Department of Anaesthesia, Toronto Western Hospital and Women's College Hospital, University of Toronto, Toronto, Canada

*Corresponding author. E-mail: eric.albrecht@chuv.ch

Abstract

Background: Hemidiaphragmatic paresis after ultrasound-guided interscalene brachial plexus block is reported to occur in up to 100% of patients. We tested the hypothesis that an injection lateral to the brachial plexus sheath reduces the incidence of hemidiaphragmatic paresis compared with a conventional intrascapular injection, while providing similar analgesia.

Methods: Forty ASA I-III patients undergoing elective shoulder and clavicle surgery under general anaesthesia were randomized to receive an ultrasound-guided interscalene brachial plexus block for analgesia, using 20 ml bupivacaine 0.5% with epinephrine 1:200 000 injected either between C5 and C6 within the interscalene groove (conventional intrascapular injection), or 4 mm lateral to the brachial plexus sheath (extrascapular injection). The primary outcome was incidence of hemidiaphragmatic paresis (diaphragmatic excursion reduction >75%), measured by M-mode ultrasonography, before and 30 min after the procedure. Secondary outcomes were forced vital capacity, forced expiratory volume in 1 s, and peak expiratory flow. Additional outcomes included time to first opioid request and pain scores at 24 h postoperatively (numeric rating scale, 0–10).

Results: The incidences of hemidiaphragmatic paresis were 90% (95% CI: 68–99%) and 21% (95% CI: 6–46%) in the conventional and extrascapular injection groups, respectively ($P < 0.0001$). Other respiratory outcomes were significantly better preserved in the extrascapular injection group. The mean time to first opioid request was similar between groups (conventional: 802 min [95% CI: 620–984 min]; extrascapular: 973 min [95% CI: 791–1155 min]; $P = 0.19$) as were pain scores at 24 h postoperatively (conventional: 1.6 [95% CI: 0.9–2.2]; extrascapular: 1.6 [95% CI: 0.8–2.4]; $P = 0.97$).

Conclusions: Ultrasound-guided interscalene brachial plexus block with an extrascapular injection reduces the incidence of hemidiaphragmatic paresis and impact on respiratory function while providing similar analgesia, when compared with a conventional injection.

Clinical trial registration: NCT02074397.

Key words: analgesia; anesthesia, regional; brachial plexus block; diaphragm; postoperative pain

[†] This report was previously presented in part at the annual meeting of the European Society of Regional Anaesthesia and Pain Medicine, Ljubljana, Slovenia, September 2–5, 2015.

Accepted: December 21, 2015

© The Author 2016. Published by Oxford University Press on behalf of the British Journal of Anaesthesia. All rights reserved.
For Permissions, please email: journals.permissions@oup.com

Editor's Key Points

- Hemidiaphragmatic paresis is common after interscalene brachial plexus block, potentially adversely affecting respiratory function.
- Strategies to reduce this side-effect would improve utility of the block.
- This prospective study assessed the effect of two different ultrasound guided approaches on hemidiaphragmatic paresis, Extrafascial injection significantly reduced hemidiaphragmatic paresis and respiratory dysfunction, with well maintained analgesia.
- This approach warrants further study to clarify its role in upper limb regional blockade.

Interscalene brachial plexus block (ISB) provides effective analgesia after shoulder surgery¹ but causes hemidiaphragmatic paresis in up to 100% of patients, because of local anaesthetic spread to the phrenic nerve traveling along the anteromedial surface of the anterior scalene muscle.^{2,3} This side-effect potentially undermines the benefit of regional anaesthesia for patients suffering from moderate to severe respiratory dysfunction.^{4,5} Attempts to reduce the rate of hemidiaphragmatic paresis associated with ISB have been inconsistent.^{6–8}

Besides hemidiaphragmatic paresis, ISB is also associated with the highest rate of postoperative neurological deficits in routine regional anaesthesia practice,⁹ most likely as a result of hazardous needle-nerve contact. Indeed, a cadaveric study concluded that difficulty with ultrasound discrimination of tissue layers may contribute to sub-epineurial injection in as many as 50% of conventional intrafascial ISB procedures.¹⁰ To explore the important relationship of needle-nerve proximity in the setting of ISB, we recently demonstrated that depositing local anaesthetics as far as 8 mm lateral to the brachial plexus sheath during US-guided ISB, can produce excellent analgesia for shoulder surgery.¹¹ This extrafascial injection lateral to the nerve roots increases the distance to the phrenic nerve and may therefore reduce the likelihood of its block by the local anaesthetic spread. In the present randomized controlled double-blinded trial, we tested the hypothesis that an extrafascial injection can reduce the rate of hemidiaphragmatic paresis compared with a conventional intrafascial approach, while providing similar analgesia.

Methods

Recruitment and randomization

This trial was approved by the Ethics Committee of the Lausanne University Hospital (Commission d'Éthique Romande, protocol number 465/13) and was prospectively registered on clinicaltrials.gov (NCT02074397). All patients aged 18–85 yr undergoing elective shoulder and clavicle surgery between March and December 2014 at Lausanne University Hospital, were eligible to participate in this study. Exclusion criteria included existing neurological deficit in the upper limb, history of neck surgery or radiotherapy, moderate to severe pulmonary disease, chest deformity, contraindications to peripheral nerve block (e.g. allergy to local anaesthetics, coagulopathy, infection in the area), and pregnancy. After providing written informed consent, participating patients were randomly allocated on the day of surgery to either the experimental group (extrafascial injection) or the control group (conventional injection), using a computer-generated randomization table in aggregates of 10. Assignments were concealed in a sealed opaque envelope.

Interscalene block procedure

All US-guided ISB were performed before surgery in a dedicated block procedure room. These blocks were achieved or directly supervised by one of the authors (EA) who had no further involvement in the study protocol. Patients were positioned supine with the head turned 45 degrees to the non-operative side. Electrocardiogram, pulse oximetry, and bp monitors were routinely applied, and oxygen was provided. Peripheral i.v. access was established and midazolam 1–4 mg i.v. was administered for anxiety and sedation as needed. The needle insertion site was sterilized with a solution of chlorhexidine 2% in isopropyl alcohol 70%. Under sterile conditions, a high-frequency linear array transducer (13–6 MHz, SonoSite S-Nerve; SonoSite, Inc, Bothell, Washington) was placed over the interscalene region, to visualize the carotid artery and brachial plexus in the short axis view. The C5, C6, and C7 roots were identified in accordance with the description of Martinoli and colleagues.¹² After infiltration of the skin with 1–3 ml of lidocaine 1%, a 22-gauge 50-mm insulated block needle (SonoPlex Stim cannula, Pajunk®, Geisingen, Germany) was inserted, in-plane with the US beam on the lateral side of the transducer. The needle was then advanced under direct ultrasound guidance through the middle scalene muscle and toward the lateral border of the brachial plexus sheath. The brachial plexus sheath was identified as the linear hyperechoic layer surrounding the roots of the brachial plexus.

Extrafascial injection group

The final needle tip position was 4 mm lateral to the brachial plexus sheath, at a level equidistant between C5 and C6 roots. The distance of 4 mm was chosen according to the calculated success rate over 90% reported recently¹¹ and our daily experience in a university teaching hospital. The on-screen calliper measurement tool was used to define this distance of 4 mm, with the proximal calliper placed on the lateral border of the plexus sheath and the distal calliper extended laterally until the designated distance was reached, marking the target end point for the needle tip position (Fig. 1).

Conventional injection group

The final needle tip position was within the brachial plexus sheath in between the C5 and C6 nerve roots.

All patients received 20 ml of bupivacaine 0.5% with epinephrine 1:200 000 through the block needle, injected in 5 ml increments with intermittent aspiration. No dose adjustments were made based on patient age. The needle tip was not repositioned, except if patients complained of paraesthesia.

Intraoperative and postoperative procedure

After application of routine monitors in the operating theatre, patients received a standard general anaesthetic administered by an anaesthetist who was blinded to group allocation. Anaesthesia was induced using fentanyl 1–2 µg kg⁻¹ i.v. and propofol 2–4 mg kg⁻¹ i.v. with tracheal intubation facilitated by rocuronium 0.6 mg kg⁻¹ IV. Maintenance of anaesthesia was via inhaled sevoflurane 1.6–2.4% in a 40:60 mixture of oxygen and air. Positive pressure ventilation was initiated with tidal volume and rate adjusted to maintain an end-tidal PCO₂ of 35–40 mm Hg. Fentanyl 25–50 µg i.v. was administered as needed to treat increases in bp or heart rate of more than 15% above preinduction baseline values. As per our routine institutional practice, all patients received magnesium sulphate 50 mg kg⁻¹ i.v.,¹³ dexamethasone 0.15 mg kg⁻¹ i.v.,¹⁴

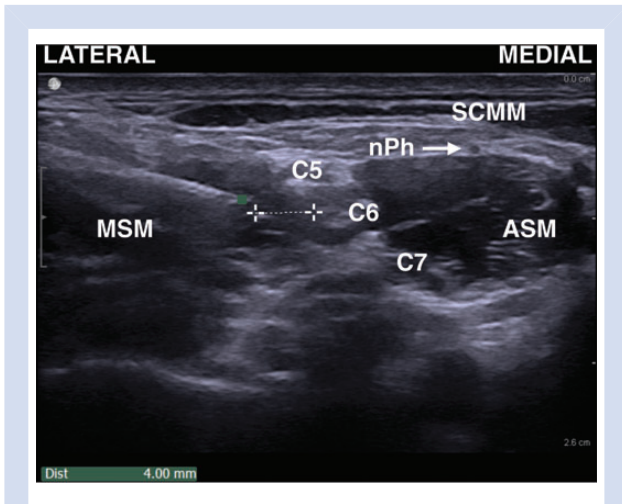


Fig 1 Ultrasound-guided interscalene brachial plexus block with an extrafascial injection: needle tip position (A) at a distance of 4 mm from the lateral border of the brachial plexus sheath. C5, C5 root; C6, C6 root; C7, C7 root; ASM, anterior scalene muscle; MSM, middle scalene muscle; nPh, phrenic nerve; SCMM, sternocleidomastoid muscle.

ondansetron 4 mg i.v. and droperidol 1 mg i.v. for the purposes of multimodal analgesia and antiemetic prophylaxis, respectively. Muscle relaxation was antagonized with neostigmine $50 \mu\text{g kg}^{-1}$ and glycopyrrolate $5\text{--}10 \mu\text{g kg}^{-1}$ at the end of surgery. In phase I recovery, pain (numeric rating scale [NRS] ≥ 4 or patient request for analgesia) was treated with morphine 1–2 mg every 10 min as needed. Once oral intake was initiated, patients received acetaminophen 1000 mg every 6 h and oxycodone 5 mg per every 3 h as needed. Antiemetic medications on the ward included ondansetron 4 mg i.v. and metoclopramide 10 mg i.v.

Block assessment and definition of successful block

Assessment of sensory and motor blocks was performed by a blinded research assistant every 5 min after local anaesthetic injection, for a total duration of 30 min. Sensory block was tested in the C5 and C6 dermatomes using a blunt tip needle pinprick test (0, no perception; 1, decreased sensation; 2, normal sensation). Motor block was tested using arm abduction (C5), and forearm flexion (C6) (incapacity to overcome gravity, 0; reduced force compared with contralateral arm, 1; no loss of force, 2). A successful block was defined as complete sensory (score, 0) and motor (score, 0) block in the distribution of the C5 and C6 nerve roots within 30 min of performing the ISB.

Hemidiaphragmatic excursion and respiratory function assessment

Hemidiaphragmatic excursion was assessed before and 30 min after the ISB procedure with a low-frequency curvilinear transducer (2–5 MHz, SonoSite S-Nerve; SonoSite, Inc, Bothell, Washington) using a subcostal approach as described previously.¹⁵ Briefly, patients were examined in the lying position and the hemidiaphragm was identified as an hyperechoic line, with breathing-related movements using the liver or spleen as an acoustic window. The hemidiaphragmatic excursion was measured by real-time M-mode ultrasonography from the resting expiratory position to a deep and quiet inspiration (Supplementary Appendix 1).

Respiratory function was also assessed before and 30 min after the regional procedure, with a bedside spirometer (Easy-One™ Spirometer; ndd Medical Technologies, Andover, UK). After standard instructions, the patient in a sitting upright position was asked to inspire maximally and blow into the device as fast and strong as possible. The test was repeated three times and the best value was recorded.

Outcomes

The primary outcome was rate of hemidiaphragmatic paresis 30 min after the procedure, defined as hemidiaphragmatic excursion reduction superior to 75% compared with the pre-procedure value.^{16,17} Secondary outcomes were divided into respiratory-related outcomes, block-related outcomes, and pain-related outcomes. Respiratory-related outcomes encompassed rates of forced vital capacity, forced expiratory volume in 1 s, and peak expiratory flow, all measured 30 min after the injection. Patients were also asked whether they felt dyspnoeic. Block-related outcomes included onset times of action of sensory and motor blocks (defined as time from removal of the needle until complete loss of sensory and motor function in C5 and C6 territories); rate of successful block 30 min after the injection; rate of paraesthesia during block performance; rates of Claude-Bernard-Horner syndrome and hoarseness 30 min after the injection; and durations of sensory block (defined as time from the injection of local anaesthetic to the time the patient recovered sensation over the shoulder), and motor block (defined as time from injection of local anaesthetic to the time the patient could raise their arm). Pain-related outcomes comprised of intraoperative fentanyl consumption; time to first opioid request (defined as time from block completion to the time to first dose of i.v. morphine or oxycodone); pain scores (NRS out of 10) upon admission to Phase 1 recovery and at 24 h postoperatively; cumulative postoperative opioid consumption (converted to equivalent doses of i.v. morphine¹⁸) in phase 1 recovery and at 24 h postoperatively; and satisfaction with overall anaesthetic management (NRS out of 10). In case of patients who did not require i.v. morphine or oxycodone during the first 24 postoperative h, time to first opioid request was defined as 1440 min (24 h \times 60 min). As per our routine institutional practice, all patients were hospitalized overnight and were evaluated at 24 h postoperatively. Patients were also contacted on postoperative day seven to capture any block-related complications such as haematoma, infection, persistent paraesthesia or weakness in the upper limb.

The patients, anaesthetists in charge of the patient in the operating theatre, Phase 1 recovery nurses, ward nurses and the research assistant measuring the respiratory data and collecting all other data were blinded to the group allocation.

Sample size calculation

Based on data reported in the literature the average rate of hemidiaphragmatic paresis after ultrasound-guided ISB with a volume of 20 ml was 100%.⁶ Assuming a 50% reduction rate, an alpha error of 0.05 and a power of 80%, we calculated that 16 patients would be required for each group (total 32) in order to detect a difference. Allowing for a 20% drop-out rate, we planned to recruit a total of 40 subjects.

Statistical analysis

Data were analysed on an intention-to-treat basis. Categorical variables are presented as frequencies and continuous variables

are summarized as mean values with 95% confidence intervals (95% CI). Continuous parametric and non-parametric data were compared using the Student's *t*-test and Mann-Whitney *U*-test, respectively. Categorical and dichotomous data were compared using the Fisher's exact test or Pearson test as appropriate. Kaplan-Meier table analysis (survival analysis) was performed for effect of localization of injection on time to first opioid request. Significance was considered at $P < 0.05$ based on a two-tailed probability. Statistical analysis was performed using the JMP 9 statistical package (SAS Institute, Cary, NC).

Results

Forty patients were recruited and 39 completed the study for the primary outcome. As a result of operating theatre time constraints, the hemidiaphragmatic excursion in one patient in the extrafascial injection group was not visualized after the interscalene brachial plexus block. All patients in both groups had a successful block 30 min after the injection. Figure 2 depicts the flow chart of patients and Table 1 presents patients characteristics.

The rate of hemidiaphragmatic paresis was significantly reduced in the extrafascial injection group (21% [95% CI: 6–46%]) compared with the conventional injection group (90% [95% CI: 68–99%]; $P < 0.0001$). Six patients in the conventional injection

group complained of dyspnoea requiring no specific treatment and none in the extrafascial group ($P < 0.01$). All other respiratory outcomes were significantly preserved in the extrafascial injection group (Table 2).

A conventional injection was associated with a faster onset of sensory and motor block, along with increased rates of paraesthesia during the procedure and hoarseness 30 min after the procedure (Table 3). There were no differences in the other block-related outcomes (Table 3).

The mean intraoperative fentanyl consumption was similar between groups (conventional injection group: 158 μg [95% CI: 142–173 μg]; extrafascial injection group: 161 μg [95% CI: 144–178 μg]; $P = 0.73$), and the mean time to first opioid request (conventional injection group: 802 min [95% CI: 620–984 min]; extrafascial injection group: 973 min [95% CI: 791–1155 min]; $P = 0.19$; Fig. 3). Other acute pain-related outcomes were similar between groups (Table 3). No patients developed haematoma, infection, persistent paraesthesia or weakness in the upper limb seven days after the regional procedure.

Discussion

This double-blinded randomized controlled trial suggests that an extrafascial injection significantly reduces the rate of

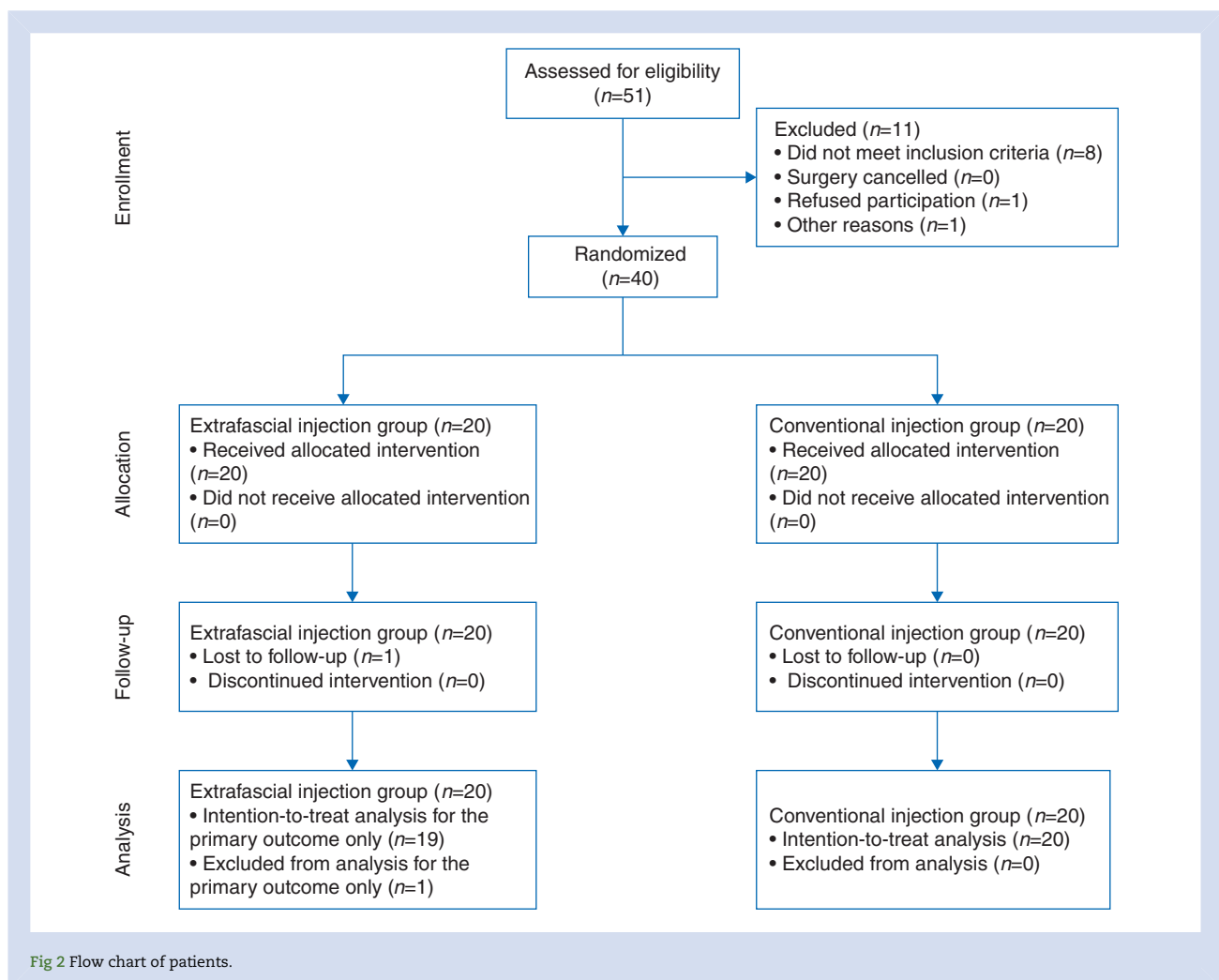


Fig 2 Flow chart of patients.

Table 1 Patients characteristics and clinical data presented as mean (95% confidence interval) standard deviations or absolute number as appropriate

	Conventional injection	Extrafascial injection	P value
Gender (male/female)	15/5	19/1	0.08
Age (yr)	35 (27–43)	37 (30–44)	0.64
Height (cm)	173 ± 8	177 ± 6	0.10
Weight (kg)	83 ± 16	77 ± 11	0.19
ASA (I/II/III)	6/12/2	13/6/1	0.09
Duration of surgery (min)	95 (80–111)	115 (100–130)	0.06
Surgical procedure			0.49
Shoulder joint capsular stabilization	8	8	
Acromioclavicular resection	3	3	
Biceps tenotomy	5	4	
Open reduction - internal fixation of the clavicle	2	5	
Other	2	0	

Table 2 Respiratory-related outcomes. Data are presented as mean and 95% confidence interval

	Conventional injection	Extrafascial injection	P value
Pre-procedure			
Forced vital capacity (L)	4.4 (3.9–5.0)	4.6 (4.3–4.9)	0.47
Forced expiratory volume in 1 s (L)	3.5 (3.1–3.9)	3.7 (3.4–4.0)	0.39
Peak expiratory flow (L s ⁻¹)	8.1 (6.9–9.2)	8.3 (7.5–9.1)	0.73
Post-procedure			
Forced vital capacity (L)	3.2 (2.7–3.7)	3.8 (3.5–4.2)	0.04
Forced expiratory volume in 1 s (L)	2.6 (2.1–3.0)	3.1 (2.8–3.4)	0.02
Peak expiratory flow (L s ⁻¹)	6.0 (5.0–7.0)	7.6 (6.7–8.5)	0.02
Percentage reduction			
Forced vital capacity (%)	28 (33–23)	17 (22–13)	<0.01
Forced expiratory volume in 1 s (%)	28 (33–22)	16 (20–12)	<0.01
Peak expiratory flow (%)	24 (34–15)	8 (13–3)	<0.01

Table 3 Block- and acute pain-related outcomes. Data are presented as mean and 95% confidence interval. NRS, Numeric Rating Scale

	Conventional injection	Extrafascial injection	P value
Block-related outcomes			
Onset time of sensory block (min)	12 (8–15)	19 (16–22)	<0.01
Onset time of motor block (min)	8 (5–11)	17 (13–21)	<0.001
Paraesthesia during the procedure (rate of)	30% (12–54%)	0%	<0.01
Hoarseness (rate of)	35% (15–59%)	5% (0–25%)	0.02
Claude-Bernard-Horner syndrome (rate of)	35% (15–59%)	20% (6–44%)	0.29
Duration of sensory block (min)	1026 (769–1284)	922 (778–1065)	0.46
Duration of motor block (min)	1134 (892–1376)	980 (851–1109)	0.25
Acute pain-related outcomes			
i.v. morphine consumption in phase I recovery (mg)	1 (0–2)	0 (0–1)	0.22
Pain scores in phase I recovery (NRS, 0–10)	0.5 (0.0–0.9)	0.4 (0.0–0.7)	0.73
Cumulative i.v. morphine equivalent consumption at 24 h postoperatively (mg)	8 (6–11)	7 (4–10)	0.48
Pain scores at 24 h postoperatively (NRS, 0–10)	1.6 (0.9–2.2)	1.6 (0.8–2.4)	0.97
Satisfaction score (NRS, 0–10)	9.5 (9.1–9.9)	9.3 (8.5–10.0)	0.58

hemiaphragmatic paresis and impact on respiratory function, while providing similar analgesia compared with a conventional injection for US-guided ISB. Prolonged onset times of sensory and motor blocks in the extrafascial injection group are insignificant for analgesic purposes and offset by increased rate of

paraesthesia and hoarseness, while groups are equally satisfied with analgesia.

Previous attempts at reducing the rate of hemidiaphragmatic paresis associated with US-guided ISB have focused on reducing the volume of local anaesthetic injected inside the brachial

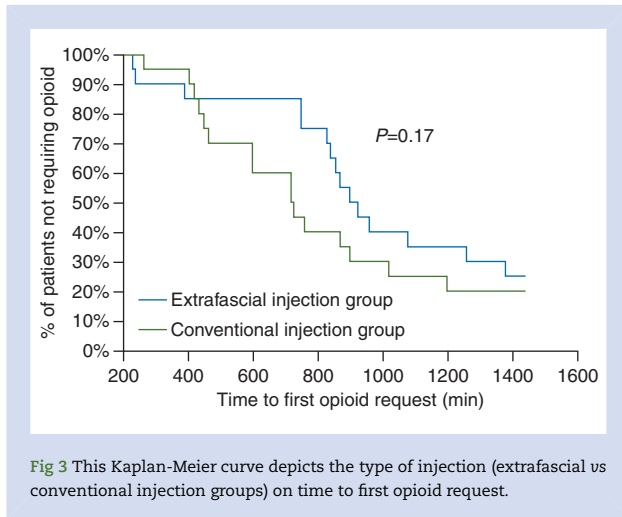


Fig 3 This Kaplan-Meier curve depicts the type of injection (extrafascial vs conventional injection groups) on time to first opioid request.

plexus sheath. Investigators have reported that reducing the volume of local anaesthetic from 20 to 10 ml or 5 ml reduced the rate of hemidiaphragmatic paresis to 93%⁷ or 45%,⁶ respectively. In the present study, we were able to reduce the rate of hemidiaphragmatic paresis to 21% by injecting outside of the brachial plexus sheath without compromising analgesia. The concept of an extrafascial injection can be easily translated into clinical practice by respecting a short distance between the needle tip and the lateral border of the brachial plexus, while ensuring that the local anaesthetic injectate spreads towards the nerve roots.

The present study is subject to several limitations. First, our results cannot be used to predict which patients are at risk to develop hemidiaphragmatic paresis despite an extrafascial injection. As this is an important consideration when performing ISB in the presence of pre-existing lung disease, our next endeavour is to define the anatomical and other patient-related characteristics that may lead to phrenic nerve block after extrafascial injection. Another limitation of this study is that hemidiaphragmatic excursion was measured only 30 min after injection of local anaesthetic, and therefore we may have failed to capture delayed-onset hemidiaphragmatic paresis. We chose to measure hemidiaphragmatic excursion at 30 min based on pertinent studies published previously.^{3 6 7} Further, we did not repeat ultrasonographic hemidiaphragmatic assessment and respiratory tests after ISB and were therefore unable to determine duration of hemidiaphragmatic paresis. Next, we did not assess local muscular effects, if any, of i.m. injection within the middle scalene muscle. While we recognize that myotoxicity of bupivacaine has been well described when injected into extraocular muscles, and after repeated high volume injection in other settings,^{19 20} the safety of intentional or unintentional i.m. injection of local anaesthetics in routine clinical practice has withstood the test of time. Finally, our results are not generalizable to continuous catheter-based ISB.

In conclusion, ultrasound-guided ISB with an extrafascial injection reduces rate of hemidiaphragmatic paresis and impact on respiratory function while providing similar analgesia, when compared with a conventional injection.

Authors' contributions

Study design/planning: R.B., A.C., E.A.

Study conduct: N.P., A.J.G., E.A.

Data analysis: E.A.

Writing paper: N.P.

Revising paper: all authors

Supplementary material

Supplementary material is available at *British Journal of Anaesthesia* online.

Acknowledgements

We gratefully thank Dr Istvan Bathory who provided care for study patients.

Declaration of interest

E.A. has received grants from the Swiss Academy for Anaesthesia Research (SACAR), Lausanne, Switzerland (no grant numbers attributed).

Funding

This work was supported by departmental funding (Department of Anaesthesia, Centre Hospitalier Universitaire Vaudois and University of Lausanne, Lausanne, Switzerland).

References

1. Fredrickson MJ, Krishnan S, Chen CY. Postoperative analgesia for shoulder surgery: a critical appraisal and review of current techniques. *Anaesthesia* 2010; **65**: 608–24
2. Urmei WF, Talts KH, Sharrock NE. One hundred percent incidence of hemidiaphragmatic paresis associated with interscalene brachial plexus anesthesia as diagnosed by ultrasonography. *Anesth Analg* 1991; **72**: 498–503
3. Urmei WF, Grossi P, Sharrock NE, Stanton J, Gloeggler PJ. Digital pressure during interscalene block is clinically ineffective in preventing anesthetic spread to the cervical plexus. *Anesth Analg* 1996; **83**: 366–70
4. Urmei WF, McDonald M. Hemidiaphragmatic paresis during interscalene brachial plexus block: effects on pulmonary function and chest wall mechanics. *Anesth Analg* 1992; **74**: 352–7
5. Cangiani LH, Rezende LA, Giancoli Neto A. Phrenic nerve block after interscalene brachial plexus block. Case report. *Rev Bras Anesthesiol* 2008; **58**: 152–9
6. Riazi S, Carmichael N, Awad I, Holtby RM, McCartney CJ. Effect of local anaesthetic volume (20 vs 5 ml) on the efficacy and respiratory consequences of ultrasound-guided interscalene brachial plexus block. *Br J Anaesth* 2008; **101**: 549–56
7. Sinha SK, Abrams JH, Barnett JT, et al. Decreasing the local anesthetic volume from 20 to 10 ml for ultrasound-guided interscalene block at the cricoid level does not reduce the incidence of hemidiaphragmatic paresis. *Reg Anesth Pain Med* 2011; **36**: 17–20
8. Lee JH, Cho SH, Kim SH, et al. Ropivacaine for ultrasound-guided interscalene block: 5 ml provides similar analgesia but less phrenic nerve paralysis than 10 ml. *Can J Anaesth* 2011; **58**: 1001–6
9. Sites BD, Taenzer AH, Herrick MD, et al. Incidence of local anesthetic systemic toxicity and postoperative neurologic symptoms associated with 12,668 ultrasound-guided nerve blocks: an analysis from a prospective clinical registry. *Reg Anesth Pain Med* 2012; **37**: 478–82

10. Orebaugh SL, McFadden K, Skorupan H, Bigeleisen PE. Subepineurial injection in ultrasound-guided interscalene needle tip placement. *Reg Anesth Pain Med* 2010; **35**: 450–4
11. Albrecht E, Kirkham KR, Taffe P, et al. The maximum effective needle-to-nerve distance for ultrasound-guided interscalene block: an exploratory study. *Reg Anesth Pain Med* 2014; **39**: 56–60
12. Martinoli C, Bianchi S, Santacroce E, Pugliese F, Graif M, Derchi LE. Brachial plexus sonography: a technique for assessing the root level. *Am J Roentgenol* 2002; **179**: 699–702
13. Albrecht E, Kirkham KR, Liu SS, Brull R. Peri-operative intravenous administration of magnesium sulphate and postoperative pain: a meta-analysis. *Anaesthesia* 2013; **68**: 79–90
14. De Oliveira GS Jr, Almeida MD, Benzon HT, McCarthy RJ. Peri-operative single dose systemic dexamethasone for postoperative pain: a meta-analysis of randomized controlled trials. *Anesthesiology* 2011; **115**: 575–88
15. Gerscovich EO, Cronan M, McGahan JP, Jain K, Jones CD, McDonald C. Ultrasonographic evaluation of diaphragmatic motion. *J Ultrasound Med* 2001; **20**: 597–604
16. Renes SH, Spoormans HH, Gielen MJ, Rettig HC, van Geffen GJ. Hemidiaphragmatic paresis can be avoided in ultrasound-guided supraclavicular brachial plexus block. *Reg Anesth Pain Med* 2009; **34**: 595–9
17. Petrar SD, Seltnerich ME, Head SJ, Schwarz SK. Hemidiaphragmatic paralysis following ultrasound-guided supraclavicular versus infraclavicular brachial plexus blockade: a randomized clinical trial. *Reg Anesth Pain Med* 2015; **40**: 133–8
18. Skaer TL. Practice guidelines for transdermal opioids in malignant pain. *Drugs* 2004; **64**: 2629–38
19. Zink W, Graf BM. Local anesthetic myotoxicity. *Reg Anesth Pain Med* 2004; **29**: 333–40
20. Hogan Q, Dotson R, Erickson S, Kettler R, Hogan K. Local anesthetic myotoxicity: a case and review. *Anesthesiology* 1994; **80**: 942–7

Handling editor: L. Colvin