

# The Importance of QuantiFERON Gold Plus Test for the Diagnosis of Presumed Ocular Tuberculosis

## Die Bedeutung des QuantiFERON Gold Plus-Tests für die Diagnose der vermuteten Augentuberkulose



### Background

In 2021, the World Health Organization (WHO) estimated 10.6 million new cases of active tuberculosis (TB) [1]. A TB infection results from the inhalation of small droplets contaminated with *Mycobacterium tuberculosis* (Mtb). Within 4 to 12 weeks after inhalation, a local tissue response and, in some cases, a hematogenous dissemination of Mtb occurs. Although the lung is the primary site of infection and pulmonary TB can be easily diagnosed by chest X-ray, extrapulmonary manifestations are not uncommon. After primary infection, patients may completely clear the Mtb, develop TB disease, or enter a latent stage (latent tuberculosis infection, LTBI) [2]. Reactivation of TB may occur without systemic symptoms and in extrapulmonary localization. In LTBI and in some extrapulmonary reactivations, diagnosis relies on indirect methods that assess the presence of sensitized lymphocytes capable of releasing cytokines when stimulated by mycobacterial antigens [3].

Ocular TB poses a challenge for ophthalmologists, often being diagnosed in the absence of pulmonary TB [4]. Its clinical presentation is diverse, requiring adherence to diagnostic criteria such as those outlined by the Standardisation of Uveitis Nomenclature (SUN) [5]. Various ocular findings can be attributed to a tubercular etiology, including tubercular anterior uveitis, intermediate uveitis, panuveitis, retinal vasculitis, serpiginous-like choroiditis, tuberculoma, multifocal choroiditis, acute posterior multifocal placoid pigment epitheliopathy, and the lesser-known variant, relentless placoid chorioretinitis, an unusual variant of serpiginous chorioretinitis [6].

Multiple diagnostic tests are available to support the identification of ocular TB, each with specific advantages and limita-

tions. The tuberculin skin test (TST) employs the purified protein derivative (PPD) as an antigen, measuring cellular immunity to PPD antigens, reflecting exposure to Mtb or other mycobacteria. Notably, prior vaccination with *Mycobacterium bovis* strains, such as bacillus Calmette-Guérin (BCG), can influence TST results [7]. While the TST has been a cornerstone of clinical practice, it has some limitations. Its sensitivity is likely comparable to that of the interferon-gamma release assay (IGRA), but its specificity is notably lower [8–10].

The aim of this paper is to focus on the potential for false-negative results in TB screening tests, particularly in patients receiving immunosuppressive drugs.

### History and Signs

A 16-year-old woman from Algeria sought medical attention for persistent blurred vision in her right eye (RE) since June 2022. Ophthalmic examination revealed six distinct white, round lesions at the posterior pole, as confirmed by retinal fluorescein angiography, and the diagnosis of multifocal choroiditis was posed. A comprehensive panel of serological tests for infectious and autoimmune etiologies, including toxoplasmosis, TPHA, VDRL, ASLO, HIV, HBV, and HCV, returned negative results. Additional investigations, encompassing angiotensin-converting enzyme (ACE), C-reactive protein, and erythrocyte sedimentation rate, gave normal values.

Given the context of an initial negative result in a 2-unit TST utilizing PPD antigens, and normal findings on chest CT scan, cerebral, and orbital angio-MRI, the patient was diagnosed with unilateral idiopathic multifocal choroiditis. Initial management was three consecutive infusions of 500 mg/day of methylprednisolone, followed by a tapering regimen of oral pred-

nisone at 1 mg/kg/day with gradual reduction by 5 mg every 2 weeks.

Over a 7-month period, the patient experienced two relapses despite the maintenance of corticosteroid therapy. Retinal fluorescein angiography confirmed an escalation in the number and size of retinochoroidal lesions in the RE, extending to the midperiphery. Subsequent therapy involved a further course of 3 methylprednisolone infusions (500 mg/day), followed by a transition to oral prednisone at a dose of 1 mg/kg/day (50 mg/day). Concurrently, azathioprine therapy was initiated at a dosage of 100 mg/day.

Notably, a second 2-unit TST and a TB-Feron test were conducted after the second dose of intravenous methylprednisolone but before starting azathioprine therapy, both yielding negative results. Notably, these laboratory results were obtained while the oral cortisone therapy was ongoing.

### Therapy and Outcome

Despite continuous immunosuppressive treatment, the patient's clinical condition exhibited a clear progression of the disease, necessitating referral to the Jules-Gonin Uveitis Clinic in Lausanne in March 2023. At the time of evaluation, her visual acuity remained at 10/10 in both eyes. Fundoscopy revealed multiple atrophic disseminated lesions at the posterior pole and periphery of her RE (► Fig. 1 a), without vitritis. Fluorescein and indocyanine green (ICG) angiography depicted multiple hyperfluorescent and hypofluorescent lesions, respectively (► Fig. 1 c, d). The left eye (LE) fundus was normal (► Fig. 1 b).

Considering the clinical history marked by two relapses under steroid therapy, together with the origin from an area with an “upper-moderate” incidence of TB ac-

cording to the 2021 WHO report, a diagnosis of tuberculous multifocal choroiditis was strongly suspected. Primary exposure to Mtb was confirmed by a positive ELISpot TB and QuantiFERON-TB Gold Plus. Knowledge of these diagnostic findings and after a multidisciplinary discussion involving ophthalmologists, immunologists, and infectious disease specialists, the decision was made to withdraw immunosuppressive therapy and instigate a quadruple therapy regimen targeting active TB.

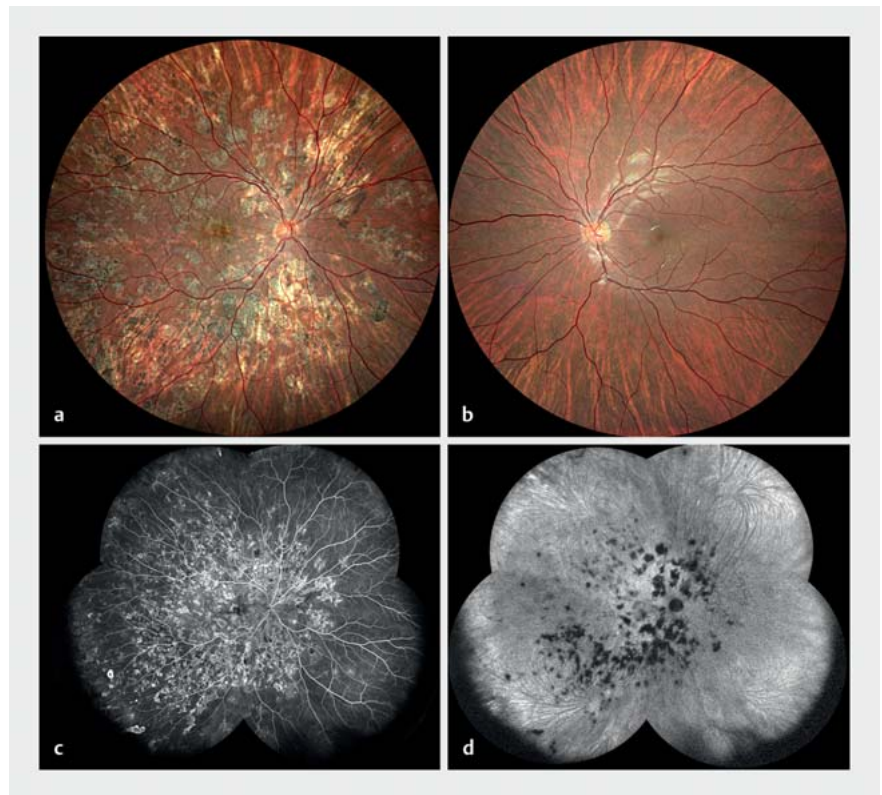
## Discussion

According to the WHO Global TB report of 2021, the incidence of TB in Algeria is 54 per 100 000 people per year, categorizing it as an “upper-moderate” risk area.

IGRAs are T cell-based *in vitro* tests that measure the presence of T cell responses against Mtb antigens, including early secreted antigenic target 6 (ESAT-6), culture filtrate protein 10 (CFP-10), and, in some cases, TB7.7 [11]. Notably, these antigens are not present in the BCG strain used for vaccination, so prior BCG vaccination does not interfere with IGRA tests based on the aforementioned antigens [12]. In general, especially in regions with endemic Mtb infection or high vaccination rates, IGRA tests are recommended to avoid false-positive results [13]. Nowadays, most laboratories propose IGRA tests as appropriate alternatives to the TST [7]. It is important to note that both IGRA and TST are functional assays that can be influenced by corticosteroids or immunosuppressive therapy [13], so it is advisable to perform these tests before initiating immunosuppression in order to avoid false-negative results.

The QuantiFERON-TB Gold In-Tube assay (QFT-GIT; Qiagen, Germantown, MD, USA) is one of the most widely used IGRAs. It is an enzyme-linked immunosorbent assay (ELISA)-based, whole blood test that uses three antigens (ESAT-6, CFP-10, and TB7.7 peptides) to predominantly stimulate CD4 T cells in an in-tube format [14].

Recently, a new ELISA-based IGRA, the Standard E TB-Feron ELISA (TBF; SD Biosensor, Gyeonggi-do, Republic of Korea), was approved by the Ministry of Food and Drug Safety of the Republic of Korea. The



► **Fig. 1** a Color fundus photography of the right eye showing multiple atrophic disseminated lesions (multifocal choroiditis). b Normal color fundus photography of the left eye. Note the presence of an artefact in the inferior arcade. c Fluorescein angiography of the right eye with multiple hyperfluorescent lesions at the posterior pole and in the periphery. d Indocyanine green angiography of the right eye with multiple hypofluorescent lesions at the posterior pole and in the periphery.

principles of this assay, including the antigens for stimulating T cells, are almost the same as those of QFT-GIT [15,16]. One distinctive difference between TBF and QFT-GIT is the structure of the TB-specific antigens; the antigens in TBF are recombinant whole proteins of ESAT-6, CFP-10, and TB7.7 [16], while those of QFT-GIT are TB-specific synthetic peptide antigens [15]. In addition, the incubation temperature and the time of the incubation procedure in ELISA differ, while TBF offers advantages in terms of cost-effectiveness compared to QFT-GIT.

A study [13] comparing the analytical performance of the TBF assay with that of QFT-GIT for detecting LTBI among health care workers demonstrated that TBF exhibits a comparable and clinically acceptable performance in detecting LTBI, positioning it as a valuable alternative to QFT-GIT. However, it is crucial to note that

TBF employs proteins instead of peptides, potentially influencing results in comparison to QuantiFERON TB Gold or Gold Plus.

A recent meta-analysis suggests that the site of TB infection significantly impacts the sensitivity of IGRAs. Notably, central nervous system TB emerged as a significant risk factor for false-negative IGRA results, possibly due to the presence of the blood-brain barrier limiting lymphocyte encounters with specific Mtb antigens [17]. A similar condition may affect IGRA results in ocular TB cases, given the existence of the blood-ocular barrier.

In our clinical case, the patient came from a region with an “upper-moderate” risk of Mtb infection, lacked systemic features, and thorax CT scans showed no pathological findings. Although the TST was negative twice, no IGRA test was conducted before initiating systemic corticosteroid

therapy. The first TBF test, performed 6 months after initiating immunosuppressive therapy, showed negative results. Despite ongoing treatment, the patient experienced relapses with increased retinochoroidal lesions, prompting reconsideration of the diagnosis of unilateral multifocal idiopathic choroiditis.

At the time of examination in Lausanne, the patient had been on azathioprine for over a month. Recognizing the diverse manifestations of ocular TB, a repeat IGRA (Quantiferon TB Gold PLUS) was performed with a positive result. Given the patient's origin from Algeria, the presence of multiple retinochoroidal lesions, recurrent relapses, and lack of improvement despite therapy, the positive QFT-GIT test raised suspicion for ocular TB. Consequently, we recommended tapering ongoing therapy and the initiation of TB therapy.

This case underscores the imperative of excluding infectious causes, such as TB or syphilis, before initiating cortisone therapy. If the disease persists despite treatment, alternative diagnoses must be explored. Infectious causes should be ruled out before introducing cortisone therapy, highlighting the crucial role of a multidisciplinary approach in a systemic disease such as TB. Additionally, ophthalmologists' understanding of the nuances of available laboratory tests is essential to ensure the correct diagnostic investigations in terms of specificity, sensitivity, and predictive value. We reiterate the superiority of IGRAs over TST in terms of specificity and emphasize the distinctions between QuantiFERON Gold and TB-Feron tests.

## Conclusion


Accurate diagnosis is crucial in these cases as immunosuppression in a patient with undiagnosed TB could lead to dissemination of the infection. Laboratory tests should be performed before the introduction of corticosteroids or immunosuppressive drugs to avoid false-negative tests.

## Conflict of Interest

This work was collected through the online JIR-cohort system with the support of the

AURIS Foundation, W. & E. Grand d'Hauteville Foundation, Ingvar Kamprad Fund, Fleurette Wagemakers Foundation, Kononchuk Family grant, Blatter Family grant and Rhumatismes-Enfants-Suisse Foundation.

## Authors

Francesca Bruzzone<sup>1</sup>, Margherita Plebani<sup>2</sup>, Aikaterini Koryllou<sup>3</sup>, Matthieu Perreau<sup>4</sup>, Yan Guex-Crosier<sup>1</sup> 

- 1 Ophthalmology, Jules-Gonin Eye Hospital, University of Lausanne, Switzerland
- 2 Pediatric Infectious Diseases and Vaccinology Unit, Department Women-Mother-Child, Lausanne University Hospital, CHUV, Lausanne, Switzerland
- 3 Unit of Pediatric Rheumatology, Immunology and Allergology, Lausanne University Hospital and University of Lausanne, Lausanne, Switzerland
- 4 Division of Immunology and Allergy, Lausanne University Hospital, University of Lausanne, 1011 Lausanne, Switzerland

## Correspondence

### Prof. Yan Guex-Crosier, MD

Ophthalmology  
Jules-Gonin Eye Hospital,  
University of Lausanne  
15 Avenue de France  
1004 Lausanne  
Switzerland  
Phone: + 41 (0) 2 16 26 82 30  
Fax: + 41 (0) 2 16 26 81 22  
yan.guex@fa2.ch

## References

- [1] World Health Organization (WHO). Global tuberculosis report 2021. Geneva: World Health Organization; 2021. Accessed January 18, 2024 at: <https://www.who.int/publications/i/item/9789240037021>
- [2] Ducommun MA, Eperon S, Khonkarly MB et al. Long-term close follow-up of chorioretinal lesions in presumed ocular tuberculosis. *Eur J Ophthalmol* 2012; 22: 195–202
- [3] Villiger PM, Zellweger JP, Möller B. Novel screening tools for latent tuberculosis: time to leave an old friend? *Curr Opin Rheumatol* 2009; 21: 238–243
- [4] Gupta V, Gupta A, Rao NA. Intraocular tuberculosis: an update. *Surv Ophthalmol* 2007; 52: 561–587
- [5] Standardization of Uveitis Nomenclature (SUN) Working Group. Classification criteria for sarcoidosis-associated uveitis. *Am J Ophthalmol* 2021; 228: 142–151
- [6] Jones BE, Jampol LM, Yannuzzi LA et al. Relentless placoid chorioretinitis: A new entity or an unusual variant of serpiginous chori-

retinitis? *Arch Ophthalmol* 2000; 118: 931–938

- [7] Pai M, Behr M. Latent *Mycobacterium tuberculosis* infection and interferon-gamma release assays. *Microbiol Spectr* 2016; 4. doi:10.1128/microbiolspec.TBTB2-0023-2016
- [8] Pai M, Riley LW, Colford JM jr. Interferon-gamma assays in the immunodiagnosis of tuberculosis: a systematic review. *Lancet Infect Dis* 2004; 4: 761–776
- [9] Pai M, Kalantri S, Dheda K. New tools and emerging technologies for the diagnosis of tuberculosis: part 1. Latent tuberculosis. *Expert Rev Mol Diagn* 2006; 6: 413–422
- [10] Menzies D, Pai M, Comstock G. Meta-analysis: new tests for the diagnosis of latent tuberculosis infection: areas of uncertainty and recommendations for research. *Ann Intern Med* 2007; 146: 340–354
- [11] Carvalho AC, Pezzoli MC, El-Hamad I et al. QuantiFERON-TB Gold test in the identification of latent tuberculosis infection in immigrants. *J Infect* 2007; 55: 164–168
- [12] Andersen P, Munk ME, Pollock JM et al. Specific immune-based diagnosis of tuberculosis. *Lancet* 2000; 356: 1099–1104
- [13] Kweon OJ, Lim YK, Kim HR et al. Evaluation of Standard E TB-Feron Enzyme-Linked Immunosorbent Assay for Diagnosis of Latent Tuberculosis Infection in Health Care Workers. *J Clin Microbiol* 2019; 57: e01347-19
- [14] Banaei N, Gaur RL, Pai M. Interferon gamma release assays for latent tuberculosis: what are the sources of variability? *J Clin Microbiol* 2016; 54: 845–850
- [15] Qiagen. QuantiFERON-TB Gold (QFT) ELISA package insert. Germantown, MD: Qiagen; 2016
- [16] SD Biosensor. Standard E TB-Feron ELISA package insert. Gyeonggi-do, Republic of Korea: SD Biosensor; 2019
- [17] Yamasue M, Komiya K, Usagawa Y et al. Factors associated with false negative interferon- $\gamma$  release assay results in patients with tuberculosis: A systematic review with meta-analysis. *Sci Rep* 2020; 10: 1607

## Bibliography

Klin Monatsbl Augenheilkd 2024; 241: 432–434

DOI 10.1055/a-2244-6657

ISSN 0023-2165

© 2024. The Author(s).

This is an open access article published by Thieme under the terms of the Creative Commons Attribution-NonDerivative-NonCommercial-license, permitting copying and reproduction so long as the original work is given appropriate credit. Contents may not be used for commercial purposes, or adapted, remixed, transformed or built upon. (<https://creativecommons.org/licenses/by-nc-nd/4.0/>)

Georg Thieme Verlag KG, Rüdigerstraße 14, 70469 Stuttgart, Germany

