

SHORT REPORT

Innovative Technique for Below the Knee Arterial Revascularisation Using Porcine Self Made Stapled Pericardial Tube Grafts

Elisabeth Côté ^{a,*}, Rafael Trunfio ^a, Celine Deslarzes-Dubuis ^a, Kenneth Tran ^{a,b}, Jean-Marc Corpataux ^{a,1}, Sebastien Déglise ^{a,1}

^a Department of Vascular Surgery, University Hospital (CHUV), University of Lausanne, Lausanne, Switzerland

^b Division of Vascular Surgery, Stanford University School of Medicine, Stanford, CA, USA

Introduction: When no autologous vein is available for distal bypass in the setting of chronic limb threatening ischaemia (CLTI), new alternatives are required to solve the problems of availability, patency, and resistance to infection. An innovative technique of below the knee bypass for CLTI using a porcine self made stapled pericardial tube graft is reported.

Report: An 84 year old man, admitted with right CLTI with foot infection due to long occlusion of the femoropopliteal segment, required urgent revascularisation. In the absence of autologous vein and cryopreserved vessels, a 4 mm self made stapled porcine pericardial tube graft 56 cm long was created from two 14 × 8 cm patches, to perform a femorotibioperoneal trunk bypass. On day 10, bypass thrombectomy and balloon angioplasty of the distal anastomosis were needed to treat early occlusion. Oral anticoagulation was then started. Right toe pressure increased from 0 to 70 mmHg, and no infection was reported. Complete wound healing was achieved. At six months, the bypass was still patent.

Discussion: The use of porcine self made stapled pericardial tube grafts could offer new options for revascularisation in CLTI. Larger cohort studies with longer follow up are needed to confirm this successful preliminary experience.

© 2020 The Author(s). Published by Elsevier Ltd on behalf of European Society for Vascular Surgery. This is an open access article under the CC BY-NC-ND license (<http://creativecommons.org/licenses/by-nc-nd/4.0/>).

Article history: Received 22 March 2020, Revised 4 June 2020, Accepted 15 June 2020,

Keywords: Chronic limb threatening ischaemia, Distal bypass, Pericardial tube

INTRODUCTION

Chronic limb threatening ischaemia (CLTI) is a serious condition associated with a 25% risk of limb loss at one year when left untreated.¹ According to the Global Vascular Guidelines for the management of CLTI, revascularisation should be offered to all average risk patients with advanced limb threatening conditions and significant perfusion deficits.¹ Open surgery should be considered in patients with advanced limb threat, in highly complex disease, and after failed endovascular attempts,¹ especially when autologous vein is available.^{1,2} As the other options for bypass material, such as prosthesis and cryopreserved arterial or venous allografts, raise some concerns regarding patency, infection risk, and availability,^{2,3} new solutions have to be found.

Self made animal pericardial tubes have been used for many years in infected aortic graft surgery, showing superior biocompatibility and reduced infection rates over prosthetic material.^{4–6} Recently, the successful use of a self made pericardial tube in the setting of lower limb bypass infection has been reported.⁷

An innovative surgical technique for below the knee bypass using self made stapled pericardial tube grafts with off the shelf porcine patches, for when urgent repair is needed and no autologous vein is available, is reported herein.

REPORT

An 84 year old man with a history of diabetes, hypertension, atrial fibrillation, and ischaemic heart disease, orally anticoagulated with Apixaban, was admitted with right CLTI with toe gangrene and foot infection, requiring urgent revascularisation. Right toe pressure was 0 mmHg. Pre-operative imaging revealed a long segment occlusion of the superficial femoral and popliteal arteries to the tibioperoneal trunk. The right saphenous vein had been used for previous left distal bypass and the left one was unusable, as were the upper limb veins. Moreover, no cryopreserved arterial or venous allografts were available at the time of operation.

¹ The two last authors contributed equally to this work.

* Corresponding author. Service de Chirurgie Vasculaire, Centre Hospitalier Universitaire Vaudois, Rue du Bugnon 46, 1011 Lausanne, Switzerland.

E-mail address: elisabeth.cote@chuv.ch (Elisabeth Côté).

2666-688X/© 2020 The Author(s). Published by Elsevier Ltd on behalf of European Society for Vascular Surgery. This is an open access article under the CC BY-NC-ND license (<http://creativecommons.org/licenses/by-nc-nd/4.0/>).

<https://doi.org/10.1016/j.ejvsf.2020.06.002>

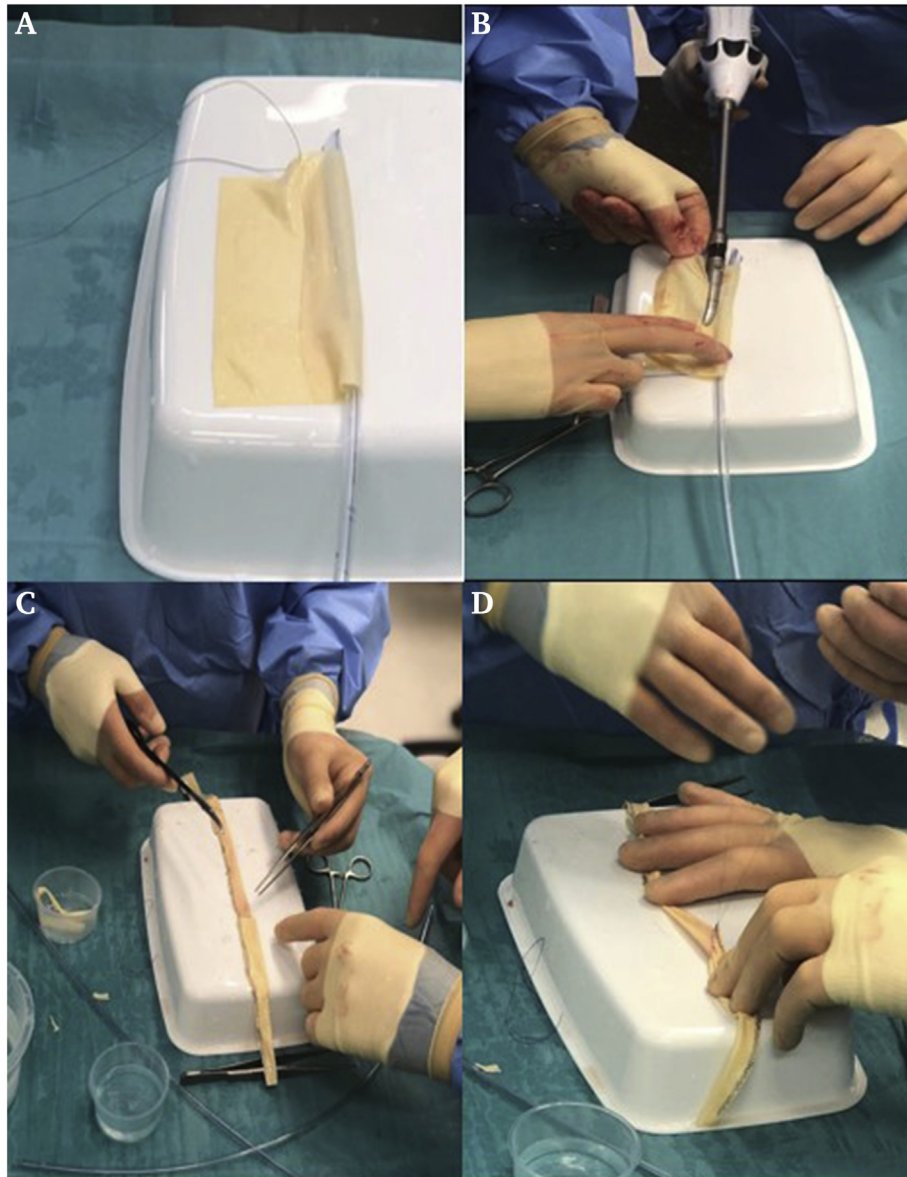


Figure 1. Self made porcine pericardial tube grafts of 14×8 cm off the shelf patches. (A) A 14×8 cm BioIntegral patch is rolled over a 12 F chest tube. (B) An Echelon Flex of 35 mm stapler was used for creation of the pericardial tube. (C) Four tube grafts were made using two 14×8 cm patches and 13 chargers of Echelon staples. (D) The different newly made tubes were sutured together end to end with 5–0 Prolene.

In order to perform a femorotibioperoneal trunk bypass, a self made stapled pericardial tube graft with a diameter of 4 mm and length of 56 cm was created from two 14×8 cm pericardial porcine patches (No-react; BioIntegral Surgical, Mississauga, ON, Canada). Four conduits with a length of 14 mm were created over a 12 F chest tube using an Echelon Flex Powered Vascular 35 mm stapler (Ethicon, Somerville, MA, USA) (Fig. 1). The four stapled pericardial conduits were then sutured together end to end using 5–0 polypropylene sutures (Prolene; Ethicon) (Fig. 1). Using a two team approach, the conduit was created in the operation room simultaneously during exposure of the proximal and distal arterial targets.

Once the proximal anastomosis to the common femoral artery had been completed, declamping allowed for bypass evaluation. Complete haemostasis of the pericardial tube was achieved using around five additional stitches at sites where some oozing was seen. The conduit was then tunnelled anatomically to the tibioperoneal trunk for the distal anastomosis. A Medistim flow probe (MCM MEDSYS, Oslo, Norway) demonstrated a flow rate of 55 mL/minute. The total duration of the operation was 174 minutes. It took less than five minutes to create the four tubes with the staplers. Then, they had to be sutured together end to end; each anastomosis took five minutes. Additional stitches were done after completion of the proximal

anastomosis, which required around five minutes. Therefore, it took a little more than 20 minutes to create the 56 cm tube.

On day seven, the post-operative angiography examination revealed a severe stenosis of a previous contralateral bypass. A crossover angioplasty using a drug coated balloon was performed with introduction of clopidogrel. Oral anti-coagulation was stopped owing to a right groin haematoma. Three days later, the recently made right lower limb bypass occluded, requiring a surgical thrombectomy. A stenosis of the distal anastomosis was found and treated by drug coated balloon. Right toe pressure increased from 0 to 70 mmHg. Oral anticoagulation was started again and the patient returned home a few days later. At the six month follow up, the bypass was patent (Fig. 2), no infection was reported and complete wound healing had been achieved.

DISCUSSION

A suitable single segment vein is lacking in about one third of patients requiring distal revascularisation.² The need for alternative conduits has become increasingly evident, particularly when multiple procedures are required for long term limb salvage.² Animal pericardial material has been used increasingly in vascular reconstruction over the last two decades, especially for patch angioplasty of the femoral or carotid artery. It confers several advantages over

prosthetic material, including superior biocompatibility, easy handling, less suture bleeding, and reduced infection rate.⁴⁻⁶

Many studies have reported self made animal pericardial tube grafts used for native or graft aortic infection.⁶⁻⁹ Czerny et al. reported a case series of 15 patients treated successfully with bovine pericardium.⁴ They presented good results in term of durability, with a mean follow up of 24 months, offering an additional alternative to cryopreserved arterial allografts. Hostalrich et al.⁵ showed encouraging results regarding durability, freedom from re-infection, and freedom from re-intervention in their systematic review of self made pericardial tube grafts in the setting of aortic infection.

In the recently published European Society of Vascular Surgery guidelines, pericardial tubes were considered a suitable alternative in the setting of aortic graft infection, but no recommendation was made owing to insufficient data.¹⁰ Pericardial tubes could be a useful option in urgent revascularisation because of their availability and adjustability. Very recently, a case of replacement of an infected femoropopliteal bypass segment was published, which showed that the concept of a homemade tube graft can be extended to the infra-inguinal level.⁷

In this context, the use of a long porcine self made stapled pericardial tube graft as an alternative option for below the knee bypass in CLTI is reported here. Self made pericardial tube grafts using off the shelf patches allow adaptation to any anatomy with customised diameter and length, by suturing multiple patches together.^{4,8} This innovative technique seems to confer several advantages.

The first advantage is the variety of designs that can be tailored,⁶ allowing the creation of tapered tubes, well adapted to the small calibre of distal vessels distally and to the larger one proximally. This tapered shape does not exist among the alternative graft materials such as prostheses, arterial allografts, or even pericardial pre-sewn conduits, which will soon be on the market. Another favourable point is the operation time, which can be saved using this approach. Tubularised grafts can be rapidly and easily constructed using vascular staplers. The time required to perform such a tube with running sutures was not evaluated, but it is estimated that the total time could be more than 45 minutes. Although the stapler technique could be time saving, the mechanical properties of this innovative graft, such as resistance, durability, and compliance, should be further investigated and compared with running sutures and also to the pre-sewn conduits. Unfortunately, the latter are not currently available in Switzerland.

Although this technique seems to have some important advantages, it also raises some concerns, especially regarding haemostasis and costs. Indeed, some form of oozing in some parts of the stapler lines was observed after proximal declamping. It stopped quickly, but when it continued to ooze, around five extra stitches were needed to ensure complete haemostasis. Once complete haemostasis was achieved, the graft was tunnelled into the anatomical position through a "tunneller", which consisted

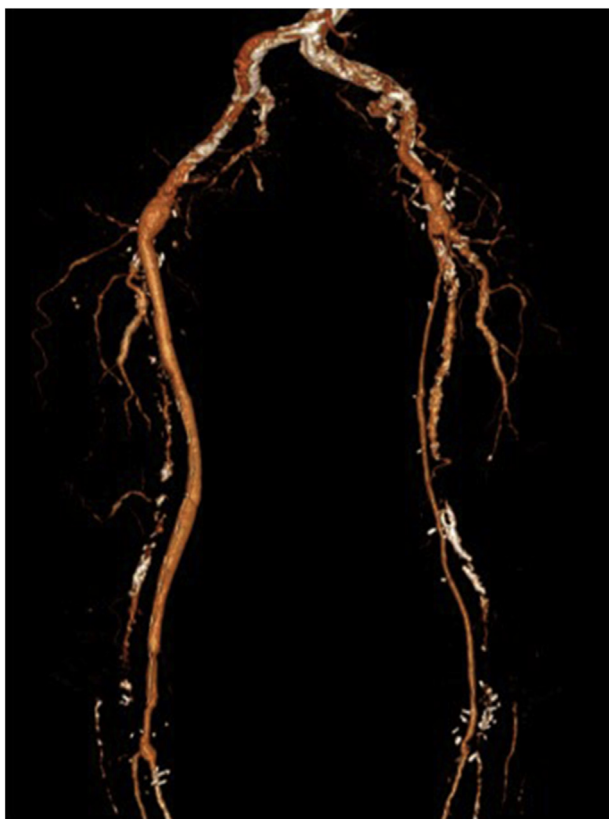

Figure 2. Three dimensional computed tomography angiography scan showing a patent right femorotibioperoneal trunk self made porcine pericardial tube bypass one month post-operatively.

of a metal tube, avoiding any friction between the graft and the surrounding tissue.

The total costs for such a pericardial tube was around €5 800, taking in account the two 14 × 8 cm pericardial porcine patches, the stapler, and the 13 chargers. These costs could be reduced using longer staplers of 60 mm, thus requiring fewer chargers. Even if it seems to be expensive, it stays in the range of the costs of arterial allografts (€1 000 per 10 cm).

Finally, the presence of metallic staples in contact with blood raises the question of thrombogenicity. There is no consensus about antiplatelet or anticoagulation therapy in self made pericardial tube grafts. As early bypass occlusion in the absence of adequate anti-coagulation was experienced, it is thought that such patients should benefit from oral anticoagulation for at least three months.

CONCLUSION

In emergency or infection settings, porcine self made stapled pericardial tube graft could be considered as an alternative conduit for below the knee bypass for CLTI treatment, when no autologous vein is available. However, larger cohort studies with longer follow up are needed to confirm the safety and durability of this innovative technique.

FUNDING

None.

CONFLICT OF INTEREST

None.

REFERENCES

- Conte MS, Bradbury AW, Kohl P, White JV, Dick F, Fitrudge R, et al. Global vascular guidelines on the management of chronic limb-threatening ischemia. GVG writing group for the joint guidelines of the society for vascular surgery (SVS), European society for vascular surgery (ESVS) and world federation of vascular societies (WFVS). *Eur J Vasc Endovasc Surg* 2019;**58**: S1–109.
- Faries PL, LoGerfo FW, Arora S, Hook S, Pulling MC, Akbari CM, et al. A comparative study of alternative conduits for lower extremity revascularization: all-autogenous conduit versus prosthetic grafts. *J Vasc Surg* 2000;**32**:1080–90.
- Masmejan S, Deslarzes-Dubuis C, Petitprez S, Longchamp A, Haller C, Déglise S, et al. Ten year experience of using cryopreserved arterial allografts for distal bypass in critical limb ischemia. *Eur J Vasc Endovasc Surg* 2019;**57**:823–31.
- Czerny M, von Allmen R, Opfermann P, Sodeck G, Dick F, Stellmes A, et al. Self-made pericardial tube graft: a new surgical concept for treatment of graft infections after thoracic and abdominal aortic procedures. *Ann Thorac Surg* 2011;**92**: 1657–62.
- Hostalrich A, Ozdemir BA, Sfeir J, Solovei L, Alric P, Canaud L. Systematic review of native and graft-related aortic infection outcome managed with orthotopic xenopericardial grafts. *J Vasc Surg* 2018;**69**:614–8.
- Weiss S, Tobler EL, von Tengg-Kobligk H, Makaloski V, Becker D, Carrel TP, et al. Self made xeno-pericardial aortic tubes to treat native and aortic graft infections. *Eur J Vasc Endovasc Surg* 2017;**54**:646–52.
- Del Tatto B, Saucy F. A new homemade stapled vascular tube graft. *Eur J Vasc Endovasc Surg* 2020;**59**:320–1.
- Kohler C, Attigah N, Demirel S, Zientara A, Weber M, Schwegler I. A technique for a self-made bifurcated graft with bovine pericardial patch in infectious vascular reconstruction. *J Vasc Surg* 2016;**2**:158–60.
- Lutz B, Reeps C, Biro G, Knappich AZ, Eckstein HH. Bovine pericardium as new technical option for in situ reconstruction of aortic graft infection. *Ann Vasc Surg* 2017;**41**:118–26.
- Chakfé N, Diener H, Lejay A, Assadian O, Berard X, Caillon J, et al. Editor's choice-European society for vascular surgery (ESVS): clinical practice guidelines on the management of vascular graft and endograft infections. *Eur J Vasc Endovasc Surg* 2020;**59**:339–84.