



The “Sombrero-Shape” Super-Thin Pedicled ALT Flap for Complete Scrotal Reconstruction Following Fournier’s Gangrene

Gianluca Sapino, MD¹ Stephanie Gonvers, MSc¹ Mario Cherubino, MD² Pietro G. di Summa, MD, PhD¹

¹Department of Plastic and Hand Surgery, Lausanne University Hospital (CHUV), University of Lausanne, Lausanne, CH, Switzerland

²Department of Plastic, Reconstructive and Hand Surgery, Varese University Hospital, Varese, Italy

Address for correspondence Pietro G. di Summa, MD, PhD, Department of Plastic and Hand surgery, Lausanne University Hospital (CHUV), BH10, Room 933, Rue du Bugnon 46, 1011 Lausanne, CH, Switzerland (e-mail: pietro.di-summa@chuv.ch).

Arch Plast Surg 2022;49:453–456.

Abstract

When the scrotal sac is entirely debrided following a Fournier gangrene, testes exposure poses unique challenges for the reconstructive surgeon. Despite the antero-lateral thigh (ALT) flap is considered a workhorse in such context, aesthetic results are often suboptimal because of the lack of natural ptosis and patchwork appearance. We describe the use of a super-thin pedicled ALT flap for total scrotal reconstruction, modified according to a peculiar flap design and inset technique. A 42-year-old man was referred to our department for delayed total scrotal reconstruction 8 months after a Fournier gangrene extensive debridement. A super-thin pedicled ALT flap from the right thigh was designed: in the central portion of the ALT, a lateral skin paddle extension was marked to guarantee adequate posterior anchorage during inset and ptosis of the scrotal sac. This particular flap arrangement has inspired the name “sombrero” as the shape is akin to the famous hat. No secondary refinements were needed, and the patient showed satisfying aesthetic and functional results at 12 months’ follow-up. The ALT flap design “sombrero” modification proposed in this article can improve scrotum cosmesis and patient satisfaction in a single-stage single-flap procedure.

Keywords

- ▶ surgical flaps
- ▶ Fournier gangrene
- ▶ reconstructive surgical procedures

Fournier’s gangrene is a necrotizing fasciitis affecting skin and soft tissues of the perineum and external genitalia. Despite medical and surgical advancements, the mortality rate associated with this pathology remains high. This rapidly progressing life-threatening infection advocates the need for immediate administration of broad-spectrum antibiotherapy and radical surgical debridement.¹

When the scrotal sac is entirely debrided, testes exposure poses unique challenges for the reconstructive surgeon. Indeed, because of the peculiar characteristics of the

scrotum skin and function, neo-scrotal reconstruction can be particularly demanding to provide satisfactory outcomes.

Different surgical techniques have been proposed so far to address such complex scenarios including skin grafts,² local pedicled flaps,^{3,4} and free flaps.^{5,6} The ideal reconstruction should include thin and pliable tissue, with a reliable vascularity and an accessible surgical technique. Moreover, the peculiar characteristics of the scrotum, such as a dual-chambered ptotic sac divided by a median raphe, should

DOI <https://doi.org/10.1055/s-0042-1748663>.
ISSN 2234-6163.

© 2022. The Korean Society of Plastic and Reconstructive Surgeons. All rights reserved.

This is an open access article published by Thieme under the terms of the Creative Commons Attribution-NonDerivative-NonCommercial-License, permitting copying and reproduction so long as the original work is given appropriate credit. Contents may not be used for commercial purposes, or adapted, remixed, transformed or built upon. (<https://creativecommons.org/licenses/by-nc-nd/4.0/>)

Thieme Medical Publishers, Inc., 333 Seventh Avenue, 18th Floor, New York, NY 10001, USA

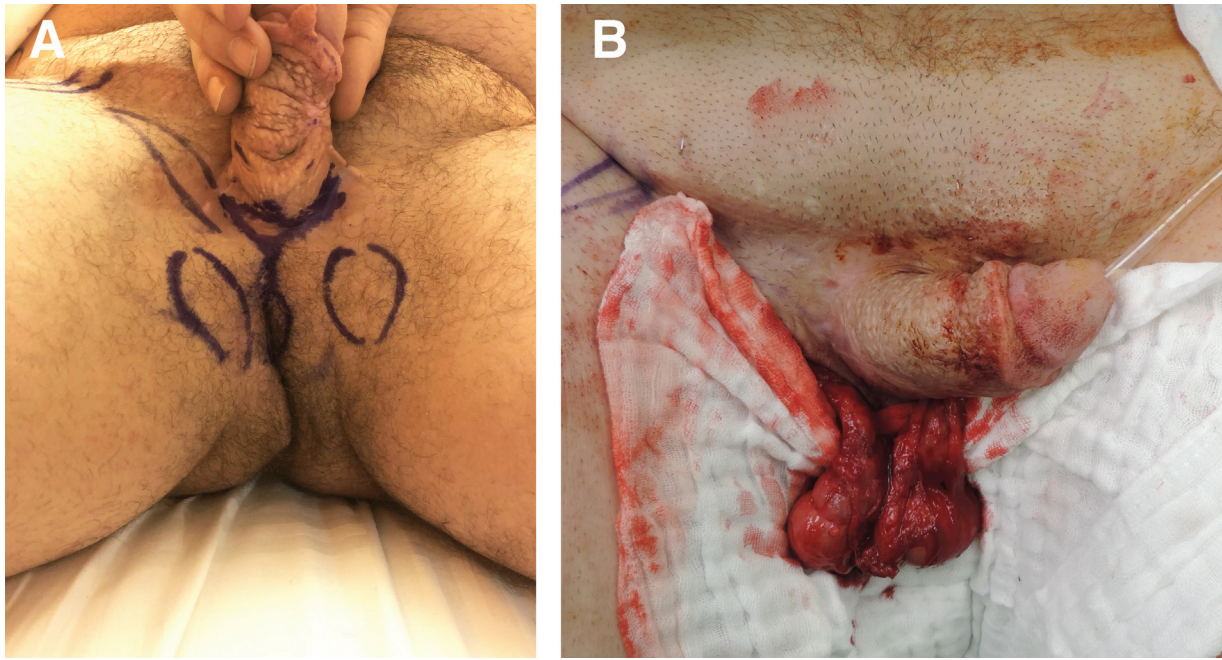


Fig. 1 (A) A 42 years old male came to our department seeking for scrotal reconstruction following Fournier's gangrene debridement and testes burial in the inner thighs. (B) Testes reexposure by the urologic team during the reconstructive surgery.

be ideally taken into account to optimize the aesthetic outcome.⁷

The pedicled anterolateral thigh (ALT) flap represents a well-known option for perineal reconstruction of large defects.¹ Furthermore, the flap can be meticulously thinned at the level of the superficial fascia, enabling to obtain a thin and pliable flap with minimal adipose tissue layer.⁸ In scrotal reconstruction, however, aesthetic results of previous reports⁹⁻¹² are often suboptimal because of the lack of natural ptosis and patchwork appearance.

Herein, we describe the use of a super-thin pedicled ALT flap for total scrotal reconstruction. A flap design modification and a peculiar inseting technique are proposed and discussed in detail.

Case

A 42-year-old male patient (intravenous drug abuser, smoker, obese, and alcoholic) sustained a Fournier's gangrene with full skin necrosis of the scrotum, penile shaft skin, and pubic area. After aggressive debridement by the urologic surgeons, a split-thickness skin graft was used to cover the penile shaft and pubic area, while testes exposure was simply treated by burying the testes in the inner thighs (→ Fig. 1A).

Eight months after discharge, the patient reported significant pain while walking, due to testicles being compressed within the inner thighs and was referred to our plastic surgery department for total scrotal reconstruction.

To relocate testicles back to their anatomical position, a super-thin ALT flap from the right thigh was designed: in the central portion of the ALT, a lateral skin flap extension was marked to guarantee adequate ptosis (→ Fig. 2). This particular flap arrangement has inspired the name "sombbrero" as the shape is akin to the famous hat.

Flap dimensions were 25 × 11 cm. Flap harvesting and dissection were performed according to previous literature.^{13,14} The plan of flap dissection was above the superficial fascia, while deepening in regard of the selected perforator. Once retrieved the testes from the medial thigh

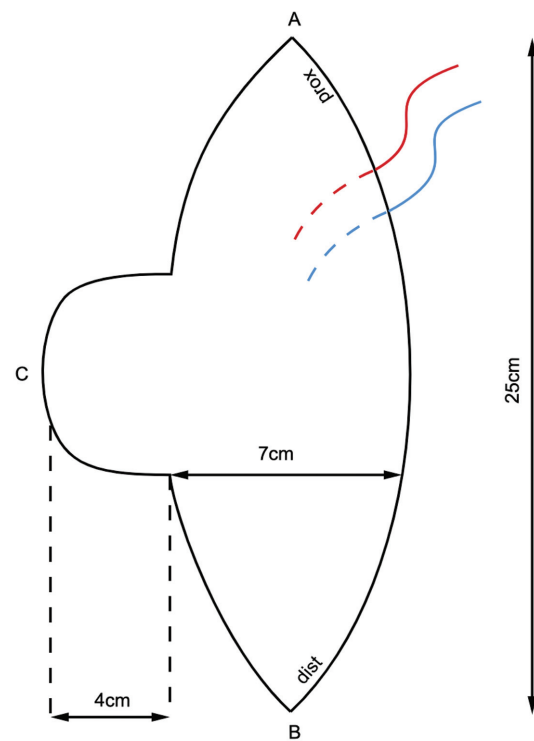


Fig. 2 Schematic drawing showing the "sombbrero-shaped" anterolateral thigh (ALT) flap: in the central portion of the ALT, a lateral skin flap extension (C) was used to guarantee adequate ptosis.

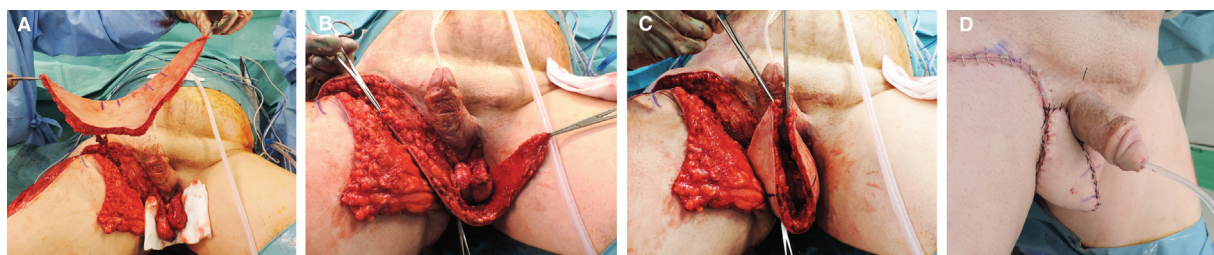


Fig. 3 (A) A pedicled “sombbrero-shaped” super-thin anterolateral thigh (ALT) flap was harvested from the right thigh. (B, C) The flap was self-folded in such way that proximal and distal extremities were sutured to the right and left penis’ sides; the medial flap borders were sutured together to recreate a median raphe anteriorly. The lateral flap extension (the tip of the “sombbrero”) was anchored posteriorly to the perineal muscles, allowing a natural ptosis of the neo-scrotum. (D) Immediate postop result.

pockets (►Fig. 1B), the flap was transposed to the perineal region passing under the rectus femoris and the sartorius muscles. Flap inset was performed as follows: the flap was self-folded in such way that proximal and distal extremities were sutured to the right and left penis’ sides; the medial flap borders were sutured together to recreate a median raphe anteriorly. The lateral flap extension (the tip of the “sombbrero”) was anchored posteriorly to the perineal muscles, allowing a natural ptosis of the neo-scrotum (►Fig. 3).

A 4 × 3 cm split-thickness skin graft was used for partial donor site closure. The operative time was 5 hours and 31 minutes. Given favorable clinical evolution, the patient was discharged 2 weeks postoperatively.

No major postoperative complications were recorded, while a donor site seroma developed 1 month postoperatively was treated conservatively in the outpatient clinic. At 6 months’ follow-up, the patient showed satisfying aesthetic and functional outcomes, with complete unpainful sexual intercourses (►Fig. 4).

Discussion

While in older patients perineal cosmesis following Fournier gangrene debridement may not be a primary concern, for

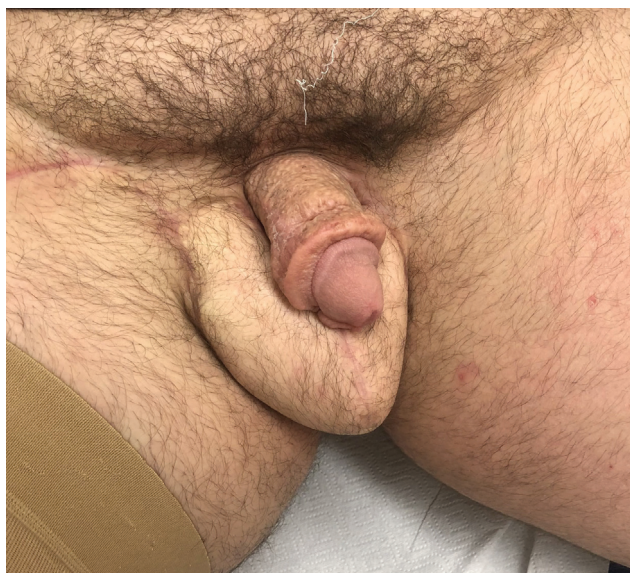

Fig. 4 Postoperative results at 6 months.

younger patients the final appearance and sexual function are of paramount importance and should be considered when performing the reconstruction.

If part of the scrotum is still available, local options are often sufficient for satisfactory scrotal reconstruction: scrotal advancement flap can ideally replace the scrotal bag “like-with-like.”¹⁴

On the contrary, when the entire scrotal compartment needs reconstruction, more complex procedures are often needed. Despite burying testis in subcutaneous thigh pouches is a feasible option in the acute setting, it cannot be considered a definitive solution: fainting attacks, testicular atrophy, sense of fullness, and unacceptable appearances are among the most important reasons why a proper reconstruction is required.¹²

When testes and spermatic cords are completely exposed, skin graft coverage may result unsightly and is prone to severe scar contracture, bacterial contamination, and maceration with delayed healing.⁹

Inner thigh-based reconstructions (e.g., pudendal flaps) are good alternatives, however, in obese patients flap bulkiness can harm the quality of reconstruction as impeding testes thermogenesis,¹⁵ while potential tethering of the scrotum–thigh junction can lead to chronic pain and need for further revision surgery.⁹ Furthermore, bilateral flap harvesting may be needed for large defects, increasing donor site morbidity and operative time.^{11,16} In our specific case, testes’ burial and multiple perineal scarring could have jeopardized inner-thigh vascularization and therefore inner thigh flaps were considered not reliable.

Muscle flaps, such as the gracilis muscle flap, are an option.⁴ Nevertheless, those flaps lack in size and a bilateral procedure is required for complete scrotal reconstruction, doubling the operative time and the risk of donor site complications. A skin graft over the muscle is necessary, adding supplementary scarring and prolonged wound healing. Moreover, muscle atrophy over time is expected and the sacrifice of functioning muscles is necessary.

The ALT flap is a perforator skin flap that leaves the muscle essentially intact, thereby minimizing donor site morbidity.¹⁷

Its application in scrotal and perineal reconstruction dates back to 2002.^{18,19} When addressing perineal reconstruction after Fournier gangrene, the ALT provides several advantages: it supplies a reliable amount of pedicled soft

tissue which is far from the debrided area and thus not jeopardized, the flap pedicle is sufficiently long and enables the flap to be placed in a wide range with minimal limitations in rotation angles. Besides, ALT tissue is hair-bearing and attributes reliable testes protection. On the other side, flap bulkiness can make flap inset more difficult and be inconvenient for patients while walking, especially when used in the perineal area.

Thanks to microsurgical techniques advancements however, the ALT flap can now be harvested in a super-thin fashion, enabling the surgeon to model the tissue to the optimal thickness.¹⁴ This can be particularly important in obese patients in which an overrepresented subcutaneous tissue can affect the viability of the reconstruction, as previously stated.

The “sombbrero-shape” ALT design increases the surface of skin tissue available thus allowing the reconstruction of a natural-looking scrotum, with a physiological ptosis and a median scrotal raphe, avoiding the need for a two-flap technique²⁰ even for total reconstructions.

To the best of our knowledge, this case represents the first super-thin pedicled ALT flap use for complete scrotal reconstruction described in literature. The ALT flap design “sombbrero” modification proposed in this article can improve scrotum cosmesis and patient satisfaction in a single-stage single-flap procedure.

Author Contributions

Conceptualization: P.G.d.-S., G.S., and M.C. Data curation: S.G. and G.S. Formal analysis: P.G.d.-S., G.S., and M.C. Methodology: S.G., G.S. and P.G.d.-S. Writing-original draft: S.G., G.S. and P.G.d.-S.

Patient Consent

Patient’s informed written consent was obtained for use of photos. Patient data were treated according to the Declaration of Helsinki as modified in 2013.

Conflict of Interest

None declared.

References

- Lin CT, Chang SC, Chen SG, Tzeng YS. Reconstruction of perineo-scrotal defects in Fournier’s gangrene with pedicle anterolateral thigh perforator flap. *ANZ J Surg* 2016;86(12):1052–1055
- Maguiña P, Palmieri TL, Greenhalgh DG. Split thickness skin grafting for recreation of the scrotum following Fournier’s gangrene. *Burns* 2003;29(08):857–862
- Mopuri N, O’Connor EF, Iwuagwu FC. Scrotal reconstruction with modified pudendal thigh flaps. *J Plast Reconstr Aesthet Surg* 2016;69(02):278–283
- Daigeler A, Behr B, Mikhail BD, Lehnhardt M, Wallner C. Bilateral pedicled gracilis flap for scrotal reconstruction. *J Plast Reconstr Aesthet Surg* 2016;69(09):e195–e196
- Teven CM, Yu JW, Zhao LC, Levine JP. Extended medial sural artery perforator free flap for groin and scrotal reconstruction. *Arch Plast Surg* 2020;47(04):354–359
- Makino Y, Matsumine H, Fujimaki H, Takagi M, Takeuchi M. Reconstruction of the necrotic scrotum with hydrosurgery system and pedicle DIEP flap: a case report of Fournier gangrene. *Plast Reconstr Surg Glob Open* 2020;8(09):e3135
- Mahadevan V, Chandak P. The surgical anatomy of the perineum. *J R Army Med Corps* 2013;159(Suppl 1):i10–i14
- Hyakusoku H, Gao JH. The “super-thin” flap. *Br J Plast Surg* 1994;47(07):457–464
- Lee SH, Rah DK, Lee WJ. Penoscrotal reconstruction with gracilis muscle flap and internal pudendal artery perforator flap transposition. *Urology* 2012;79(06):1390–1394
- El-Sabbagh AH. Coverage of the scrotum after Fournier’s gangrene. *GMS Interdiscip Plast Reconstr Surg DGPW* 2018;7:Doc01
- Kadota H, Momii K, Hanada M, et al. Simultaneous deep inferior epigastric and bilateral anterolateral thigh perforator flap reconstruction of an extended perineoscrotal defect in Fournier’s gangrene: a case report. *Microsurgery* 2019;39(03):263–266
- Khanal B, Agrawal S, Gurung R, Sah S, Gupta RK. Pudendal flap—a good option for creating neo-scrotum after Fournier’s gangrene: a case series. *J Surg Case Rep* 2020;2020(11):a414
- Hong JP, Choi DH, Suh H, et al. A new plane of elevation: the superficial fascial plane for perforator flap elevation. *J Reconstr Microsurg* 2014;30(07):491–496
- Guiotto M, Watfa W, Raffoul W, di Summa PG. Anterolateral thigh flap with vascularized fascia lata associated with thigh flaps: a case report of an all-in-one reconstruction of the suspensory ligament and penoscrotal district after Fournier gangrene. *Ann Plast Surg* 2020;85(06):e44–e47
- Wang D, Wei Z, Sun G, Luo Z. Thin-trimming of the scrotal reconstruction flap: long-term follow-up shows reversal of spermatogenesis arrest. *J Plast Reconstr Aesthet Surg* 2009;62(11):e455–e456
- Yao H, Zheng D, Wen J, et al. Reconstruction of major scrotal defects by anterolateral thigh flap. *Cell Biochem Biophys* 2014;70(02):1331–1335
- di Summa PG, Sapino G, Cherubino M, et al. Reconstruction of complex soft tissue defects including tendons with anterolateral thigh flap extended to fascia lata: long term recovery and functional outcomes. *Microsurgery* 2019;39(05):405–415
- Spyropoulou GA, Jeng SF, Demiri E, Dionyssopoulos A, Feng KM. Reconstruction of perineoscrotal and vaginal defects with pedicled anterolateral thigh flap. *Urology* 2013;82(02):461–465
- di Summa PG, Tremp M, Meyer Zu Schwabedissen M, Schaefer DJ, Kalbermatten DF, Raffoul W. The combined pedicled anterolateral thigh and vastus lateralis flap as filler for complex perineal defects. *Ann Plast Surg* 2015;75(01):66–73
- Dayan JH, Clarke-Pearson EM, Dayan E, Smith ML. Aesthetic scrotal reconstruction following extensive Fournier’s gangrene using bilateral island pedicled sensate anterolateral thigh flaps: a case report. *Can Urol Assoc J* 2014;8(1-2):E114–E117