

BRIEF COMMUNICATION

Antibodies to TRIM46 are associated with paraneoplastic neurological syndromes

Marleen H. van Coevorden-Hameete^{1,2}, Sam F.B. van Beuningen¹, Matthieu Perrenoud³, Lena M. Will¹, Esther Hulsenboom², Jean-Francois Demonet⁴, Lidia Sabater⁵, Johan M. Kros⁶, Jan J.G.M. Verschuuren⁷, Maarten J. Titulaer², Esther de Graaff¹, Peter A.E. Sillevs Smitt² & Casper C. Hoogenraad¹

¹Cell Biology, Department of Biology, Faculty of Science, Utrecht University, Padualaan 8, 3584 CH, Utrecht, The Netherlands

²Department of Neurology, Erasmus University Medical Center, Dr. Molewaterplein 40, 3015 GD, Rotterdam, The Netherlands

³Service of Neurology, Centre Hospitalier Universitaire Vaudois (CHUV), Chemin du Mont-Paisible 16, CH 1011, Lausanne, Switzerland

⁴Leenaards Memory Centre, Department of Clinical Neurosciences, Centre Hospitalier Universitaire Vaudois (CHUV), Chemin du Mont-Paisible 16, CH 1011, Lausanne, Switzerland

⁵Institut d'Investigació Biomèdica August Pi i Sunyer (IDIBAPS), Carrer del Rosselló 149, 08036, Barcelona, Spain

⁶Department of Pathology, Erasmus University Medical Center, Dr. Molewaterplein 40, 3015 GD, Rotterdam, The Netherlands

⁷Department of Neurology, Leiden University Medical Center, Albinusdreef 2, 2333 ZA, Leiden, The Netherlands

Correspondence

Peter A.E. Sillevs Smitt, Department of Neurology, Room H639, Erasmus MC, 's-Gravendijkwal 230, 3015 CE Rotterdam, the Netherlands. Tel: +31107033327; Fax: +31107033208;

E-mail: p.sillevismitt@erasmusmc.nl and

Casper C. Hoogenraad, Cell Biology, Department of Biology, Faculty of Science, Utrecht University, Padualaan 8, 3584 CH Utrecht, the Netherlands. Tel: +31302534585; Fax: +31302532837; E-mail: c.hoogenraad@uu.nl

Abstract

Paraneoplastic neurological syndromes (PNS) are often characterized by the presence of antineuronal antibodies in patient serum or cerebrospinal fluid. The detection of antineuronal antibodies has proven to be a useful tool in PNS diagnosis and the search for an underlying tumor. Here, we describe three patients with autoantibodies to several epitopes of the axon initial segment protein tripartite motif 46 (TRIM46). We show that anti-TRIM46 antibodies are easy to detect in routine immunohistochemistry screening and can be confirmed by western blotting and cell-based assay. Anti-TRIM46 antibodies can occur in patients with diverse neurological syndromes and are associated with small-cell lung carcinoma.

Funding information

This study was funded by NUTS-OHRA (1104-034), Hersenstichting (2012(1)-141).

Received: 22 January 2017; Accepted: 25 January 2017

Annals of Clinical and Translational Neurology 2017; 4(9): 680–686

doi: 10.1002/acn3.396

Introduction

Paraneoplastic neurological syndromes (PNS) include a variety of immune-mediated neurological disorders that occur in association with cancer. PNS is caused by an immune reaction directed at an autoantigen that is shared by neurons and cancer cells. Mostly, the neurological symptoms precede the diagnosis of cancer. Early recognition of PNS can facilitate tumor detection and treatment

and thereby increases the chance of stabilizing the neurological symptoms.¹

The immune reaction in PNS is often hallmarked by the presence of antineuronal antibodies in patient serum or cerebrospinal fluid (CSF). The detection of antineuronal antibodies has proven to be a useful tool in PNS diagnosis. Some antineuronal antibodies, such as anti-DNER (Tr), are very syndrome and tumor specific.^{2,3} Others, such as anti-Hu, are associated with a variety of

neurological syndromes but predict an underlying small-cell lung carcinoma (SCLC) in most cases.⁴

Autoantibodies to components of the axon initial segment (AIS) and (para)nodes of Ranvier (NOR) have been reported in PNS and other neurological disorders.^{5–8} The AIS and NOR are molecularly related axonal regions that are involved in the initiation and propagation of action potentials.⁹ Recently, the protein tripartite motif 46 (TRIM46) was found to be the autoantigen in a patient with paraneoplastic encephalomyelitis (PEM) and antibodies to the AIS but not the NOR of the sciatic nerve.^{6,10} TRIM46 localizes specifically to the proximal axon where it bundles parallel microtubules and is important for axon specification and outgrowth during early brain development.¹⁰

Here, we clinically and experimentally characterize three patients with antibodies to TRIM46. We show that TRIM46 antibodies are associated with the presence of a SCLC and can present with a broad clinical variety of central nervous system (CNS) symptoms.

Materials and Methods

Patients with AIS staining were identified in two European PNS laboratories (Erasmus University Medical Center (EMC), Rotterdam, the Netherlands. IDIBAPS, Barcelona, Spain) that test over 2000 samples yearly for the presence of onconeural antibodies. Routine diagnostic testing was performed using immunohistochemistry (IHC) of rat brain slices. The AIS staining patterns of patient 1 and 2 were previously described.^{6,11} This study was approved by the Institutional Review Board of the EMC.

The controls included serum or plasma from 88 anonymous blood bank donors, 20 rheumatoid factor-positive patients, 10 patients with systemic lupus erythematosus, 10 patients with Sjögren's syndrome, 30 patients with anti-Hu antibodies and SCLC and 50 patients with SCLC without neurological symptoms (13 with limited disease, 31 with extensive disease, six with unknown disease severity) that were previously used in Ref. 12

The following antibodies and reagents were used in this study: mouse anti-ankyrinG (Life Technologies, Carlsbad, USA), chicken anti-MAP2 (Abcam, Cambridge, UK), mouse anti-GFP (Roche, Almere, Netherlands), rabbit anti-TRIM46 (in-house, generated as described in¹⁰), and Alexa-405, -488, or -568-conjugated secondary antibodies directed at human, mouse, chicken, or rabbit IgG (Thermo Fisher, Landsmeer, Netherlands). For western blotting, horseradish peroxidase-conjugated donkey anti-human (Calbiochem, Amsterdam, Netherlands) and swine anti-mouse (DAKO, Heverlee, Belgium) were used. For immunohistochemistry, biotin-conjugated goat anti-human IgG antibodies (Vector Laboratories, Youngstown,

USA) and Vectastain Elite ABC complex (Vector Laboratories, Youngstown, USA) were used.

The TRIM46 and TRIM36 DNA clones were kindly provided by Dr. T Cox.¹³ Expression constructs and chimeric constructs were generated in-house by PCR as described in Ref. 10. Primer sequences are available on request. Immunohistochemistry of rat brain slices and SCLC tissue with diaminobenzidine stain was performed essentially as described in Ref. 14. Fluorescent staining of brains from P5 C57BL/6 wild-type mice was performed as described in Ref. 10. Primary hippocampal neuron cultures were obtained according to established procedures.¹⁵ DNA transfection and immunofluorescent staining procedures of HeLa cells and neurons and western blotting were performed as described in Ref. 14. Confocal images were acquired with the Zeiss LSM 700 using the 63× oil objective.

Results

Routine IHC screening for onconeural antibodies revealed serum samples from three patients with staining of the AIS throughout the rat brain (Fig. 1A). Detailed clinical information on these patients can be found in Table 1. Patient 1 presented with PEM and SCLC. Patient 2 presented with cerebellar degeneration and was diagnosed with SCLC 10 months later. Patient 3 presented with rapidly progressive dementia, resembling Creutzfeldt-Jakob disease, without a known underlying tumor. No other antineuronal antibodies were detected. Patient 1 showed no response to oncologic treatment and died of tumor progression 3 months after onset of the neurological symptoms. Patient 2 was lost to follow up and patient 3 died of neurological progression 7 months after onset of the neurological symptoms. At autopsy of the brain from patient 3 showed extensive perivascular and parenchymal CD8⁺ T-cell infiltration.

To verify the specific labeling of the proximal axon, we performed double immune labeling using the patients' sera and the well-known AIS marker ankyrinG (AnkG). The staining pattern of the patients' sera largely colocalized with AnkG both in mouse brain (Fig. 1B) and cultured rat hippocampal neurons (Fig. 1C).

To identify the molecular target of the antibodies, we tested the reactivity of the patients' sera against various AIS proteins. The patients' antibodies did not react with β IV-spectrin and AnkG (data not shown). Also, the patient sera did not label the surface of live hippocampal neurons, as would be expected for antibodies against neurofascin-186 (NF186). All three sera specifically reacted with TRIM46 in a cell-based assay (CBA) (Fig. 1D) and on western blot (Fig. 1E). We tested 208 healthy and

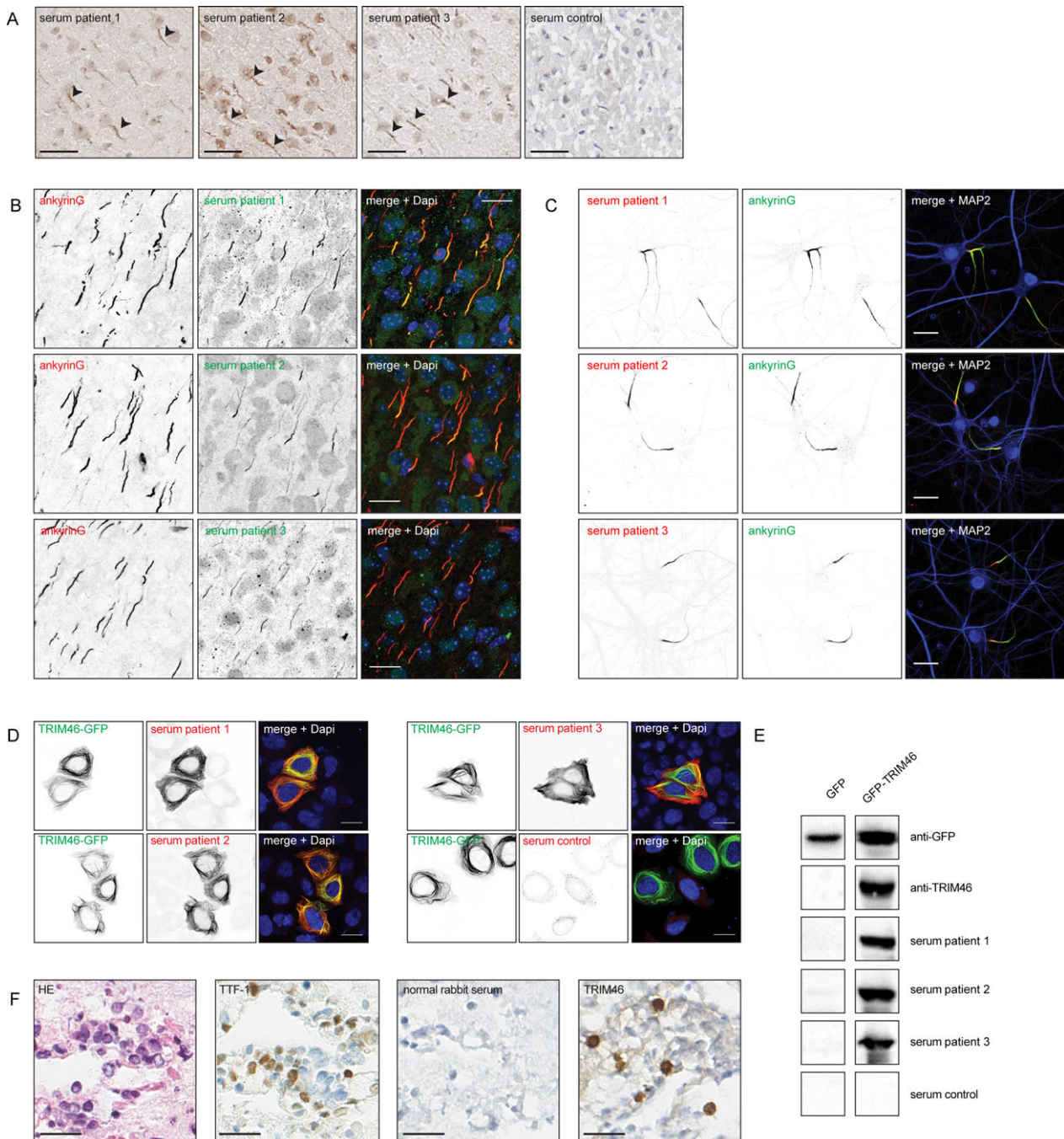


Figure 1. Identification and validation of TRIM46 as neuronal autoantigen. (A) Immunohistochemistry (IHC) of adult rat brains stained with the patients' serum. The figures depict a part of the cortex showing prominent staining of the axon initial segment (AIS) (indicated with arrows) by the patients' sera, which is absent in the staining with healthy control serum. Scale bars: 50 μm (B) IHC of P5 mouse cortex. The patients' sera (green) stain the initial part of the axon and partially colocalize with the AIS marker ankyrinG (red). Scale bars: 20 μm . (C) Immunocytochemistry of cultured rat hippocampal neurons (DIV25). The patients' sera (red) stain the initial part of the axon and partially colocalize with the AIS marker ankyrinG (green) but not with the dendritic marker MAP2 (blue). Scale bars: 20 μm . (D) HeLa cells expressing TRIM46-GFP (green) were fixed, permeabilized and stained with patients' or healthy control sera (red). The patients' sera strongly recognize TRIM46, whereas the control serum does not. Scale bars: 10 μm . (E) Western blots using lysates of HEK cells overexpressing GFP or TRIM46-GFP. The blots were stained with a GFP antibody, TRIM46 antibody, patients' or healthy control sera. The patients' sera recognize TRIM46-GFP on blot but not GFP. (F) IHC of tumor tissue from patient 1, stained with hematoxylin-eosin (HE), the lung carcinoma marker thyroid transcription factor 1 (TTF-1), normal rabbit serum, and TRIM46 antibody. The picture shows TRIM46 expression in a subset of tumor cells. Stainings were performed on sequential slides, pictures were taken in the same area of the sample. Scale bars: 25 μm .

Table 1. Patients' clinical information.

	Patient 1	Patient 2	Patient 3
Gender	Male	Male	Female
Age at disease onset	78 years	64 years	73 years
Neurological syndrome	Progressive encephalomyelitis	Cerebellar ataxia	Rapidly progressive dementia
Main symptoms	Gait instability, change of character, complex partial seizures	Vertigo, nausea, vomiting, truncal ataxia	Mood disorder, rapidly progressive dementia, followed by ataxia, myoclonus, dysarthria, sleep cycle inversion
Tumor	SCLC	SCLC	No tumor on thoraco-abdominal CT-scan
Brain CT/MRI	Normal	Normal	Bilateral hyperintensity (T2, DWI) in the head of the caudate and pallidum, right hippocampus and right anterior cingulate gyrus
EEG	Not performed	Not performed	Progressive diffuse slowing
Blood examination	Na 120 mmol/l (SIADH)	Normal	Normal
CSF examination	1 WBC/ μ L. Normal protein, glucose, and cytology.	25 WBC/ μ L. Normal protein, glucose, and cytology	14 WBC/ μ L. Protein: 0.723 g/L. Normal glucose and cytology. 14-3-3 positive
Paraneoplastic/Neuronal surface antibodies	Negative (Hu, Yo, Ri, Amp)	Negative (Hu, Yo, Ri, Ma1, Ma2, Tr, Amp, NMDAR, AMPAR, GABA _B R, GABA _A R, LGI1, CASPR2, DPPX, GlycineR, Zic4, Sox1, CRMP5, GAD65, VGCC)	Negative (Hu, Yo, Ri, Ma1, Ma2, Tr, Amp, NMDAR, AMPAR, GABA _B R, GABA _A R, LGI1, CASPR2, DPPX, GlycineR, VGKC, Zic4, Sox1, CRMP5, GAD65)
Treatment	Etoposide (1 cycle)	Unknown	No
Neurological response to treatment	No	Unknown	N.A.
Brain autopsy	Not performed	Not performed	Perivascular and parenchymal CD8 ⁺ infiltration. Most prominent in limbic regions. Extensive neuronal loss. No evidence for CJD
Disease course	Change of character, gait instability and complex partial seizures developed over weeks. Diagnosis of SCLC (extensive disease). After one cycle of etoposide, the tumor progressed and the patient died 3 months after onset of symptoms	Subacute cerebellar and brainstem symptoms. Diagnosis of SCLC was made 10 months after onset of symptoms. Patient was lost to follow up	Rapidly progressive dementia mimicking CJD. No tumor was found. Patient died of neurological progression 7 months after onset of symptoms

SCLC, small-cell lung carcinoma; CJD, Creutzfeldt-Jakob disease; SIADH, syndrome of inappropriate ADH secretion. WBC, white blood cells.

disease controls of which none reacted with TRIM46 in a CBA (Fig. 1D, data not shown).

To test whether the immune reaction could have been triggered by aberrant expression of TRIM46 by the SCLC, we performed IHC on the SCLC tissue of patient 1. The patient's tumor tissue showed specific TRIM46 expression (Fig. 1F).

Next, we mapped the epitopes of the patients' antibodies using chimeric constructs of GFP-TRIM46 and -TRIM36. TRIM36 is a family member that is highly similar to TRIM46¹³ but does not localize to axonal microtubules and is not recognized by the patients' antibodies. By swapping domains of TRIM46 with the corresponding regions of TRIM36, we were able to identify the specific domains to which the anti-TRIM46 antibodies

are directed. All three patients had multiple epitopes on the B-box, coiled-coil, and C-terminal domains of TRIM46 (Fig. 2).

Conclusion and Discussion

In this article, we describe a novel onconeurological antibody directed at the AIS protein TRIM46. We clinically and experimentally characterize three patients with anti-TRIM46 antibodies and show that these antibodies are associated with CNS symptoms and an underlying SCLC. Anti-TRIM46 antibodies are polyclonal and directed at multiple, most likely linear epitopes on TRIM46. Anti-TRIM46 antibodies can robustly be detected with multiple techniques.

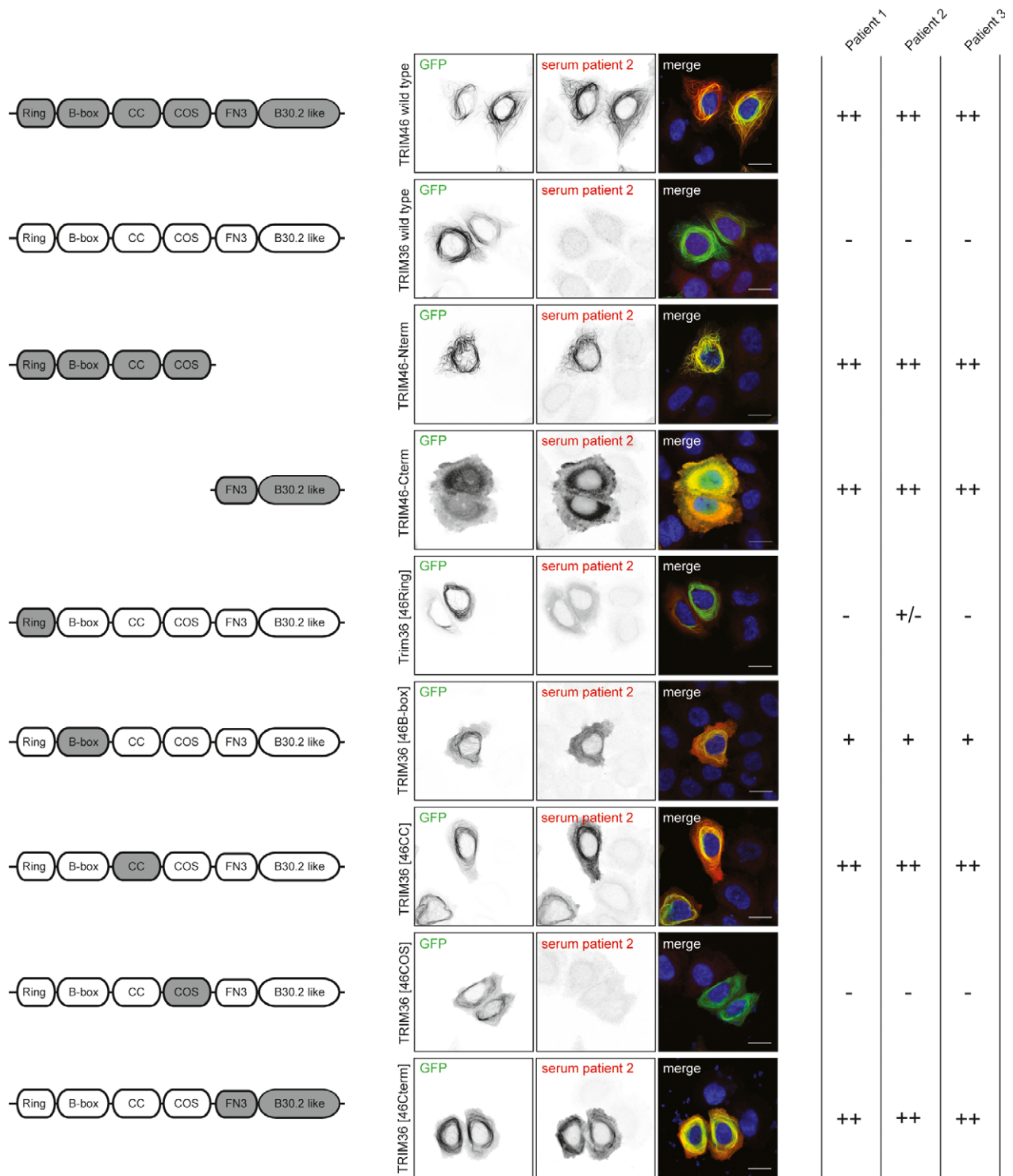


Figure 2. Epitope mapping of anti-TRIM46 autoantibodies. Schematic representation of TRIM46 (gray) and TRIM36 (white). **CC** = coiled-coil. **COS** = C-terminal subgroup one signature. **FN3** = Fibronectin type III. GFP-tagged truncated TRIM46 and chimeric proteins of TRIM46 and TRIM36 (green) expressed in HeLa cells and stained with patient's serum (red). The patients' sera recognize the TRIM46 C-terminus and N-terminal B-box, and CC region.

Although the number of patients in this case series is too small to make any general conclusions, the patients' diverse symptoms fit with the expression of TRIM46 throughout the CNS. A large variety in clinical presentation is also seen in disorders associated with other onconeural antibodies such as anti-Hu.⁴ Similar to anti-Hu, anti-TRIM46 antibodies are associated with an underlying SCLC. However, although low titers of anti-Hu antibodies occur in 16–26% of patients with SCLC without PNS,^{12,16,17} we did not detect anti-TRIM46 antibodies in sera from patients with SCLC but without neurological symptoms.

TRIM46 antibodies are polyclonal and directed at immunoreactive epitopes in the B-box, coiled-coil, and C-terminal domains of TRIM46. A polyclonal immune reaction, directed at multiple immunogenic sites that are shared between individual patients, is similar to the well-studied onconeural antigen HuD.^{18,19} As TRIM46 is a cytosolic protein, most likely not a humoral but a T-cell-mediated response against TRIM46 is causing the neurological dysfunction. The autopsied brain of patient 3 indeed showed infiltration with CD8⁺ T cells. Also the poor prognosis of all three patients is in line with irreversible neuronal damage. The presence of TRIM46 in the SCLC of one of the patients suggests that ectopic TRIM46 expression by tumor tissue is the immunological trigger. However, as an underlying SCLC was not found in one of the patients, a possible nonparaneoplastic nature of anti-TRIM46 antibodies cannot be ruled out.

We have only rarely detected staining of the AIS in routine IHC. In all cases known to us, this was due to antibodies to TRIM46 and could robustly be confirmed with multiple laboratory techniques. Autoantibodies to other components of the AIS have been reported in literature; for example, antibodies to NF186 have been detected by ELISA in a small group of patients with peripheral neuropathies. Their frequency of occurrence varies greatly between different studies and their clinical value remains unclear.⁸ Antibodies to scaffold protein AnkG are present in patients with Alzheimer's disease and in up to 25% of healthy individuals over 65 years of age.⁷ The discrepancy between the reported high frequency of AnkG antibodies and the low frequency of AIS staining on IHC could be explained by detection methods used (only western blot for AnkG antibodies). Possibly, the formation of AnkG antibodies is triggered by neurodegeneration occurring with age and should be seen separate from the highly specific antibodies occurring in PNS, such as anti-TRIM46 antibodies.

In this case series, we show that anti-TRIM46 antibodies are rare but easy to detect in routine IHC for intracellular antigens. They can occur in patients with diverse neurological syndromes, and can be associated with SCLC.

Acknowledgments

We thank the patients and their physicians for their trust and collaboration. This study was funded by NUTS-OHRA (1104-034), Hersenstichting (2012(1)-141).

Author Contributions

MvC-H has designed, performed and analyzed most of the experiments and drafted the manuscript, SFBvB has generated the chimeric DNA constructs and has provided critical comments to the manuscript, MP provided and collected information on patient 3 and has provided critical comments to the manuscript, LMW has performed immunostaining of mouse brain and has provided critical comments to the manuscript, EH has performed and analyzed immunohistochemistry experiments and has provided critical comments to the manuscript, JFD provided and collected information on patient 3 and has provided critical comments to the manuscript, LS provided and collected information on patient 2 and has provided critical comments to the manuscript, JMK has pathologically assessed SCLC tissue and has provided critical comments to the manuscript, JV has provided SCLC serum samples and has provided critical comments to the manuscript, MJT has provided critical comments to the experiments and manuscript, EdG, PAESS, and CCH have designed and coordinated the study and have provided critical comments to the experiments and manuscript.

Conflicts of Interest

MvC-H, SFBvB, MP, LMW, EH, JFD, LS, and JMK have nothing to disclose, JV has a patent for MusK therapy and receives royalties for anti-MuSK ELISA. He performs consultancy functions for Argen-X and Alexion. He received grants from Duchenne Parent Project, Association contre les Myopathies Française, ZonMw, Spieren voor Spieren and Prinses Beatrix Spierfonds, MJT received research funds for serving on a scientific advisory board of MedImmune LLC and a travel grant for lecturing in India from Sun Pharma, India. He received research funds from Guidepoint for consultation for future trials, EdG received a research grant from Euroimmun for a patent for the use of DNER as an autoantibody test, PAESS received a research grant from Euroimmun for a patent for the use of DNER as an autoantibody test, CCH has nothing to disclose.

References

1. Graus F, Delattre JY, Antoine JC, et al. Recommended diagnostic criteria for paraneoplastic neurological

- syndromes. *J Neurol Neurosurg Psychiatry* 2004;75:1135–1140.
2. Probst C, Komorowski L, de Graaff E, et al. Standardized test for anti-Tr/DNER in patients with paraneoplastic cerebellar degeneration. *Neurol Neuroimmunol Neuroinflamm* 2015;2:e68.
 3. de Graaff E, Maat P, Hulsenboom E, et al. Identification of delta/notch-like epidermal growth factor-related receptor as the Tr antigen in paraneoplastic cerebellar degeneration. *Ann Neurol* 2012;71:815–824.
 4. Graus F, Keime-Guibert F, Rene R, et al. Anti-Hu-associated paraneoplastic encephalomyelitis: analysis of 200 patients. *Brain* 2001;124(Pt 6):1138–1148.
 5. Berghs S, Ferracci F, Maksimova E, et al. Autoimmunity to beta IV spectrin in paraneoplastic lower motor neuron syndrome. *Proc Natl Acad Sci USA* 2001;98:6945–6950.
 6. Shams'ili S, deLeeuw B, Hulsenboom E, et al. A new paraneoplastic encephalomyelitis autoantibody reactive with the axon initial segment. *Neurosci Lett* 2009;467:169–172.
 7. Santucci AC, Merlini M, Shetty A, et al. Active vaccination with ankyrin G reduces beta-amyloid pathology in APP transgenic mice. *Mol Psychiatry* 2013;18:358–368.
 8. Stathopoulos P, Alexopoulos H, Dalakas MC. Autoimmune antigenic targets at the node of Ranvier in demyelinating disorders. *Nat Rev Neurol* 2015;11:143–156.
 9. Rasband MN. Composition, assembly, and maintenance of excitable membrane domains in myelinated axons. *Semin Cell Dev Biol* 2011;22:178–184.
 10. van Beuning SF, Will L, Harterink M, et al. TRIM46 Controls Neuronal Polarity and Axon Specification by Driving the Formation of Parallel Microtubule Arrays. *Neuron* 2015;88:1208–1226.
 11. Sabater L, Hoftberger R, Boronat A, et al. Antibody repertoire in paraneoplastic cerebellar degeneration and small cell lung cancer. *PLoS ONE* 2013;8:e60438.
 12. Titulaer MJ, Klooster R, Potman M, et al. SOX antibodies in small-cell lung cancer and Lambert-Eaton myasthenic syndrome: frequency and relation with survival. *J Clin Oncol* 2009;27:4260–4267.
 13. Short KM, Cox TC. Subclassification of the RBCC/TRIM superfamily reveals a novel motif necessary for microtubule binding. *J Biol Chem* 2006;281:8970–8980.
 14. van Coevorden-Hameete MH, de Graaff E, Titulaer MJ, et al. Plasticity-related gene 5: a novel surface autoantigen in paraneoplastic cerebellar degeneration. *Neurol Neuroimmunol Neuroinflamm* 2015;2:e156.
 15. Brewer GJ, Torricelli JR, Evege EK, Price PJ. Optimized survival of hippocampal neurons in B27-supplemented Neurobasal, a new serum-free medium combination. *J Neurosci Res* 1993;35:567–576.
 16. Graus F, Dalmou J, Rene R, et al. Anti-Hu antibodies in patients with small-cell lung cancer: association with complete response to therapy and improved survival. *J Clin Oncol* 1997;15:2866–2872.
 17. Monstad SE, Drivsholm L, Storstein A, et al. Hu and voltage-gated calcium channel (VGCC) antibodies related to the prognosis of small-cell lung cancer. *J Clin Oncol* 2004;22:795–800.
 18. Sodeyama N, Ishida K, Jaeckle KA, et al. Pattern of epitopic reactivity of the anti-Hu antibody on HuD with and without paraneoplastic syndrome. *J Neurol Neurosurg Psychiatry* 1999;66:97–99.
 19. Manley GT, Smitt PS, Dalmau J, Posner JB. Hu antigens: reactivity with Hu antibodies, tumor expression, and major immunogenic sites. *Ann Neurol* 1995;38:102–110.