
UNIVERSITE DE LAUSANNE - FACULTE DE BIOLOGIE ET DE MEDECINE

Département de l'appareil locomoteur
Service de chirurgie plastique et reconstructive

**Le lambeau musculo-cutané du grand dorsal en V-Y dans la
reconstruction de pertes de substances étendues de la paroi thoracique
postérieure**

THESE

préparée sous la direction du Professeur Wassim Raffoul

et présentée à la Faculté de biologie et de médecine de
l'Université de Lausanne pour l'obtention du grade de

DOCTEUR EN MEDECINE

par

Thierry CHRISTEN

WF
980
CHR

Médecin diplômé de la Confédération Suisse
Originaire de Genève (Genève)

BHTE 3657

Lausanne

2012

Imprimatur

Vu le rapport présenté par le jury d'examen, composé de

Directeur de thèse Monsieur le Professeur Wassim Raffoul

Co-Directeur de thèse

Expert

*Directrice de l'Ecole Madame le Professeur Stephanie Clarke
doctorale*

la Commission MD de l'Ecole doctorale autorise l'impression de la thèse de

Monsieur Thierry Christen

intitulée

*Le lambeau musculo-cutané du grand dorsal en V-Y dans la
reconstruction de pertes de substances étendues de la paroi
thoracique postérieure*

Lausanne, le 17 avril 2012

*pour Le Doyen
de la Faculté de Biologie et de Médecine*



*Madame le Professeur Stephanie Clarke
Directrice de l'Ecole doctorale*

Résumé du travail de thèse intitulé

Le lambeau musculo-cutané du grand dorsal en V-Y dans la reconstruction des pertes de substances étendues de la paroi thoracique postérieure

présenté par Thierry Christen

Les pertes de substances étendues de la paroi thoracique postérieure sont régulièrement rencontrées en chirurgie reconstructive. Les causes les plus habituelles sont les escarres, l'extirpation de lésions néoplasiques et les déhiscences de plaie dans le cadre d'une chirurgie du rachis. L'exposition fréquente des côtes ou des vertèbres rend nécessaire l'emploi d'un lambeau afin de s'assurer de la pérennité de la couverture.

Le lambeau musculo-cutané du trapèze est classiquement indiqué dans les plaies du rachis cervical et dorsal haut alors que le lambeau musculo-cutané du grand dorsal l'est dans les pertes de substances dorsales basses. Lorsque la taille du lambeau prélevé rend impossible la fermeture directe du site donneur, ce dernier doit être recouvert soit par une greffe de peau, soit par un autre lambeau, ce qui majore la morbidité dans les deux cas.

En 2001, Micali a proposé un nouveau tracé de la palette cutanée du lambeau du grand dorsal en utilisant l'artifice du V-Y, permettant par conséquent la fermeture directe du site de prélèvement. Cette modification s'intéressait uniquement à la paroi thoracique antérieure. Nous avons étudié la faisabilité de cette technique appliquée au thorax postérieur.

Trois patients ont bénéficié de la couverture d'une perte de substance thoracique postérieure par un lambeau musculo-cutané du grand dorsal en V-Y. Il s'agissait de 2 cas de déhiscence de plaie après chirurgie de stabilisation rachidienne et d'un cas d'exérèse d'un sarcome. La palette cutanée est orientée obliquement depuis la berge externe de la plaie, son bord médial étant cranial alors que son bord latéral est caudal et forme une pointe. Le muscle grand dorsal est levé selon la technique habituelle en conservant la palette cutanée attachée afin de préserver les vaisseaux perforants nourriciers. Le lambeau est avancé postérieurement afin d'oblitérer le défaut sans tension. Le site donneur est ensuite suturé en première intention.

Les trois lambeaux ont intégralement survécu et ont permis une couverture cutané-musculaire durable sans la survenue de complications.

La modification de la technique de Micali que nous proposons permet d'obtenir de façon reproductible une couverture stable de pertes de substances étendues intéressant la paroi thoracique postérieure. Contrairement au dessin habituel de la palette cutanée, l'artifice du V-Y rend obsolète l'utilisation de greffes de peau puisque le site donneur peut être suturé sans tension. La chirurgie étant courte et la morbidité faible, cette technique peut également être appliquée aux patients fragiles pour lesquels une intervention longue de type lambeau libre est contre-indiquée.

The V-Y Latissimus Dorsi Musculocutaneous Flap in the Reconstruction of Large Posterior Chest Wall Defects

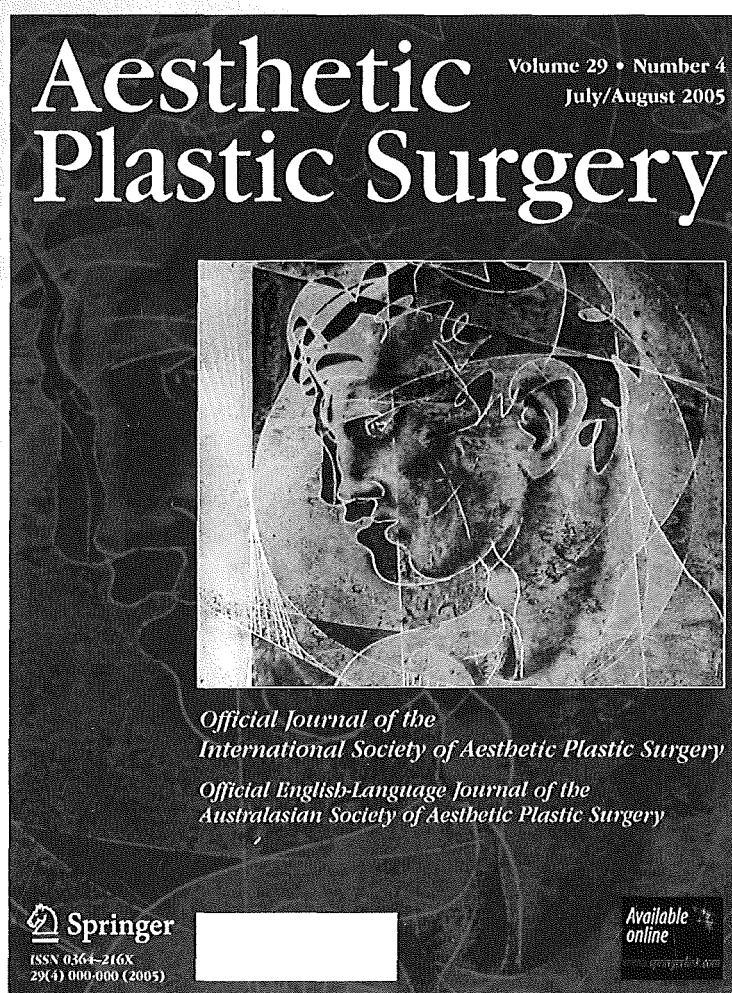
**T. Christen, N. Koch, C. Philandrianos,
R. Ramirez, W. Raffoul, M. Beldi &
D. Casanova**

Aesthetic Plastic Surgery

ISSN 0364-216X

Aesth Plast Surg

DOI 10.1007/s00266-011-9866-x



The V-Y Latissimus Dorsi Musculocutaneous Flap in the Reconstruction of Large Posterior Chest Wall Defects

T. Christen · N. Koch · C. Philandrianos ·
R. Ramirez · W. Raffoul · M. Beldi ·
D. Casanova



Received: 19 September 2011 / Accepted: 13 December 2011
© Springer Science+Business Media, LLC and International Society of Aesthetic Plastic Surgery 2012

Abstract Posterior chest wall defects are frequently encountered after excision of tumors as a result of trauma or in the setting of wound dehiscence after spine surgery. Various pedicled fasciocutaneous and musculocutaneous flaps have been described for the coverage of these wounds. The advent of perforator flaps has allowed the preservation of muscle function but their bulk is limited. Musculocutaneous flaps remain widely employed. The trapezius and the latissimus dorsi (LD) flaps have been used extensively for upper and middle posterior chest wounds, respectively. Their bulk allows for obliteration of the dead space in deep wounds. The average width of the LD skin paddle is limited to 10–12 cm if closure of the donor site is expected without skin grafting. In 2001 a modification of the skin paddle design was introduced in order to allow large flaps to be raised without requiring grafts or flaps for donor site closure. This V-Y pattern allows coverage of large anterior chest defects after mastectomy. We have modified this flap to allow its use for posterior chest wall defects. We describe the flap design, its indications, and its limitations with three clinical cases.

Level of Evidence V This journal requires that authors assign a level of evidence to each article. For a full description of these Evidence-Based Medicine ratings, please refer to the Table of Contents or the online Instructions to Authors at www.springer.com/00266.

Keywords Latissimus dorsi · Posterior chest wall defect · V-Y design

Introduction

The surgical treatment of large defects of the chest wall constitutes a difficult challenge. These wounds are commonly referred to as anterior or posterior in order to define the surgical strategy. They can further be divided into upper, middle, or lower defects as a way to choose the best coverage strategy [5]. Most of these wounds are deep and bone exposure is frequently encountered, thus skin grafts are not considered a good coverage option. Local flaps may be useful but are limited to small wounds. Therefore, pedicled fasciocutaneous and musculocutaneous flaps are considered the mainstay of treatment.

Anterior chest wall defects are most commonly encountered after tumor excision or mediastinitis following open cardiac surgery. Various flaps indicated for that setting include the transverse rectus abdominis muscle (TRAM) [7], the latissimus dorsi (LD) [18], and the pectoralis major flap [9].

Posterior midline defects occur most commonly after wound dehiscence following surgery of the spine and frequently in relation with preoperative radiotherapy or wound hematoma and infection. Bedsores are another frequent cause of dorsal midline wounds, whereas congenital deformities such as meningocele are rarely

T. Christen (✉) · N. Koch · W. Raffoul
Department of Plastic, Reconstructive and Aesthetic Surgery,
University Hospital of Lausanne, 46 rue du Bugnon,
1011 Lausanne, Switzerland
e-mail: thierry.christen@chuv.ch

C. Philandrianos · R. Ramirez · D. Casanova
Department of Plastic, Reconstructive and Aesthetic Surgery,
University Hospital of Marseille, Bourrely Road, North Hospital,
13915 Marseille cedex 20, France

M. Beldi
Private Practice, 36A avenue de Tourbillon, 1950 Sion,
Switzerland

seen [8]. Cerebrospinal fluid leak, bacterial contamination, or a combination of both [4] are often found concomitantly and may lead to severe life-threatening septic complications. From a reconstructive point of view, the wound should undergo a thorough debridement of dead tissues followed by coverage of the resulting defect by a well-vascularized flap. Use of the trapezius flap [13] has been reported for defects of the upper spine, while coverage of the lower dorsal area is best achieved by the LD flap [14]. Recently, perforator flaps based on the thoracodorsal [1] or iliolumbar vessels have been gaining popularity [10].

The LD flap is considered a versatile V-type flap according to Mathes and Nahai [12], with a reliable blood supply provided by both a dominant pedicle (thoracodorsal vessels) and a secondary segmental supply (perforating branches of the intercostal and lumbar arteries). With the conventional elliptical skin paddle design, direct donor site closure cannot be achieved when large flaps are needed [3]. In 2001, Micali and Carramaschi [15] described a new skin paddle V-Y design that allows broad flaps to be raised while primarily closing the donor site. Although this technique was meant to be used for anterior chest wall defects, we also found it useful for posterior wounds. We report our experience with three original cases of posterior chest wall reconstruction using a modification of Micali's flap.

Materials and Methods

Three patients underwent pedicled LD flaps with a V-Y design of the skin paddle.

Case 1 involved a 69-year-old man who sustained a fracture of the 8th dorsal vertebra in a motor vehicle accident resulting in paraplegia (Fig. 1). No comorbidities were reported in the chart. Stabilization of the spine was achieved by the trauma team. Wound dehiscence occurred at 3 weeks and the hardware became exposed. The resulting defect measured 10 cm × 12 cm.

Case 2 was a healthy 45-year-old male involved in a motor vehicle accident resulting in a fracture of the 7th dorsal vertebra (Fig. 2). A laminectomy was performed on the fractured vertebra as well as arthrodesis of the 6th, 7th, and 8th vertebrae. A right pneumothorax required a chest drain that was removed after 4 days. Subsequent leakage of the wound led to maceration and dehiscence of the dorsal scar, with exposure of the hardware through an 8-cm × 10-cm wound.

Case 3 was a 55-year-old male suffering from a soft-tissue sarcoma of the posterior midline. He underwent wide surgical resection with rib removal and radiotherapy. Infected wound dehiscence occurred and required thorough debridement as well as intravenous antibiotherapy (Fig. 3). The defect measured 18 cm × 19 cm.

Preoperatively the borders of the LD flap were outlined on the skin as were the inferior angle of the scapula and the iliac crest. Patients were positioned in ventral or lateral recumbency. Debridement of dead tissues was carried out in all cases. The flap was designed to extend from the widest borders of the defect. It was obliquely oriented, with its medial side cranial and lateral side caudal. The lateral tip was kept narrow to allow closure in a V-Y manner. The cutaneous borders of the flap were incised and the LD was exposed after incising its fascia which was sutured to the skin in order to avoid tethering forces. The muscle was carefully dissected from the serratus anterior anteriorly, the external oblique inferiorly, and the trapezius and paraspinal muscles posteriorly. The flap was then raised from caudal to cranial up to the point where it could be inset over the defect without tension. Care was taken not to injure the thoracodorsal vessels in the axilla. The medial border of the flap was deepithelialized in case 2 to obliterate the dead space overlying the spine. After flap inset, the donor site was closed over two drains with quilting sutures while the flap was sutured in layers.

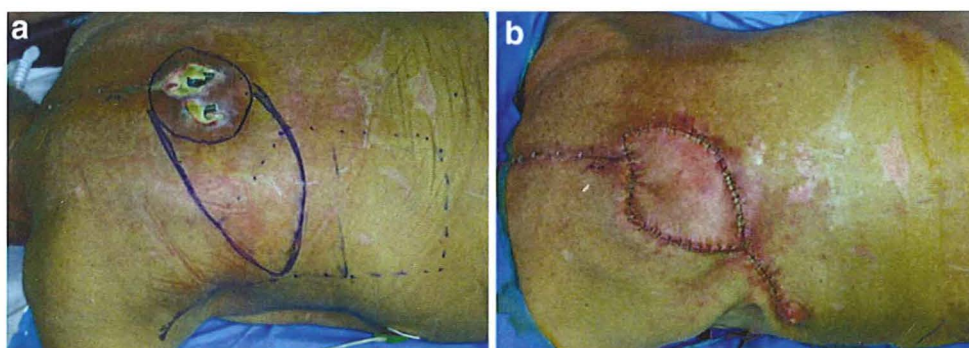


Fig. 1 **a** Posterior midline defect with apparent hardware. The excision area is outlined as is the flap. The LD projection is represented by the dotted line. **b** The flap is advanced posteriorly and the donor site sutured

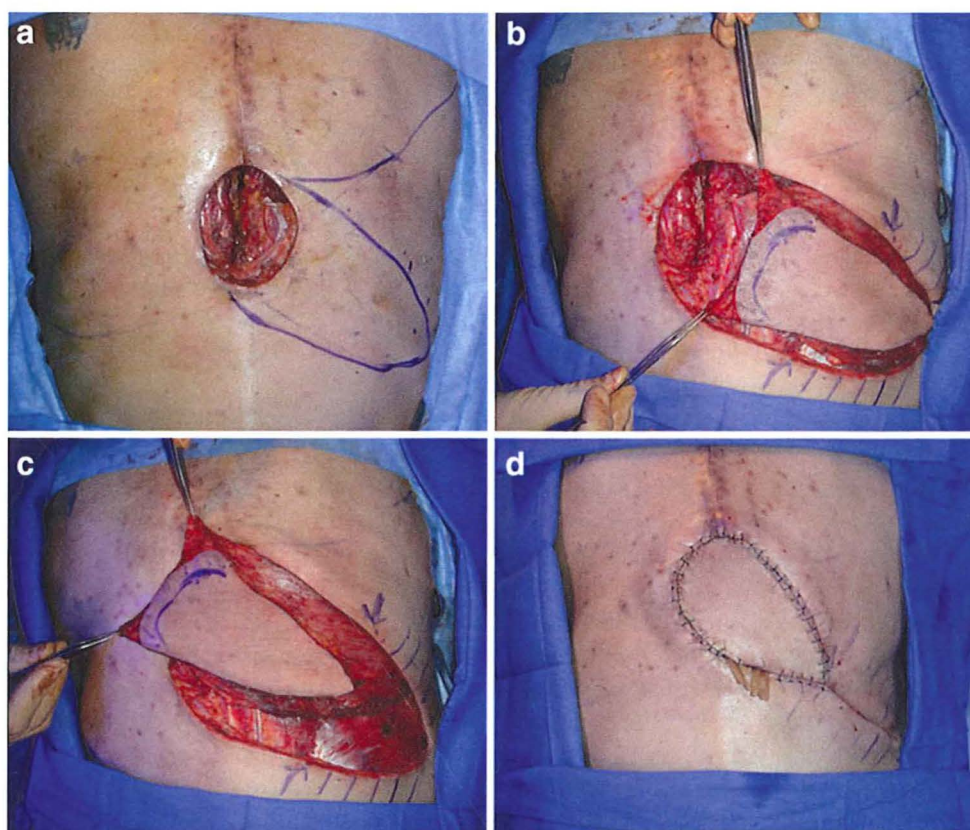


Fig. 2 **a** Posterior midline defect with outline of the flap. **b** Dissection of the flap. **c** The flap is advanced posteriorly over the defect and deepithelialized medially in order to obliterate the dead space over the exposed hardware. **d** Immediate postoperative result

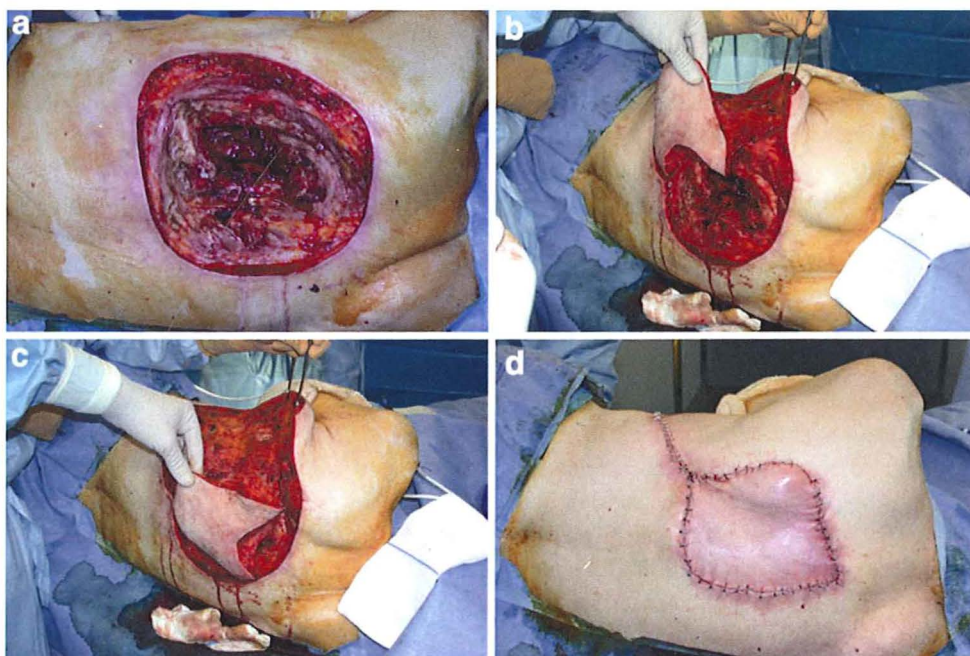


Fig. 3 **a** Large posterior chest wall defect with spine and rib exposure. **b, c** The pedicled musculocutaneous flap is raised and advanced over the defect. **d** Immediate postoperative result

Results

The three procedures allowed complete coverage of the defects and direct closure of the donor site with limited tension. The drains were removed when oozing was less than 40 ml/day. Healing was uneventful in all cases, with all flaps showing complete survival. There were no infectious complications and lymphatic drainage helped in resorbing mild dorsal seromas.

Discussion

Posterior chest wall defects are usually encountered in either the traumatic or the oncological setting. Various local, pedicled, or free flaps have been described and reviewed thoroughly by Netscher et al. [17]. Local flaps are limited to small- or medium-size defects, while free flaps require lengthy surgeries. Fragile or unstable patients are not always fit for such procedures. Large pedicled flaps are often considered a good option, but donor site closure without excessive tension may be impossible and split-thickness skin grafts should be used in such cases. The ideal flap should cover large defects with reliably vascularized tissues, minimal morbidity, and direct donor site closure, and the procedure should be relatively short.

The trapezius flap is commonly used for upper posterior chest wall defects [13]. If preservation of the superior muscular fibers is possible, the shoulder does not show any droop. Nevertheless, one should ascertain the integrity of the transverse cervical artery and vein as previous surgeries may have disrupted them. The width of the flap is limited if closure of the donor site is desired. The LD flap is often referred to as the most appropriate choice for middle and lower defects as the flap is easily raised, it is large when considered as a muscular flap, and its morbidity is acceptable. The LD flap may reach posterior midline wounds, especially when harvested as a muscular turnover flap based on the perforating branches of the posterior intercostal and lumbar arteries [4]. Skin grafts are necessary in this setting. McCraw et al. [14] undermined the two LD flaps paraspinously and advanced them toward the midline while preserving the perforators for closure of myelomeningocele in newborns. Relaxing skin incisions were unnecessary; however, Moore [16] stated that they are unavoidable if tension-free closure is wanted. The usual LD skin paddle design should not exceed a width of 8–12 cm when primary closure of the donor site is expected [3]. Ruetschi et al. [19] reported raising LD flaps with a skin paddle width of 12–18 cm without specifically mentioning if a skin graft was necessary. The use of a second local flap has been reported by Maruyama and Iwahira [11].

The description of the LD skin paddle design in a V-Y fashion by Micali and Carramaschi [14] allows transposing large flaps anteriorly while directly suturing the donor site. The original description reported cases of unilateral anterior flaps. Although V-Y musculocutaneous LD flaps are indicated mainly for anterior or lateral chest wall defects, we have found it possible to advance them posteriorly across the midline. In these cases, the V-Y LD flap has several advantages over the trapezius flap. The dissection is fast, the vascularization robust, and the skin paddle may be large without donor site closure difficulties. The largest paddle used in this series was 18 cm × 19 cm. According to Mathes and Nahai [12], the area of a LD flap can reach 30 cm × 40 cm; therefore, larger flaps could be raised, keeping in mind the V-Y design. When more advancement is necessary, the LD tendon may be cut while taking great care to avoid stretching the pedicle. Deep defects need obliteration of the dead space to avoid the occurrence of hematoma or seroma which might lead to infection. In this setting, part of the flap might be deepithelialized and buried deeply to add vascularized tissue and provide adequate coverage of vertebrae and ribs.

Apart from Hayashi and Maruyama in 1991 [8], who reported using a bilateral V-Y musculocutaneous LD flap for closure of a large meningomyelocele in an infant, we were not able to find any other mention of such a flap in the literature.

We feel the V-Y LD flap should be considered a reliable option in the surgical armamentarium for coverage of large posterior chest wounds. The surgery is short, the morbidity low, and the functional deficit has been shown to be transient when patients were followed prospectively for 1 year [6]. The flap is indicated mainly for middle posterior defects as its upper reach is limited to the first dorsal vertebrae and wounds of the lumbar area cannot be covered when pedicled on the thoracodorsal vessels. Theoretically a LD flap with a V-Y skin paddle design might be raised pedicled on the iliolumbar perforators, thus allowing coverage of lower wounds [20]. We have not yet performed such a procedure. Perforator flaps have become popular and constitute a valuable option. The dorsal scapular [2] artery perforator flap is able to reach upper midline defects, the thoracodorsal artery perforator flap [1] can reach the middle area, and the lumbar perforator flap [10] is useful for lower wounds. Their main advantages are the preservation of healthy muscle and the length of the vascular pedicle, but their bulk is limited. When bone or hardware is exposed, the bulk of the flap is of paramount importance to obliterate the dead space and treat the underlying infected bone. We have found the V-Y musculocutaneous LD flap useful and reliable for coverage of large middle posterior chest defects when primary closure of the donor site is desired.

Disclosure The authors have no conflicts of interest to disclose.

References

1. Angrigiani C, Grilli D, Siebert J (1995) Latissimus dorsi musculocutaneous flap without muscle. *Plast Reconstr Surg* 96:1608–1614
2. Angrigiani C, Grilli D, Karanavas YL, Longaker MT, Sharma S (2003) The dorsal scapular island flap: an alternative for head, neck, and chest reconstruction. *Plast Reconstr Surg* 111:67–78
3. Bostwick J, Nahai F, Wallace JG, Vasconez LO (1979) Sixty latissimus dorsi flaps. *Plast Reconstr Surg* 63:31–41
4. De Fontaine S, Gaede F, Berthe JV (2008) The reverse turnover latissimus dorsi flap for closure of midline lumbar defects. *J Plast Reconstr Aesthet Surg* 61:917–924
5. Few JW, Nahai F (2006) Reconstruction of the back. In: Mathes SJ (ed) *Plastic Surgery*, vol 6, 2nd edn. Saunders, Philadelphia, pp 441–456
6. Glassey N, Perks GB, McCulley SJ (2008) A prospective assessment of shoulder morbidity and recovery time scales following latissimus dorsi breast reconstruction. *Plast Reconstr Surg* 122:1334–1340
7. Hartrampf CR, Schefflan M, Black PW (1982) Breast reconstruction with a transverse abdominal island flap. *Plast Reconstr Surg* 69:216–225
8. Hayashi A, Maruyama Y (1991) Bilateral latissimus dorsi V-Y musculocutaneous flap for closure of a large meningomyelocele. *Plast Reconstr Surg* 88:520–523
9. Jurkiewicz MJ, Bostwick J 3rd, Hester TR, Bishop JB, Craver J (1980) Infected median sternotomy wound. Successful treatment by muscle flaps. *Ann Surg* 191:738–744
10. Kroll SS, Rosenfield L (1988) Perforator-based flaps for low posterior midline defects. *Plast Reconstr Surg* 81:561–566
11. Maruyama Y, Iwahira Y (1987) Latissimus dorsi musculocutaneous flap: correction of donor-site defect with reverse latissimus flap. *Plast Reconstr Surg* 80:848–851
12. Mathes SJ, Nahai F (1997) *Reconstructive surgery: principles, anatomy and technique*. Churchill Livingstone, New York
13. Mathes SJ, Stevenson TR (1988) Reconstruction of posterior neck and skull with vertical trapezius musculocutaneous flap. *Am J Surg* 156:248–251
14. McCraw JB, Penix JO, Baker JW (1978) Repair of major defects of the chest wall and spine with the latissimus dorsi myocutaneous flap. *Plast Reconstr Surg* 62:197–206
15. Micali E, Carramaschi FR (2001) Extended V-Y latissimus dorsi musculocutaneous flap for anterior chest wall reconstruction. *Plast Reconstr Surg* 107:1382–1390
16. Moore TS, Dreyer TM, Bevin AG (1984) Closure of large spina bifida cystica defects with bilateral bipedicle musculocutaneous flaps. *Plast Reconstr Surg* 73:288–292
17. Netscher DT, Baumholz MA, Bullocks J (2009) Chest reconstruction: II. Regional reconstruction of chest wall wounds that do not affect the respiratory function (axilla, posterolateral chest, and posterior trunk). *Plast Reconstr Surg* 124:427e–435e
18. Olivari N (1976) The latissimus flap. *Br J Plast Surg* 29:126–128
19. Ruetschi MS, LeWinn LR, Chaglassian TA (1981) Variation of latissimus dorsi skin island design for postmastectomy reconstruction. *Ann Plast Surg* 6:171–178
20. Stevenson TR, Rohrich RJ, Pollock RA, Dingman RO, Bostwick J 3rd (1984) More experience with the “reverse” latissimus dorsi musculocutaneous flap: precise location of blood supply. *Plast Reconstr Surg* 74:237–243