

EACTS Presidential Address

# The contraindications of today are the indications of tomorrow<sup>†</sup>

Ludwig K. von Segesser\*

Department of Surgery, Centre Hospitalier Universitaire Vaudois, Lausanne, Switzerland

\* Corresponding author. Department of Surgery, CHUV, BH 05-105, Rue du Bugnon 46, CH-1005 Lausanne, Switzerland. Tel: +41-21-3142279; fax: +41-21-3202442; e-mail: lk@segesser.com (L.K. von Segesser).

With his proverbial thoughts on the 'Perpetual Flux' (Πάντα ῥεῖ : *panta rhei*), Heraclitus from Ephesus [1] expressed, around the year 500 BC, a universal rule that is also applicable to healthcare, including thoracic and cardio-vascular surgery. Some of the drivers for change in our field today that are most frequently raised are demographic changes and cost issues. Indeed, there is no easy solution to the resulting dilemma due to rising caseloads in combination with more fragile patients. However, it may be shortsighted to focus on this issue alone when the standard answer is to do more for less.

It must be worth considering that there may be other routes of development for thoracic and cardio-vascular surgery that deserve to be explored. There are many recommendations for shaping the future, including the one given in the Bible [2]: 'seek and you will find'. Alternatively, waiting for serendipity (finding by not searching) with an unlimited timeline is an option. But, the combination of both approaches is more promising, as suggested by Thomas Alva Edison [3]: 'Pretty much everything will come to him who hustles while he waits'. Those who wonder what 'hustling' means in (t)his context may like to consider a second Edison quote: 'Personally, I enjoy working about 18 h a day. Besides the short catnaps I take each day, I average about four to five hours of sleep per night'. A statement obviously incompatible with the European Working Time Directive [4] and its 48 h default right to work in order to protect the people's health and safety. Obviously, a worker's safety, i.e. a doctor's, is put above the patient's here. Indeed, this is an interesting position coming from our cash-strapped governments.

In looking for alternatives, the most important question to ask is what to focus on in our research and development efforts, in order to make a difference. Fortunately enough, I got some inspiration from one of my late uncles, Albin Mayr, from Innsbruck, Austria. He claimed that the most beautiful tracks for driving are there, where it is forbidden to drive. As a boy, I was extremely impressed by that statement, because I was sure, that he was speaking from experience. Despite this, I cannot tell until today, whether this experience was gained before or after the introduction of the regulations, i.e. the traffic ban.

This being said, I suggest visiting some forbidden fruit in the field of thoracic and cardio-vascular surgery hanging at various levels by looking at the following with a somewhat structured approach:

- (i) Contraindications of yesterday
- (ii) Indications of today

- (iii) Contraindications of today
- (iv) Indications of tomorrow

When I was a student, bleeding gastric ulcers were primarily treated with iced water, and if that did not work, a Sengstaken–Blakemoore balloon was inserted, usually not an easy task in blood-vomiting patients. If that was not effective either, open surgery was performed for a direct suture of the bleeding gastric vessel, excision of the ulcer, and partial gastrectomy in more severe cases [5]. For some of the gastrectomy procedures, the so-called PETZ apparatus was used, an ingenious stapling device invented in 1921 by Aldar von Petz, a Hungarian surgeon [6]. In those days, an essential lesson I learned was that those hand-loaded staples of the staple instruments worked immediately in about 50% of cases. In the other half, some staples would fall in the open peritoneal cavity and/or some staples would not close in a reliable fashion. By the time reliable staplers were developed, i.e. in the 1980s [7], gastric resection for bleeding ulcers had disappeared several times. The first time, it was replaced by vagotomy and its supraseductive variations, the second time by efficient medication including proton-pump inhibitors for the blocking of acid production and the third time by the eradication of *Helicobacter pylori*. Today, more than 100 years after its inception, very efficient and even motorized staplers, that were originally developed and indicated for laparoscopic abdominal surgery are used frequently for the removal of left atrial appendages (Fig. 1) in minimally invasive surgery for the treatment of atrial fibrillation [8], a treatment option that was offered for a long time in combination with other open heart procedures and contraindicated in lone atrial fibrillation.


Another interesting observation can be made for the treatment of traumatic fractures of the extremities. For a long time, 'stabilization' of the fracture by extensions bound the patient to the hospital bed and had him fight against many kilos for weeks and months, a condition to be followed by another period with casts made from plaster. Immobilization was the rule! This changed completely with the advent of inner stabilization of the fractured bone by nails, plates and screws [9], allowing for early mobilization of the patient out of the bed, out of the room, out of the ward and out of the hospital. On top of the reduction in muscle loss and improved comfort for the patient, this new approach indicating early mobilization also markedly reduced the risk of thrombo-

<sup>†</sup>Presented at the 26th Annual Meeting of the European Association for Cardio-Thoracic Surgery, Barcelona, Spain, 27–31 October 2012.

embolic complications [10], a major cardio-vascular threat with often fatal consequences.

## TERMINAL HEART FAILURE

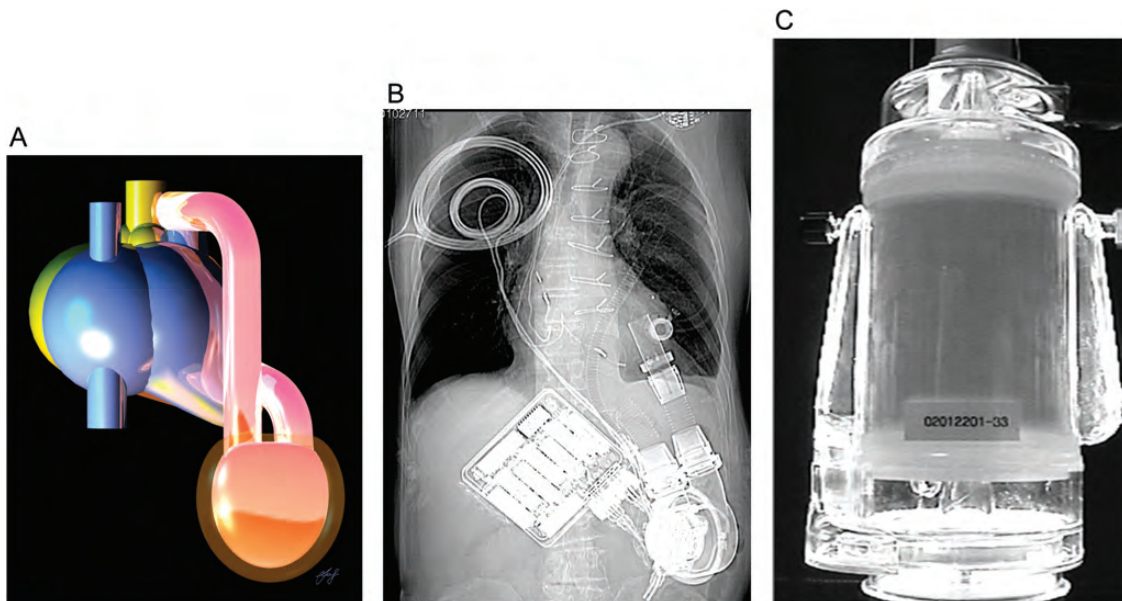
A fairly similar observation can be made for mechanical circulatory support, where the first surviving patients [11] had their chests kept open for the connection of para-corporeal ventricular assist devices (VADs), and were therefore not only tied to



**Figure 1:** Schematic view of the surgical treatment of atrial fibrillation: the dotted lines represent the basis of the stapled left atrial appendage, a procedure that is now routinely realized with video-endoscopic techniques.

heavy drivers with back-up and monitoring equipment, but also to the bed. As a matter of fact, it was sometimes contraindicated to turn the patients on their side, with all the unpleasant implications for the skin, especially if vaso-constricting drugs had to be used in addition. Indeed, immobilization was the rule. With the advent of implantable VADs (Fig. 2A) with portable drivers, the picture changed completely. Suddenly, patients could be moved out of the bed, out of the intensive care unit, out of the ward and again out of the hospital [12]. Mobilization that was previously contraindicated became very much indicated. There were still some limitations due to the skin-crossing driver and vent lines, but with the development of transcutaneous energy transfer systems such as the Lion Heart (Fig. 2B), even this barrier could be crossed for up to half an hour. Strongly contraindicated activities (due to electrical short circuits and/or water aspiration into vent lines), such as swimming in a pool, or simpler things like taking a bath in a tub became a reality, despite the dependence on an active VAD. Of course, such wireless systems can be further improved and adapted to the current continuous flow pumps used for ventricular support and the same holds true for the implantable energy storage capacity. However, there are also very different approaches under investigation like, e. g. motor-less cardiac compression designs as suggested by P. Tozzi [13, 14], which are made from electroactive materials allowing for contraction like artificial muscles. Hence, extra-cardiac compression devices without direct exposure to the bloodstream can be designed, potentially eliminating the currently contraindicated withdrawal of anticoagulants in VAD patients.

There are also new indications for cardiopulmonary support (CPS) and extra-corporeal membrane oxygenation (ECMO) [15]. As everyone knows, the pump-oxygenator was initially devised by John Gibbon for the treatment of severe pulmonary emboli after he had witnessed the sad outcome of such an event in a young patient. The development of ECMO has been rather slow but steady, and the extracorporeal life support organization



**Figure 2:** (A) Schematic view of an implantable LVAD connected to the left ventricle (inflow) and the aorta (outflow). Implantable VADs made a major contribution for the indicated out-patient treatment of terminal heart failure. (B) The Lion Heart: a totally implantable LVAD including the pump [47], the motor, the controller, the compliance chamber with its port for volume adjustment and the smaller internal coil in the right infra-clavicular area. The larger coil on the skin could be removed for up to half an hour providing unprecedented freedom to the patient including swimming. (C) The CORx device: a miniaturized pump-oxygenator design with extra-low priming volume on the road to stealth perfusion.

registry ([www.elsonet.org](http://www.elsonet.org)) has shown that this approach was useful not only for the indicated respiratory, but also for the supposedly contraindicated cardiac failure [16]. One of the remaining problems is the considerable haemodilution due to the ECMO circuit, which can become a major issue if the latter has to be changed several times. However, stripped down, integrated pump-oxygenator designs have been developed (Fig. 2C) with minimized priming volumes below 400 ml for the entire circuit, which allow for stealth perfusion [17], i.e. without visible modification of the haematocrit. Hence, the theoretically contraindicated mass transfusions in this setting may no longer be indicated. A different issue is the scavenging of a major part of the circulating blood volume in the pulmonary circulation in patients with weak or fibrillating heart, a situation where the aortic valve does not open, and nothing can be ejected from the

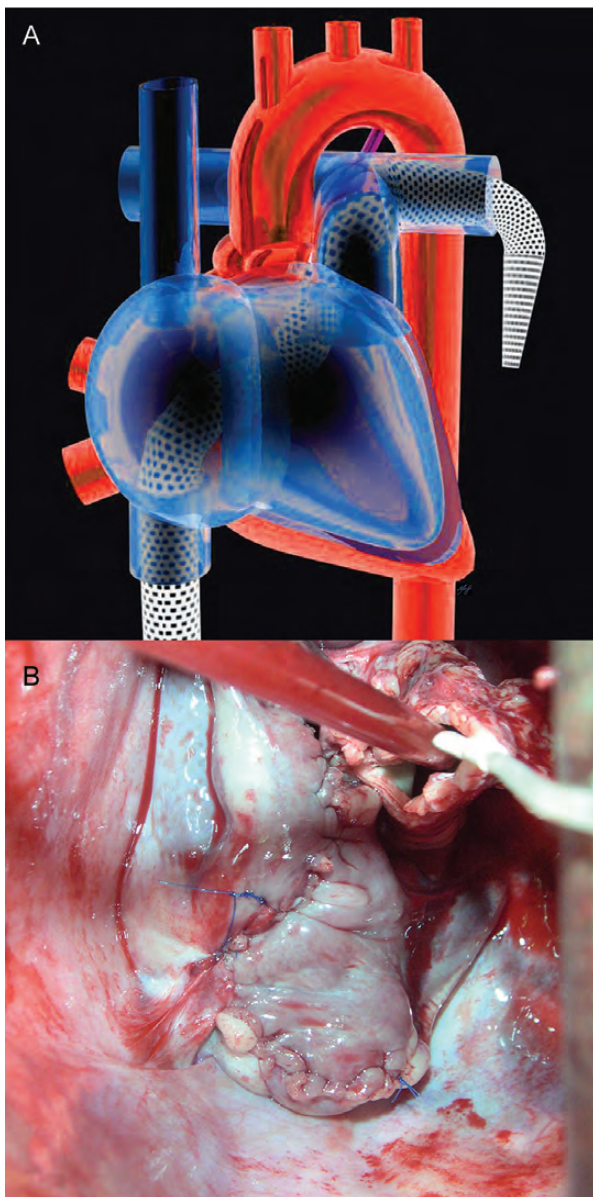
left ventricle. Remote pulmonary artery drainage (Fig. 3A) by flexible wall-less venous cannulas (Smartcanula LLC, Lausanne, Switzerland) introduced from the groin through the tricuspid and pulmonary valves [18] is promising for this scenario. An alternative to this unfamiliar and thus still contraindicated closed-chest approach, e.g. in hyper-acute rejection of an orthotopic heart transplant, may be cardiectomy (Fig. 3B) combined with a bi-atrial anastomosis [19] and temporary caval stenting [20]. In addition, there are also an increasing number of indications for CPS in resuscitation [21], a promising field based on technologies similar to that of ECMO.

## CONGENITAL HEART DISEASE

An essential difference between adult cardio-vascular surgery and paediatric cardio-vascular surgery is the growing organism in the latter, which implies that repairs that are right today will probably not be so tomorrow and may be contraindicated. Hence, there is increasing interest in re-adjustable procedures, re-adjustable implants, bio-absorbable structures and hybrid repairs. Although re-dilatable stents are already quite indicated in current practice, the compensation for growth remains a major challenge as soon as tube grafts, valve prostheses and more complex devices are required. Quite some time ago, we reported growing grafts based on intestinal tissue [22], and others have worked with extracellular matrix [23] in an experimental setting. However, there are not too many formal indications with this approach in clinical practice yet. At this time, the pragmatic approach for extra-cardiac conduits in the growing organism is to implant a conduit as big as possible, and this despite the fact that conduit compression may result in valve leakage, suboptimal flow characteristics, delayed recovery and earlier conduit failure, problems that make excessive oversizing contraindicated. Hence, there is an indication for patient-adjusted conduit configurations with optimized sizes, taking in account both the current functional requirements in a given chest, and the maximally implantable flow reserve based on geometrical simulations (Fig. 4A), computational fluid dynamics and preoperative fitting studies *in silico* and/or *in vitro* by the means of rapid prototyping [24].

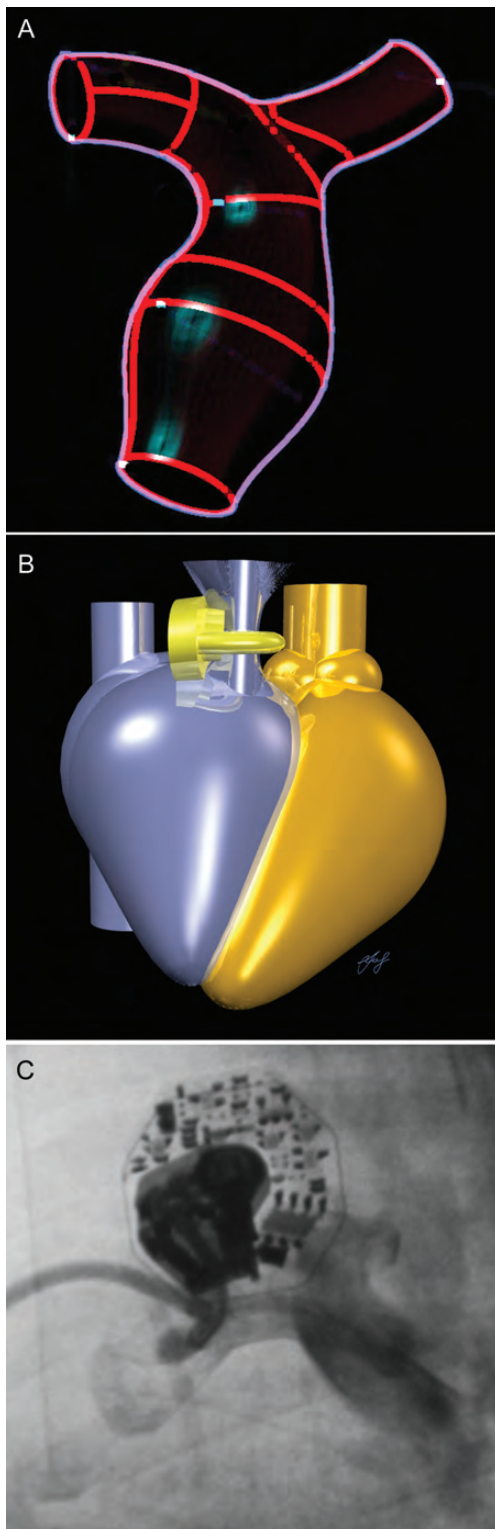
## PULMONARY ARTERY HYPERTENSION

Pulmonary hypertension is a frequent problem in simple and more complex congenital heart disease. But there are also numerous other situations where cardiac and non-cardiac surgeries are considered contraindicated because of chronic long-lasting pulmonary artery hypertension [25]. It has been shown that pulmonary artery hypertension can be reversed in late referrals of complex transpositions of the great arteries undergoing progressive pulmonary artery banding (Fig. 4B). For this paediatric application, a telemetrically adjustable pulmonary artery band (Fig. 4C), the so-called FloWatch® (Leman Medical Technologies SA, Geneva, Switzerland) was developed [26]. It has also been shown that hypertension-induced sclerosis in the kidney and the heart could be reversed if the systemic hypertension was controlled by adequate medication [27]. Likewise, it is well known for severe pulmonary hypertension contraindicating cardiac transplantation that temporary ventricular assist can result in reduced pulmonary vascular artery resistance, thus making

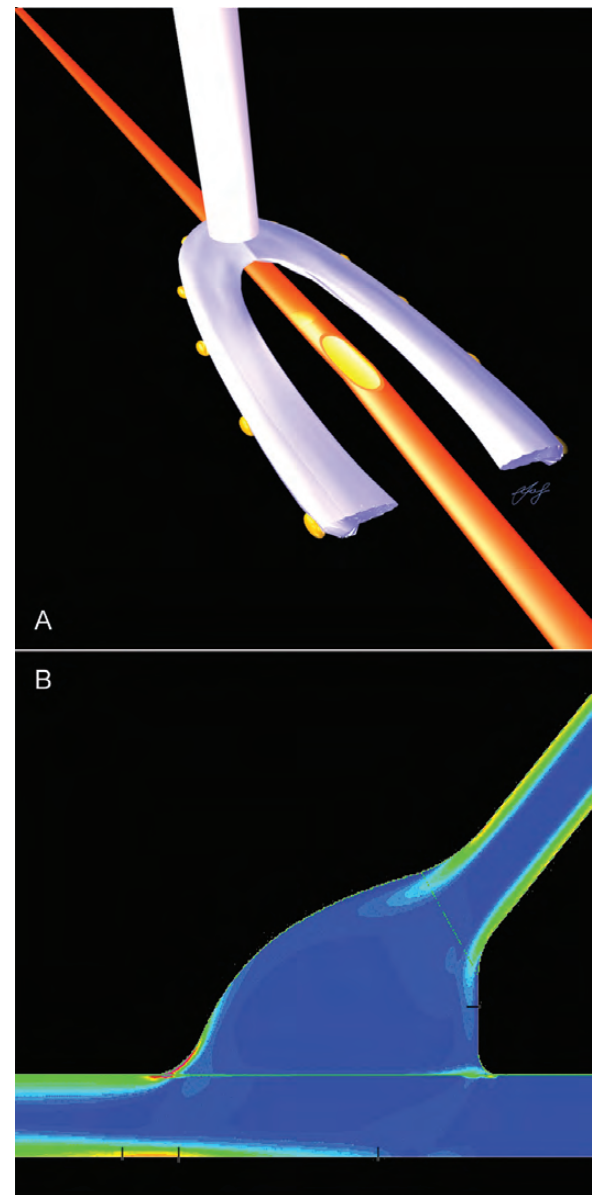


**Figure 3:** (A) Schematic view of trans-femoral decompression of the pulmonary vascular bed with a wall-less cannula during ECMO with fibrillating or arrested heart resulting in improved perfusion. (B) Peroperative view of cardiectomy with bi-atrial anastomosis and temporary caval stenting in the experimental setting: improved venous drainage can be achieved.





**Figure 4:** (A) Geometrical modelling of an oversized extra-cardiac conduit between the right ventricle and the pulmonary bifurcation required for size optimization with regard to intrathoracic space restrictions and growth reserve by computational fluid dynamics (courtesy D. Berdajs, Lausanne, Switzerland). (B) Schematic view of an implantable device for incremental pulmonary artery banding. (C) X-ray showing the FloWatch<sup>®</sup>, an implantable device for the remote control of pulmonary artery blood flow designed for congenital heart disease in the neonatal and infant age group. Adequate energy transmission for larger patients is not yet available (energy for the step motor is transmitted by the external controller, and thus larger distances between the device and the skin currently limit the application).

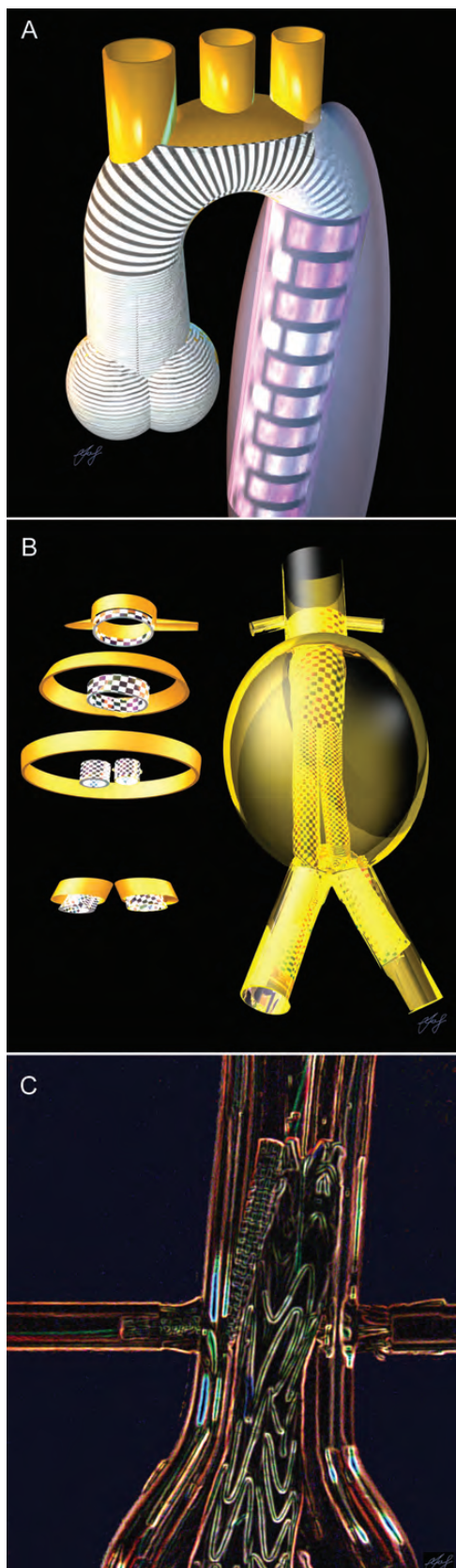

**Figure 5:** (A) Schematic view of a sensing stabilizer designed for minimally invasive direct coronary artery bypass and off-pump coronary artery bypass on the beating heart, a technique providing electric feedback during bypass surgery without cardiopulmonary bypass. (B) Computational fluid dynamics (blue = low velocity fields, red = high velocity fields) of an optimized end to side anastomosis for coronary artery revascularization inspired by technical applications (courtesy C. Oedman, Lausanne, Switzerland).

cardiac transplantation ultimately indicated. Hence, it can be speculated that pulmonary hypertension currently contraindicating numerous therapies should also be influenced under certain circumstances if appropriate devices for progressive but slow pulmonary inflow reduction, e.g. in the grown-up with uncorrected congenital heart disease, were made available.

## CORONARY ARTERY DISEASE

Coronary artery revascularization remains one of the main activities in most cardio-vascular surgical programmes [21]. Once again, the most recent European guidelines on myocardial



**Figure 6:** (A) Schematic view of a hybrid repair of the thoracic aorta after Type A aortic dissection combining a Valsalva composite graft, arch repair with the island technique and a frozen elephant trunk, which can be completed later on by thoracic endovascular aneurysm repair (TEVAR). (B) Schematic view of endovascular abdominal aortic aneurysm repair (EVAR)

revascularization have made the superiority of surgical revascularization in chronic coronary artery disease very clear [28], and the late results of the so-called all-comer Syntax trial [29] are even more supporting the recommendations for surgical revascularization. Hence, surgical myocardial revascularization apparently contraindicated in the catheterization lab is, in fact, very much indicated in the vast majority of patients with chronic multivessel coronary artery disease. However, coronary artery bypass grafting (CABG) in patients with very low ejection fraction remains a major challenge. Several techniques like off-pump CABG and assisted beating heart surgery both relying on stabilizers (Fig. 5A), have been promoted. As an alternative, Tudorache *et al.* [30] have shown, in an experimental setting that pedicled autologous intestinal patches could not only provide contractile elements to the heart, but nourish it due to the patch vasculature. This approach may also be indicated as a platform for grafted pluripotent stem cells or cultured contractile tissue, in order to reconnect them to the bloodstream, even for severely infarcted territories of the heart, thus turning a contraindication into an indication.

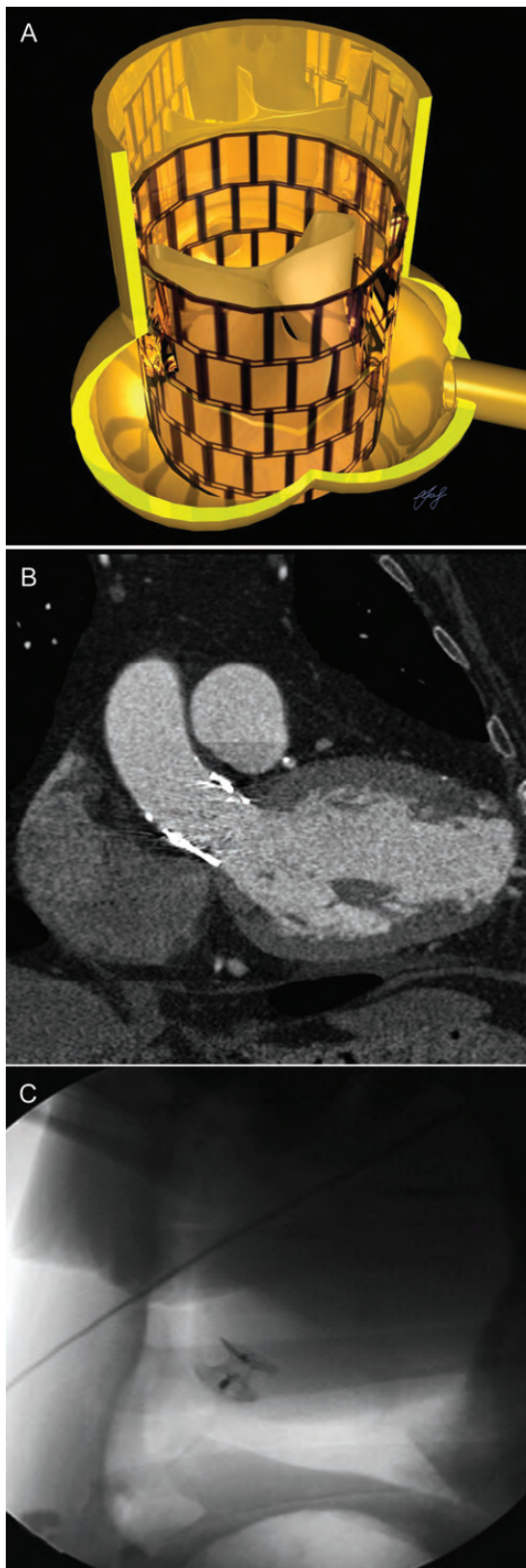
Standardization of anastomoses in coronary artery bypass surgery certainly has great potential. In this field, there has been a period of enthusiasm with very broad indications for mechanical anastomoses at the end of the 20th century. Unfortunately, this enthusiasm has faded due to late occlusions, and thus many anastomotic connecting devices became contraindicated and have disappeared. It should be considered that stapling was introduced in general surgery more than 100 years ago (see above) and has only relatively recently become the standard for intestinal resections and anastomoses. In the vascular field, devices avoiding foreign material within the vascular lumen have already been developed [31]. Optimization of anastomotic configurations with the help of computational fluid dynamics taking advantage of the knowledge gained in technical applications can also provide further insights (Fig. 5B). Hence, writing off mechanical anastomoses seems to be premature, taking into account the numbers of anastomoses performed in cardio-vascular surgery under various conditions every day. Particularly in less-easy redo procedures, the search for quick and reliable mechanical anastomoses is certainly indicated. In addition, the potential indications for glues [32] in the surgical field appear to be underexplored when compared with technical disciplines with similar physical constraints.

## ANEURYSMS

A different challenge is thoracic endovascular aneurysm repair including the entire aortic arch. Nowadays, open as well as hybrid solutions (Fig. 6A) without or with transposition of one or several supra-aortic vessels are standard. A glance at abdominal aortic aneurysm repair (Fig. 6B) shows that almost 100% of these cases can be operated with endovascular techniques relying on fenestrated, branched and chimney grafts (Fig. 6C). It would be naïve to expect that this development [33] will stop at the diaphragm or the left subclavian artery and, therefore, it is a must

reaching just below the renal arteries and the corresponding sections as it can be visualized by intravascular ultrasound (IVUS). (C) Supra-renal fixation of the body of a bifurcated stent-graft for EVAR: the right renal artery is perfused through a chimney graft, whereas a stent is placed in an orifice for perfusion of the left renal artery (experimental set-up)





**Figure 7:** (A) Schematic view of a catheter valve in the aortic position with annular and ascending aortic fixation. (B) Computed tomography scan after transapical aortic valve implantation (TAVI) through an apical aneurysm, which was repaired at this occasion: a contraindication becoming an indication [37]. (C) NOTES for cardiac valve implantation: a trans-umbilical route was developed with an endoscopic saphenous-vein-harvesting system for TAVI. Cardiac access closure was realized with an occluder [40].

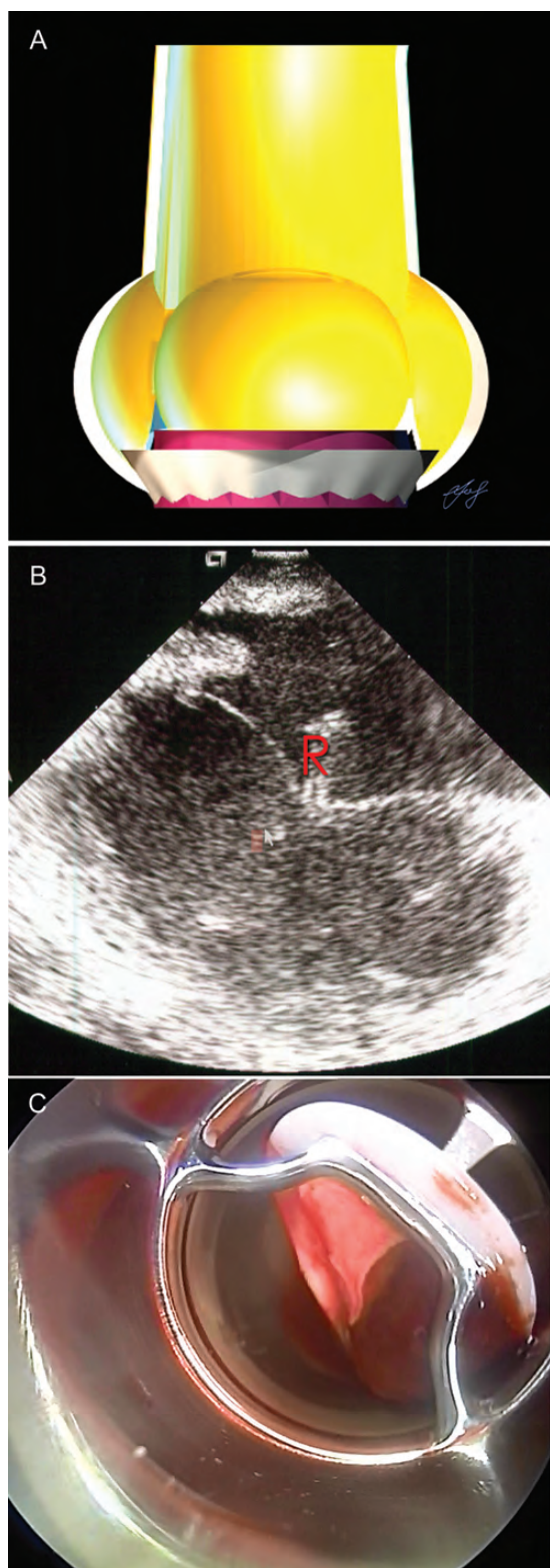
to get actively involved in the development of endovascular solutions for the arch and the ascending aorta [34]. This even more so, as the formerly contraindicated transapical access allows for antegrade insertion of stent-grafts as shown by L. Niclauss [35], can be considered the royal route to the aortic arch and the entire aorta and thus will become indicated sooner or later.

## VALVULAR HEART DISEASE

This brings us to the expanding use of catheter valves (Fig. 7A). Today, the main concern about catheter valves is their durability [36]. However, once the latter is proven to be acceptable, exponential growth can be expected in this field. This development can be further enhanced by improved device designs, reducing the contraindications for existing applications, introducing new indications and developing underexplored routes. To give an example, a left ventricular aneurysm is considered a contraindication for transapical implantation of a catheter valve. However, Ferrari *et al.* [37] have used precisely this approach for the repair of an apical left ventricular aneurysm (Fig. 7B) on the occasion of a catheter valve implantation in an aortic position. Pushing the frontiers further, we have reported the totally endoscopic trans-catheter valve implantation relying on pericardium covered closure devices [38] and by now, there are several devices for apex closure under investigation. In addition, a right trans-ventricular, trans-septal route [39] allowed for the transfer of the access orifice into the low-pressure zone on the right side, with consecutive ease of sealing. This latter approach does not require opening the pleural space and may therefore be carried out under local anaesthesia, even in patients with advanced respiratory problems.

However, the 'nec plus ultra' in surgery is NOTES, i.e. Natural Orifice Transluminal Endoscopic Surgery, a procedure without visible scarring. Of course, this can also be applied to cardiothoracic surgery, and this despite the fact that there is no natural orifice leading to the heart. But the umbilicus is not too far away, and a small incision can be made inside as reported by Kalejs *et al.* [40]. For this purpose, a channel was developed from the umbilicus to the pericardial sac behind the processus xiphoides using a saphenous-vein-harvesting device. Then, the heart was punctured at the apex, and a guide-wire was introduced for implantation of the catheter valve. Although not indicated yet, the challenge of this procedure, which is less how to get in there, but much more how to get out of there, can be solved with a plug (Fig. 7C)—as usual, I might say.

Valve repair certainly dominates the treatment of mitral valves in Europe. Hence, it comes as no surprise that also the approach for trans-catheter mitral valve therapies has been dominated by repair techniques [41]. Nevertheless, catheter valves are also increasingly being used for the mitral position, even if the initial steps are valve-in-valve procedures for degenerated bioprostheses [42] and valve-in-rings for recurrent regurgitation [43], thus taking advantage of the known geometry for the attachment of the new implant. This brings us to mechanical issues and the future indications for mechanical heart valve prostheses (Fig. 8A), which still require anticoagulation with warfarin and the like—drug therapies with inherent complications on their own, in addition to the lack of comfort due to the life-long blood analyses, which are required for dose adjustment. The new oral anticoagulants not requiring regular lab work are already changing the



**Figure 8:** (A) Schematic view of a mechanical valve in the aortic position: conical cuff and low profile are on top of the durability of prostheses made from pyrolytic carbon. (B) Intracardiac ultrasound displaying the a-v valve leaflets and the robotic instruments (R) during off-pump cardiac repair (OPCARE). (C) Thrombus sitting on a tilting disc within an LVAD: a target to be collected by a robot-guided aspirator, provided visualization through the blood can be improved.

field in the prophylaxis of thrombo-embolic events. It does not take in-depth analyses to predict that once the safety of these new anticoagulant drugs in conjunction with mechanical heart valves, i.e. in the aortic position, is proven, a major shift from the failing biological heart valve prosthesis [44] back towards the much more reliable mechanical heart valve prosthesis may become indicated.

## OUTLOOK

Robotic surgery has not yet been identified as being widely indicated in routine thoracic and cardio-vascular surgery. There are a number of reasons for this, including the fact that the beating heart does not make it easier compared with similar targets in other surgical disciplines. However, it is possible to operate successfully within the working heart using robotic telemanipulators with multiple degrees of freedom. When we explored this approach some time ago [45] in order to realize procedures within the working heart that cannot be performed with traditional means (Fig. 8B), we found two essential issues: instrumentation and visualization (Fig. 8C). The latter problem has since been addressed with real-time three-dimensional echocardiography [46] and thus confirms the statement that 'the solution to problems with technology is more technology' (personal communication by Li-Chien Hsu, Mission Viejo, CA, USA). On the contrary, there is also another concept promising success in the future development of thoracic and cardio-vascular surgery like the position accorded to architecture by John Pawson, London, UK, which seems very apt: 'The minimum could be defined as the perfection that an artefact (suggestion by LvS : a surgical technique) achieves when it is no longer possible to improve it by subtraction'.

## REFERENCES

- [1] Platonis Cratylus: 401,d and 402,a in: Platonis philosophi quae extant graece ad editionem Henrici Stephani, Studiis Societatis Bipontinae, Volumen Tertium, Biponti, 1782.
- [2] Biblia, Latin vulgate ; Matthew 7:7 : Gryphius, Louvain 1554.
- [3] Thomas Alva Edison (1847-1931) in Les Inventeurs célèbres - Science physiques et applications; Editions d'Art, Lucien Mazenot, Paris 1950: 168-169.
- [4] European Working Time Directive 2003/88/EC; Amtsblatt der Europäischen Union 18. 11. 2003: L 299/9-19.
- [5] Saegesser M. Der Ulcus-Magen: Pathophysiologische und chirurgische Probleme. Huber, Bern 1966.
- [6] Olah A. Aldar von Petz, the inventor of the modern surgical staplers. *Surgery* 2008;143:146-7.
- [7] Von Segesser LK, Marti MC. Abdomino-perineal amputation: socio-occupational reintegration and late postoperative complications. *Schweiz Med Wochenschr* 1983;113:542-4.
- [8] Gelsonimo S, La Meir M, Luca F, Lorusso R, Crudeli E, Vasquez L *et al.* Treatment of lone atrial fibrillation: a look at the past, a view of the present and a glance at the future. *Eur J Cardiothorac Surg* 2012;41:1284-94.
- [9] Allgöwer M, Perren S, Matter P. A new plate for internal fixation—the dynamic compression plate (DCP). *Injury* 1970;2:40-7.
- [10] He C, von Segesser LK, Kappetein PA, Mestres CA, Smith JA, Choong KC. Acute pulmonary embolectomy. *Eur J Cardiothorac Surg* 2012; doi:10.1093/ejcts/ezs605.
- [11] Turina M, Bosio R, Senning A. Paracorporeal artificial heart in post-operative heart failure. *Artif Organs* 1978;2:273-6.
- [12] Kugler C, Malesha D, Schrader E, Tegtbur U, Guetzlaff E, Haverich A *et al.* A multi-modal intervention in management of left ventricular assist



- device outpatients: dietary counseling, controlled exercise, and psychosocial support. *Eur J Cardiothorac Surg* 2012;42:1026-32.
- [13] Tozzi P, Hayoz D, Taub S, Muradbegovic M, Rizzo E, von Segesser LK. Bimetal muscle to restore atrial transport function in a permanent atrial fibrillation animal model: a potential tool in the treatment of end-stage heart failure. *Eur J Cardiothorac Surg* 2010;37:870-4.
- [14] Tozzi P, Michalis A, Hayoz D, Locca D, von Segesser LK. Artificial muscle for end-stage heart failure. *ASAIO J*. 2012;58:103-8.
- [15] Beckmann A, Benk C, Beyersdorf F, Haimerl G, Merkle F, Mestres C *et al*. ECLS Working Group. Position article for the use of extracorporeal life support in adult patients. *Eur J Cardiothorac Surg* 2011;40:676-80.
- [16] Conrad SA, Rycus PT, Dalton H. Extracorporeal life support registry report 2004. *ASAIO J* 2005;51:4-10.
- [17] Von Segesser LK, Tozzi P, Mallabiabarrena I, Jegger D, Horisberger J, Corno A. Miniaturization for cardiopulmonary bypass. *Perfusion* 2003;18:19-24.
- [18] Von Segesser LK, Kwang K, Tozzi P, Horisberger J, Dembitsky W. A simple way to decompress the left ventricle during venoarterial bypass. *Thorac CardioVasc Surg* 2008;56:337-41.
- [19] Marinakis S, Niklauss L, Rolf T, von Segesser LK. How to improve flow during cardiopulmonary bypass in an acardia experimental model. *Interact CardioVasc Thorac Surg* 2012;15:574-7.
- [20] Von Segesser LK, Sinischalchi G, Kang K, Maunz O, Horisberger J, Ferrari E *et al*. Temporary caval stenting improves venous drainage during cardiopulmonary bypass. *Interact CardioVasc Thorac Surg* 2008;7:1096-100.
- [21] Von Segesser LK. EACTS Day in the new EACTS House. *Eur J Cardiothorac Surg* 2013;43:215-18.
- [22] Tucker OP, Syburra T, Augstburger M, van Melle G, Genhard S, Bosman F *et al*. Small intestine without mucosa as a growing vascular conduit: a porcine experimental study. *J Thorac CardioVasc Surg* 2002;124:1165.
- [23] Padalino MA, Castellani C, Dedia A, Fedrigo M, Vida VL, Thiene G *et al*. Extracellular matrix graft for vascular reconstructive surgery: evidence of autologous regeneration of the neo-aorta in a murine model. *Eur J Cardiothorac Surg* 2012;42:e128-35.
- [24] Abdel-Sayed P, Kalajs M, von Segesser LK. A new training set-up for trans-apical aortic valve replacement. *Interact CardioVasc Thorac Surg* 2009;8:599-601.
- [25] De Santo LS, Romano G, Maiello C, Buonocore M, Cefarelli M, Galdieri N *et al*. Pulmonary artery hypertension in heart transplant recipients: how much is too much? *Eur J Cardiothorac Surg* 2012;42:864-70.
- [26] Sekarski N, Hurni M, von Segesser LK, Meijboom EJ, Di Bernardo S. Adaptable pulmonary artery band for late arterial switch procedure in transposition of the great arteries. *Ann Thorac Surg* 2012;94:1311-6.
- [27] Lekgabe ED, Kiriazis H, Zhao C, Xu Q, Moore XL, Su Y *et al*. Relaxin reverses cardiac and renal fibrosis in spontaneously hypertensive rats. *Hypertension*. 2005;46:412-8.
- [28] Kolh P, Wijns W, Danchin N, Di Mario C, Falk V, Folliguet T *et al*. Guidelines on myocardial revascularization: Task Force on Myocardial Revascularization of the European Society of Cardiology (ESC) and the European Association for Cardio-Thoracic Surgery (EACTS); European Association for Percutaneous Cardiovascular Interventions (EAPCI). *Eur J Cardiothorac Surg* 2010;38 (Suppl):S1-S52.
- [29] Taggart DP. Lessons learned from the SYNTAX trial for multivessel and left main stem coronary artery disease. *Curr Opin Cardiol* 2011;26:502-7.
- [30] Tudorache I, Kostin S, Meyer T, Teebken O, Bara C, Hilfiker A *et al*. Viable vascularized autologous patch for transmural myocardial reconstruction. *Eur J Cardiothorac Surg*. 2009;36:306-11. ; discussion 311.
- [31] Ferrari E, Tozzi P, von Segesser LK. The vascular join: a new sutureless anastomotic device to perform end-to-end anastomosis. Preliminary results in an animal model. *Interact CardioVasc Thorac Surg* 2007;6:5-8.
- [32] Perrin BR, Dupeux M, Tozzi P, Delay D, Gersbach P, von Segesser LK. Surgical glues: are they really adhesive? *Eur J Cardiothorac Surg*. 2009;36:967-72.
- [33] Tozzi P, Corno AF, von Segesser LK. Sutureless thoracic aorta to femoral artery bypass with robotic, video-endoscopic approach: a fast track procedure. *Interact CardioVasc Thorac Surg* 2003;2:186-9.
- [34] Papadimitriou D, Mayer D, Lachat M, Pecoraro F, Frauenfelder T, OPfammater T *et al*. A clampless and sutureless aortic anastomosis technique using an endograft connector for aorto-iliac occlusive disease in which the aorta cannot be clamped or sewn due to calcification or scarring. *Vascular* 2012;20:262-7.
- [35] Niclauss L, von Segesser LK. Total aortic arch stenting—hemodynamic impact of carotid artery perfusion. *Interact CardioVasc Thorac Surg* 2009;9:562-4.
- [36] Ferrari E, Namasivayam J, Marcucci C, Gronchi F, Berdajs D, Niclauss L *et al*. Transapical aortic valve replacement in extreme-risk patients: outcome, risk-factors, and mid-term results. *Eur J Cardiothorac Surg* 2012; doi:10.1093/ejcts/ezs458.
- [37] Ferrari E, Gronchi F, Qanadli SD, von Segesser LK. Transapical aortic valve replacement through a chronic apical aneurysm. *Interact CardioVasc Thorac Surg* 2012;14:367-9.
- [38] Tozzi P, Pawelec-Wojtalic M, Bukowska D, Argitis V, von Segesser LK. Endoscopic off-pump aortic valve replacement: does the pericardial cuff improve the sutureless closure of the left ventricular access. *Eur J Cardiothorac Surg* 2007;31:22-5.
- [39] Liu L, Tozzi P, Ferrari E, von Segesser LK. The transventricular-transseptal access to the aortic root: a new route for extrapleural transcatheter aortic stent-valve implantation. *Eur J Cardiothorac Surg* 2011;39:635-42.
- [40] Kalejs M, Ferrari E, von Segesser LK. Towards no-scar cardiac surgery—minimally invasive access through umbilicus for aortic valve replacement. *Eur J Cardiothorac Surg* 2009;36:773-5.
- [41] Alfieri O, Denti P. Alfieri stitch and its impact on mitral clip. *Eur J Cardiothorac Surg* 2011;39:807-8.
- [42] Santarpino G, Fischlein T, Concistrè G, Pfeiffer S. A staged approach to transcatheter aortic valve implantation and mitral valve-in-valve implantation for degenerated bioprosthesis in a high risk patient. *Interact CardioVasc Thorac Surg* 2012;15:764-5.
- [43] Zou Yu, Ferrari E, von Segesser LK. Off-pump transapical mitral valve-in-ring implantation. *Eur J Cardiothorac Surg* 2013;43:849-55.
- [44] Kalejs M, Laciš R, Kasyanov V, Ozolanta I, Abdel Sayed P, Stradins P *et al*. Comparison of radial deformability of stent posts of different aortic bioprostheses. *Eur J Cardiothorac Surg* 2013;43:704-8.
- [45] Von Segesser LK, Tozzi P, Augstburger M, Corno A. Working heart off-pump cardiac repair (OPCARE)—the next step in robotic surgery. *Interact CardioVasc Thorac Surg* 2003;2:120-4.
- [46] Kawata M, Vasilyev NV, Perrin DP, del Nido PJ. Beating heart mitral valve suture annuloplasty under real time three-dimensional echocardiography guidance: an ex-vivo study. *Interact CardioVasc Thorac Surg* 2010;11:6-9.
- [47] Qanadli S, Tozzi P, Schnyder P, von Segesser LK. Slicing the Lion Heart for assessment of pump shortening fraction after 1 year of follow-up. *Eur J Cardiothorac Surg* 2003;24:642-3.