

# Endovascular Treatment of Active Splenic Bleeding After Colonoscopy: A Systematic Review of the Literature

Antonella Corcillo · Steve Aellen · Tobias Zingg ·  
Pierre Bize · Nicolas Demartines · Alban Denys

Received: 12 September 2012 / Accepted: 22 November 2012 / Published online: 21 December 2012

© Springer Science+Business Media New York and the Cardiovascular and Interventional Radiological Society of Europe (CIRSE) 2012

## Abstract

**Purpose** Colonoscopy is reported to be a safe procedure that is routinely performed for the diagnosis and treatment of colorectal diseases. Splenic rupture is considered to be a rare complication with high mortality and morbidity that requires immediate diagnosis and management. Nonoperative management (NOM), surgical treatment (ST), and, more recently, proximal splenic artery embolization (PSAE) have been proposed as treatment options. The goal of this study was to assess whether PSAE is safe even in high-grade ruptures.

**Methods** We report two rare cases of post colonoscopy splenic rupture. A systematic review of the literature from 2002 to 2010 (first reported case of PSAE) was performed and the three types of treatment compared.

**Results** All patients reviewed (77 of 77) presented with intraperitoneal hemorrhage due to isolated splenic trauma.

Splenic rupture was high-grade in most patients when grading was possible. Six of 77 patients (7.8 %) were treated with PSAE, including the 2 cases reported herein. Fifty-seven patients (74 %) underwent ST. NOM was attempted first in 25 patients with a high failure rate (11 of 25 [44 %]) and requiring a salvage procedure, such as PSAE or ST. Previous surgery (31 of 59 patients), adhesions (10 of 13), diagnostic colonoscopies (49 of 71), previous biopsies or polypectomies (31 of 57) and female sex (56 of 77) were identified as risk factors. In contrast, splenomegaly (0 of 77 patients), medications that increase the risk of bleeding (13 of 30) and difficult colonoscopies (16 of 51) were not identified as risk factors. PSAE was safe and effective even in elderly patients with comorbidities and those taking medications that increase the risk of bleeding, and the length of the hospital stay was similar to that after ST.

**Conclusion** We propose a treatment algorithm based on clinical and radiological criteria. Because of the high failure rate after NOM, PSAE should be the treatment of choice to manage grade I through IV splenic ruptures after colonoscopy in hemodynamically stabilized patients.

---

Antonella Corcillo and Steve Aellen contributed equally to this study.

A. Corcillo (✉)

Département de Médecine Interne, Centre Hospitalier  
Universitaire Vaudois (CHUV), Lausanne, Switzerland  
e-mail: antonella.corcillo@chuv.ch

S. Aellen · T. Zingg · N. Demartines

Service de Chirurgie Viscérale, Centre Hospitalier  
Universitaire Vaudois (CHUV), Lausanne, Switzerland  
e-mail: steve.aellen@hopitalvs.ch

S. Aellen

Service de Chirurgie Viscérale, Thoracique et Vasculaire, Centre  
Hospitalier du Centre du Valais (CHCVs), Av. du Grand-  
Champsec 80, CP 736, 1951 Sion, Switzerland

P. Bize · A. Denys

Département de Radiologie Interventionnelle, Centre Hospitalier  
Universitaire Vaudois (CHUV), Lausanne, Switzerland

**Keywords** Splenic · Spleen · Colonoscopy · Rupture ·  
Trauma · Embolization · Computed tomography-scan

## Introduction

Colonoscopy is the investigation of choice for the diagnosis and treatment of colorectal tumors. An estimated 1.69 million screening colonoscopies are performed each year in the United States, [1] and >2,400 colonoscopies were performed in 2009 at our institution.

Although it is considered to be a safe procedure in experienced hands, the most frequent complications are

intraluminal hemorrhage and colonic perforation (1–2 and 0.1–0.2 % incidence, respectively) [2]. The risk of complications increases if therapeutic procedures, such as polypectomy, are added [2, 3]. Although very rare, splenic rupture is known to be a serious complication with high morbidity and mortality rates. Its incidence, which is probably lower than that of perforation, is not known and is rarely reported: There have been <80 published cases in the literature worldwide since 2002. Even though presentation may be delayed, in most cases the patient presents within 24 h after the procedure and most require urgent management [2]. Rapid management, including fluid resuscitation, can prevent a fatal outcome. Successful treatment may also be obtained without surgery by a minimally invasive endovascular procedure that has been described for blunt splenic injury [4]. Because of the increase in the number of diagnostic and therapeutic colonoscopies, not only general practitioners, but also radiologists and emergency room specialists, will face increasing numbers of patients with this complication.

Thus, this review presents two consecutive cases of splenic rupture with active bleeding after colonoscopy who were both successfully treated with arterial embolization. A review of the literature describes the clinical circumstances, treatment modalities, and outcome of this rare condition. To our knowledge, this is the largest systematic review of the literature to date to describe this unusual complication and propose a treatment algorithm.

## Material and Methods

Two cases of splenic bleeding after colonoscopy occurred at our institution and were treated with proximal splenic artery splenic embolization (PSAE). They were compared with similar cases in the literature. A PubMed search for English, French, German, and Italian articles was performed using the following key words: “splenic,” “spleen,” “colonoscopy,” “rupture,” “trauma,” “embolization,” and “computed tomography (CT) scan.” Referenced articles were also considered. Because the first case to be treated by PSAE was reported in 2002, only relevant reports published between 2002 and 2010 were considered in the search flow chart (Fig. 1).

### Case No. 1

A 66 year-old man underwent colonoscopy to investigate recurrent episodes of rectal bleeding. His medical history included hypertension, diabetes, hypercholesterolemia, severe vascular disease with hemorrhagic cerebrovascular events, multiple peripheral arterial revascularizations with iliac artery replacement, and pancreaticojejunostomy for

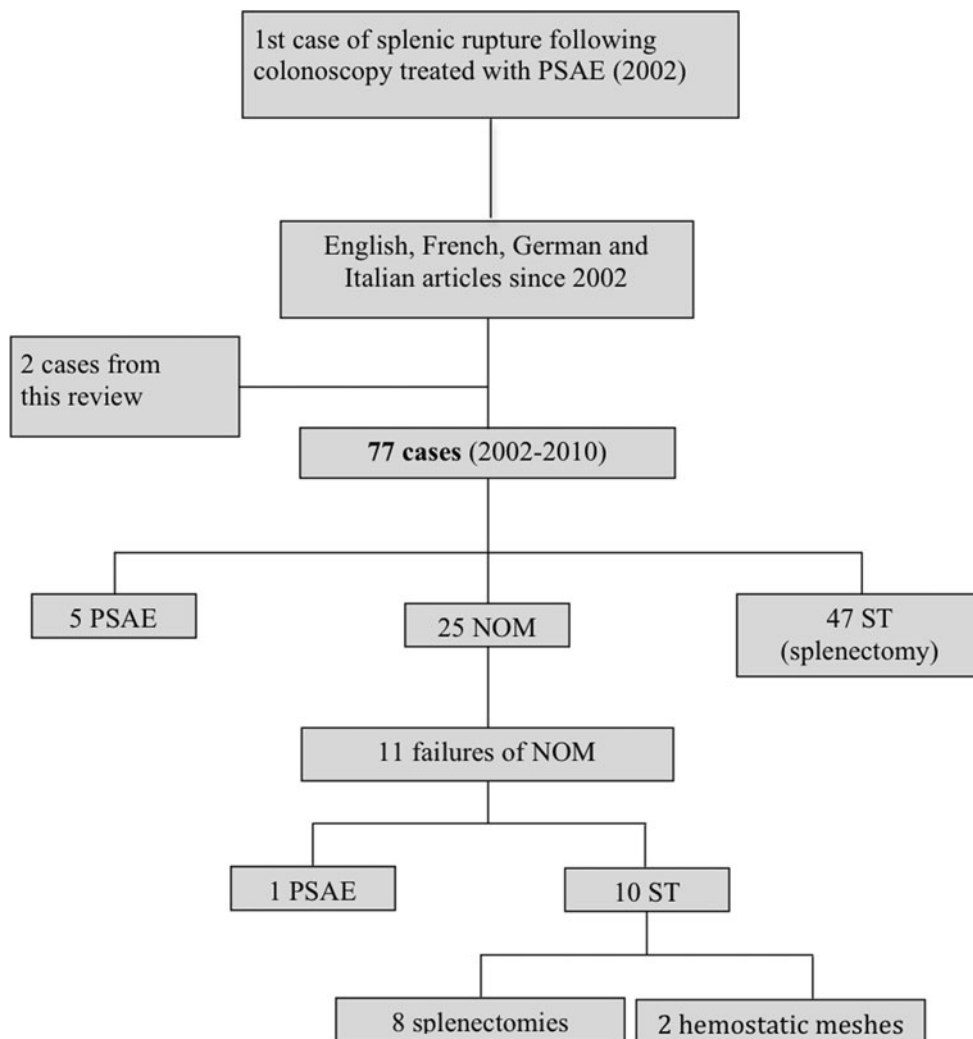
chronic pancreatitis. Ongoing antiplatelet therapy was stopped for the procedure. Coagulation tests 3 days before colonoscopy were normal, and the hemoglobin concentration was 138 g/l. The patient was sedated with 5 mg midazolam and 50 mg pethidine. The colonoscopy was performed by a trainee and lasted 50 min with no reported difficulties. Cecal and transverse polypectomies were performed, leaving a sessile rectal polyp in situ because of its large implantation base of 5 cm. Twelve hours after colonoscopy, the patient complained of sudden abdominal pain. On admission to the emergency room, his blood pressure was 84/55 mm Hg and heart rate 100 bpm. Physical examination showed signs of peritoneal irritation. Hemodynamic stabilization was obtained with rapid perfusion of 1,000 ml saline solution. The initial hemoglobin concentration was 86 g/l and the hematocrit 26 %, with normal blood coagulation tests. Abdominal CT scan showed hemoperitoneum in all four abdominal quadrants with grade IV splenic rupture based on the American Association for the Surgery of Trauma (AAST) classification [5] as well as active intraperitoneal bleeding (Fig. 2A, B). Active arterial splenic bleeding was not identified on selective angiography performed immediately after CT scan (Fig. 3A). Nevertheless, PSAE was performed with the patient under local anesthesia by placing a series of coils in the median part of the splenic trunk. This resulted in proximal splenic artery occlusion and interrupted distal flow causing immediate significant hemodynamic improvement (Fig. 3B, C).

The patient was monitored in the intensive care unit with ongoing fluid resuscitation. He received 2 U packed red cells (PRCs) and 2 U fresh frozen plasma (FFP). The clinical course was favorable, and the hemoglobin concentration remained stable. Follow-up CT scan showed regression of both subcapsular hematoma and free peritoneal fluid. Resection of the remaining tubulo-villous rectal adenoma by transanal endoscopic microsurgery was performed 11 days after embolization. However, the patient then developed a pneumococcal bacteremia, which was successfully treated with 10 days of antibiotherapy; he was finally discharged from the hospital 33 days after admission. Control CT scan performed 4 months after the procedure showed a well-vascularized spleen, and the platelet count was normal ( $256 \times 10^9$  thrombocytes/l).

### Case No. 2

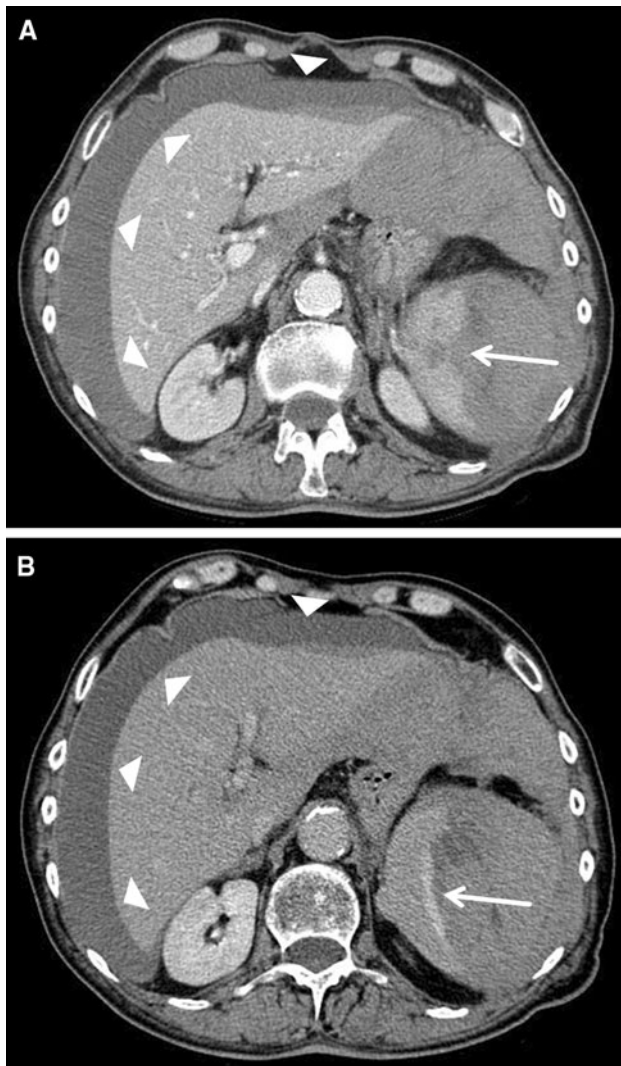
A 74-year-old woman was referred to our institution for a large cecal polyp that had been diagnosed in another hospital during a screening colonoscopy for constipation. Because of the size of the tumor, it could not be removed during the same procedure. Relevant medical history included beta blockers and acenocoumarol; the surgical history included

**Fig. 1** Flow chart of systematic search. *PSAE* proximal splenic artery embolization, *NOM* non-operative management, *ST* surgical treatment



hysterectomy and appendectomy. Acenocoumarol was replaced by therapeutic low molecular-weight heparin in preparation for a second colonoscopy. This procedure was performed without patient sedation by a senior gastroenterologist consultant. The procedure lasted 20 min. The cecal polyp could not be removed; however, rectal and transverse polypectomies were performed. One hour after discharge, the patient suddenly experienced progressive abdominal pain without rectal bleeding. The next day, she had syncope and was transferred to the hospital. Her blood pressure was 75/47 mm Hg on admission, and the heart rate was 75 bpm. The physical examination showed signs of generalized peritoneal irritation. The patient responded well to resuscitation with 1,000 ml saline solution and 500 ml colloids and recovered a systolic pressure of 110 mm Hg. The hemoglobin concentration was 54 g/l; the hematocrit was 16 %; and blood coagulation tests were normal. Erect chest

radiography showed no air under the diaphragmatic cupula. Abdominal CT scan showed hemoperitoneum in all four abdominal quadrants with an AAST grade IV splenic rupture [5]. PSAE was performed with coils with the patient under local anesthesia, and controlled the bleeding. The patient received 2 U PRC during the procedure. She was monitored in the intensive care unit and received an additional 4 U PRC and 2 U FFP. The patient remained stable throughout the rest of the hospital stay and did not require any additional transfusions. However, she developed pneumonia from an unknown bacteria 3 days after the procedure. Control CT scan performed 3 days after embolization showed a stable perisplenic hematoma and regression of hemoperitoneum. The patient was finally discharged from the hospital 11 days after the procedure. Ten months after embolization, the platelet count was within the normal range ( $309 \times 10^9$  thrombocytes/l).



**Fig. 2** Abdominal CT-scan showing a massive hemoperitoneum (arrowheads) due to complete splenic rupture (arrow). **A** Early (arterial) contrast enhanced acquisition. **B** Late contrast enhanced acquisition. Extravasation of contrast media throughout the splenic rupture (arrow)

## Results

Seventy-five cases of splenic bleeding after colonoscopy have been reported in 51 publications [6–57]. Available data on patient characteristics, management, and outcome—including sex; age; colonoscopy type and any difficulties; sedation; additional procedures, such as biopsy; previous surgery; medications that increase the risk of bleeding; time until the first symptoms; hemodynamic instability; number of units of PRC transfused; intra-abdominal adhesions; length of hospital stay; and outcome—were collected and are listed in Tables 1 and 2. All of these factors were analyzed for the three different types of treatment.

## Patient Data

The median age at colonoscopy was 65 years (range 29–85). The prevalence of iatrogenic splenic injury was higher in women than in men (56 of 77 vs. 21 of 77 patients). The six patients treated with PSAE were older than those treated with surgical treatment (ST) and nonoperative management (NOM) at a median age of 70.5 (range 60–81), 63.6 (range 38–82), and 60 (range 29–85) years respectively.

Previous abdominal surgery was reported in 4 of 6 patients who underwent PSAE. In the ST group, 20 of 45 (44.4 %) patients had undergone previous abdominal surgery, but there were no data on previous surgery in 12 of 57 patients. Intra-abdominal adhesions were identified in 10 of 13 patients in the ST group, whereas no data were reported in 44 of 57 patients. There were no data on intra-abdominal adhesions or previous surgery in 6 of 14 patients in the NOM group. Seven of the 8 remaining patients who received NOM had undergone previous abdominal surgery. A pathological spleen was only found in 1 of 77 cases. This was due to primary amyloidosis and surgery was performed; however, there were no data on its size [23].

## Colonoscopy

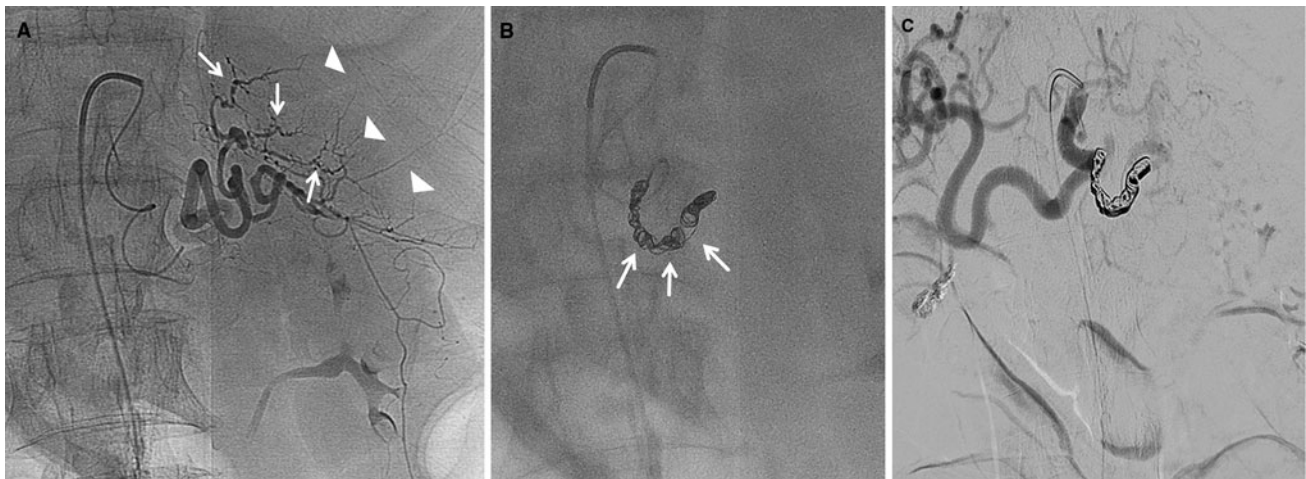
Diagnostic and screening colonoscopies were performed in 49 of 71 (69.0 %) and 22 of 71 (31.0 %) patients, respectively. Reports show that procedures were performed without any difficulty or external intraoperative manoeuvres in 35 of 51 patients (68.6 %). There was no data on sedation in most cases (60 of 77). Biopsy or polypectomy procedures were performed in 31 of 57 patients (54.4 %), whereas no data were reported in the remaining 20 of 77. Biopsy or polypectomy procedures were performed in several sites in the colon but predominantly in the rectum and descending colon (15 patients), the transverse colon (5 patients), and the ascending colon and cecum (10 patients). This information was only reported in 23 of 77 patients.

## Anticoagulants, Antiplatelet Therapy, or Medication Increasing the Risk of Bleeding

Information on medications that increase the risk of bleeding, such as anticoagulants, antiplatelets, nonsteroidal anti-inflammatory drugs (NSAIDs), and acetylsalicylic acid (ASA), was available in 30 of 77 patients (39 %) (4 of 6 in the PSAE, 22 of 57 in the ST, and 4 of 14 in the NOM groups). These treatments were being taken by 13 of 30 (43 %) of these patients (3 of 4 in the PSAE, 8 of 22 in the ST, and 2 of 4 in the NOM groups).

## Clinical Presentation at Hospital

Seventy-four patients presented with signs and symptoms of splenic rupture within a median of 12 h after the



**Fig. 3** Splenic arteriography. **A** The splenic vessels are grossly displaced by the perisplenic hematoma (*arrowheads*). The diameter is also irregular with active vascular spasm (*arrow*), but no obvious active bleeding. **B** Embolization of the proximal splenic artery by

coils (*arrows*) placed in the median part of the splenic trunk. **C** The blood flow in the distal splenic artery has been interrupted by embolization

procedure (range 0–288). This information was not available for 3 of 77 patients. The onset of symptoms was delayed by several days in 9 of 74 cases. At admission, 47 of 69 patients (68.1 %) were found to be hemodynamically unstable. An emergency procedure (1 SAE and 10 ST) was required in 11 patients who became unstable after admission.

#### Number of Units of PRCs

The number of units of PRCs transfused did not depend on the type of treatment. Transfusions with a median of 4 U PRC (range 1–14) were reported in 26 of 30 patients, whereas this information was not provided for 47 of 77 patients. On arrival in the emergency room, the decrease in hemoglobin levels was 52 and 54 g/l, respectively, in 2 PSAE patients and a median of 52 g/l (range 18–85) in 13 ST patients but only a median of 20 g/l in 5 NOM patients (range 11–54). Moreover, embolization was effective in 3 PSAE patients who were taking anticoagulation or antiplatelet therapy with 1, 4, and 5 U PRC transfused, respectively.

#### Management

Percutaneous PSAE was performed in 6 of 77 patients (7.8 %). Laparotomy and splenectomy were performed in 57 of 77 cases (74 %). Conservative treatment (NOM), which included bed rest, transfusions, and pain control, was performed in 25 of 77 patients (32.5 %). It was successful in 14 of 25 patients (56 %), but rebleeding occurred in 11 of 25 patients (44 %). Surgery—including 8 splenectomies, 2 hemostatic meshes, and 1 PSAE—was performed in 10 cases due to hemodynamic instability or secondary rupture. Splenic lesions, except for blunt splenic trauma, were not

routinely graded according to AAST classification, making determination of splenic lesions difficult [5].

#### Outcome

Patients stayed in the hospital for a median of 10 days (range 3–12) in the PSAE group (5 of 6 patients), 9 days (range 3–22) in the ST group (29 of 57 patients), and 3 days (range 0–10) in the NOM group (11 of 14 patients). Pulmonary complications developed in 3 of 6 patients in the PSAE group. One patient died from respiratory insufficiency due to worsening of chronic obstructive airway disease [9]. In the ST group, 13 of 57 (22.8 %) patients developed complications, mostly respiratory insufficiency and postoperative ileus. One patient with pulmonary silicosis developed postoperative respiratory insufficiency and died 16 days after splenectomy [30]. Another patient underwent 3 additional operations: one for postoperative bleeding, one for intestinal obstruction due to adhesions 1 month later, and finally a third laparotomy for intestinal perforation, after which the patient died [30]. Wound infections, myocardial infarcts, rebleeding, secondary infection of the splenic hematoma, and pancreatic duct injury were also reported as complications. No complications were observed in the 14 of 25 patients who were successfully treated with NOM.

#### Discussion

The two cases reported here had severe bleeding from splenic rupture after colonoscopy and were treated successfully by PSAE. Although very rare, post colonoscopy intraperitoneal hemorrhage is usually reported to be due to splenic injury. Other sources of hemoperitoneum after colonoscopy are

**Table 1** Clinical presentation and management

Management (n)	Sex (F/M)	Age (y)	Diagnostic vs. screening colonoscopy	Difficulties or external manoeuvres during colonoscopy		Sedation		Biopsies or polypectomies during procedure		Previous abdominal surgery		Anticoagulation				
				Yes	No	Yes	No	Yes	No	Yes	No	Yes	No	Yes	No	
PSAE (5 + 1 = 6)	2/4	70.5 (60–81)	6	0	1	4	1	2	1	3	3	2	1	3	1	2
ST (47 + 10 = 57)	40/17	63.6 (38–82)	36	16	12	25	20	12	1	44	24	17	16	20	25	12
NOM (25–11 = 14)	14/0	60 (29–85)	7	6	3	6	5	1	0	13	4	7	3	7	1	6

Median age values and range (parentheses) are given

PSAE proximal splenic artery embolization, ST surgical treatment, NOM non-operative management. Anticoagulation includes anticoagulant drug, platelet inhibitors, acetylsalicylic acid and non steroidal anti-inflammatory

extremely unusual and include a torn mesenteric vessel, a ruptured appendix epiploica, and bleeding from a necrotic intestinal leiomyosarcoma [58].

Hypothetic mechanisms of splenic injury are direct trauma by the endoscope when it is positioned in the splenic flexure or excessive traction on the splenicocolic ligament when pushing the endoscope into the transverse colon. The result is avulsion of the splenic capsule and parenchymal disruption of various grades. Predisposing factors, such as previous intra-abdominal surgery causing adhesions, splenomegaly, medications increasing the risk of bleeding, difficult colonoscopy, and therapeutic colonoscopy, have been suggested [7, 36]. The present review confirms that previous surgery and the presence of adhesions are risk factors of splenic injury: Adhesions have been reported in 10 of 13 patients who underwent surgery, whereas 31 of 59 had undergone previous surgery. Diagnostic colonoscopies (49 of 71 patients), biopsies, or polypectomies (31 of 57) and female sex (56 of 77) were other identified risk factors. Conversely, splenomegaly (0 of 77 patients with 1 case of amyloidosis without splenomegaly [23]), medications that increase the risk of bleeding (13 of 30 cases), and difficult colonoscopies (16 of 51 cases) were not identified as risk factors. Although recent data have suggested that inflammatory bowel disease, pancreatitis, rapid completion time, a history of chronic smoking, propofol sedation, and inadequate colon wash-out were associated with a greater risk of splenic rupture [36, 59], there were no data on these issues in this review.

Splenic bleeding after colonoscopy is life-threatening. This review showed that 47 of 69 (68.1 %) patients presented with hemodynamic shock at diagnosis. Small splenic lesions might be misdiagnosed in patients with slight symptoms who do not consult a physician or in whom further investigations are not performed. Thus, the most severe cases of splenic rupture are seen in the hospital and require emergency management. Most patients described in this article presented with severe bleeding corresponding to high grades of splenic trauma (III to IV) according to the AAST classification [5] with 26 of 30 patients requiring transfusion.

Because this condition can be fatal, active management should be started with fluid resuscitation, followed-up by abdominal CT-scan for diagnosis, as long as the patient remains hemodynamically stable. A flow chart for management is shown in Fig. 4.

Management of this isolated organ trauma should follow AAST recommendations for management of blunt splenic trauma. Thus, the protocol for investigating patients with severe acute abdominal pain after colonoscopy, especially if it is associated with hemodynamic shock, should be FAST (focused assessment with sonography for trauma) and contrast-enhanced abdominal CT scan, both of which

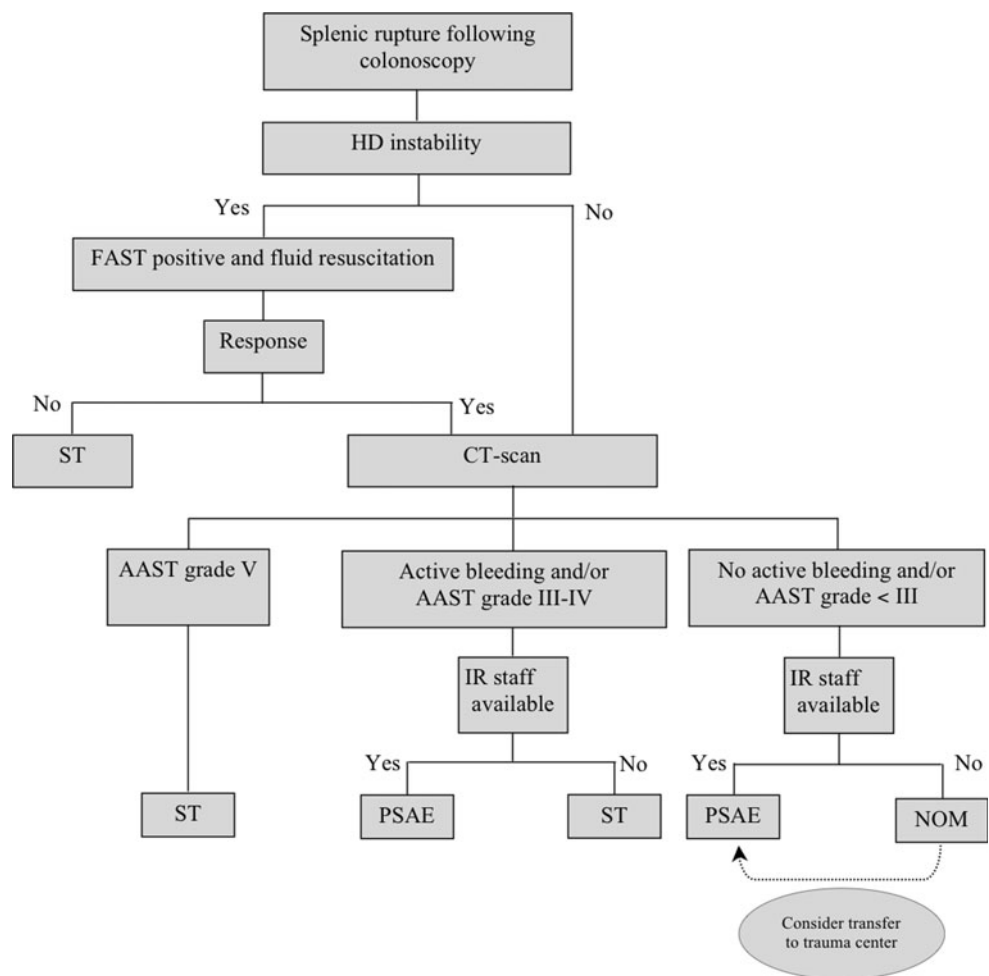
**Table 2** Clinical presentation and management

Management (n)	Time (h) until onset of symptoms from colonoscopy (median, range)	Decrease in hemoglobin rate (g/l)		Presence of hemodynamic instability (systolic BP < 90 mm Hg, tachycardia, tachypnea)			Number of U of PRC transfusions		Presence of intra-abdominal adhesions			Length of hospital stay (d)		Postoperative complications (medical and surgical)			
		No data	No data	Yes	No	No data	No data	Yes	No	No data	No data	Yes	No	No data			
PSAE (5 + 1 = 6)	36 (1–120)	0	53 (52–54)	4	5	0	1	4 (1–5)	1	NA		10 (3–12)	1	3	2	1	
ST (47 + 10 = 57)	12 (0–288)	2	52 (18–85) no decrease : 1	43	42	12	3	5 (2–14)	37	10	3	44	9 (3–22)	28	13	29	15
NOM (25–11 = 14)	6 (3–96)	1	20 (11–54)	9	0	10	4	4 (4–6)	9	NA		3 (0–10)	3	0	12	2	

Median age values and range (parentheses) are given

PSAE proximal splenic artery embolization, ST surgical treatment, NOM non-operative management, PRC packed red cells, ND no data available, NA not applicable

**Fig. 4** Management of splenic rupture following colonoscopy, PSAE proximal splenic artery embolization, NOM non operative management, ST surgical treatment, IR interventional radiologist, AAST American Association for the Surgery of Trauma, FAST focused assessment with sonography for trauma



are the standard diagnostic tools used in the setting of blunt abdominal trauma [5]. Sensitivity of FAST for intra-abdominal fluid detection in hemodynamically unstable patients is considered to be between 63 and 96 % [60].

A positive FAST is usually a sufficient indication for exploratory laparotomy. Abdominal CT scan is the imaging modality of choice in hemodynamically stable patients or in those with a positive response to fluid resuscitation. The

sensitivity and specificity of CT scan for the detection of splenic injuries is as high as 98 % [60]. In the two reported cases, intra-abdominal hemorrhage secondary to splenic rupture was confirmed by contrast-enhanced CT scan. The injury should be radiologically graded in reference to the AAST classification for blunt splenic trauma [5], and although there is no definite consensus, grades of up to III and IV should usually be treated with PSAE or ST, whereas grades I and II should be treated with NOM [61]. Recent publications suggest that PSAE could be more beneficial in patients with low-grade splenic injury [62]. Grade V injuries require ST. The use of NOM has increased in the past decade, and an estimated 85 % patients now undergo this treatment [63]. Nevertheless, in case of post colonoscopy trauma, NOM seems to fail more frequently than for blunt trauma with 11 of 25 patients (44 %) requiring a salvage procedure (PSAE or ST) compared with 16 of 159 of patients (10 %), respectively [64]. In addition, PSAE is increasingly performed in combination with NOM, thus decreasing the failure rate from 12–13 to 2–3 % [63, 65, 66]. PSAE appears to be safe and effective even in elderly patients with comorbidities and those taking medication that increase the risk of bleeding. The 2 cases reported in this review corresponded to grade IV injuries, suggesting that manipulation of the colonoscope on the splenic flexure may be as severe or worse than blunt external trauma. PSAE provided effective long-term haemostasis in both cases. Due to high failure rate of NOM in this specific condition, a more extensive use of PSAE, compared with usual recommendation in the general polytrauma population, can be proposed [61].

Obviously, risk factors, such as hemodynamic instability or not responding to fluid resuscitation, advanced age with the presence of severe associated diseases, or medications that increase the risk of bleeding, must be taken into consideration. Nevertheless considering the high failure rate of NOM alone, a conservative therapeutic approach combined with interventional radiology should be an alternative to surgery.

Interestingly, PSAE did not decrease the hospital stay compared with ST. Some surgeons may feel safer and more comfortable with performing a splenectomy than embolization due to a perceived risk of secondary rupture of the spleen. Death occurred in 3 of 77 patients (3.9 %) (2 in the ST group and 1 in the PSAE group). Considering that only isolated splenic traumas were included, this rate is significantly lower than that (8 %) after splenectomy for external blunt trauma [4]. Our two patients developed pneumonia during hospitalization. Although splenic function does not seem to be impaired after PSAE [4], the blood culture of the first patient was positive for *Streptococcus pneumoniae* 10 days after the procedure. Platelet counts in both patients remained normal a few months after the procedure. PSAE is a well-tolerated technique that presents no major long-

term influence on splenic function in patients with sufficient immunity against *Haemophilus influenzae B* and pneumococcus. Although vaccination against these bacteria has been suggested, no consensus exists for cases of splenic artery embolization [4].

To our knowledge, only four previous cases of endovascular treatment of splenic rupture after colonoscopy have been reported [6–9]. Our analysis suggests that this complication is underestimated and underreported, with <80 cases having been reported worldwide between 2002 and 2010.

In conclusion, although colonoscopy performed by an experienced operator is a safe procedure, it is by no means harmless. Splenic rupture, such as bowel perforation and intraluminal bleeding, should be considered as a potential cause of abdominal pain in the presence of hemodynamic shock after colonoscopy. Because of the extended indications for colonoscopy, clinicians should be more aware of this complication. The identified risk factors are adhesions, female sex, diagnostic colonoscopy with biopsy, and medications that increase the risk of bleeding. Splenic lesions are high-grade, and conservative management is associated with a high failure rate. Thus, active management with a less invasive procedure, such as PSAE, should always be considered in a patient with splenic rupture after colonoscopy. PSAE for isolated splenic trauma is safe and effective and should be considered the method of choice in the above-mentioned specific situations according to the flow chart guidelines.

**Conflict of interest** All the authors declare that they have no conflict of interest.

## References

1. Vijan S, Inadomi J, Hayward RA et al (2004) Projections of demand and capacity for colonoscopy related to increasing rates of colorectal cancer screening in the United States. *Aliment Pharmacol Ther* 20:507–515
2. Macrae FA, Tan KG, Williams CB (1983) Towards safer colonoscopy: a report on the complications of 5000 diagnostic or therapeutic colonoscopies. *Gut* 24:376–383
3. Schwesinger WH, Levine BA, Ramos R (1979) Complications in colonoscopy. *Surg Gynecol Obstet* 148:270–281
4. Bessoud B, Duchosal MA, Siegrist CA et al (2007) Proximal splenic artery embolization for blunt splenic injury: clinical, immunologic, and ultrasound-doppler follow-up. *J Trauma* 62:1481–1486
5. Moore EE, Cogbill TH, Jurkovich GJ et al (1995) Organ injury scaling: spleen and liver (1994 revision). *J Trauma* 38:323–324
6. Stein DF, Myaing M, Guillaume C (2002) Splenic rupture after colonoscopy treated by splenic artery embolization. *Gastrointest Endosc* 55:946–948
7. Holubar S, Dwivedi A, Eisdorfer J et al (2007) Splenic rupture: an unusual complication of colonoscopy. *Am Surg* 73:393–396
8. Parker WT, Edwards MA, Bittner JG 4th et al (2008) Splenic hemorrhage: an unexpected complication after colonoscopy. *Am Surg* 74:450–452



9. de Vries J, Ronnen HR, Oomen AP et al (2009) Splenic rupture following colonoscopy, a rare complication. *Neth J Med* 67:203–230
10. Rinzivillo C, Minutolo V, Gagliano G et al (2003) Splenic trauma following colonoscopy. *G Chir* 24:309–311
11. Al Alawi I, Gourlay R (2004) Rare complication of colonoscopy. *ANZ J Surg* 74:605–606
12. Goitein D, Goitein O, Pikarski A (2004) Splenic rupture after colonoscopy. *Isr Med Assoc J* 6:61–62
13. Jaboury I (2004) Splenic rupture after colonoscopy. *Intern Med J* 34:652–653
14. Janes SE, Cowan IA, Dijkstra B (2005) A life threatening complication after colonoscopy. *BMJ* 330(7496):889–890
15. Naini MA, Masoompour SM (2005) Splenic rupture as a complication of colonoscopy. *Indian J Gastroenterol* 24:264–265
16. Shah PR, Raman S, Haray PN (2005) Splenic rupture following colonoscopy: rare in the UK? *Surgeon* 3:293–295
17. Weisgerber K, Lutz MP (2005) Splenic rupture after colonoscopy. *Clin Gastroenterol Hepatol* 3:A24
18. Johnson C, Mader M, Edwards DM et al (2006) Splenic rupture following colonoscopy: two cases with CT findings. *Emerg Radiol* 13:47–49
19. Luebke T, Baldus SE, Holscher AH et al (2006) Splenic rupture: an unusual complication of colonoscopy: case report and review of the literature. *Surg Laparosc Endosc Percutan Tech* 16:351–354
20. Shatz DV, Rivas LA, Doherty JC (2006) Management options of colonoscopic splenic injury. *JLSLS* 10:239–243
21. Volchok J, Cohn M (2006) Rare complications following colonoscopy: case reports of splenic rupture and appendicitis. *JLSLS* 10:114–116
22. Zenooz NA, Win T (2006) Splenic rupture after diagnostic colonoscopy: a case report. *Emerg Radiol* 12:272–273
23. Zerbi S, Crippa S, Di Bella C et al (2006) Splenic rupture following colonoscopy in a hemodialysis patient. *Int J Artif Organs* 29:335–336
24. Di Lecce F, Viganò P, Pilati S et al (2007) Splenic rupture after colonoscopy. a case report and review of the literature. *Chir Ital* 59:755–757
25. Lalor PF, Mann BD (2007) Splenic rupture after colonoscopy. *JLSLS* 11:151–156
26. Pfefferkorn U, Hamel CT, Viehl CT et al (2007) Haemorrhagic shock caused by splenic rupture following routine colonoscopy. *Int J Colorectal Dis* 22:559–560
27. Cappellani A, Di Vita M, Zanghì A et al (2008) Splenic rupture after colonoscopy: report of a case and review of literature. *World J Emerg Surg* 3:8
28. Famularo G, Minisola G, De Simone C (2008) Rupture of the spleen after colonoscopy: a life-threatening complication. *Am J Emerg Med* 26:834
29. Guerra JF, San Francisco I, Pimentel F et al (2008) Splenic rupture following colonoscopy. *World J Gastroenterol* 14:6410–6412
30. Petersen CR, Adamsen S, Gocht-Jensen P et al (2008) Splenic injury after colonoscopy. *Endoscopy* 40:76–79
31. Pichon N, Mathonnet M, Verdrière F et al (2008) Splenic trauma: an unusual complication of colonoscopy with polypectomy. *Gastroenterol Clin Biol* 32:123–127
32. Schilling D, Kirr H, Mairhofer C et al (2008) Splenic rupture after colonoscopy. *Dtsch Med Wochenschr* 133:833–835
33. Kamath AS, Iqbal CW, Sarr MG et al (2009) Colonoscopic splenic injuries: incidence and management. *J Gastrointest Surg* 13:2136–2140
34. Kiosoglous AJ, Varghese R, Memon MA (2009) Splenic rupture after colonoscopy: a case report. *Surg Laparosc Endosc Percutan Tech* 19:e104–e105
35. Lewis SR, Ohio D, Rowley G (2009) Splenic injury as a rare complication of colonoscopy. *Emerg Med J* 26:147
36. Sarhan M, Ramcharan A, Ponnappalli S (2009) Splenic injury after elective colonoscopy. *JLSLS* 13:616–619
37. Patselas TN, Gallagher EG (2009) Splenic rupture: an uncommon complication after colonoscopy. *Am Surg* 75:260–261
38. Skipworth JR, Raptis DA, Rawal JS et al (2009) Splenic injury following colonoscopy—an underdiagnosed, but soon to increase, phenomenon? *Ann R Coll Surg Engl* 91:W6–W11
39. Younes NA, Al-Ardah MI, Daradkeh SS (2009) Rupture of spleen post colonoscopy. *Saudi Med J* 30:1095–1097
40. DuCoin C, Acholonu E, Ukleja A et al (2010) Splenic rupture after screening colonoscopy: case report and literature review. *Surg Laparosc Endosc Percutan Tech* 20:e31–e33
41. Meier RP, Toso C, Volonte F et al (2011) Splenic rupture after colonoscopy. *Am J Emerg Med* 29:241.e1–241.e2
42. Michetti CP, Smeltzer E, Fakhry SM (2010) Splenic injury due to colonoscopy: Analysis of the world literature, a new case report, and recommendations for management. *Am Surg* 76:1198–1204
43. Murariu D, Takekawa S, Furumoto N (2010) Splenic rupture: A case of massive hemoperitoneum following therapeutic colonoscopy. *Hawaii Med J* 69:140–141
44. Rasul T, Leung E, McArdle K et al (2010) Splenic rupture following routine colonoscopy. *Dig Endosc* 22:351–353
45. Pothula A, Lampert J, Mazeh H et al (2010) Splenic rupture as a complication of colonoscopy: report of a case. *Surg Today* 40:68–71
46. Stauch P, Dietrich P, Bernhard M et al (2010) Spleen ruptures after screening colonoscopy. *Chirurg* 81:746–749
47. Theodoropoulos J, Krecioch P, Myrick S et al (2010) Delayed presentation of a splenic injury after colonoscopy: a diagnostic challenge. *Int J Colorectal Dis* 25:1033–1034
48. Weidman MW, Kater F, Bohme B (2010) Splenic rupture following endoscopic polypectomy. *Z Gastroenterol* 48:476–478
49. Hamzi L, Soyer P, Boudiaf M et al (2003) Splenic rupture following colonoscopy: report of an unusual case in the absence of underlying splenic disease. *J Radiol* 84:320–322
50. Boghossian T, Carter JW (2004) Early presentation of splenic injury after colonoscopy. *Can J Surg* 47:148
51. Holzer K, Thalhammer A, Bechstein WO (2004) Splenic trauma—a rare complication during colonoscopy. *Z Gastroenterol* 42:509–512
52. Leaks BJ (2004) Splenic hematoma as a complication of colonoscopy. *J Am Geriatr Soc* 52:320–321
53. Prowda JC, Trevisan SG, Lev-Toaff AS (2005) Splenic injury after colonoscopy: conservative management using CT. *AJR Am J Roentgenol* 185:708–710
54. Tsoraides SS, Gupta SK, Estes NC (2007) Splenic rupture after colonoscopy: case report and literature review. *J Trauma* 62:255–257
55. Duarte CG (2008) Splenic rupture after colonoscopy. *Am J Emerg Med* 26:117
56. Saad A, Rex DK (2008) Colonoscopy-induced splenic injury: report of 3 cases and literature review. *Dig Dis Sci* 53:892–898
57. Ranganath R, Selinger S (2009) An uncommon complication of a common procedure. *Postgrad Med J* 85(1002):224
58. Tagg W, Woods S, Razdan R et al (2008) Hemoperitoneum after colonoscopy. *Endoscopy* 40(Suppl 2):E136–E137
59. Rao KV, Beri GD, Sterling MJ et al (2009) Splenic injury as a complication of colonoscopy: a cases series. *Am J Gastroenterol* 104:1604–1605
60. Poletti PA, Wintermark M, Schnyder P et al (2002) Traumatic injuries: role of imaging in the management of the polytrauma victim (conservative expectation). *Eur Radiol* 12:969–978
61. Van der Vlies CH, van Delden OM, Punt BJ et al (2010) Literature review of the role of ultrasound, computed tomography and transcatheter arterial embolization for the treatment of traumatic splenic injuries. *Cardiovasc Interment Radiol* 33(6):1079–1087
62. Van der Vlies CH, Hoekstra J, Ponsen KJ et al (2012) Impact of splenic artery embolization on the success rate of nonoperative

- management for blunt splenic injury. *Cardiovasc Intervent Radiol* 35(1):76–81
63. Moore FA, Davies JW, Moore EE et al (2008) Western Trauma Association (WTA) critical decision in trauma: management of adult blunt splenic trauma. *J Trauma* 65:1007–1011
64. Renzulli P, Hostettler A, Schoepfer AM et al (2009) Systematic review of atraumatic splenic rupture. *Br J Surg* 96:1114–1121
65. Bessoud B, Denys A (2004) Main splenic artery embolisation using coils in blunt splenic injuries: effects on the intrasplenic blood pressure. *Eur Radiol* 14:1718–1719
66. Haan JM, Biffi W, Knudson MM et al (2004) Splenic embolization revisited: a multicenter review. *J Trauma* 56:542–547