

Systematic Review of Delayed Postoperative Hemorrhage after Pancreatic Resection

Didier Roulin · Yannick Cerantola ·
Nicolas Demartines · Markus Schäfer

Received: 6 November 2010 / Accepted: 11 January 2011 / Published online: 26 January 2011
© 2011 The Society for Surgery of the Alimentary Tract

Abstract

Introduction This review assesses the presentation, management, and outcome of delayed postpancreatectomy hemorrhage (PPH) and suggests a novel algorithm as possible standard of care.

Methods An electronic search of Medline and Embase databases from January 1990 to February 2010 was undertaken. A random-effect meta-analysis for success rate and mortality of laparotomy vs. interventional radiology after delayed PPH was performed.

Results Fifteen studies comprising of 248 patients with delayed PPH were included. Its incidence was of 3.3%. A sentinel bleed heralding a delayed PPH was observed in 45% of cases. Pancreatic leaks or intraabdominal abscesses were found in 62%. Interventional radiology was attempted in 41%, and laparotomy was undertaken in 49%. On meta-analysis comparing laparotomy vs. interventional radiology, no significant difference could be found in terms of complete hemostasis (76% vs. 80%; $P=0.35$). A statistically significant difference favored interventional radiology vs. laparotomy in term of mortality (22% vs. 47%; $P=0.02$).

Conclusions Proper management of postoperative complications, such as pancreatic leak and intraabdominal abscess, minimizes the risk of delayed PPH. Sentinel bleeding needs to be thoroughly investigated. If a pseudoaneurysm is detected, it has to be treated by interventional angiography, in order to prevent a further delayed PPH. Early angiography and embolization or stenting is safe and should be the procedure of choice. Surgery remains a therapeutic option if no interventional radiology is available, or patients cannot be resuscitated for an interventional treatment.

Keywords Postpancreatectomy hemorrhage · Sentinel bleed · Pseudoaneurysm

Introduction

Despite the fact that modern pancreatic surgery has successfully evolved during recent years, postoperative hemorrhage still represents an important source of concern

after major pancreatic resection. Together with delayed gastric emptying, pancreatic fistula and intraabdominal infections (i.e., abscess formation), bleeding complications mainly contribute to the high rate of postoperative morbidity after pancreatic surgery.^{1–5}

Standardized definition and classification of postpancreatectomy hemorrhage (PPH) have been lacking until recently. In consequence incidences and mortality rates in the literature reveal a large range from 2% to 18% and 15% to 60%, respectively.^{1,3–8} To overcome these shortcomings, the International Study Group of Pancreatic Surgery (ISGPS) proposed a new classification of PPH based on time of onset, location, and severity of hemorrhage.⁹ Early PPH within 24 h postoperatively is generally caused by a technical failure of appropriate hemostasis at anastomotic sites, e.g., suture lines and resection area, or by an underlying perioperative coagulopathy.⁶ Delayed PPH after the first postoperative day, is related to ulceration of

D. Roulin · Y. Cerantola · N. Demartines · M. Schäfer
Department of Visceral Surgery,
University Hospital of Lausanne (CHUV),
Lausanne, Switzerland

M. Schäfer (✉)
Service de Chirurgie Viscérale, CHUV,
Rue du Bugnon 46,
1011 Lausanne, Switzerland
e-mail: markus.schafer@chuv.ch

gastroenteral anastomosis (marginal ulcer), leakage of venous anastomosis after portal vein resection or, more importantly, to erosion of peripancreatic vessels. Stepwise erosion of the celiac trunk and the superior mesenteric artery induces pseudoaneurysm formation that may subsequently rupture.

While early bleeding can be treated rather easily, delayed PPH is more difficult to manage. Since typical clinical signs such as sentinel bleeding heralding pseudoaneurysm formation may be lacking, early diagnosis may not be possible. However, prompt diagnosis and treatment are crucial factors determining successful outcome. During recent years, interventional radiology and gastroenterology offered new approaches for the treatment of various postoperative complications after major pancreatic surgery, and have challenged surgery as rescue procedure.

The aim of the study was to assess the clinical presentation, management, and outcome of delayed PPH by systematically reviewing the current literature, and to provide a novel algorithm as a possible standard of care.

Methods

Literature Search Strategies

An electronic search of Medline and Embase databases was performed using different keywords: pancreatectomy, duodenopancreatectomy, pancreaticoduodenectomy, pancreatic resection, postoperative bleeding, postoperative hemorrhage delayed bleeding, delayed hemorrhage, arterial bleeding, arterial hemorrhage, risk factor, pseudoaneurysm, pancreatic fistula, sentinel bleed, angiography, transcatheter arterial embolization, coil embolization, covered stent, and stent graft. Terms were searched both in isolation and in combinations (Boolean operators). The search terms were identified in the title, abstract or medical subject heading. In addition, hand-searching of electronic links to related articles and of references of selected studies was performed.

Inclusion and Exclusion Criteria

Only original articles that evaluated the outcomes of delayed PPH were included. Delayed PPH was defined, in accordance to the recently published ISGPS classification, as a postoperative bleeding occurring more than 24 h after major pancreatic resection.⁹ The term “pancreatic resection” includes all of the following procedures: pylorus-preserving or classical pancreaticoduodenectomy, pancreatic left (tail) resection, duodenum-preserving pancreatic head resection, pancreatic segment resection, or total pancreatectomy. Studies that evaluated outcomes after other pancreatic

procedures such as necrosectomy and pancreatic transplantation were excluded.

We decided to exclude review articles, studies with less than ten patients, experimental studies, case reports, as well as studies that were only reported as abstracts or letters. Only articles published in English between January 1990 and February 2010 were included.

Data Extraction and Analysis

Summaries and abstracts of each identified publication were screened for exclusion criteria. Only publications, which fulfilled the inclusion criteria and addressed the clinical questions of this analysis, were further assessed. Each of these publications was independently and thoroughly reviewed by D.R. and M.S. Relevant data including authors, title, study design, methodology, main results, and conclusions were extracted and documented on a separate data sheet developed a priori for each publication.

Excel (Microsoft Corp.) was used for all data collection and tables. The meta-analysis was performed by using Review Manager, version 5.0 (The Cochrane Collaboration) according to its instructions. The Mantel–Haenszel method was used to combine the odds ratio by mean of a random-effect model. An odds ratio of less than 1 favored laparotomy, and the point estimate of the odds ratio was considered to be statistically significant at the level of $P < 0.05$, if the 95% confidence interval did not include the value 1.

Results

The literature search retrieved 1,357 publications. Of these, 1,319 were primarily excluded because they were not relevant (1,303: no outcome data reported, duplicated data, letters and abstracts only), included less than ten patients (10), or were review articles (6). The remaining 38 publications were fully assessed. Another 23 articles were excluded due to incomplete data (11), insufficient number of patients (six), duplicated data (one), lack of relevance (four), or patient inclusion operated before 1980 (one). Finally, 15 studies with 7,400 patients were included for final analysis (Fig. 1). In total, there were 248 patients with delayed PPH (Table 1). All included articles were retrospective case series; eight of them presented prospectively collected data. No randomized controlled trial was found.

Onset of Bleeding

All studies, except two^{10,11} which applied the 24-h cut-off defined by the ISGP definition, used different time points to determine delayed PPH. Six studies^{2,12–16} used the fifth postoperative day, another five studies^{17–21} used the seventh

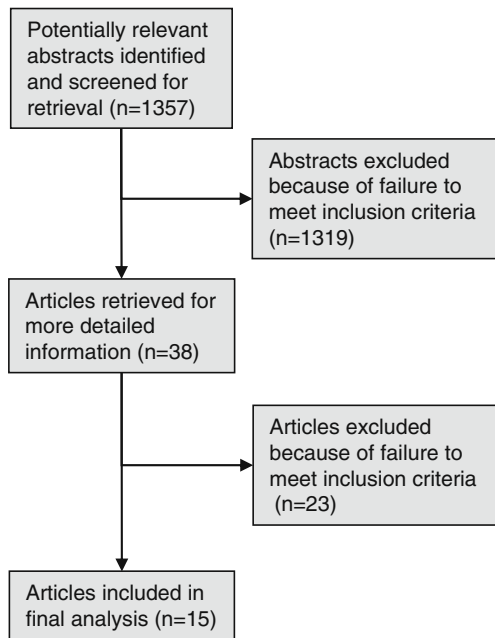


Fig. 1 Flow chart of systematic search

postoperative day, and the two remaining studies^{22,23}, in which all of their PPH occurred after the first postoperative week, did not specify any cut-off as time point.

Incidence, Clinical Presentation, and Risk Factors

There were 248 patients with delayed PPH out of an overall group of 7,400 patients who underwent pancreatic resec-

tion. However, five patients were excluded from the incidence calculation since pancreatic resection was performed outside the index hospital.^{14,21} Therefore, the overall incidence of delayed PPH was 3.3% (243/7,400), ranging from 1.6% to 12.3% among the included studies. While the incidence was 4.5% in studies considering the ISGP definition as time point, studies using the fifth and seventh postoperative day revealed an overall incidence of 2.8% (range 2.0–4.9%) and 3.4% (range 1.9–8.7%), respectively.

Onset of delayed PPH revealed an overall median range of 13 to 27 days postoperatively. The most frequent localization of bleeding was the abdominal cavity in 58% (106/182) of cases, followed by the gastrointestinal tract in 35% (64/182). Seven percent of delayed PPH (12/182) occurred in both the abdominal cavity and the gastrointestinal tract. Sentinel bleeding heralding a PPH was observed in 45% (54/119) of cases. Only three studies^{14,22,23} with a total of 23 sentinel bleedings described their location: 15 were coming from abdominal drains, and eight were originating from the gastrointestinal tract.

A pancreatic leak was found in 78 of 156 patients (50%) with delayed PPH. When cumulating both pancreatic and biliary leaks with intraabdominal abscess, the prevalence of intraabdominal complications reached 62% (96/156). Among five studies analyzing risk factors of PPH,^{2,11,12,17,20} only pancreatic leak was always found to be an independent risk factor. Biliary leak and intraabdominal abscess were also significant prognostic factors in four of these publications.^{2,11,12,17} Balachandran further identified male gender,

Table 1 Incidence and clinical presentation of delayed postpancreatectomy hemorrhage

Authors	Year	Pancreatectomy (n)	PPH (n)	Onset of PPH (median POD)	Sentinel bleed (n)	Type of PPH (n) (GI/IA/both)
Balachandran et al. ¹⁷	2004	218	19	NR	NR	10/9/0
Blanc et al. ¹⁸	2007	411	16	NR	3	5/10/1
Boggi et al. ¹⁹	2007	818	19	NR	4	3/16/0
Buchler et al. ¹⁰	2000	331	12	NR	NR	NR
Choi et al. ¹²	2004	500	22	13	NR	10/12/0
Koukoutsis et al. ²⁰	2006	362	14	13	8	NR
Liu et al. ¹³	2009	308	15	10	NR	4/9/2
Makowiec et al. ²¹	2005	464	12	24	4	7/5/0
Miura et al. ²²	2009	708	11	11	5	0/11/0
Sato et al. ²³	1998	81	10	27	10	NR
Tien et al. ²	2005	402	10	22	3	0/6/4
Treckmann et al. ¹⁴	2008	189	11	17	8	6/5/0
Wei et al. ¹¹	2009	628	31	NR	NR	12/19/0
Yekebas et al. ¹⁵	2007	1,524	30	NR	NR	NR
Yoon et al. ¹⁶	2003	456	16	13	9	7/4/5

PPH postpancreatectomy hemorrhage, POD postoperative day, GI gastrointestinal, IA intraabdominal, NR not reported

longer duration of jaundice, and duct-to mucosa type of pancreaticojejunal anastomosis.¹⁷ Neither the type of operation,^{2,11,12} nor a duration of surgery of more than six hours,¹⁷ nor a lymph node dissection,^{2,12} could be identified as risk factors predicting bleeding after pancreatic resection.

Diagnostics and Site of Bleeding

The diagnostic procedures employed after the development of delayed PPH were endoscopy, angiography, and computed tomography (CT). The frequency and the sensitivity of the CT were not systematically reported in the included studies. When reported,^{2,11–13,15,16,18–23} a diagnostic angiography was performed in 55% of the patients with delayed PPH (113/206). The main reason for not performing a diagnostic angiography was hemodynamic instability. The bleeding source could be localized in 88% (99/113) of cases. An endoscopic approach, when precisely numbered,^{15,21,23} was used in ten out of 52 patients. The use of endoscopy was restricted to gastrointestinal bleeding. When documented,^{11–14,16,18,21–23} the anatomical site of bleeding (Table 2) determined either after angiography, endoscopy, or relaparotomy, was as follows: eroded or ruptured visceral arteries in 66% (101/154), the pancreatic stump in 12% (18/154), and the entero-jejuno-stomy in 6% (9/154) of cases. The exact bleeding location could not be determined in sixteen out of 154 cases (10%). Among visceral arteries, the most frequent source was the gastroduodenal artery, representing 50% (50/101) of all arterial hemorrhage. The common hepatic artery was implicated in 21% (21/101) and the proper hepatic artery and its branches in 11% (11/101).

Treatment and Outcome (including mortality)

The first-line treatment of delayed PPH was either interventional radiology (coil embolization or covered stenting) or laparotomy. Among the 215 patients with reported first-line treatment,^{2,11–16,18–23} interventional radiology was attempted in 39% (83/215) of cases, and the laparotomy approach was chosen in 53% (114/215) of cases. The 18 remaining patients were either treated conservatively or endoscopically. There was one study including 11 patients for whom no radiological treatment was performed.¹⁴ Hemodynamic instability, which was quantified in four studies, occurred in 34 out of 51 patients.^{2,14,18,20} This was the main criterion for surgical approach in these studies. When a radiological approach was taken, arterial coil embolization was most commonly used (95%). The implementation of a covered stent in case of bleeding from the hepatic or the superior mesenteric artery was described in four patients.^{11,18,21} Regarding the surgical approach, a completion pancreatectomy was undertaken in 41% (20/49) as documented in seven studies.^{2,14,18,20–23} Half of these completion pancreatectomies ($n=10$) were described in a single study.² Other interventions including hemostasis and arterial ligation were undertaken in 59% (29/49) of cases.

The documented outcomes after the first-line treatment^{2,11–13,21–23} are shown in Figs. 2 and 3. The intervention was considered as successful when complete hemostasis was achieved at the end of the procedure. The success rate of laparotomy was 76% (34/45) and 80% (48/60) in interventional radiology. On statistical analysis, there was a tendency favoring laparotomy in term of success rate (Fig. 2), without reaching statistical significance ($P=0.35$). The mortality rate of the patients having

Table 2 Bleeding source of delayed postpancreatectomy hemorrhage

	Visceral arteries (<i>n</i>)						PS (<i>n</i>)	EJ (<i>n</i>)	Other (<i>n</i>)	Unknown (<i>n</i>)	
	GDA	CHA	PHA	SA	SMA	Other					Total
Blanc et al. ¹⁸	4	0	0	3	0	0	7	6	1	1	1
Choi et al. ¹²	5	3	2	1	3	0	14	2	1	0	5
Liu et al. ¹³	14	0	0	0	0	0	14	1	0	0	0
Makowiec et al. ²¹	6	5	0	1	0	0	12	0	0	0	0
Miura et al. ²²	5	0	2	0	4	0	11	0	0	0	0
Sato et al. ²³	2	3	3	1	1	0	10	0	0	0	0
Tien et al. ²	1	5	4	0	0	0	10	0	0	0	0
Treckmann et al. ¹⁴	1	2	0	2	0	1	6	0	2	1	2
Wei et al. ¹¹	8	0	0	0	0	0	8	7	3	7	6
Yoon et al. ¹⁶	4	3	0	0	0	2	9	2	2	1	2
Total							101	18	9	10	16
Relative amount							66%	12%	6%	6%	10%

PPH postpancreatectomy hemorrhage, GDA gastroduodenal artery, CHA common hepatic artery, PHA proper hepatic artery, SA splenic artery, SMA superior mesenteric artery, PS pancreatic stump, EJ enterostomy

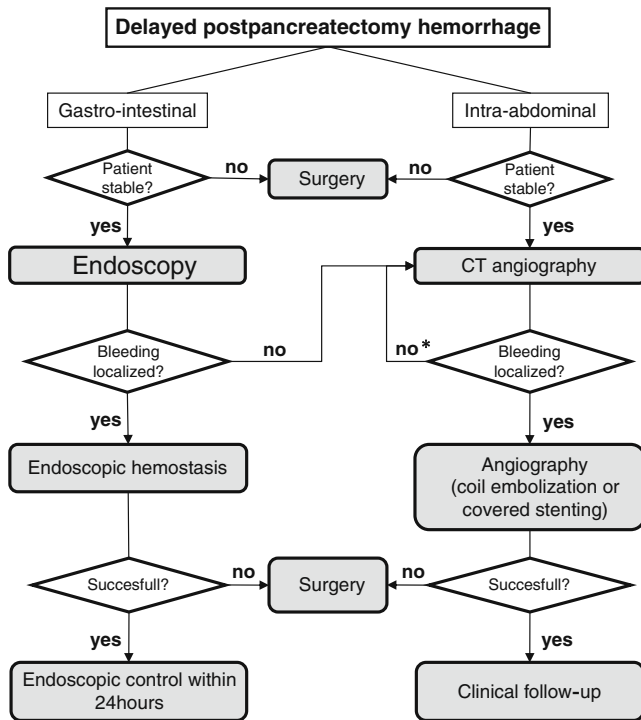


Fig. 2 Forest plots of success rate (i.e., complete hemostasis) for laparotomy vs. interventional radiology after delayed postpancreatectomy hemorrhage. *Squares* indicate the point estimate of the treatment effect (odds ratio), with 95% confidence intervals [CI] indicated by *horizontal bars*. The *diamond* represents the summary estimate from the pooled studies with 95% CI

initially undergone a laparotomy or a radiological intervention was 47%, and 22%, respectively. On meta-analysis, there was a statistically significant difference ($P=0.02$) in favor of interventional radiology in term of mortality after PPH (Fig. 3).

The overall mortality rate of delayed PPH was 35% (87/248). Reported causes of death were hemorrhagic shock, septic shock, disseminated intravascular coagulation, and multiple organ failure.

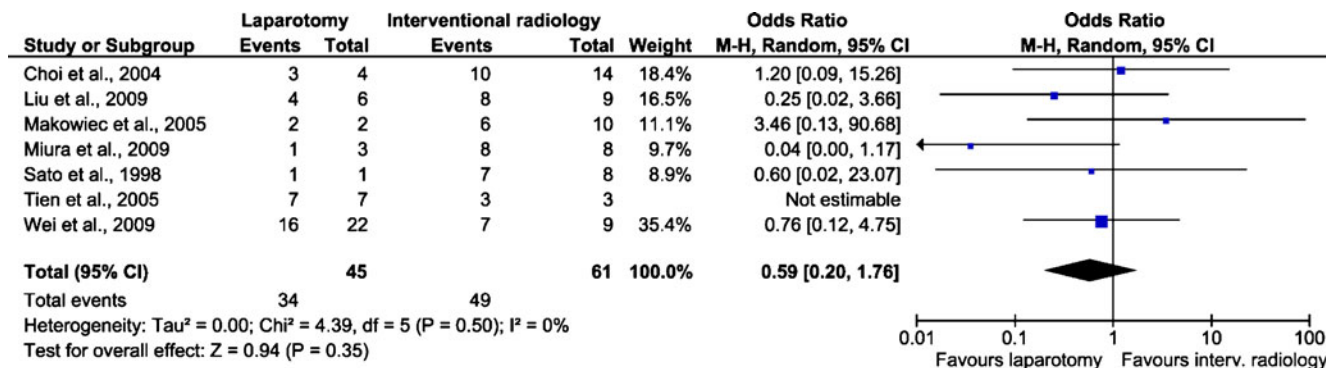


Fig. 3 Forest plots of mortality for laparotomy vs. interventional radiology after delayed postpancreatectomy hemorrhage. *Squares* indicate the point estimate of the treatment effect (odds ratio), with

Discussion

Delayed PPH is a rare complication which occurred in 3.3% of the included patients, but it is associated with a high mortality rate as high as 35% in our review. Therefore, its timely identification and prompt management as proposed by the diagnostic and therapeutic algorithm (Fig. 4) is of critical importance to achieve a good outcome. The ideal cut-off for the definition of early versus late bleeding remains controversial and somewhat arbitrary. While the majority of the included studies used the fifth or the seventh postoperative day for the definition of late bleeding, the recent consensus statement of the ISGPS proposed a cut-off of 24 h.⁹ This variability of definition induced a lack of homogeneity in the publications included in our review. The median onset of delayed PPH was reported to be within a range of 13 to 27 days postoperatively. Therefore, there remains a major risk of delayed PPH even after patient's discharge.

Different mechanisms inducing major bleeding from visceral arteries and veins are discussed. First, extensive skeletonization of the celiac axis and the superior mesenteric artery during lymphadenectomy or resection of the pancreas may injure the vessel wall. This may be due to thermal injuries by using electrocautery or to damages to the vascular outer layer during dissection.^{24,25} Secondly, postoperative leak of the pancreaticojejunostomy or hepaticojejunostomy may induce digestion of vascular structures by the erosive pancreatic or biliary juice, respectively.^{2,6,11,12,17} In addition, subsequent abscess formation can also erode the vessel wall or a vascular anastomosis, e.g., after portal vein resection. In some few cases, local tissue destruction may disrupt ligatures and sutures, typically at the stump of the gastroduodenal artery. Finally, local vessel wall necrosis could be induced by mechanical pressure of a drain lying on a vessel or an ascending infection along the drain.²⁶ Typically, the

95% confidence intervals [CI] indicated by *horizontal bars*. The *diamond* represents the summary estimate from the pooled studies with 95% CI

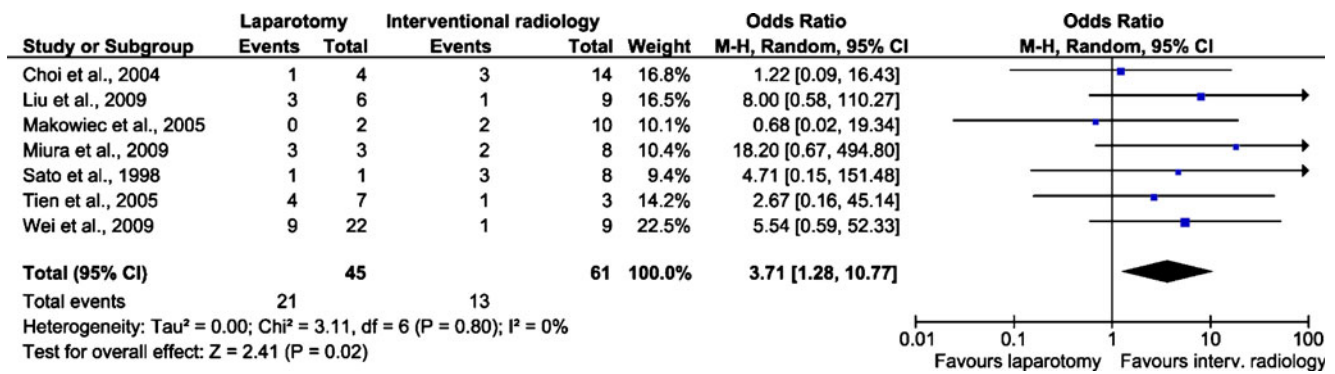


Fig. 4 Diagnostic and therapeutic algorithm for delayed postpancreatectomy hemorrhage. *Asterisk*, repeat CT angiography in case of persistent suspected bleeding

stepwise and rather slow destruction of the vessel wall causes a pseudoaneurysm of a major visceral artery. The presence of a local abscess, mainly resulting from an anastomotic leakage (either pancreatic or biliary), was the most common risk factor, and was identified in 62% of all delayed PPH in our review. We also found that the majority (66%) of all delayed PPH were coming from an eroded or ruptured visceral artery. Since pancreatic leak and intraabdominal sepsis have been demonstrated to be independent risk factors of subsequent massive bleeding,^{2,11,12,17} their prompt recognition and management represents the mainstay of delayed PPH prevention. In case of conservatively treated pancreatic fistula, some authors advocated a strict surveillance including a weekly CT angiography to detect the development of a pseudonaneurysm.^{12,14,27}

The term “sentinel bleed” was first introduced by Brodsky et al. in 1991²⁸ to describe intermittent minor bleeding (either intraabdominal or intraluminal) that sometimes precede delayed PPH. In our review, this preliminary event was identified in almost half of the patients before massive bleeding occurred. Yekebas et al.¹⁵ showed that the coincidence of pancreatic fistula and a sentinel bleed, preceding delayed PPH, is associated with a mortality of 57%. If there was no sentinel bleed before PPH, the mortality was lowered down to 38%. On the contrary, Treckmann et al.¹⁴ could not detect any mortality difference between patients with or without a preceding sentinel bleed. However, as delayed PPH is a highly lethal event, some authors suggested that any sentinel bleed after pancreatic surgery should lead to an emergency angiography.^{11,14,15,23,29} Alternatively, the use of CT angiography, as proposed by Blanc et al.,¹⁸ is less invasive and also identifies pseudoaneurysm and associated complications.

Angiography was able to localize the bleeding source in almost 90% of cases. The false-negative angiographies could be due to the intermittent character of bleeding episodes.⁵ If the bleeding source could not be identified,

Yekebas et al.¹⁵ suggested proceeding to a novel angiography after 6–24 h as long as the patient remains hemodynamically stable. “Blind” coiling of the gastroduodenal artery could also provide bleeding control after a negative angiography. The success rate of angiographic hemostasis was 80% in our review, which was close to the 76% of successful hemostasis obtained after relaparotomy. There was no statistically significant difference between both treatments regarding their respective success rate. In contrast, the mortality rate of the patients having initially undergone a relaparotomy was 47% versus 22% for those with primary radiological intervention. This difference reached statistical significance, favoring interventional radiology in term of mortality. However, this difference of outcome may reflect a selection bias as stabilized patients can be transferred to angiography, but those who are hemodynamically unstable require a crush laparotomy. The mortality rate after a delayed PPH is higher than the failure rate of hemostasis, emphasizing the fact that even after a successful hemostasis the underlying complications such as pancreatic leak and intraabdominal abscess have to be considered and treated. For that reason, some authors still prefer surgery as first-line therapy.^{6,30} On the other hand, patients with pancreatic leaks can be treated conservatively if no local or systemic inflammatory response occurs.³¹ Intraabdominal abscess can be treated by a CT-guided percutaneous drainage,^{32,33} to prevent recurrent bleeding.

Different surgical techniques have been reported to prevent pseudoaneurysm formation. Turrini et al.³⁴ suggested performing the pancreaticojejunostomy far on the left side, away from the celiac trunk and portal vein to avoid direct contact of pancreatic juice with adjacent vessels in case of pancreatic leak. Kurosaki et al.³⁵ proposed to wrap an omental flap around the pancreaticojejunostomy to minimize anastomotic leakage. Koukoutsis et al.²⁰ described the spreading of the round ligament around the common hepatic artery after pancreaticoduodenectomy. The real benefits of all these technical modifica-

tions are poorly supported by clinical data, and remain on the level of personal opinion and experience.

The traditional treatment of delayed PPH has so far been surgery. However, surgical access to the bleeding vessel is always difficult because of the overlying pancreaticoenteric and bilioenteric anastomosis as well as the presence of postsurgical adhesions. The eroded bleeding vessel is also difficult to repair due to peripancreatic inflammation and vessel wall friability.^{17,26} With recent advances in interventional radiology, radiological hemostasis (e.g., coiling or stenting) was described as the preferred option in hemodynamically stabilized patients.^{2,12,16,23,36–38} Bleeding arising from the gastroduodenal artery is the most frequently encountered in delayed PPH, representing half of all delayed arterial bleeding in our review. Bleeding coming from this artery may be difficult to control surgically, as reported by Balachandran et al.,¹⁷ where all three patients re-bled following surgical ligation of the gastroduodenal stump. In contrast, the gastroduodenal artery can easily be embolized. The second most common site of arterial bleeding is the common and the proper hepatic artery, which accounted for almost a third of all delayed visceral arteries hemorrhage included in the present review. Complete occlusion of these arteries by angiographic embolization can lead to intra-hepatic abscess as a result of liver necrosis, biliary ischemia, as well as fatal hepatic failure.^{16,23,30,39} To avoid these severe complications, the use of covered stent was described for the treatment of bleeding of hepatic arteries.^{11,40–42} However, anatomical reasons, such as kinking, and anatomical variations may impede successful stent placement.²¹ Bleeding from the superior mesenteric artery (SMA), which occurred in 7.9% in our review, also inherits the potential risk of intestinal infarction subsequently to coil embolization. In 1998, Mc Graw et al.⁴³ first reported the successful use of covered stents for the management of a SMA pseudoaneurysm occurring after pancreaticoduodenectomy. Thus, if technically feasible, covered stents may represent the best treatment option in order to preserve a superior mesenteric and hepatic arterial flow.

Conclusion

Delayed postoperative bleeding after a pancreatic resection is a rare but highly lethal complication. The prompt recognition and treatment of risk factors such as pancreatic leakage and intraabdominal abscess is essential to prevent its deleterious outcome. Sentinel bleeding occurring after a pancreatic surgery needs to be thoroughly investigated for a pseudoaneurysm formation, and if detected, interventional angiography provides optimal management by avoiding collateral damage after major revisional surgery. Early

angiography with embolization or stenting should be the procedure of choice in case of delayed bleeding, whenever possible. Surgery remains a therapeutic option if no interventional radiology is available, or patients cannot be resuscitated for an interventional treatment.

References

- Trede M, Schwall G. The complications of pancreatectomy. *Ann Surg* 1988;207:39–47.
- Tien YW, Lee PH, Yang CY, Ho MC, Chiu YF. Risk factors of massive bleeding related to pancreatic leak after pancreaticoduodenectomy. *J Am Coll Surg* 2005;201:554–9.
- Miedema BW, Sarr MG, van Heerden JA, Nagorney DM, McIlrath DC, Ilstrup D. Complications following pancreaticoduodenectomy. Current management. *Arch Surg* 1992;127:945–9; discussion 949–50.
- Yeo CJ, Cameron JL, Sohn TA, Lillemoe KD, Pitt HA, Talamini MA, Hruban RH, Ord SE, Sauter PK, Coleman J, Zahurak ML, Grochow LB, Abrams RA. Six hundred fifty consecutive pancreaticoduodenectomies in the 1990s: Pathology, complications, and outcomes. *Annals of Surgery* 1997;226:248–260.
- van Berge Henegouwen MI, Allema JH, van Gulik TM, Verbeek PC, Obertop H, Gouma DJ. Delayed massive haemorrhage after pancreatic and biliary surgery. *Br J Surg* 1995;82:1527–31.
- Rumstadt B, Schwab M, Korth P, Samman M, Trede M. Hemorrhage after pancreatoduodenectomy. *Ann Surg* 1998;227:236–41.
- Shankar S, Russell RC. Haemorrhage in pancreatic disease. *Br J Surg* 1989;76:863–6.
- Kleespies A, Albertsmeier M, Obeidat F, Seeliger H, Jauch KW, Bruns CJ. The challenge of pancreatic anastomosis. *Langenbeck's Archives of Surgery* 2008;393:459–471.
- Wente MN, Veit JA, Bassi C, Dervenis C, Fingerhut A, Gouma DJ, Izbicki JR, Neoptolemos JP, Padbury RT, Sarr MG, Yeo CJ, Buchler MW. Postpancreatectomy hemorrhage (PPH): an International Study Group of Pancreatic Surgery (ISGPS) definition. *Surgery* 2007;142:20–5.
- Buchler MW, Friess H, Wagner M, Kulli C, Wagener V, Z'Graggen K. Pancreatic fistula after pancreatic head resection. *Br J Surg* 2000;87:883–9.
- Wei HK, Wang SE, Shyr YM, Tseng HS, Tsai WC, Chen TH, Su CH, Wu CW, Lui WY. Risk factors for post-pancreaticoduodenectomy bleeding and finding an innovative approach to treatment. *Dig Surg* 2009;26:297–305.
- Choi SH, Moon HJ, Heo JS, Joh JW, Kim YI. Delayed hemorrhage after pancreaticoduodenectomy. *J Am Coll Surg* 2004;199:186–91.
- Liu C, Qiu YH, Luo XJ, Yi B, Jiang XQ, Tan WF, Yu Y, Wu MC. Treatment of massive pancreaticojejunal anastomotic hemorrhage after pancreatoduodenectomy. *World J Gastroenterol* 2009;15:1625–9.
- Treckmann J, Paul A, Sotiropoulos GC, Lang H, Ozcelik A, Saner F, Broelsch CE. Sentinel bleeding after pancreaticoduodenectomy: a disregarded sign. *J Gastrointest Surg* 2008;12:313–8.
- Yekebas EF, Wolfram L, Cataldegirmen G, Habermann CR, Bogoevski D, Koenig AM, Kaifi J, Schurr PG, Bubenheim M, Nolte-Ernsting C, Adam G, Izbicki JR. Postpancreatectomy hemorrhage: diagnosis and treatment: an analysis in 1669 consecutive pancreatic resections. *Ann Surg* 2007;246:269–80.
- Yoon YS, Kim SW, Her KH, Park YC, Ahn YJ, Jang JY, Park SJ, Suh KS, Han JK, Lee KU, Park YH. Management of postoperative hemorrhage after pancreatoduodenectomy. *Hepatogastroenterology* 2003;50:2208–12.

17. Balachandran P, Sikora SS, Raghavendra Rao RV, Kumar A, Saxena R, Kapoor VK. Haemorrhagic complications of pancreaticoduodenectomy. *ANZ J Surg* 2004;74:945–50.
18. Blanc T, Cortes A, Goere D, Sibert A, Pessaux P, Belghiti J, Sauvanet A. Hemorrhage after pancreaticoduodenectomy: when is surgery still indicated? *Am J Surg* 2007;194:3–9.
19. Boggi U, Del Chiaro M, Croce C, Amorese G, Signori S, Vistoli F, Di Candio G, Campatelli A, Morelli L, D'Imporzano S, Sgambelluri FA, Mosca I, Mosca F. Vascular complications of pancreatectomy. *JOP* 2007;8:102–13.
20. Koukoutsis I, Bellagamba R, Morris-Stiff G, Wickremesekera S, Coldham C, Wigmore SJ, Mayer AD, Mirza DF, Buckels JA, Bramhall SR. Haemorrhage following pancreaticoduodenectomy: risk factors and the importance of sentinel bleed. *Dig Surg* 2006;23:224–8.
21. Makowiec F, Riediger H, Euringer W, Uhl M, Hopt UT, Adam U. Management of delayed visceral arterial bleeding after pancreatic head resection. *J Gastrointest Surg* 2005;9:1293–9.
22. Miura F, Asano T, Amano H, Yoshida M, Toyota N, Wada K, Kato K, Yamazaki E, Kadowaki S, Shibuya M, Maeno S, Furui S, Takeshita K, Kotake Y, Takada T. Management of postoperative arterial hemorrhage after pancreato-biliary surgery according to the site of bleeding: re-laparotomy or interventional radiology. *J Hepatobiliary Pancreat Surg* 2009;16:56–63.
23. Sato N, Yamaguchi K, Shimizu S, Morisaki T, Yokohata K, Chijiwa K, Tanaka M. Coil embolization of bleeding visceral pseudoaneurysms following pancreatectomy: the importance of early angiography. *Arch Surg* 1998;133:1099–102.
24. Reber PU, Baer HU, Patel AG, Wildi S, Triller J, Buchler MW. Superselective microcoil embolization: treatment of choice in high-risk patients with extrahepatic pseudoaneurysms of the hepatic arteries. *J Am Coll Surg* 1998;186:325–30.
25. Sugimoto H, Kaneko T, Ishiguchi T, Takai K, Ohta T, Yagi Y, Inoue S, Takeda S, Nakao A. Delayed rupture of a pseudoaneurysm following pancreatoduodenectomy: Report of a case. *Surgery Today* 2001;31:932–935.
26. Otah E, Cushin BJ, Rozenblit GN, Neff R, Otah KE, Cooperman AM. Visceral artery pseudoaneurysms following pancreatoduodenectomy. *Arch Surg* 2002;137:55–9.
27. Santoro R, Carlini M, Carboni F, Nicolas C, Santoro E. Delayed massive arterial hemorrhage after pancreaticoduodenectomy for cancer. Management of a life-threatening complication. *Hepatogastroenterology* 2003;50:2199–204.
28. Brodsky JT, Turnbull AD. Arterial hemorrhage after pancreatoduodenectomy. The 'sentinel bleed'. *Arch Surg* 1991;126:1037–40.
29. Tien YW, Wu YM, Liu KL, Ho CM, Lee PH. Angiography is indicated for every sentinel bleed after pancreaticoduodenectomy. *Ann Surg Oncol* 2008;15:185561.
30. de Castro SM, Kuhlmann KF, Busch OR, van Delden OM, Lameris JS, van Gulik TM, Obertop H, Gouma DJ. Delayed massive hemorrhage after pancreatic and biliary surgery: embolization or surgery? *Ann Surg* 2005;241:85–91.
31. de Castro SM, Busch OR, Gouma DJ. Management of bleeding and leakage after pancreatic surgery. *Best Pract Res Clin Gastroenterol* 2004;18:847–64.
32. Gervais DA, Fernandez-del Castillo C, O'Neill MJ, Hahn PF, Mueller PR. Complications after pancreatoduodenectomy: imaging and imaging-guided interventional procedures. *Radiographics* 2001;21:673–90.
33. vanSonnenberg E, Wittich GR, Goodacre BW, Casola G, D'Agostino HB. Percutaneous abscess drainage: update. *World J Surg* 2001;25:362–9; discussion 370–2.
34. Turrini O, Moutardier V, Guiramand J, Lelong B, Bories E, Sannini A, Magnin V, Viret F, Blache JL, Giovannini M, Delpero JR. Hemorrhage after duodenopancreatectomy: impact of neoadjuvant radiochemotherapy and experience with sentinel bleeding. *World J Surg* 2005;29:212–6.
35. Kurosaki I, Hatakeyama K. Omental wrapping of skeletonized major vessels after pancreaticoduodenectomy. *Int Surg* 2004;89:90–4.
36. Balladur P, Christophe M, Tiret E, Parc R. Bleeding of the pancreatic stump following pancreatoduodenectomy for cancer. *Hepatogastroenterology* 1996;43:268–70.
37. Cullen JJ, Sarr MG, Ilstrup DM. Pancreatic anastomotic leak after pancreaticoduodenectomy: incidence, significance, and management. *Am J Surg* 1994;168:295–8.
38. Reber PU, Baer HU, Patel AG, Triller J, Buchler MW. Life-threatening upper gastrointestinal tract bleeding caused by ruptured extrahepatic pseudoaneurysm after pancreatoduodenectomy. *Surgery* 1998;124:114–5.
39. Noun R, Zeidan S, Tohme-Noun C, Smayra T, Sayegh R. Biliary ischemia following embolization of a pseudoaneurysm after pancreaticoduodenectomy. *Journal of the Pancreas* 2006;7:427–431.
40. Burger T, Halloul Z, Meyer F, Grote R, Lippert H. Emergency stent-graft repair of a ruptured hepatic artery secondary to local postoperative peritonitis. *J Endovasc Ther* 2000;7:324–7.
41. Heiss P, Bachthaler M, Hamer OW, Piso P, Herold T, Schlitt HJ, Feuerbach S, Zorger N. Delayed visceral arterial hemorrhage following Whipple's procedure: minimally invasive treatment with covered stents. *Ann Surg Oncol* 2008;15:824–32.
42. Stoupis C, Ludwig K, Inderbitzin D, Do DD, Triller J. Stent grafting of acute hepatic artery bleeding following pancreatic head resection. *Eur Radiol* 2007;17:401–8.
43. McGraw JK, Patzik SB, Gale SS, Dodd JT, Boorstein JM. Autogenous vein-covered stent for the endovascular management of a superior mesenteric artery pseudoaneurysm. *J Vasc Interv Radiol* 1998;9:779–82.