



**UNIL** | Université de Lausanne

Unicentre

CH-1015 Lausanne

<http://serval.unil.ch>

---

*Year : 2013*

## Quantification de la perfusion rénale par échographie de contraste, une étude pilote

Schneider Antoine

Schneider Antoine, 2013, Quantification de la perfusion rénale par échographie de contraste, une étude pilote

Originally published at : Thesis, University of Lausanne

Posted at the University of Lausanne Open Archive.  
<http://serval.unil.ch>

### **Droits d'auteur**

L'Université de Lausanne attire expressément l'attention des utilisateurs sur le fait que tous les documents publiés dans l'Archive SERVAL sont protégés par le droit d'auteur, conformément à la loi fédérale sur le droit d'auteur et les droits voisins (LDA). A ce titre, il est indispensable d'obtenir le consentement préalable de l'auteur et/ou de l'éditeur avant toute utilisation d'une oeuvre ou d'une partie d'une oeuvre ne relevant pas d'une utilisation à des fins personnelles au sens de la LDA (art. 19, al. 1 lettre a). A défaut, tout contrevenant s'expose aux sanctions prévues par cette loi. Nous déclinons toute responsabilité en la matière.

### **Copyright**

The University of Lausanne expressly draws the attention of users to the fact that all documents published in the SERVAL Archive are protected by copyright in accordance with federal law on copyright and similar rights (LDA). Accordingly it is indispensable to obtain prior consent from the author and/or publisher before any use of a work or part of a work for purposes other than personal use within the meaning of LDA (art. 19, para. 1 letter a). Failure to do so will expose offenders to the sanctions laid down by this law. We accept no liability in this respect.

---

**UNIVERSITE DE LAUSANNE- FACULTE DE BIOLOGIE ET DE MEDECINE**

Département de Médecine Interne  
Service de Néphrologie et d'hypertension

---

**Quantification de la perfusion rénale par échographie de contraste,  
une étude pilote**

THESE

préparée sous la direction du Professeur Michel Burnier  
(avec la collaboration du Docteur Bruno Vogt)  
et présentée à la faculté de biologie et de médecine de  
l'Université de Lausanne pour l'obtention du grade de

DOCTEUR EN MEDECINE

par

Antoine SCHNEIDER  
Médecin diplômé de la Confédération Suisse  
Originaire de Genève

Lausanne

2013

# *Imprimatur*

*Vu le rapport présenté par le jury d'examen, composé de*

*Directeur de thèse Monsieur le Professeur Michel Burnier*

*Co-Directeur de thèse*

*Expert Monsieur le Professeur Jean-Yves Meuwly*

*Directrice de l'Ecole  
doctorale Madame le Professeur Stephanie Clarke*

*la Commission MD de l'Ecole doctorale autorise l'impression de la thèse de*

***Monsieur Antoine SCHNEIDER***

*intitulée*

***Quantification de la perfusion rénale par échographie de  
contraste, une étude pilote***

*Lausanne, le 10 septembre 2013*

*pour Le Doyen  
de la Faculté de Biologie et de Médecine*



*Madame le Professeur Stephanie Clarke  
Directrice de l'Ecole doctorale*

## Renal perfusion evaluation with contrast-enhanced ultrasonography

Antoine G. Schneider<sup>1,2</sup>, Lucie Hofmann<sup>1</sup>, Grégoire Wuerzner<sup>1</sup>, Nicolas Glatz<sup>1</sup>, Marc Maillard<sup>1</sup>, Jean-Yves Meuwly<sup>3</sup>, Philippe Eggimann<sup>2</sup>, Michel Burnier<sup>1</sup> and Bruno Vogt<sup>1</sup>

<sup>1</sup>Department of Internal Medicine, Division of Nephrology and Hypertension, Centre Hospitalier Universitaire Vaudois (CHUV) and University of Lausanne, Lausanne, Switzerland, <sup>2</sup>Adult Intensive Care Unit, Centre Hospitalier Universitaire Vaudois (CHUV) and University of Lausanne, Lausanne, Switzerland and <sup>3</sup>Department of Radiology, Centre Hospitalier Universitaire Vaudois (CHUV) and University of Lausanne, Lausanne, Switzerland

Correspondence and offprint requests to: Bruno Vogt; E-mail: bruno.vogt@chuv.ch

### Abstract

**Background.** Contrast-enhanced ultrasonography (CEUS) is a novel imaging technique that is safe and applicable on the bedside. Recent developments seem to enable CEUS to quantify organ perfusion. We performed an exploratory study to determine the ability of CEUS to detect changes in renal perfusion and to correlate them with effective renal plasma flow.

**Methods.** CEUS with destruction-refilling sequences was studied in 10 healthy subjects, at baseline and during infusion of angiotensin II (AngII) at low (1 ng/kg/min) and high dose (3 ng/kg/min) and 1 h after oral captopril (50 mg). Perfusion index (PI) was obtained and compared with the effective renal plasma flow (ERPF) obtained by parallel para-aminohippurate (PAH) clearance.

**Results.** Median PI decreased from 188.6 (baseline) to 100.4 with low-dose AngII (−47%;  $P < 0.02$ ) and to 66.1 with high-dose AngII (−65%;  $P < 0.01$ ) but increased to 254.7 with captopril (+35%;  $P > 0.2$ ). These changes paralleled those observed with ERPF, which changed from a median of 672.1 mL/min (baseline) to 572.3 (low-dose AngII, −15%,  $P < 0.05$ ) and to 427.2 (high-dose AngII, −36%,  $P < 0.001$ ) and finally 697.1 (captopril, +4%,  $P < 0.02$ ).

**Conclusions.** This study demonstrates that CEUS is able to detect changes in human renal cortical microcirculation as induced by AngII infusion and/or captopril administration. The changes in perfusion indices parallel those in ERPF as obtained by PAH clearance.

**Keywords:** angiotensin II; contrast-enhanced ultrasound; effective renal plasma flow; microcirculation; renal haemodynamic

### Introduction

#### Background

The methods currently available to assess and monitor renal perfusion are either very inaccurate or not applicable in human and particularly in critically ill patients. The

physiological gold standard to estimate the renal plasma flow is the calculation of PAH clearance which has long been recognized as inaccurate in oliguria and acute kidney injury [1, 2]. Doppler studies have been demonstrated to be unreliable [3]. The use of scintigraphy or magnetic resonance imaging (MRI) is limited by equipment availability, costs and their requirement for extensive and prolonged patient manipulation. These methods anyway only give information about the global organ perfusion (macrocirculation) and not about the microcirculation whose importance is being increasingly recognized in the literature [4–6]. A method enabling the evaluation of renal microcirculation, which would be applicable in every day clinic routine and especially in the intensive care unit, would greatly improve the understanding of the pathophysiology of acute kidney injury.

Contrast-enhanced ultrasonography (CEUS) is a novel imaging technique associating low mechanical index (MI) ultrasonography and microbubble-based contrast agents [7]. CEUS has found numerous applications in particular for the characterization of focal liver lesions and in the assessment of myocardial perfusion. Recently developed techniques have been proposed to quantify blood flow within an organ with CEUS [8]. They make use of the purely intravascular distribution of the microbubbles and their sensitivity to high-power acoustic pulses to obtain so-called destruction-refilling sequences, from which some parameters proportional to blood flow can be derived. Initially validated for the myocardium [8, 9], these techniques are being applied to other organs such as the kidney [10, 11]. The validation of CEUS as a diagnostic tool in monitoring renal perfusion is still under development but several studies have shown promising results [12, 13].

To confirm the ability of CEUS to detect changes in cortical microcirculation in humans, we decided to perform CEUS with destruction-refilling sequences in 10 healthy volunteers at baseline, during infusion of angiotensin II (AngII, an arterial vasoconstrictor) and after oral intake of captopril (an arterial vasodilator).

## Materials and methods

### Subjects

Twelve healthy normotensive male subjects without any history of cardiovascular, renal or endocrine disease were recruited. A full medical history, a complete physical examination, ECG and blood tests for routine chemistry and haematology as well as a standard renal echography to ensure adequate visualization of both kidneys were performed before inclusion.

The study protocol was approved by the local hospital ethical committee and written informed consent was obtained from each subject.

### Study design

The general scheme of the experiment is depicted in Figure 1. CEUS and para-aminohippurate (PAH) clearance study, as the gold standard for estimating effective renal plasma flow (ERPF), were performed in parallel.

In order to maintain a high urinary output (hourly micturition required), the subjects were asked to drink 5 mL/kg of mineral water on arrival and 150 mL every hour. A peripheral venous catheter was inserted in each arm for infusion of the contrast agent and the study drugs. A baseline CEUS with destruction-refilling sequences was performed. The infusion of AngII (Clinalfa®; Bachem AG, Offenburg, Germany) was then started at a rate of 1 ng/kg/min under close monitoring of the arterial blood pressure. The peak effect of AngII is achieved within minutes [14]. We allowed a 45-min equilibration period before performing the second CEUS study. The AngII infusion was then increased to 3 ng/kg/min. After 45 min of infusion at this rate, the third CEUS was performed. The AngII infusion was then stopped and 50 mg of captopril (Captopril Mepha®; Mepha Pharma AG, Aesch, Switzerland) were administered orally. Since, after oral administration, the peak plasma concentration of captopril is obtained in <1 h [15], we performed the last CEUS 1 h after the administration.

The subjects were monitored for an additional hour and then discharged.

Renal perfusion measurement with contrast-enhanced ultrasound CEUS of the kidney was performed with an Aplio XG® (Toshiba Medical, Tokyo, Japan) using a 3.5 MHz probe and a dedicated low MI (low acoustic power of the ultrasound) mode (MI = 0.1). Both kidneys were initially visualized and the most accessible chosen to perform the study. The contrast agent used was Sonovue® (Bracco SpA, Milan, Italy). It was injected as a continuous infusion with a dedicated syringe pump (VueJect®; Bracco SA, Milano, Italy) at a rate of 0.5 mL/min. Infusion was started 2 min before examination to reach a steady state. During this time, an optimal long axis view of the kidney was obtained by placing the transducer probe over the lower back with the subject in supine position. Image depth, focus, gain and frame rate were optimized at the beginning of each experiment and held constant during the study. At each time point,

three consecutive destruction-refilling sequences (with 15 s refilling time) were performed. Destruction was obtained by applying five pulses at high MI (flash) and refilling observed at low MI. DICOM clips were acquired and exported via DVD-R.

### Data analysis

In each series, we analysed the sequence associated with the less movements artefact and with the larger cortical visualization. These sequences were analysed blindly, using prototype software called SonoPerf® (Bracco Research SA, Geneva, Switzerland). After loading the DICOM sequences, three regions of interest (ROI) were drawn in the renal cortex (Figure 2). Very strict criteria were used to accept a ROI. The ROI had to be located within the outer cortex of the kidney and could only include microvasculature (which can be verified by the total absence of bubbles immediately after flash). After flash, the perfusion curve had to start from a level close to zero and display the expected replenishment shape not to be mistaken for noise. Lastly, a quality-of-fit index was observed to ensure appropriate signal quality. To minimize the effects of ultrasound attenuation and beam non-uniformity, the three ROI's were drawn at approximately the same depth.

The software then determined for each ROI the mean transit time (mTT), the regional blood volume (RBV) and calculated a perfusion index (PI;  $PI = RBV/mTT$ ) which is deemed to be proportional to blood flow [16]. These measurements were repeated for each sequence: at baseline, low-dose AngII, high-dose AngII and after captopril.

The two readers (A.S. and L.H.) selected independently the ROIs to be analysed in each sequence, using the same above-mentioned criteria. These data were analysed independently and used for confirmation purposes.

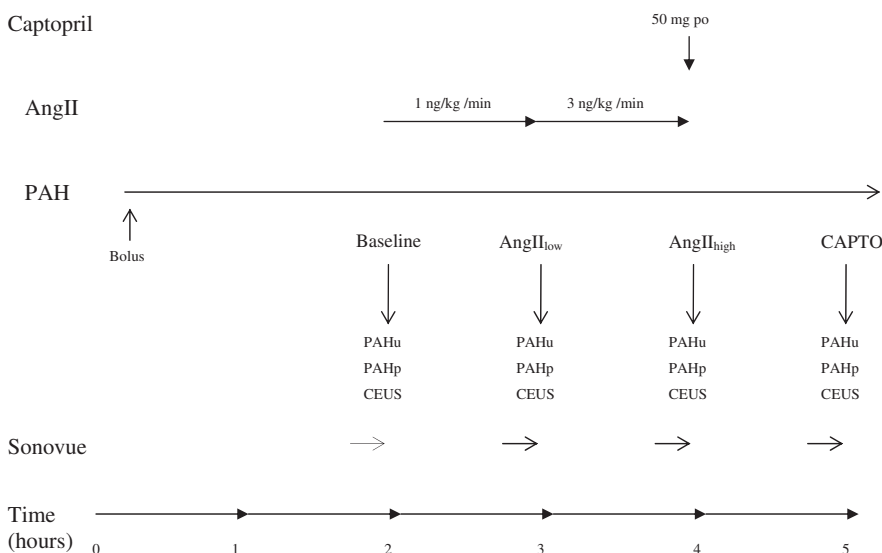
### PAH clearance

The infusion of PAH was primed with a bolus and started 2 h before the first CEUS to achieve a predetermined serum PAH concentration (calculated according to the subjects weight). Baseline blood and urine samples were obtained before starting AngII infusion. The next samples were obtained 1 h after adjusting the AngII infusion rate and 1 h after captopril to allow PAH serum levels to reach a new steady state.

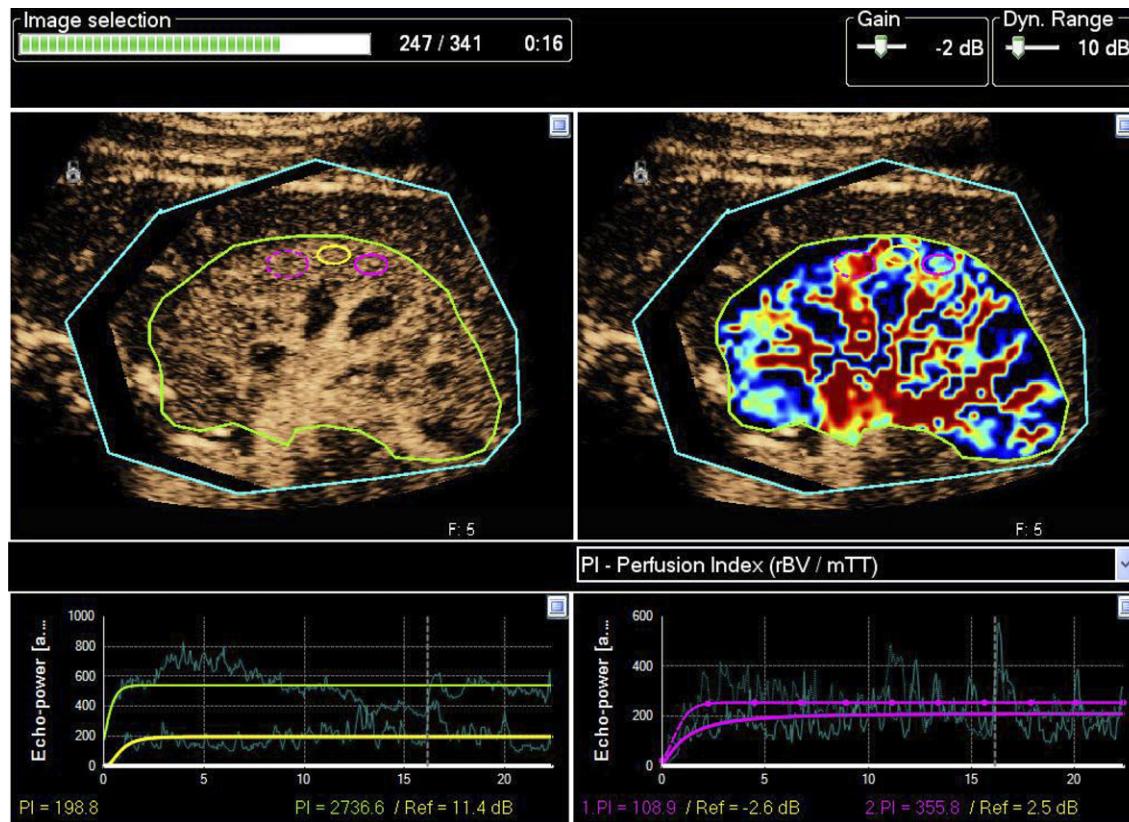
The samples were analysed blinded to sequence time by the research laboratory of the nephrology unit. ERPF was evaluated by calculation of renal PAH clearance using the classic formula ( $RPF \sim Cl_{PAH} = U_{PAH} \times V / P_{PAH}$ ) [17].

### Statistical analysis

From previous studies [18], the ERPF was expected to drop by 40% after AngII infusion and to increase by 20% after captopril intake. Based on these values, a statistical significance of 0.05 with a power of 0.8 was expected to be obtained with 10 subjects. We decided to recruit 12 to allow for some technical problems to occur.



**Fig. 1.** General plan of the study. AngII low, angiotensin II 1 ng/kg/min; AngII high, angiotensin II 3 ng/kg/min; PAHu, urinary PAH concentration; PAHp, plasmatic PAH concentration.



**Fig. 2.** Screenshot from Sonopert® illustrating localization of ROI and determining perfusion indices. Only PI is shown. Upper left corner: native DICOM sequence allowing placement of ROI (colour ovals). The green ROI around the whole kidney is used for reference and calculation only; its size and shape does not modify the numerical results. Upper right corner: parametric imaging mode improving ROI placement quality. Bottom right and left: replenishment curves; actual data (clear curve) and fitted curved (bold curve). Colours relate to the corresponding ROI.

As the condition of normally distributed data is not fulfilled the non-parametric Wilcoxon signed rank-sum test was used to compare to baseline the results obtained at the different time points. These comparison statistics were carried out with STATA/IC 10.0 for Windows (StataCorp, College Station, TX).

The data obtained by the two readers at each time point were compared using an analysis of variance test or the Kruskal–Wallis test depending on the homogeneity of variances (homoscedacity). These analyses were generated with the help of StatgraphicsPlus 5.1 (Manugistic SA, Rockville, MD).

Results are expressed as means for normally distributed data and as median and interquartile range (IQR) for non-normally distributed data. A P-value of <0.05 was considered to be significant.

## Results

### General

Of the 12 subjects enrolled, the full protocol could be performed for 10 of them. One subject was excluded because of an accidental change in the echography machine settings making the results non-comparable with the others and the other because no urine sample could be obtained on AngII infusion making urinary PAH measurement impossible. The mean age of the 10 subjects that completed the study was 23 (21 to 25) years, the mean body mass index was 24.4 (19.2–32) kg/m<sup>2</sup> and the mean serum creatinine level, 85 (75–104) µmol/L. Baseline serological values were all within normal.

AngII infusion, captopril ingestion and Sonovue® infusion were well tolerated and no adverse event was recorded. The mean arterial pressure (Figure 3) increased

with the high dose of AngII by 11 mmHg on average (maximum increase 18 mmHg) and returned to baseline once the infusion was stopped. It then remained unchanged after the administration of captopril.

Adequate visualization of the kidneys was obtained and CEUS easily performed in all subjects. The exact duration was not recorded but due to the study design, CEUS had to be performed within a 15 min time frame, which proved to be easily feasible in a setting where everything was already pre-installed.

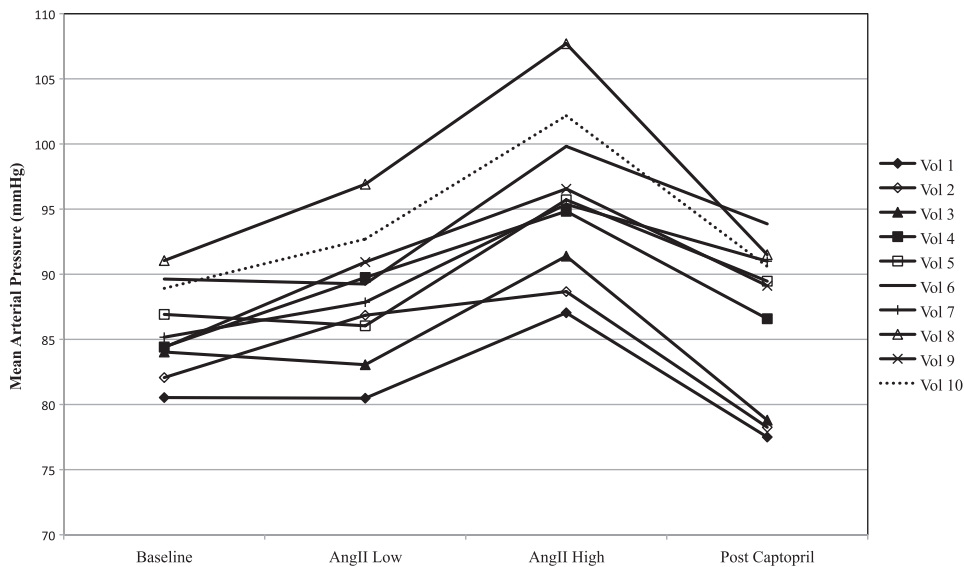
Three adequate ROI could be drawn in all but four sequences (90%) where only two were deemed acceptable.

### Perfusion indices

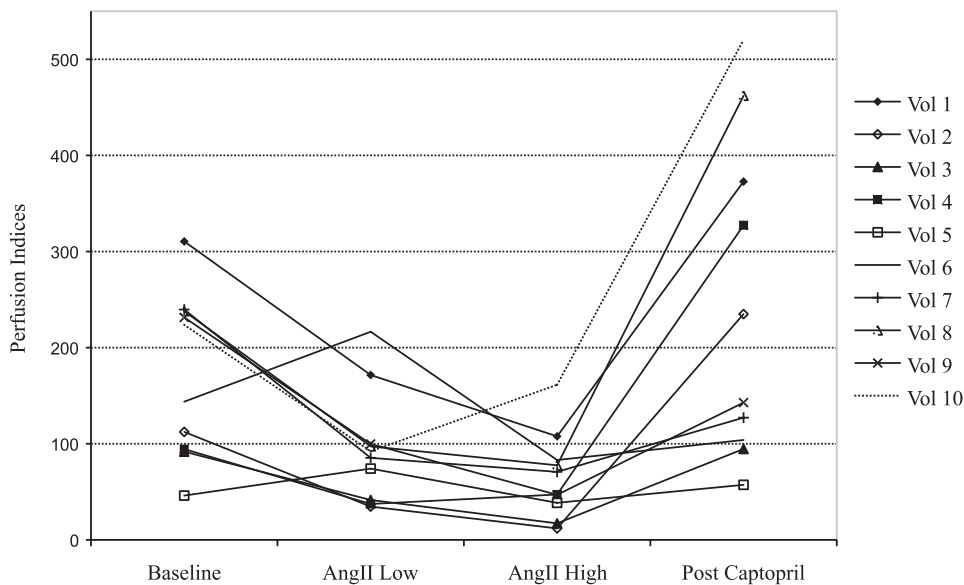
The median perfusion indices obtained by CEUS are shown in Figure 4. A statistically significant decrease in PI was observed on AngII infusion as compared to baseline from a median value of 188.6 (baseline, IQR 136.9) to 100.4 (IQR 88.7, –45%;  $P < 0.02$ ). They further decreased on AngII dose to 66.1 (IQR 83.8; –65%;  $P < 0.01$ ). After captopril administration, we observed a nonstatistically significant increase in PI to 254.7 (IQR 336.9; +35%;  $P > 0.2$ ).

### Interobserver variability

The readings performed by the main reader were compared to those of a second reader for confirmation purposes. A non-parametric test (Kruskal–Wallis) was used and



**Fig. 3.** Mean arterial pressure. AngII low, angiotensin II 1 ng/kg/min; AngII high, angiotensin II 3 ng/kg/min; Vol, volunteer.



**Fig. 4.** Perfusion indices. AngII Low: angiotensin II 1 ng/kg/min, AngII High: angiotensin II 3 ng/kg/min, Vol: volunteer. Scale has been adapted for Volunteer 3 and is  $\times 10$  the other.

showed no statistically significant differences between the three measurements at each time point since all P-values were  $>0.05$ .

*Effective renal plasma flow*

The results of the PAH clearance studies are depicted in Figure 5. Due to sampling issues, no data could be obtained for Volunteers 8 and 9 at the AngII low-dose experimental point.

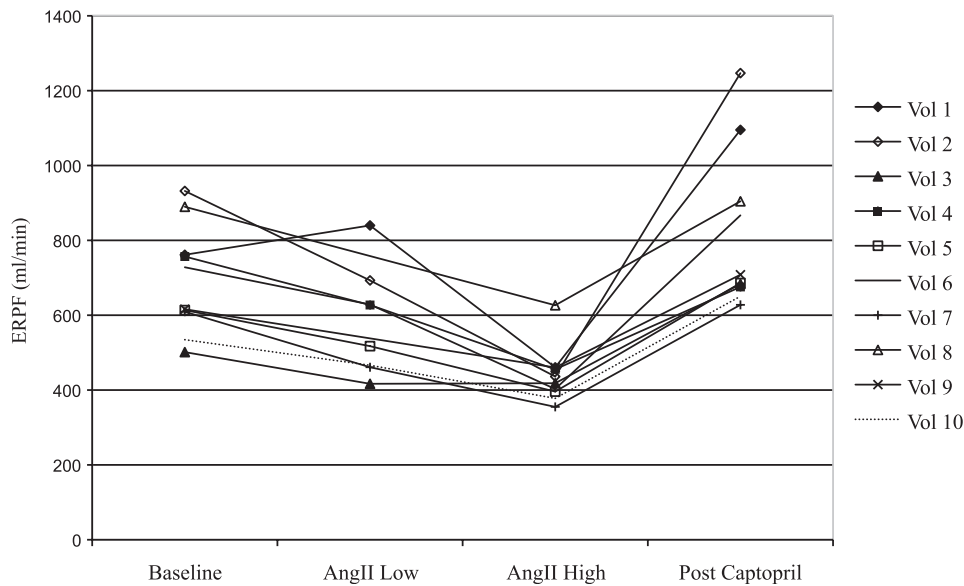
The median ERPF was 672.1 mL/min (IQR 147.7) on baseline. It decreased to 572.3 mL/min (IQR 162.4) on AngII low dose ( $-15\%$ ,  $P < 0.05$ ) and to 427.2 mL/min (IQR 58.5) during high-dose infusion ( $-36\%$  from base-

line,  $P < 0.001$ ) of AngII. It increased to 697.1 mL/min (IQR 206.1) after oral administration of captopril ( $+4\%$  from baseline;  $P < 0.02$ ).

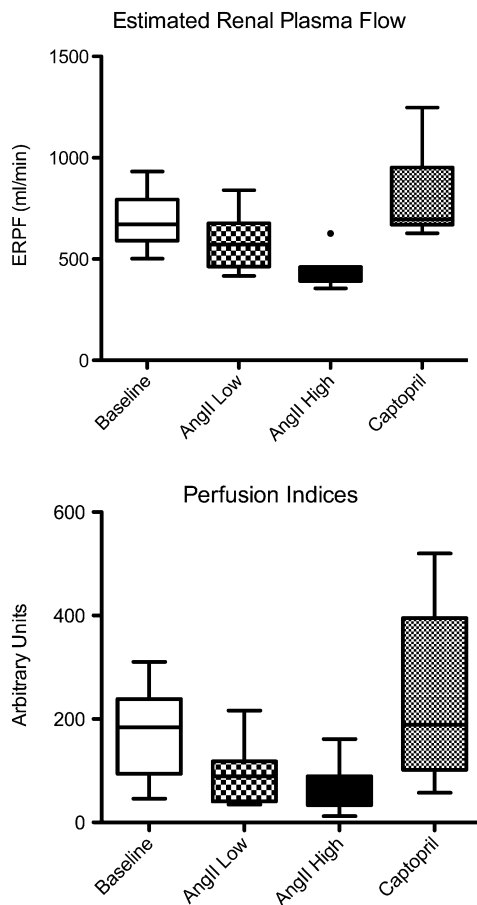
*Relationship between PI and ERPF*

As presented in Figure 6, the changes in PI paralleled those observed in ERPF as measured by PAH clearance.

ERPF and PI decreased during low-dose AngII infusion, by 15% (ERPF) and by 47% (PI) of their baseline values. During high-dose AngII infusion, they decreased even further by 36% (ERPF) and 65% (PI). Similarly, after oral captopril intake and compared to baseline, a minimal (4%)



**Fig. 5.** ERPF (estimated by PAH clearance). ERPF expressed in millilitres per minute, AngII Low: angiotensin II 1 ng/kg/min, AngII High: angiotensin II 3 ng/kg/min, Vol: volunteer.



**Fig. 6.** Comparison between perfusion indices and ERPF. ERPF expressed in millilitres per minute, AngII Low: angiotensin II 1 ng/kg/min, AngII High: angiotensin II 3 ng/kg/min. Data expressed as median value.

increase in ERPF was observed, while the PI increase (+35%) was not statistically significant. Detailed results are presented in Figure 7.

The Spearman test demonstrated a correlation between the two parameters ( $r = 0.57$ ,  $P = 0.002$ ).

## Discussion

In this study, we have shown, in 10 healthy volunteers, that CEUS with the SonoPerf<sup>®</sup> software is able to reliably detect changes in the renal microcirculation when associated to a 15% decrease in ERPF. Our results also showed that a further decrease in ERPF (−36% in total) was associated with a further decrease of the PI (−65% in total). On the other hand, a 4% increase in ERPF after captopril resulted in a non-significant 35% increase in the PI.

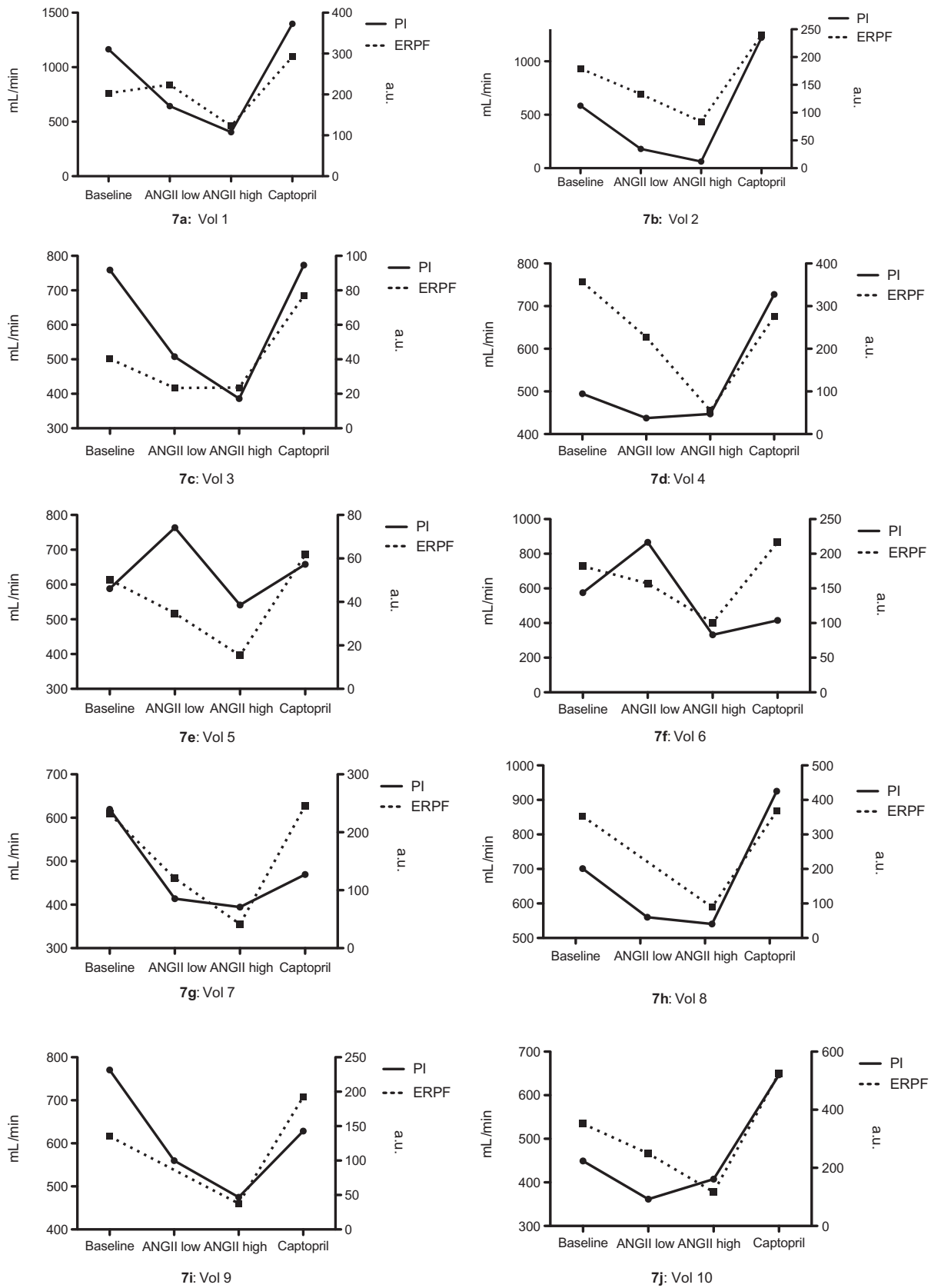
All study drugs were well tolerated. The mean arterial pressure increased as expected and returned to normal once AngII infusion was stopped and captopril administered.

CEUS studies with destruction-refilling sequences were performed in a very short time. There was no technical difficulty to visualize the kidneys. The duration of examination never exceeded 15 min.

Microcirculation in the critically ill has been well studied by way of orthogonal polarization spectral (OPS) imaging [19]. This technique, applied to the sublingual mucosa, allowed to demonstrate marked alterations in microcirculation in sepsis particularly in the patients with the worst outcome [6, 20]. It also revealed alterations after cardiopulmonary bypass correlated with lactate elevation [21] and in severe heart failure correlated with survival [22]. CEUS can add to techniques like OPS by enabling another type of assessment of the microcirculation. Its applicability to other organs and relative ease of execution makes CEUS potentially usable in the every day clinical routine.

Following Wei *et al.* [8], initial description of a technique for myocardial blood flow quantification using high MI and intermittent imaging mode, several authors attempted





**Fig. 7.** Perfusion indices (PI) and ERPF in 10 volunteers at baseline, after infusion of 1 ng/kg/min of AngII (AngII low), after infusion of 3 ng/kg/min of AngII (AngII high) and after oral captopril (captopril). Vol = volunteer with the number for each volunteer next to it; ERPF expressed in millilitres per minute, AngII Low: angiotensin II 1 ng/kg/min, AngII High: angiotensin II 3 ng/kg/min. Data expressed as median value.

to use CEUS to study organ microcirculation [9, 23, 24]. In the kidney, the first animal study was reported by Schlosser *et al.* [12] who showed that the acquisition of destruction-refilling sequences was also feasible using low-MI real-time imaging and allowed the differentiation between macro- and microcirculation. Wei *et al.* [9] then reported an excellent correlation ( $r = 0.82$ ,  $P < 0.001$ ) between the measurement of renal perfusion as obtained by CEUS and the flow measured by a probe directly placed on the renal artery when the flow was modified by either mechanical blockade or dopamine infusion. To our knowledge, the first report of human renal blood flow (RBF) quantification by CEUS was made by Hosotani *et al.* [13] who showed a significant correlation between RBF obtained by CEUS and radionuclide scanning values using technetium-99m mercaptoacetyltriglycine (Tc-99m MAG3) ( $r = 0.67$ ,  $P = 0.005$ ), as well as PAH clearance ( $r = 0.69$ ,  $P = 0.005$ ) in 16 patients with chronic kidney disease of various causes. Later, Kishimoto *et al.* [11] reported an increased micro-bubble velocity and fractional vascular volume during an infusion of dopamine, which was correlated with an increase in regional blood flow. More recently, Kalantarinia *et al.* [23] used CEUS to monitor the expected increase in renal blood flow after a high-protein meal in healthy volunteers. They reported a 42.8% increase in the  $A \times \beta$  parameter (representing renal blood flow) 2 h following a high-protein meal.

All these studies consistently showed promising results and concluded that CEUS could be a precise and reproducible way of evaluating renal perfusion. However, they present several limitations. Most of them make use of the method of Wei *et al.* [8] for quantifying renal blood flow. This method was experimentally well correlated but suffers from several flaws because it quantifies video after log compression and hence produces results, which depend on the US system used and user setting. A new approach developed by Arditi *et al.* [16] was shown to allow more objective estimates of flow when applied to data first linearized to be proportional to local ultrasound contrast agent concentration. This formalism was implemented within the Windows<sup>®</sup>-based software SonoPerf<sup>®</sup> used in the present study. SonoPerf<sup>®</sup> performs relative-flow quantification. SonoPerf<sup>®</sup> includes a tool for motion compensation and proposes a parametric imaging mode allowing to display colourimetric maps of any of the computed parameters, this feature being very helpful for precise ROI drawings.

The most remarkable result obtained in our study is the ability of CEUS to detect, on the basis of a PI measurement, a decrease in ERPF as small as 15%. Overall, the observed changes in PI induced by AngII were all statistically significant despite the small number of subjects. A non-significant increase in PI was observed, when associated with a very small (4%) increase in ERPF. PI and ERPF were not expected to be linearly correlated since they actually measure different parameters (macro- versus microcirculation). However, their parallel evolution establishes CEUS as a sensitive and reliable tool to assess renal perfusion changes. This study also showed that CEUS can be performed in a very limited time (<15 min). This finding is especially relevant if CEUS has to be applied in the intensive care unit.

Apart from the small number of subjects, this study has some limitations worth discussing. Firstly, the comparison between ERPF and PI cannot be strict since these two techniques actually compare different parameters, respectively, total renal blood flow and regional cortical flow. Thus, the study drugs can affect the renal microvasculature and the renal artery differently. However, in the absence of a generally recognized gold standard to measure renal cortical blood flow, we believe that even an imperfect comparator can provide a useful sense of changes in renal cortical blood flow as obtained for instance in response to a pharmacological stimulation.

Secondly, CEUS with SonoPerf provides a relative measurement of perfusion. The results are not expressed in millilitre per minutes but as perfusion indices that need to be compared to a baseline or another tissue reference. This is illustrated by the highly heterogeneous range of PI values at baseline (from 46 to 918) and the important IQR. This limitation has to be considered when designing studies relying on this technique. However, this study shows that changes are interpretable and trends in the evolution of perfusion indices provide valuable indications.

Heterogeneity of measurements was also present within each individual subject although less pronounced than across subjects. This might very well represent local micro-heterogeneities [24] but can also be related to imprecisions in the placement of ROI. To minimize this parameter, we applied strict standardized criteria for ROI selection, as shown in the Materials and Methods section. Three ROI's were drawn for each experimental time point and the results averaged. This approach limits the number of areas available for analysis but allowed us to minimize heterogeneity of measurement as confirmed by the good interobserver agreement.

Medullary perfusion indices and more importantly corticomedullary ratios of PI would probably be of great importance in the clinical setting. However, we were not able to obtain consistent data in the medullary segment due to wide local heterogeneity, possibly linked to the presence of numerous arteries and veins in this non-homogeneous zone.

Despite initial concerns, recent publications now establish CEUS as a very safe procedure [25–28], even applicable to critically ill patients. Since it is a fast, sensitive and reliable technique applicable at the bedside, CEUS is probably well designed to study renal microcirculation in humans and might be promising particularly in critically ill patients, in whom other techniques are not applicable.

## Conclusion

This study demonstrates that CEUS is able to detect changes in human renal cortical microcirculation as induced by AngII infusion and/or captopril administration. CEUS is a fast, sensitive and reliable technique to assess renal microcirculation. Further studies are necessary to establish its feasibility and its role in the evaluation of renal perfusion in situations such as acute kidney injury.

*Acknowledgements.* Financial support was provided by Bracco SA.

A.G.S. participated in the study design, carried out the volunteer recruitment, performed the contrast-enhanced ultrasounds studies, participated in the data interpretation and drafted the manuscript. L.H. participated in the data interpretation, performed the statistical analysis and reviewed the manuscript. G.W. participated in the volunteer recruitment, performed the statistical analysis and reviewed the manuscript. N.G. participated in the volunteer recruitment, in the renal haemodynamic studies and data interpretation. M.M. participated in the study design, prepared all study drugs, carried out the PAH clearance analysis and reviewed the manuscript. J.Y.M. participated in the study design, participated in the data evaluation and reviewed the manuscript. P.E. participated in the study design and reviewed the manuscript. M.B. participated in the study design and the data interpretation and reviewed the manuscript. B.V. participated in the study design and the data interpretation and reviewed the manuscript.

Genevieve Perrenoud—Department of Radiology, CHUV; Nicolas Rognin, Marcel Arditi, Anne Broillet, François Tranquart and Michel Schneider—Bracco Research Geneva, Switzerland; Ricardo Berti—Toshiba Medical, Switzerland.

## References

- Prowle JR, Ishikawa K, May CN *et al*. Renal blood flow during acute renal failure in man. *Blood Purif* 2009; 28: 216–225
- Selkurt EE. Renal blood flow and renal clearance in hemorrhagic shock. *Am J Physiol* 1946; 145: 699–799
- Wan L, Yang N, Hiew CY *et al*. An assessment of the accuracy of renal blood flow estimation by Doppler ultrasound. *Intensive Care Med* 2008; 34: 1503–1510
- Chierego M, Verdant C, De Backer D. Microcirculatory alterations in critically ill patients. *Minerva Anestesiol* 2006; 72: 199–205
- Buchele GL, Ospina-Tascon GA, De Backer D. How microcirculation data have changed my clinical practice. *Curr Opin Crit Care* 2007; 13: 324–331
- De Backer D, Dubois MJ. Assessment of the microcirculatory flow in patients in the intensive care unit. *Curr Opin Crit Care* 2001; 7: 200–203
- Schneider A, Johnson L, Goodwin M *et al*. Bench-to-bedside review: Contrast enhanced ultrasonography - a promising technique to assess renal perfusion in the ICU. *Critical Care* 2011; 15: 157.
- Wei K, Jayaweera AR, Firoozan S *et al*. Quantification of myocardial blood flow with ultrasound-induced destruction of microbubbles administered as a constant venous infusion. *Circulation* 1998; 97: 473–483
- Vogel R, Indermuhle A, Reinhardt J *et al*. The quantification of absolute myocardial perfusion in humans by contrast echocardiography: algorithm and validation. *J Am Coll Cardiol* 2005; 45: 754–762
- Wei K, Le E, Bin JP *et al*. Quantification of renal blood flow with contrast-enhanced ultrasound. *J Am Coll Cardiol* 2001; 37: 1135–1140
- Kishimoto N, Mori Y, Nishiue T *et al*. Renal blood flow measurement with contrast-enhanced harmonic ultrasonography: evaluation of dopamine-induced changes in renal cortical perfusion in humans. *Clin Nephrol* 2003; 59: 423–428
- Schlosser T, Pohl C, Veltmann C *et al*. Feasibility of the flash-replenishment concept in renal tissue: which parameters affect the assessment of the contrast replenishment? *Ultrasound Med Biol* 2001; 27: 937–944
- Hosotani Y, Takahashi N, Kiyomoto H *et al*. A new method for evaluation of split renal cortical blood flow with contrast echography. *Hypertens Res* 2002; 25: 77–83
- Hall JE. *Guyton & Hall Textbook of Medical Physiology*. Philadelphia, PA: Elsevier Saunders, 2011 Chapter 19: p. 221
- Jarrott B, Drummer O, Hooper R *et al*. Pharmacokinetic properties of captopril after acute and chronic administration to hypertensive subjects. *Am J Cardiol* 1982; 49: 1547–1549
- Arditi M, Frinking PJ, Zhou X *et al*. A new formalism for the quantification of tissue perfusion by the destruction-replenishment method in contrast ultrasound imaging. *IEEE Trans Ultrason Ferroelectr Freq Control* 2006; 53: 1118–1129
- Guyton A, Hall JE. *Textbook of Medical Physiology*. Saunders, 2006; Chapter 26
- Coltamai L, Maillard M, Simon A *et al*. Comparative vascular and renal tubular effects of angiotensin II receptor blockers combined with a thiazide diuretic in humans. *J Hypertens* 2010; 28: 520–526
- Groner W, Winkelman JW, Harris AG *et al*. Orthogonal polarization spectral imaging: a new method for study of the microcirculation. *Nat Med* 1999; 5: 1209–1212
- De Backer D, Creteur J, Preiser JC *et al*. Microvascular blood flow is altered in patients with sepsis. *Am J Respir Crit Care Med* 2002; 166: 98–104
- De Backer D, Dubois MJ, Schmartz D *et al*. Microcirculatory alterations in cardiac surgery: effects of cardiopulmonary bypass and anesthesia. *Ann Thorac Surg* 2009; 88: 1396–1403
- De Backer D, Creteur J, Dubois MJ *et al*. Microvascular alterations in patients with acute severe heart failure and cardiogenic shock. *Am Heart J* 2004; 147: 91–99
- Kalantarinia K, Belcik JT, Patrie JT *et al*. Real-time measurement of renal blood flow in healthy subjects using contrast-enhanced ultrasound. *Am J Physiol Renal Physiol* 2009; 297: F1129–F1134
- Rim SJ, Leong-Poi H, Lindner JR *et al*. Quantification of cerebral perfusion with “Real-Time” contrast-enhanced ultrasound. *Circulation* 2001; 104: 2582–2587
- Wei K, Mulvagh SL, Carson L *et al*. The safety of deFinity and Optison for ultrasound image enhancement: a retrospective analysis of 78,383 administered contrast doses. *J Am Soc Echocardiogr* 2008; 21: 1202–1206
- Main ML, Ryan AC, Davis TE *et al*. Acute mortality in hospitalized patients undergoing echocardiography with and without an ultrasound contrast agent (multicenter registry results in 4,300,966 consecutive patients). *Am J Cardiol* 2008; 102: 1742–1746
- Kusnetzky LL, Khalid A, Khumri TM *et al*. Acute mortality in hospitalized patients undergoing echocardiography with and without an ultrasound contrast agent: results in 18,671 consecutive studies. *J Am Coll Cardiol* 2008; 51: 1704–1706
- Dolan MS, Gala SS, Dodla S *et al*. Safety and efficacy of commercially available ultrasound contrast agents for rest and stress echocardiography a multicenter experience. *J Am Coll Cardiol* 2009; 53: 32–38

Received for publication: 4.1.11; Accepted in revised form: 17.5.11