

A Focus on Subtle Signs and Motor Behavior to Unveil Awareness in Unresponsive Brain-Impaired Patients

The Importance of Being Clinical

Karin Diserens, MD,* Ivo A. Meyer, MD,* Jane Jöhr, PhD, Alessandro Pincherle, MD, Vincent Dunet, MD, Polona Pozeg, PhD, Philippe Ryvlin, MD, PhD, Dafin F. Mureşanu, MD, PhD, Robert D. Stevens, MD, and Nicholas D. Schiff, MD

Neurology® 2023;100:1144-1150. doi:10.1212/WNL.0000000000207067

Correspondence

Dr. Meyer
meyer.ivo@gmail.com

Abstract

Brain-injured patients in a state of cognitive motor dissociation (CMD) exhibit a lack of command following using conventional neurobehavioral examination tools but a high level of awareness and language processing when assessed using advanced imaging and electrophysiology techniques. Because of their behavioral unresponsiveness, patients with CMD may seem clinically indistinguishable from those with a true disorder of consciousness that affects awareness on a substantial level (coma, vegetative state/unresponsive wakefulness state, or minimally conscious state minus). Yet, by expanding the range of motor testing across limb, facial, and ocular motricity, we may detect subtle, purposeful movements even in the subset of patients classified as vegetative state/unresponsive wakefulness state. We propose the term of clinical CMD to describe patients showing these slight but determined motor responses and exhibiting a characteristic akinetic motor behavior as opposed to a pyramidal motor system behavior. These patients may harbor hidden cognitive capabilities and significant potential for a good long-term outcome. Indeed, we envision CMD as ranging from complete (no motor response) to partial (subtle clinical motor response) forms, falling within a spectrum of progressively better motor output in patients with considerable cognitive capabilities. In addition to providing a decisional flowchart, we present this novel approach to classification as a graphical model that illustrates the range of clinical manifestations and recovery trajectories fundamentally differentiating true disorders of consciousness from the spectrum of CMD.

RELATED ARTICLE

Editorial

Examining Unresponsive Patients: Basics Come First
Page 1127

MORE ONLINE

Podcast

*These authors contributed equally to this work as first authors.

From the Neurology and Acute Neurorehabilitation Unit (K.D., I.A.M., J.J., P.R.), Department of Clinical Neurosciences, and Department of Radiology (V.D., P.P.), Lausanne University Hospital and University of Lausanne; University Hospital of Old Age Psychiatry (I.A.M.), University of Bern, Switzerland; Neurology Unit (A.P.), Department of Medicine, Hôpitaux Robert Schuman, Luxembourg; Department of Neuroscience (D.F.M.), Luliu Hatjeganu University of Medicine and Pharmacy, Cluj-Napoca, Romania; Departments of Anesthesiology and Critical Care Medicine, Neurology, and Neurosurgery (R.D.S.), School of Medicine, Johns Hopkins University, Baltimore, MD; Feil Family Brain and Mind Research Institute (N.D.S.), Weill Cornell Medical College, New York, NY; and Department of Neurology (N.D.S.), New York Presbyterian Hospital.

Go to [Neurology.org/N](https://www.neurology.org/N) for full disclosures. Funding information and disclosures deemed relevant by the authors, if any, are provided at the end of the article.

Glossary

AIE = advanced imaging and electrophysiology technique; **CMD** = cognitive motor dissociation; **CRS-R** = Coma Recovery Scale–Revised; **MBT-r** = Motor Behavior Tool–Revised.

Advanced imaging and electrophysiology techniques (AIEs) can detect intact awareness and significant cognitive abilities in unresponsive brain-impaired patients, a condition called cognitive motor dissociation (CMD). However, the tools and experts competent in analyzing and interpreting the results are not widely available. We propose that inspection of overall motor behavior and detection of subtle clinical signs across limb, facial, and ocular motricity using extended testing by means of the Coma Recovery Scale–Revised (CRS-R)¹ in conjunction with the Motor Behavior Tool–Revised (MBT-r)^{2,3} are clinical keys to revealing the presence of intentional movement and awareness. In addition, we describe an algorithm-based procedure for evaluating unresponsive brain-injured patients using clinical and basic paraclinical examinations. Finally, we present a graphical representation modeling the range of clinical manifestations of patients with true disorders of consciousness and CMD and potential recovery trajectories after major brain impairment.

Diagnosing CMD: A Clinical and Technical Challenge

The existence of covert awareness was first demonstrated in 2006,⁴ and the term CMD was introduced in 2015⁵ to describe patients with command following discernible by specific AIE-derived neural signatures but without externally observable motor responses. In a recent article in this journal, an algorithmic flowchart to determine when AIEs should be used was proposed.⁶ We welcome these efforts to establish criteria for whether AIEs are suitable on an individual patient basis. Currently, AIEs are not warranted in routine clinical practice if evidence of a conscious motor response is observed during bedside neurobehavioral assessment.

Ideally, AIEs should be used for patients with a higher probability of harboring covert awareness, although guidelines establishing such probabilities are only slowly emerging now. Performing AIEs and interpreting their results, especially in the acute setting, requires considerable technical and medical expertise. A possible solution to the logistics posed by these technologies might be a hub-and-spoke model, as proposed by Young et al.,⁷ whereby peripheral collaborating sites with less resources (i.e., spokes) collect AIE data locally and then send the data to a specialized medical center (i.e., hub) that provides the expertise for processing and analysis. This could help reduce geographic and financial gaps and guarantee the detection of covert awareness in patients who might otherwise be misdiagnosed. Still, there are at least 2 major

limitations. First, this approach is currently only viable in health systems with sizeable economical resources. Second, given that patients in the acute setting often have considerable executive, attentional, or language dysfunction from which they would eventually recover, there is an unquantifiable risk of misclassifying such patients as lacking conscious awareness when strict AIE assessment protocols are used. Proving that an unresponsive patient is aware is hard, but proving that the patient is lacking awareness is harder, if not impossible.

Clinical Unmasking of Covert Awareness

We argue that a practical and immediate advance in detecting patients with apparent covert awareness can be achieved by further expanding the current clinical assessment scales. Recent studies indicate that a significant fraction of patients with covert awareness defined by the combination of traditional standardized neurobehavioral assessments and AIEs can be identified clinically, circumventing the need for AIEs in these patients.^{2,3} Current clinical assessment scales, including the thorough CRS-R, often fail to diagnose awareness in patients who show subtle signs of interaction, even in those retaining some motor localization of the painful stimulus, visual fixation, or visual tracking. In the acute care setting, the rate of patients with covert awareness misdiagnosed as lacking consciousness is at least as high as 15% when using the CRS-R as this is the percentage of unresponsive cases (as classified by the CRS-R) for which AIEs captured evidence of unequivocal brain activation in response to a command.⁸ In our experience, we estimate the misclassification rate to be around 30% when comparing the CRS-R diagnosis (e.g., vegetative state) at admission to an acute neurorehabilitation unit to the diagnosis at discharge.⁹

Patients with true disorders of consciousness are not motionless but display an array of reflexive behaviors and, after recovering fragments of awareness, purposeful motor behavior. These patients often progress through a prolonged or permanent confusional state, associated with motor hyperactivity (agitation) stemming from an underlying lack of orientation and incoherent cognition. On the cognitive level, such residual fragments of consciousness may be detected using the CRS-R as limited but overt and reproducible motor responses, with patients failing to regain consistent and accurate communication systems (via speech or gesture). In contrast to the motor patterns observed in patients with true disorders of consciousness, relatively focal lesions that globally affect the motor

Table Motor Behavior Tool–Revised (MBT-r)

Sign	Observations	Comments
Positive signs		
1. Spontaneous nonreflexive movement	Any nonstereotypical, noncontextualized, and nonrepetitive intentional motor behavior	Observation of spontaneous behavior without stimulation at baseline or at any moment
2. Response to a command	Any nonreflexive intentional response to a verbal command	Use the CRS-R command-following protocol ¹
3. Visual fixation or visual pursuit	Any visual fixation or visual pursuit in any direction	Defined as eyes changing from an initial to a new fixation point or eyes tracking a moving target
4. Response in a motivational context	Any appearance or increase in the frequency of nonreflexive motor response in a salient context	For example, on hearing a familiar voice, the patient's mother tongue or the patient's own or nickname
5. Response to a noxious stimulation		
5a. Defensive response: nipple sign	Any attempt of defense when twisting the patient's nipple while holding the patient's arm	Before scoring, exclude stereotypical posturing as a confounding factor
5b. Defensive response: nail bed sign	Any defense gesture to deep pressure applied to a nail bed (test all 4 extremities)	The kinematics of an intentional defense differ from those of a nociceptive withdrawal reflex ²
5c. Grimace	Any nonreflexive grimace on administering a noxious stimulation	Do not score the reflexive rictus-like grimace of stereotypical posturing or tetanus
Negative signs (brainstem release signs)		
6. Decorticate posturing, decerebrate posturing, or incessant paroxysmal sympathetic hyperactivity	Spontaneous or stimulus-induced stereotypical posturing (decorticate or decerebrate posturing) or incessant neurovegetative responses (i.e., rapid-onset episodes of tachycardia, hypertension, tachypnea, fever, diaphoresis, and dystonic posturing of up to 30-min duration)	In the absence of brainstem lesions, these signs reflect large and widespread forebrain lesions resulting in functional disconnection of the red nucleus (decorticate posturing), of vestibulo-/tecto-reticulospinal postural reflexes (decerebrate posturing), or of neurovegetative centers
7. Pathologic conjugate roving eye movements (ping-pong gaze)	Resembles slow eye movements of light sleep; can persist with open or closed eyes, lack total excursion, or move from an extreme gaze to the midline instead of to the opposite extreme; and may present or lack pauses between excursions	Also called short-cycle periodic alternating gaze; caused by large and widespread lesions causing a disconnection between the cortical inhibitory control and brainstem gaze centers

Abbreviation: CRS-R = Coma Recovery Scale–Revised.

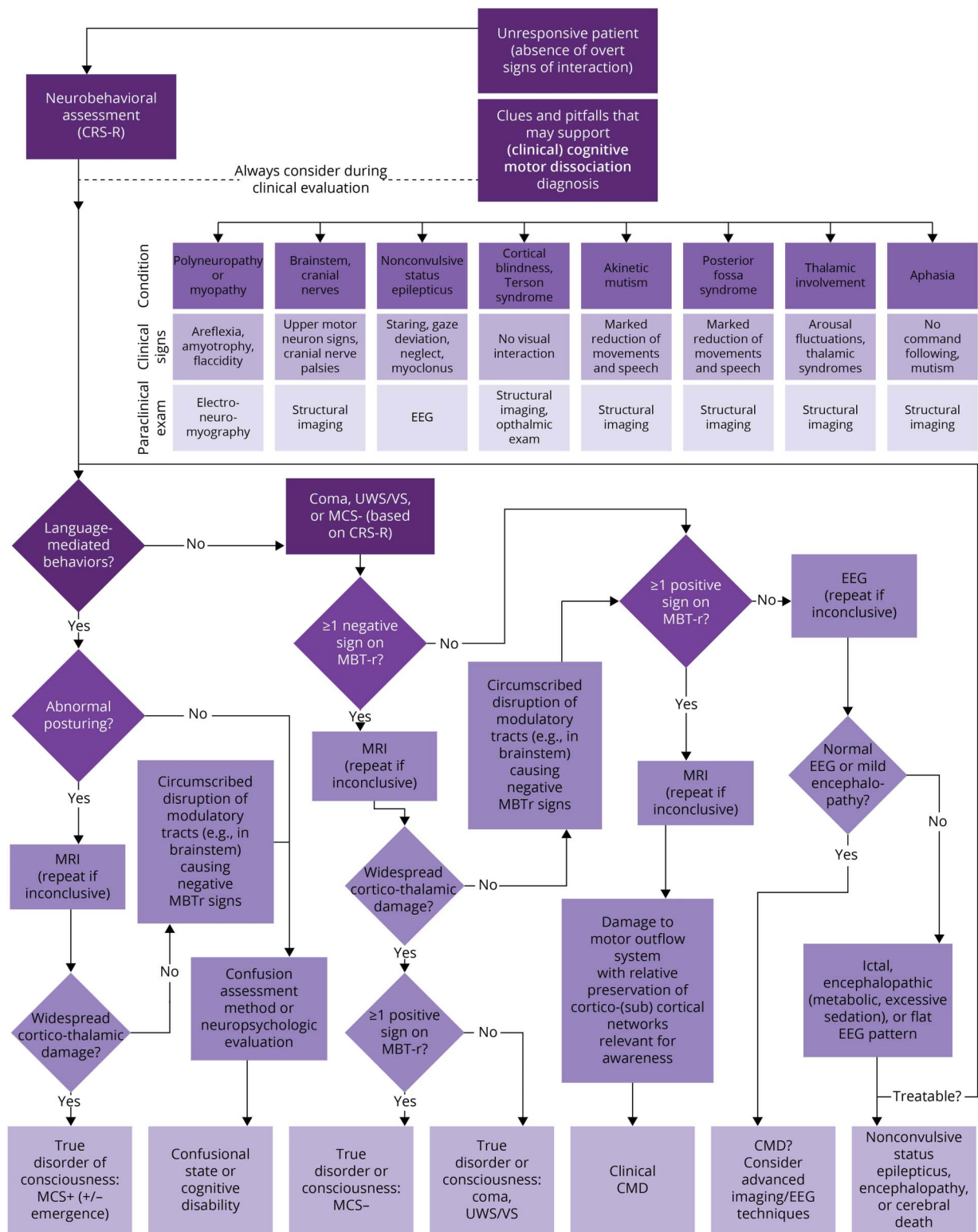
A positive sign is scored even if subtle if it stands out clearly from a reflexive or stereotypical background movement. Note that repeatability is not necessary for the MBT-r: the observation of a single subtle intentional movement, for example, visual pursuit obviously discernible from the baseline eye movement, is scored as a positive sign. When in doubt, the sign is not recorded. To facilitate interpretation of subtle signs, whenever possible, patients are filmed with the consent of their relatives. An older version of the MBT-r included the absence of oculoccephalic reflex as a negative sign (as an alternative to roving eye movements). Although this clinical finding is associated with bad prognosis, it is not a brainstem release sign.

output channels can cause a characteristic lack of motor or verbal interaction in patients with CMD, hiding their considerable cognitive capability. As mentioned above, the residual signs in such motionless patients may be too subtle to be identified using the CRS-R alone. We have evaluated, and propose using, a complementary clinical tool, the MBT-r (see description in Table), designed to detect subtle motor behaviors that are overlooked by the CRS-R that establishes strict criteria for scoring a specific motor behavior as an expression of consciousness.² In a prospective validation study, the MBT-r was shown to identify a subset of patients whose cognitive abilities were underestimated by the CRS-R and demonstrated excellent interrater agreement.³ Subsequent data from a sample of 141 patients undergoing inpatient rehabilitative care suggested that the MBT-r used in conjunction with the CRS-R leads to greater sensitivity in detecting awareness than the CRS-R alone and identified patients with a high probability of functional recovery at discharge.⁹

Scrutinize Clues and Pitfalls to Maximize the Clinical Detection Rate of Awareness

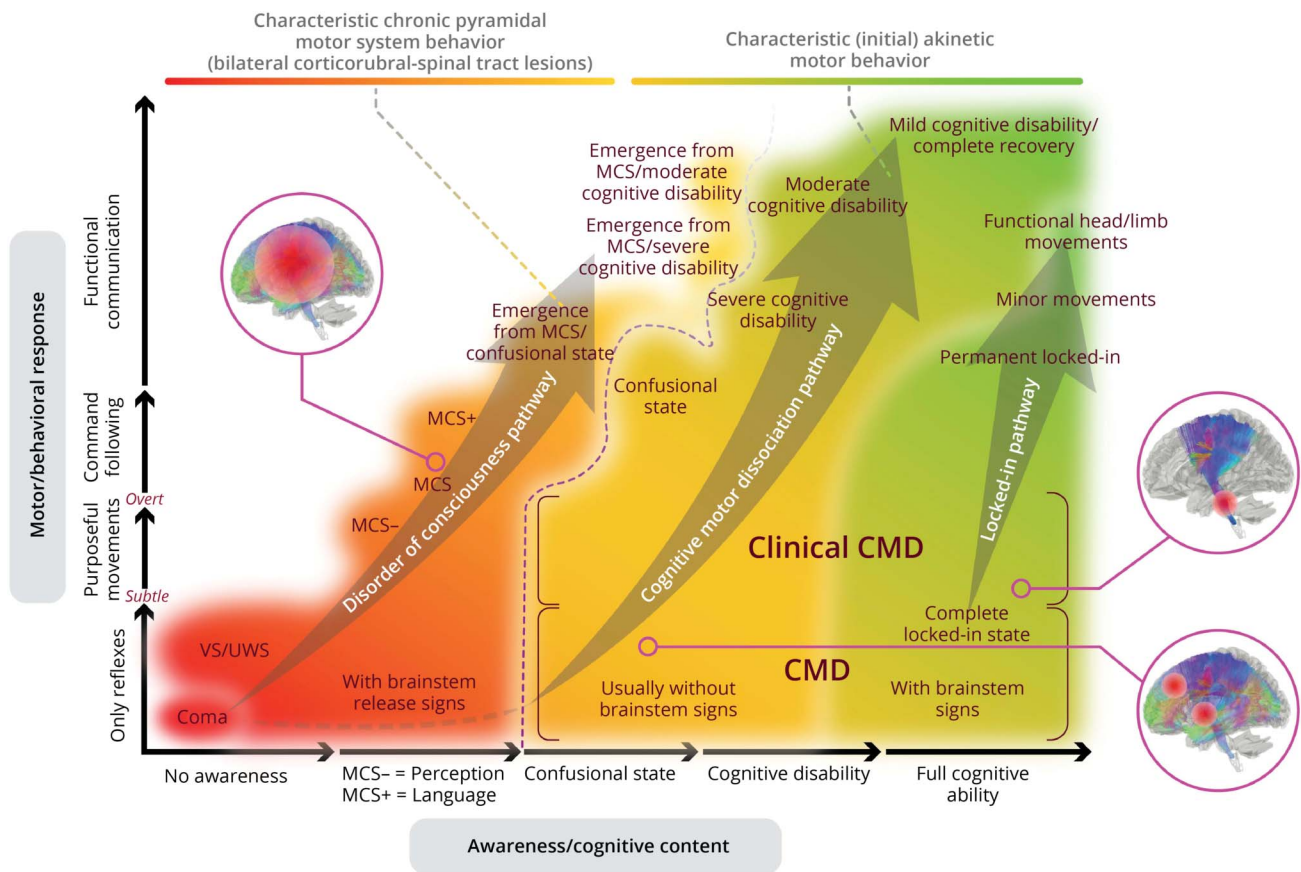
During the assessment of unresponsive patients, it is essential to scrutinize the clues and pitfalls that may support the diagnosis of CMD.¹⁰ Bringing all this together, we created a flowchart that considers clinical, pathophysiologic, radiologic, and electrophysiologic aspects to establish an early diagnosis of either a true disorder of consciousness or CMD (Figure 1).¹¹ We propose using the suggested flowchart as soon as possible, that is, in the intensive care unit 24 hours after sedation withdrawal, always considering residual anesthesia as a potential confounder. A comprehensive clinical assessment should be conducted at least 3 times a week in conjunction with pathophysiologic considerations and paraclinical investigations if necessary. As indicated in the flowchart, we use conventional

Figure 1 Flowchart for Acute Assessment of Unresponsive Patients With a Suspected Major Cerebral Impairment



For an explanation of MBT-r signs, see the Table. For a better understanding of the different nosological diagnoses (true disorders of consciousness vs cognitive motor dissociation spectrum), see the model in Figure 2. Language-mediated behavior includes command following, intelligible verbalization, and communication. Abnormal posturing refers to stereotypical decorticate and decerebrate posturing (one of the negative MBT-r signs). Note that the vertical eye movements/eye blinking of an incomplete locked-in state are considered overt signs of interaction. CMD = cognitive motor dissociation; CRS-R = Coma Recovery Scale-Revised; MBT-r = Motor Behavior Tool-Revised; MCS = minimally conscious state (+ = plus and - = minus); VS/UWS = vegetative state/unresponsive wakefulness syndrome. Created using the web-based diagram application Lucidchart (Lucid Software Inc., South Jordan, UT). It is an updated version of a flowchart published under an open access Creative Common CC BY license.¹⁰

Figure 2 Model of Behavioral and Cognitive Evolution After Severe Brain Impairment



The diagnostic spectrum and clinical evolution after severe brain impairment is represented on a 2-dimensional graph comparing the degree of cognitive content (x-axis) against the degree of behavioral response (y-axis). The red-yellow-green color gradient represents an approximation of the degree of recovery, with red being the worst and green the best. Both cognitive content and behavioral response are determined using the CRS-R in conjunction with the MBT-r, which we developed to expand the range of motor testing to detect subtle, purposeful movements (the so-called positive signs) and brainstem release signs (the so-called negative signs). Concerning the motor/behavioral response of patients with CMD, the functional ambulation category quantifies the degree of functional motor recovery. In cases of a total lack of motor response, AIEs may unveil CMD-defining covert cognition. For patients with a good behavioral response, confusion and neuropsychological assessment protocols distinguish between the different degrees of functional recovery. Patients with a severe brain impairment appear to fall mainly into 2 categories—true disorders of consciousness (spanning from VS/UWS to MCS+, red hues) and CMD/locked-in state (yellow-green hues)—with different underlying lesions (represented by the symbolic brain images), clinical manifestations (e.g., brainstem release signs), and prognosis (represented by the arrows along the recovery pathways). The circles/ellipses surrounding the different diagnoses (VS/UWS, MCS-, etc.) account for the fact that many patients never recover after a specific point in the recovery pathway. Widespread lesions across heteromodal cortical association areas and cortico-thalamic tracts cause the impairment in patients with true disorders of consciousness. Consequently, many of these patients may suffer chronically from a total (VS/UWS) or partial (MCS) lack of awareness. Posturing typically lasts after conscious emergence, causing characteristic clinical motor patterns usually not seen in patients with CMD. Patients with CMD, on the other hand, are characterized by a total (complete CMD, with covert cognition only detectable by AIEs) or near-total (clinical CMD with subtle, purposeful movements) lack of determined movements. Most patients with CMD do not develop brainstem release signs, except for complete locked-in state patients, who typically manifest decorticate/decerebrate posturing. We indicate the potential recovery pathways using symbolic arrows. AIE = advanced imaging and electrophysiology technique; CMD = cognitive motor dissociation; CRS-R = Coma Recovery Scale-Revised; MBT-r = Motor Behavior Tool-Revised; MCS = minimally conscious state (+ = plus and - = minus); VS/UWS = vegetative state/unresponsive wakefulness state. Created using the vector graphics editor Adobe Illustrator (Adobe Inc., San Jose, CA). Brain images were derived from the population-averaged tractography atlas by Yeh et al.²⁴

structural MRI as an adjunctive examination to dichotomize patients into true disorders of consciousness or clinical CMD.¹² It is not our intention to challenge the importance of AIEs. In its most complete form, that is, in the complete absence of motor response, CMD is only uncovered if task-based AIEs demonstrate evidence of command following. Resting-state AIE examinations also play an important role, and the pursuit of covert awareness should include an investigation of the functional architecture dynamics using resting-state functional MRI and PET, concentrating primarily on the brain's ability to

shift between the internal (default mode) and external awareness (frontoparietal) networks. The brain's aptitude to switch between intrinsic and extrinsic network activation has been associated with recovery of consciousness¹³ and could potentially be used as a biomarker for covert awareness. Neurophysiologic evaluations such as non-task-evoked potentials help to discriminate clinical CMD (especially with aphasia and attention deficit) from patients with a true disorder of consciousness,¹⁴ thus contributing to a better understanding of the underlying network mechanisms.

A Spectrum of Clinical Manifestations and Recovery Trajectories: Neuroanatomic and Physiologic Rationale for a New Model

Given that brain function in patients with CMD is likely to be closer to that of healthy and locked-in state patients than to minimally conscious state plus patients with reliable command following,^{15,16} we suggest that there is a dividing line separating true disorders of consciousness from CMD and locked-in state patients. However, we propose this partition should be considered a gradient rather than a sharp boundary. In other words, although we should avoid simplistic dichotomizations, this concept forms the basis of a new approach to classification in which unresponsive patients with CMD are in a distinct category from unresponsive patients without CMD. We envision a spectrum of different motor/cognitive states, ranging from complete CMD that cannot be detected even by extended clinical testing to partial CMD (clinical CMD) with subtle clinical signs and typical motor behavior to classical locked-in state (preservation of vertical eye movements/eye blinking) (Figure 2).

The cognitive abilities of patients with CMD may range from the limited language comprehension functions of minimally conscious state plus patients to the almost intact cognitive capabilities of complete locked-in state patients.¹⁷ This raises the question of how to distinguish patients with CMD at the lower end of the cognitive spectrum from those with true disorders of consciousness who have regained some command-following abilities (e.g., minimally conscious state patients). Based on pathophysiologic considerations, a key feature clinically dichotomizing most CMD and true disorders of consciousness might be the presence of brainstem release signs in the absence of brainstem lesions. Such release signs imply widespread destruction of the cortico-cortical networks relevant for awareness. However, it is essential to initially exclude additional brainstem or cerebellar lesions as these can complicate the clinical assessment for at least 2 reasons. First, these lesions can disrupt the ascending arousal system, affecting wakefulness despite the relative intactness of structures essential for awareness. Second, circumscribed lesions of the corticospinal tract and the tracts connecting the higher modulatory centers and the rubral and/or vestibular nuclei in the rostral part of the brainstem can cause tetraplegia with decorticate or decerebrate posturing, respectively, which may be falsely attributed to larger lesions located more cranially.

Although the exact nature of awareness remains an unsolved complex problem of neuroscience, it is a plausible assumption that it requires the activation of large-scale decentralized cortico-cortical networks.¹⁸ This decentralization increases the robustness of awareness against focal damage. It also means that large and widespread lesions will be necessary to significantly disrupt this fundamental function of the brain.¹² Classically, neurologic practice has considered bilateral lesions of

the cortex or of the upper brainstem and central thalamus or lesions altering both as a requirement for producing coma.¹⁹ Because of such widespread lesions, a functional cortical disconnection is detected clinically as decorticate or decerebrate posturing,²⁰ pathologic roving eye movements (ping-pong gaze, i.e., short-cycle periodic alternating gaze),²¹ and/or incessant paroxysmal sympathetic hyperactivity.²² These clinical manifestations have long been associated with poor outcome and, on a pathophysiologic level, are likely caused by a disruption of modulatory (mainly inhibitory) corticorubral-spinal, cortico-vestibular, cortico-mesencephalic, and/or cortico-diencephalic tracts (see negative MBT-r signs in Table).

Patients within the CMD spectrum as opposed to those with true disorders of consciousness are not only characterized by specific clinical, radiologic, and pathophysiologic features but, most importantly, by their particular recovery trajectories.⁹ An early diagnosis of CMD does not automatically imply a good outcome, as the individual prognosis depends heavily on the specific cerebral functions affected; but overall, patients with CMD have far better long-term outcomes, as measured by multiple prognostic scales.^{8,9,23}

Conclusion

In conclusion, we want to underscore the importance of a thorough clinical assessment targeted to observing the motor behavior, as well as the role of careful clinical and paraclinical screening (Figure 1), selecting conventional structural MRI before proceeding to more sophisticated technical diagnostic tools. We present this approach as a model depicting the spectrum of clinical manifestations and recovery trajectories after significant brain impairment (Figure 2).

Acknowledgment

The authors are grateful to Dr. Melanie Price Hirt for proofreading this manuscript and Mr. Ehsan Faridi for significantly improving the graphical design of Figure 2. The authors also thank Dr. Edlow for his feedback on an earlier version of this work. The authors are particularly indebted to their forebears and mentors who always emphasized the importance of a proper clinical examination.

Study Funding

No targeted funding reported.

Disclosure

The authors report no disclosures relevant to the manuscript. Go to [Neurology.org/N](https://www.neurology.org/N) for full disclosures.

Publication History

Received by *Neurology* August 13, 2022. Accepted in final form January 3, 2023. Submitted and externally peer reviewed. The handling editor was Associate Editor Rebecca Burch, MD.

Appendix Authors

Name	Location	Contribution
Karin Diserens, MD	Neurology and Acute Neurorehabilitation Unit, Department of Clinical Neurosciences, Lausanne University Hospital and University of Lausanne, Switzerland	Drafting/revision of the manuscript for content, including medical writing for content
Ivo A. Meyer, MD	Neurology and Acute Neurorehabilitation Unit, Department of Clinical Neurosciences, Lausanne University Hospital and University of Lausanne; University Hospital of Old Age Psychiatry, University of Bern, Switzerland	Drafting/revision of the manuscript for content, including medical writing for content; additional contributions: creation of the graphical model and flowchart
Jane Jöhr, PhD	Neurology and Acute Neurorehabilitation Unit, Department of Clinical Neurosciences, Lausanne University Hospital and University of Lausanne, Switzerland	Drafting/revision of the manuscript for content, including medical writing for content
Alessandro Pincherle, MD	Neurology Unit, Department of Medicine, Hôpitaux Robert Schuman, Luxembourg	Drafting/revision of the manuscript for content, including medical writing for content
Vincent Dunet, MD	Department of Radiology, Lausanne University Hospital and University of Lausanne, Switzerland	Drafting/revision of the manuscript for content, including medical writing for content
Polona Pozeg, PhD	Department of Radiology, Lausanne University Hospital and University of Lausanne, Switzerland	Drafting/revision of the manuscript for content, including medical writing for content
Philippe Ryvlin, MD, PhD	Neurology and Acute Neurorehabilitation Unit, Department of Clinical Neurosciences, Lausanne University Hospital and University of Lausanne, Switzerland	Drafting/revision of the manuscript for content, including medical writing for content
Dafin F. Mureşanu, MD, PhD	Department of Neuroscience, Luliu Haţieganu University of Medicine and Pharmacy, Cluj-Napoca, Romania	Drafting/revision of the manuscript for content, including medical writing for content
Robert D. Stevens, MD	Departments of Anesthesiology and Critical Care Medicine, Neurology, and Neurosurgery, School of Medicine, Johns Hopkins University, Baltimore, MD	Drafting/revision of the manuscript for content, including medical writing for content

Appendix (continued)

Name	Location	Contribution
Nicholas D. Schiff, MD	Feil Family Brain and Mind Research Institute, Weill Cornell Medical College, New York, NY; Department of Neurology, New York Presbyterian Hospital	Drafting/revision of the manuscript for content, including medical writing for content

References

- Giacino JT, Kalmar K, Whyte J. The JFK Coma Recovery Scale-Revised: measurement characteristics and diagnostic utility. *Arch Phys Med Rehabil*. 2004;85(12):2020-2029.
- Pignat JM, Mauron E, Jöhr J, et al. Outcome prediction of consciousness disorders in the acute stage based on a complementary motor behavioural tool. *PLoS One*. 2016; 11(6):e0156882.
- Pincherle A, Jöhr J, Chatelle C, et al. Motor behavior unmasks residual cognition in disorders of consciousness. *Ann Neurol*. 2019;85(3):443-447.
- Owen AM, Coleman MR, Boly M, Davis MH, Laureys S, Pickard JD. Detecting awareness in the vegetative state. *Science*. 2006;313(5792):1402.
- Schiff ND. Cognitive motor dissociation following severe brain injuries. *JAMA Neurol*. 2015;72(12):1413-1415.
- Monti MM, Schnakers C. Flowchart for implementing advanced imaging and electrophysiology in patients with disorders of consciousness: to fMRI or not to fMRI. *Neurology*. 2022;98(11):452-459.
- Young MJ, Edlow BL. The quest for covert consciousness: bringing neuroethics to the bedside. *Neurology*. 2021;96(19):893-896.
- Claassen J, Doyle K, Matory A, et al. Detection of brain activation in unresponsive patients with acute brain injury. *N Engl J Med*. 2019;380(26):2497-2505.
- Jöhr J, Halimi F, Pasquier J, Pincherle A, Schiff N, Diserens K. Recovery in cognitive motor dissociation after severe brain injury: a cohort study. *PLoS One*. 2020;15(2):e0228474.
- Pincherle A, Rossi F, Jöhr J, et al. Early discrimination of cognitive motor dissociation from disorders of consciousness: pitfalls and clues. *J Neurol*. 2021;268(1):178-188.
- Jöhr J, Aureli V, Meyer I, Cossu G, Diserens K. Clinical cognitive motor dissociation: a case report showing how pitfalls can hinder early clinical detection of awareness. *Brain Sci*. 2022;12(2):157.
- Pozeg P, Jöhr J, Pincherle A, et al. Discriminating cognitive motor dissociation from disorders of consciousness using structural MRI. *Neuroimage Clin*. 2021;30:102651.
- Bodien YG, Chatelle C, Edlow BL. Functional networks in disorders of consciousness. *Semin Neurol*. 2017;37(5):485-502.
- Noel JP, Chatelle C, Perdiks S, et al. Peri-personal space encoding in patients with disorders of consciousness and cognitive-motor dissociation. *Neuroimage Clin*. 2019;24:101940.
- Forgacs PB, Conte MM, Fridman EA, Voss HU, Victor JD, Schiff ND. Preservation of electroencephalographic organization in patients with impaired consciousness and imaging-based evidence of command-following. *Ann Neurol*. 2014;76(6):869-879.
- Stender J, Gosseries O, Bruno MA, et al. Diagnostic precision of PET imaging and functional MRI in disorders of consciousness: a clinical validation study. *Lancet*. 2014; 384(9942):514-522.
- Posner JB, Saper CB, Schiff ND, Claassen J. Prognosis in coma and related disorders of consciousness and mechanisms underlying outcomes. In: *Plum and Posner's Diagnosis and Treatment of Stupor and Coma*. Oxford University Press; 2019:379-436.
- Qureshi AY, Stevens RD. Mapping the unconscious brain: insights from advanced neuroimaging. *J Clin Neurophysiol*. 2022;39(1):12-21.
- Plum F, Posner JB. *The Diagnosis of Stupor and Coma*. F. A. Davis Co.; 1972:4.
- Knight J, Decker LC. Decerebrate and decorticate posturing. In: *StatPearls*. StatPearls Publishing; 2022.
- Johkura K, Komiyama A, Tobita M, Hasegawa O. Saccadic ping-pong gaze. *J Neuroophthalmol*. 1998;18(1):43-46.
- Rabinstein AA. *Paroxysmal Sympathetic Hyperactivity*. UpToDate; 2022.
- Eggebike J, Shen Q, Doyle K, et al. Cognitive-motor dissociation and time to functional recovery in patients with acute brain injury in the USA: a prospective observational cohort study. *Lancet Neurol*. 2022;21(8):704-713.
- Yeh FC, Panesar S, Fernandes D, et al. Population-averaged atlas of the macroscale human structural connectome and its network topology. *Neuroimage*. 2018;178:57-68.

Neurology[®]

A Focus on Subtle Signs and Motor Behavior to Unveil Awareness in Unresponsive Brain-Impaired Patients: The Importance of Being Clinical

Karin Diserens, Ivo A. Meyer, Jane Jöhr, et al.

Neurology 2023;100;1144-1150 Published Online before print February 28, 2023

DOI 10.1212/WNL.0000000000207067

This information is current as of February 28, 2023

Updated Information & Services	including high resolution figures, can be found at: http://n.neurology.org/content/100/24/1144.full
References	This article cites 20 articles, 3 of which you can access for free at: http://n.neurology.org/content/100/24/1144.full#ref-list-1
Subspecialty Collections	This article, along with others on similar topics, appears in the following collection(s): All Imaging http://n.neurology.org/cgi/collection/all_imaging All Rehabilitation http://n.neurology.org/cgi/collection/all_rehabilitation Clinical neurology examination http://n.neurology.org/cgi/collection/clinical_neurology_examination Coma http://n.neurology.org/cgi/collection/coma Prognosis http://n.neurology.org/cgi/collection/prognosis
Permissions & Licensing	Information about reproducing this article in parts (figures, tables) or in its entirety can be found online at: http://www.neurology.org/about/about_the_journal#permissions
Reprints	Information about ordering reprints can be found online: http://n.neurology.org/subscribers/advertise

Neurology® is the official journal of the American Academy of Neurology. Published continuously since 1951, it is now a weekly with 48 issues per year. Copyright © 2023 American Academy of Neurology. All rights reserved. Print ISSN: 0028-3878. Online ISSN: 1526-632X.

