



OPEN ACCESS

Clinical science

# Ten-year experience with intracameral chemotherapy for aqueous seeding in retinoblastoma: long-term efficacy, safety and toxicity

Christina Stathopoulos,<sup>1</sup> Maja Beck-Popovic,<sup>2</sup> Alexandre P Moulin,<sup>1</sup> Francis L Munier <sup>1</sup>

<sup>1</sup>Jules-Gonin Eye Hospital, Fondation Asile des Aveugles, University of Lausanne, Lausanne, Switzerland  
<sup>2</sup>Paediatric Haemato-Oncology Unit, Department of Paediatrics, CHUV, Lausanne, Switzerland

**Correspondence to**

Professor Francis L Munier, Ophthalmology, Jules Gonin Eye Hospital, 1000 Lausanne 7, Vaud, Switzerland; Francis.Munier@fa2.ch

Received 29 August 2022  
Accepted 25 October 2022  
Published Online First 15 November 2022

**ABSTRACT**

**Aims** To report long-term results of intracameral chemotherapy (ICC) for aqueous seeding (AS) in retinoblastoma.

**Methods** Retrospective study including 20 patients with primary (n=4) or secondary non-iatrogenic (n=16) AS treated with ICC according to a previously described technique between 2011 and 2020 with at least 1-year follow-up.

**Results** AS control was initially achieved in all cases with a mean 5 injections of melphalan (n=13) or topotecan (n=7). Three eyes had an isolated AS relapse at a mean interval of 8 months after the first ICC course, which regressed with a second course of intracameral melphalan. Concomitant intercalary process seed implantation was treated with additional brachytherapy if sectorial (n=3) or proton therapy if annular (n=1). Other therapies including systemic, intra-arterial chemotherapy and/or focal treatments were given in 15 eyes to treat concomitant tumour sites. Eye preservation was achieved in 85% of the eyes (n=17/20) at a mean event-free follow-up of 45 months for aqueous disease, and 40 months for any other intraocular tumour activity. Three cases were enucleated due to refractory non-aqueous disease. All patients are alive without metastasis (mean follow-up of 48 months after first ICC). ICC-related intraocular toxicity included iris atrophy (n=5), cataract (n=4), posterior synechiae (n=2) and iris heterochromia (n=1). No patient suffered irreversible vision loss. Useful to normal vision was found in 82% of the cases (n=14/17).

**Conclusion** ICC appears to be safe and efficient for AS without irreversible vision-threatening adverse effects. More data are needed to determine any superiority in efficiency/toxicity of topotecan versus melphalan.

**INTRODUCTION**

Among the different seeding compartments of retinoblastoma (rb) at diagnosis, aqueous seeding (AS) is considered a rare finding compared with its subretinal and vitreous counterparts, characterising exophytic and endophytic growth patterns, respectively.<sup>1</sup> The only exception to this rule concerns diffuse infiltrating and anterior diffuse rb, two rare subtypes of the disease where AS is a typical feature, present in 65%–100% of the cases.<sup>2,3</sup>

Primary AS, that is, seen at presentation, is observed clinically in 1% of the rb at diagnosis<sup>4</sup>

**WHAT IS ALREADY KNOWN ON THIS TOPIC**

⇒ There is only limited information to date on the treatment of aqueous seeding (AS) in retinoblastoma, mainly based on few case reports/series with short follow-up.

**WHAT THIS STUDY ADDS**

⇒ This study is the largest case series of conservatively treated retinoblastoma cases with AS, reporting for the first time long-term efficacy, safety and intraocular toxicity of intracameral chemotherapy (ICC).

**HOW THIS STUDY MIGHT AFFECT RESEARCH, PRACTICE OR POLICY**

⇒ By demonstrating long-term efficacy (85% eye salvage), safety (100% survival without metastasis) and absence of irreversible vision-threatening complications, ICC appears to valuably enrich the armamentarium against retinoblastoma in the case of AS.

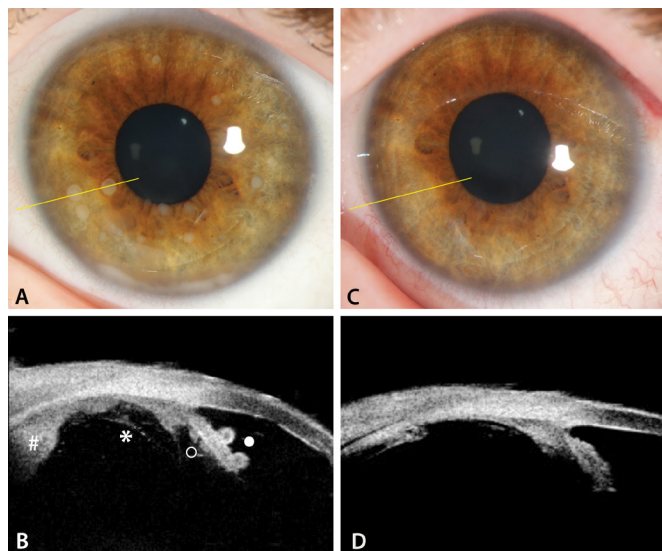
and histopathologically in 4%–9% of primarily enucleated eyes.<sup>5,6</sup> According to the International Intraocular Classification of Retinoblastoma (IIRC),<sup>7</sup> primary AS is a feature of group E rb, treated with upfront enucleation. Secondary AS, that is, appearing during the course of conservative management, has been reported to be the cause of treatment failure and subsequent secondary enucleation in 1% of eyes after external beam radiotherapy<sup>4</sup> and 6% of those treated with neoadjuvant systemic chemotherapy.<sup>8</sup> In the era of targeted chemotherapy using intra-arterial and intravitreal injections, AS is now found in 23%–67% of the secondary enucleated eyes,<sup>9,10</sup> thus appearing to be a more frequent reason for treatment failure doomed to enucleation for lack of effective and safe treatment.

Intracameral chemotherapy (ICC) was given for the first time in 2011 to successfully treat AS in a patient with diffuse anterior rb.<sup>11</sup> In 2018, we reported a series of 12 cases treated by ICC, among which 5 had AS post iatrogenic disrupted anterior hyaloid and 7 spontaneous AS, that achieved a globe preservation rate of 25% and 71%, respectively.<sup>12</sup>

Check for updates

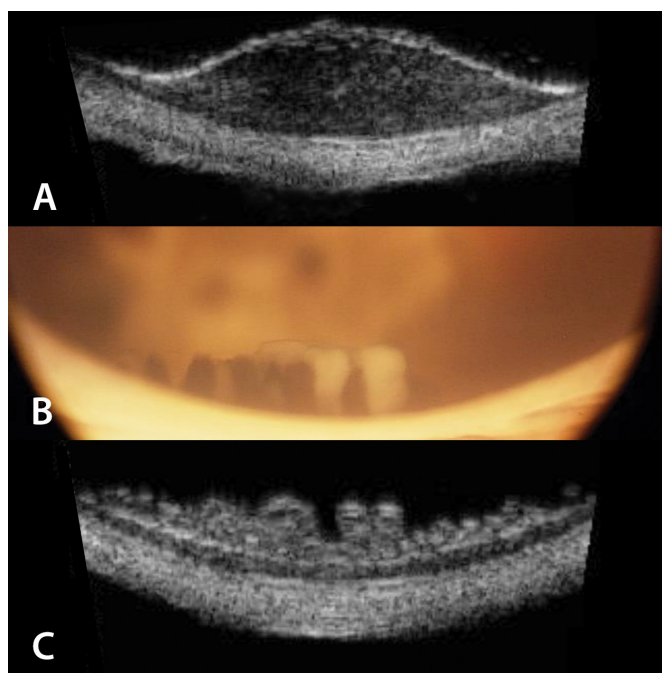
© Author(s) (or their employer(s)) 2024. Re-use permitted under CC BY-NC. No commercial re-use. See rights and permissions. Published by BMJ.

**To cite:** Stathopoulos C, Beck-Popovic M, Moulin AP, et al. *Br J Ophthalmol* 2024;**108**:124–130.



**Figure 1** Biomicroscopic view of anterior chamber (case #18) at presentation (A) and at treatment completion (C) and corresponding ultrasound biomicroscopy longitudinal section (B,D), showing peripheral retinal tumour (#) expanding on the surface of pars plana in the Petit's canal and peeling off the insertion of anterior hyaloid (\*), as well as aqueous seeds anchored on posterior (°) and anterior (•) surface of the iris.

To date, all these patients remain alive without metastasis. In the present study we report our 10-year experience with ICC in a cohort of 20 cases with spontaneous AS, including an update on the 7 previously published cases, reporting AS control, treatment-related intraocular toxicity, long-term survival, metastasis and globe salvage rate.



**Figure 2** Ultrasound biomicroscopy (UBM) transverse pars plana section (A) of sectorial intraciliary invasion (case #8); biomicroscopic view (B) and UBM transverse pars plicata section (C) of intercalary process seed implantation in the posterior chamber (case #5).

## METHODS

This is a retrospective review of all consecutive patients with primary or secondary non-iatrogenic AS treated by ICC in Lausanne between December 2011 and December 2020 with a minimum of 1-year follow-up. Cases with secondary AS seen after previous intraocular surgery such as cataract surgery with posterior capsulotomy or pars plana vitrectomy were considered iatrogenic cases of aqueous humour invasion and were not included.

All included patients were followed regularly under general anaesthesia. For all cases, treatment of the aqueous invasion consisted of bicameral injections of melphalan (concentration 6–30 µg/mL) or topotecan (concentration 15–30 µg/mL) administered every 5–15 days by the same operator (FLM) according to the previously described safety-enhanced aqueous replacement technique performed under pharmacologic suppression of aqueous secretion (acetazolamide 5 mg/kg),<sup>13</sup> combined with intravitreal injections of the same drug (injected dose of 20–30 µg) to prevent back contamination of a tumour-free vitreous across the anterior hyaloid or to sterilise the diseased vitreous. Drug concentration was chosen by discretion of the operator according to the AS burden or treatment response, as monitored by ultrasound biomicroscopy (UBM) of the posterior chamber and cytopathology of the aqueous humour sampling. Injections were stopped once two negative cytopathology analyses were obtained and/or complete AS regression on UBM in the posterior chamber. Additional therapies were performed as necessary to treat the seeding source or any other active tumour.

Patient data included gender, age at the time of rb diagnosis, classification of the disease according to the IIRC,<sup>7</sup> interval between diagnosis and AS invasion, as well as any treatment given prior aqueous humour invasion diagnosis. At date of the first ICC, AS was classified using a portable slit lamp as class 1 for dust, class 2 for spheres and class 3 for cloud according to a previous classification of vitreous seeding.<sup>14</sup> Thirty five MHz (OTIScan 2000; Ophthalmic Technologies, North York, Ontario, Canada) or 50 MHz (ABSolu, Quantel Medical, Couron d'Auvergne, France) UBM was performed in each case to determine (1) the extent of the posterior chamber invasion in sectorial degrees, (2) the presence or not of an intercalary process seed implantation, as well as (3) any concomitant anterior uveal involvement (ciliary body and/or iris).

Intracameral treatment data included injected drug type, drug concentration and number of intracameral injections given. Additional treatments as well as ICC-related immediate and late intraocular complications were noted. Treatments started at the time of, or given within 2 months of, a series of ICC to treat other intraocular active tumour sites (retinal/subretinal/intravitreal and/or anterior uveal disease) were considered concomitant to ICC treatments. Treatments given for relapsing rb without aqueous humour involvement initiated more than 2 months following the last ICC were considered non-concomitant treatments. Amblyopia treatment was systematically performed when indicated and best-corrected visual acuity assessed by linear Snellen acuity, Teller tables or Cardiff cards according to age was measured at last visit and reported according to the foveal status on optic coherence tomography (OCT) (Biotigen, Durham, North Carolina, USA or SPECTRALIS with the Flex Module, Heidelberg Engineering, Heidelberg, Germany). The fovea was considered intact if there were no microanatomical abnormalities on OCT, damaged if the fovea was present but altered on OCT and absent if no fovea was visible on OCT.

**Table 1** Characteristics of patients at first intracameral chemotherapy (ICC): demographics, previous treatments, clinical and cytological features

Patient #	Sex	Age at Dx RB (months)	Age at Dx AS (months)	Laterality	IIRC group	AS type	Previous treatments			Aqueous seeding (AS) features			Concomitant active tumour						
							IVC	IAC	IVIC	BCT	Classification 1=dust 2=spheres 3=cloud	Posterior chamber involvement Angular involvement in degrees	Interciliary involvement	Anterior chamber cytology	Anterior uvea invasion	Vitreous seeding	Retinal tumour	Subretinal seeding	
1	F	132	132	U	E <sup>1</sup>	P	0	0	0	0	0	2	360	-	Malignant	-	-	+	-
2	M	6	23	B*	D	S	5	0	0	0	0	1	30	+	Atypical	Ciliary body	-	-	+
3	M	57	60	U	D	S	3	0	0	0	0	2	60	-	Negative	-	+	-	-
4	M	6	14	U	E	S	1	3	0	0	0	2	360	-	Malignant	-	-	-	-
5	M	3	76	B*	B	S	25	0	1	1	1	1	45	+	Malignant	-	+	+	-
6	M	3	101	B*	D	S	26	0	2	2	2	2	30	+	Malignant	-	+	+	-
7	F	60	73	U	D	S	6	0	0	0	0	1	30	-	Malignant	-	+	+	-
8	M	4	26	B*	B	S	8	0	2	1	1	3	360	-	Malignant	Iris+ciliary body	-	-	-
9	M	0.1	259	B	B	S	13	6	8	1	3	360	360	+	Malignant	-	+	-	-
10	M	137	137	B*	E <sup>2</sup>	P	0	0	0	0	0	2	105	-	Malignant	-	+	+	-
11	M	115	115	U	E <sup>1</sup>	P	0	0	0	0	0	3	360	-	Malignant	-	+	+	-
12	M	12	50	B	D	S	4	2	0	2	2	2	15	-	Negative	-	-	+	-
13	M	23	28	U	E	S	5	0	2	1	1	1	15	-	Negative	-	+	-	+
14	F	161	161	U	E	P	0	0	0	0	0	2	360	-	Malignant	-	+	+	+
15	M	88	116	U	D	S	0	3	3	0	0	UBM only	90	-	Malignant	-	+	+	-
16	F	42	55	U	C	S	5	3	1	0	0	UBM only	10	-	Negative	-	+	+	+
17	M	53	85	U	D	S	1	3	1	5	0	UBM only	30	-	Negative	-	+	-	+
18	M	3	80	B	B	S	5	0	4	0	0	2	135	-	Malignant	-	+	+	-
19	M	7	47	B	na	S	6	5	0	0	0	UBM only	10	-	No analysis	-	+	+	-
20	M	2	56	B	na	S	6	6	5	1	1	2	45	-	Malignant	-	-	-	-

IIRC (Linn Murphree<sup>7</sup> 2005).

\* Only remaining eye.

B, bilateral; BCT, brachytherapy; Dx, diagnosis; IAC, intra-arterial chemotherapy; IIRC, International Intraocular Retinoblastoma Classification; IVC, intravenous chemotherapy; IVIC, intravitreal chemotherapy; na, not available; p, primary; rb, retinoblastoma; S, secondary; U, unilateral; UBM, ultrasound biomicroscopy.

**Table 2** Treatments given during or post intracameral chemotherapy (ICC) for aqueous seeding (AS)

#	ICC				Other tumour treatments		Non-concomitant (=given >2 months after the last ICC)	Adjuvant IVC post secondary enucleation (SE)
	Injections number		Drug concentration (µg/mL)		Concomitant (=given at the same time as ICC)			
	First AS	Relapsing AS	First AS	Relapsing AS	First AS	Relapsing AS		
1	M 7	M 6	3×6; 2×8; 2×10	6×15	IVC (4×), IAC M (2×), IVIC M (6×)	IVIC M (4)	–	–
2	M 5	–	5×15	0	IVIC M (4×), BCT (1×)*	–	FT, BCT (1×)†	–
3	M 6	–	6×15	0	IVIC M (8×)	–	–	–
4	M 5	–	5×15	0	IVIC M (3×)	–	SE‡	IVC (4×)
5	M 8	–	8×15	0	IVIC M (7×), FT, BCT (1×)§	–	–	–
6	M 4	M 9	4×15	5×15; 4×20	IVIC M (3×)	IVIC M (2×), BCT (3×)§	FT, IVIC M (4×), IVIC T (3×)	–
7	M 3	–	3×15	0	IAC M (1×), IVIC M (4×)	–	SE¶	–
8	M 8	–	6×15; 2×20	0	IAC M (2×), IAC M+T (1×), IVIC M (1×), BCT (4×)‡‡	–	–	–
9	M 14	–	8×20; 6×30	0	IVIC M (10×), Protons**	–	–	–
10	T 5	–	5×15	0	IVC (3×) IVIC T (3×), FT	–	FT, IVIC M (1×)	–
11	T 5	–	5×20	0	IAC M (3×), IVIC T (5×)	–	IVIC M (2×), IAC M+T (3×), FT, BCT (1×)†	–
12	M 2	–	2×20	0	FT, IVIC M (3×)	–	BCT (1×)†	–
13	M 2	–	2×15	0	IAC M (1×), IAC M+T (2×), IVIC M (3×)	–	FT, IVIC M (2×)	–
14	T 5	M 7	5×20	1×20; 6×30	IAC M (3×), IVIC T (4×)	IVIC M (6×)	–	–
15	T 4	–	4×20	0	FT, IVIC T (4×)	–	–	–
16	M 2	–	1×15; 1×20	0	IVIC M (3×), FT, IAC M+T (1×)	–	–	–
17	M 2	–	2×20	0	IAC M+T (2×), IVIC M (4×)	–	FT, IAC M+T (4×), BCT (1×)†, IVIC M (4×), IVIC M+T (7×), SE††	IVC (4×)
18	T 4	–	4×20	0	IAC M (2×), IVIC T (5×)	–	FT, BCT (2×)†, IVIC M (2×)	–
19	T 2	–	2×20	0	FT, IVIC M (3×)	–	–	–
20	T 5	–	2×20; 3×30	0	IVIC T (3×)	–	–	–

\*Given for concomitant intraciliary relapse and intercalary process seed implantation.

†Given for retinal relapse.

‡Histopathological analysis showed sclerochoroidal and retrolaminar invasion with free surgical section.

§Given for sectorial intercalary process seed implantation.

¶Histopathological analysis showed active retinoblastoma with no risk factors for metastasis.

\*\*Given for 360° intercalary process seed implantation.

††Histopathological analysis showed retrolaminar optic nerve invasion with free surgical section.

‡‡Given for concomitant intraciliary relapse.

.BCT, brachytherapy with Ru-106; FT, focal treatment; IAC, intra-arterial chemotherapy; IVC, intravenous chemotherapy; IVIC, intravitreal chemotherapy; M, melphalan; T, topotecan.

## RESULTS

Of a total of 417 new rb cases treated in Lausanne during the study period, 20 eyes of 20 patients (10 with bilateral and 10 with unilateral rb) complied with the inclusion criteria. All included cases, except 1, were referred from abroad (11 different countries). Overall, Four had primary and 16 secondary spontaneous AS. Five cases were only remaining eyes. Among the cases with primary AS, two had anterior diffuse, one had diffuse infiltrating and one had mixed endophytic/exophytic late onset rb and all had concomitant retinal and vitreous disease but no anterior uveal involvement. All cases with secondary AS had undergone previous heavy treatments. At the time of AS involvement, 12 cases had concomitant retinal/subretinal and active vitreous disease, 3 had concomitant active vitreous seeding only, 2 had concomitant anterior uveal involvement with or without intercalary process seed implantation and 1 had concomitant retinal disease. Only two relapsed with isolated AS disease, of which one (case #20) had undergone three previous AS relapses over a 3.5-year period treated with a combination of intravenous, intra-arterial and intravitreal chemotherapies before being referred to Lausanne.

Mean interval between rb diagnosis and occurrence of secondary AS was 47 months (range: 3–259 months). Mean age at diagnosis of the first AS invasion was significantly older in the group with primary AS compared with the one with secondary AS (137 vs 70 months,  $p < 0.01$ ). AS was visible in the anterior

chamber by biomicroscopy (figure 1) in 16 cases as seeding class 3 ( $n=3$ ), 2 ( $n=9$ ) or 1 ( $n=4$ ) but remained infraclinical in 4 cases that had sectorial invasion of the Petit's canal. In those four cases, invasion was suspected by indentation of the extreme periphery on indirect ophthalmoscopy and confirmed by UBM. Extension of posterior chamber invasion was circumferential (360°) in 6 eyes and sectorial (10°–135°) in the other 14 eyes. Four eyes also presented intercalary process seed implantation (figure 2). Demographics, IIRC grouping, clinical, infraclinical and cytopathological features at the time of AS presentation, as well as treatments given prior to first ICC, are detailed in table 1.

AS was initially treated with intracameral melphalan in 13 eyes with a mean of 5 injections (range: 2–14) at a mean concentration of 17 µg/mL (range 6–30 µg/mL), and with intracameral topotecan in 7 eyes with a mean of 4 injections (range: 2–5) at a mean concentration of 20 µg/mL (range 15–30 µg/mL). Complete response of AS in both anterior and posterior chambers was achieved in all cases after a mean of 1 month following the first ICC (range: 1 week to 3 months). Three cases with AS±active vitreous disease (cases #4, 6 and 20) were treated with the ICC protocol only. Two cases with AS alone received in addition to the ICC protocol brachytherapy (case #5) or proton therapy (case #9) due to intercalary tumour involvement. Finally, 15 eyes had additional therapies to control other intraocular active sites including IAC for retinal/subretinal disease,



**Table 3** Clinical outcome and functional results at date last seen

#	Time to AS resolution (months)		Follow-up time (months)		Treatment-related complications		Other complications		Visual acuities and OCT-assessed foveal microanatomy			
	First event	Second event	From first ICC	Tumour-free aqueous humour from last ICC	Tumour-free globe from last rb treatment	Type	Management	Type	Management	Fovea	BCVA Distance	BCVA Near
1	3.0	1.8	119	111	111	CT	L+IOL	0	0	Intact	1.6	1.25
2	1.9	–	92	91	86	HI/IA/PS	0	0	0	Altered	0.10	0.10
3	1.2	–	66	65	64	IA/CT	L+IOL	RRD	SB/PPV+silicone	Intact	0.8	0.8
4	0.8	–	67	*	*	0	0	0	0	*		
5	2.0	–	71	68	68	CT	L+IOL	0	0	Altered	0.5	0.5
6	0.7	2.8	64	58	33	PS/IA/CT	L+IOL	0	0	Destroyed	0.06	0.10
7	0.7	–	54	*	*	0	0	0	0	*		
8	1.7	–	61	56	55	CT	L+IOL	0	0	Altered	0.5	0.5
9	3.2	–	48	45	45	CT	L+IOL	0	0	Altered	0.03	0.03
10	0.8	–	41	40	24	CT	L+IOL	RRD	Endolaser/PPV+silicone	Intact	1.0	1.0
11	1.4	–	39	38	28	CT	L+IOL	0	0	Intact	1.25	1.0
12	0.5	–	38	37	29	IA	0	0	0	Destroyed	0.06	0.06
13	1.0	–	33	32	24	CT	L+IOL	0	0	Altered	0.5	0.4
14	1.6	1.1	33	13	13	IA / CT	L+IOL	TRD	SB/retinotomy/PPV+silicone	Altered	0.13	0.13
15	1.0	–	27	26	26	0	0	0	0	Intact	0.8	1.0
16	0.2	–	27	27	26	0	0	0	0	Intact	0.8	0.8
17	0.2	–	29	*	*	CT	L+IOL	0	0	*		
18	0.7	–	25	25	2	0	0	0	0	Intact	1.0	1.0
19	0.2	–	19	18	18	0	0	0	0	Destroyed	No LP	
20	1.2	–	16	15	15	0	0	0	0	Intact	1.25	1.0

\*Enucleated eye.  
AS, aqueous seeding; BCVA, best-corrected visual acuity; CT, cataract; HI, heterochromia iridis; IA, iris atrophy; ICC, intracameral chemotherapy; L+IOL, lensectomy+intraocular lens; LP, light perception; OCT, optical coherence tomography; PPV, pars plana vitrectomy; PS, posterior synechia; rb, retinoblastoma; RRD, rhegmatogenous retinal detachment; SB, scleral buckle; TRD, tractional retinal detachment.

brachytherapy for anterior uvea involvement and/or focal treatment for isolated retinal/subretinal relapses. Treatment details given at the time of aqueous invasion and until the last follow-up are presented in table 2.

In total, AS relapse occurred in three cases (cases #1, 6 and 14). The recurrence was isolated in the aqueous humour in all of them and treated by a new course of ICC with melphalan, increasing both the number (mean: 7; range 6–9) and the injected drug concentration (mean 20 µg/mL, range: 15–30 µg/mL). In the first case (case #1), the first patient to be treated with ICC in Lausanne, the recurrence occurred 4 months after the last ICC and was attributed to our pilot protocol, consisting of melphalan injections performed in the anterior chamber but at a too low concentration (range: 6–10 µg/mL). Salvage ICC was successfully performed by increasing the dose to 15 µg/mL and by converting our protocol into a bicameral injection technique to ensure tumouricidal concentration in the posterior chamber. In the second patient (case #6), the relapse occurred 3 months after the last intracameral melphalan given for active AS with intercalary process seed implantation. Complete regression was achieved with no further occurrence after a second series of intracameral melphalan injections, combined with brachytherapy to sterilise the meridians of the intercalary process implantation, at an aqueous tumour-free follow-up of 58 months. The third case (case #14) presented a late aqueous humour recurrence 16 months after intracameral topotecan that regressed after a series of intracameral melphalan, with no further relapse observed at a 15 months follow-up.

Overall, eye preservation was achieved in 85% (n=17/20) of the treated eyes, including all 4 eyes with primary AS, at a mean event-free follow-up of 45 months (range: 13–111 months) for aqueous disease and 40 months (range: 2–111 months) for other intraocular rb treatments. Three cases underwent

secondary enucleation after a mean retention time of 9 months (range: 1–23 months), two for progressive resistant retinal and subretinal disease with concomitant neovascular glaucoma and one for optic nerve invasion detected by MRI with no active intraocular rb. Histopathologic analysis showed intermediate risk factors for metastasis in two of them, who subsequently received four courses of adjuvant IVC. All 20 patients are alive without extraocular relapse or metastasis at a mean follow-up of 48 months since the first AS diagnosis (range: 16–119 months).

Peroperative ICC-related complications included self-limited iris haemorrhage without hyphaema in 1 case (n=1/20, 5%). Cataract was the most frequently observed adverse effect, requiring surgery in 55% of the cases (n=11/20) after a mean latency of 19 months. Cataractogenesis could, however, be unequivocally attributed to ICC in only 4/11 cases due to concomitant confounding factors in the other eyes, including brachytherapy (n=5), proton therapy (n=1) and silicone oil (n=1). Other intraocular adverse effect consisted of iris atrophy in 25% (n=5/20), posterior synechiae in 10% (n=2/20) and iris heterochromia in 5% (n=1/20). In patients old enough to have endothelial cell count (n=7), two treated with intracameral melphalan and five with intracameral topotecan, no significant lowering of the endothelial cell density was observed over the period of the treatment initiation and the date last seen (data not shown). At last visit, best-corrected visual acuity after amblyopia treatment ranged from 0.8 to 1.6 in 47% of salvaged eyes (n=8/17) with an intact fovea, 0.03–0.5 in 35% (n=6/17) of those with a damaged fovea, and no light perception to 0.06 in 18% (n=3/17) of those with no fovea visible on OCT. None of the patients lost vision due to the treatment. Clinical and functional outcomes at date last seen are presented in table 3.

## DISCUSSION

Until recently, eyes with AS were not only associated with a poor prognosis for eye salvage but also considered to be at an increased risk for metastasis, and therefore assigned an absolute indication for enucleation<sup>7</sup> and adjuvant chemotherapy.<sup>15</sup> This consensus was challenged in 2015 by the emergence of a new chemotherapy delivery route directly to the aqueous,<sup>11</sup> and by an increasing body of evidence excluding AS as a risk factor for extraocular disease.<sup>16–18</sup> Little information is, however, available on the actual AS treatment and long-term prognosis of eyes treated with ICC.

In this paper, we report the use of ICC performed according to a safety-enhanced technique involving concomitant intravitreal chemotherapy<sup>13</sup> in the management of a total of 23 occurrences of AS in 20 rb eyes. Interestingly, 22% of the cases for which grouping was available (n=4/18) were classified IIRC group B, indicating that progression to aqueous disease seems not to be restricted to advanced rb at diagnosis. Overall, complete regression of aqueous disease could be achieved with one series of the ICC protocol in 85% of the eyes (n=17/20) and 2 series in 15% of them (n=3/20) with no irreversible vision-threatening adverse events at a mean event-free follow-up of 45 months for aqueous disease.

According to the published pharmacokinetic data, intravenous, intravitreal or periocular chemotherapies do not allow to reach a tumouricidal drug concentration into the aqueous,<sup>15–17</sup> and eyes with AS invasion were until recently commonly enucleated even following IAC.<sup>9–10</sup> In our series, the ICC protocol was efficient to treat both primary and secondary AS, as well as relapsing AS after previous ICC. Concomitant involvement of the interciliary processes by the tumour burden may correspond to a resistant reservoir of tumour cells secondary to chemotherapy dilution by the secreted aqueous humour, and such cases were treated with additional targeted irradiation (brachytherapy if sectorial or proton therapy if circular) to the involved pars plicata.

To our knowledge, AS control without the use of ICC has been reported in only four cases to date. One was treated with a combination of intravenous, intravitreal and periocular chemotherapy,<sup>18</sup> whereas the three others were anterior diffuse rb cases with no retinal or vitreous involvement treated with iodine brachytherapy delivered to the entire anterior segment (mean tumour-free follow-up of 36 months).<sup>19</sup> In the first case, it is not possible to determine which of the three routes of delivery and four injected drugs or combinations of drugs contributed to the result, nor to draw any conclusion on long-term efficacy considering the short follow-up of 7 months. On the other hand, all treated eyes with diffuse anterior rb treated with plaque brachytherapy needed cataract surgery within a mean interval of 16 months, while delayed potentially vision-threatening side effects such as ciliary body atrophy, glaucoma and/or corneal decompensation due to radioinduced limbal cells deficiency are to be feared. In our series, cataract was seen in half of the treated cases during their follow-up but with cataractogenesis being unequivocally attributed to the intracameral treatment in only four of them. Thus, the ICC protocol seems to be a preferable option to brachytherapy although both must be combined when interciliary processes are involved.

Ultrasound biomicroscopy is an important tool for the early detection of AS, accurate evaluation of the seeding extent and anterior uvea (especially for the detection of any intraciliary or interciliary process implantation), as well as for the monitoring of treatment response.<sup>20</sup> In our series, posterior chamber invasion was detected by UBM at the level of the Petit's canal in all

eyes, with biomicroscopically visible anterior chamber involvement in 16 of them. Cytopathology analysis of the aqueous humour should be done in every case to assess the presence of tumour or residual tumour, although it may be negative despite the clear presence of AS in the anterior chamber, as in 4 of the 16 eyes with biomicroscopically visible anterior chamber seeding. We hypothesised that this was due to the tumour burden in the posterior chamber, with the cytopathology-negative cases having a lower mean posterior chamber angular tumour involvement compared with the cytopathology-positive ones (30° vs 196°). Similarly, among the four infraclinical AS cases, that is, detected by UBM only, cytopathology analysis was positive in the only eye displaying a large tumour angular involvement of 90°, in contrast with the mean 16° of the three cytology-negative ones.

In our series, there were no deaths nor metastasis at a mean follow-up of 48 months since AS diagnosis. Concomitant systemic chemotherapy, the indication for which remains controversial to prevent metastasis in the case of anterior segment invasion, was given in only two patients, indirectly supporting the fact that AS alone, with or without anterior uvea invasion, should not be considered a risk factor for metastasis.<sup>21–23</sup> The first case (case #1) diagnosed in 2011, received 4 monthly courses of carboplatin/etoposide just before AS was removed from our list of metastatic risk factors. The second (case #10), received a single dose of carboplatin, ifosfamide and vincristine in his country of origin 2 weeks before presenting at Jules Gonin, after the parents refused enucleation of his only remaining eye.

This study carries the limitations inherent to its retrospective design and relatively small number of cases due to the rarity of the aqueous disease. Another limitation is the initially non-standardised protocol of injection using escalating doses of melphalan<sup>13</sup> and the fact that the choice between melphalan and topotecan was left to the operator's discretion without randomisation. Despite this, ICC appears to be safe with no extraocular disease after a mean follow-up of 4 years. Late-isolated relapses of AS can, however, occur and patients should undergo close follow-up for at least 2 years post-treatment completion. More data are needed to determine any superiority of intracameral melphalan versus topotecan when injected at the recommended concentration of 20–30 µg/mL. Secondary enucleation without delay remains recommended whenever regular follow-up with ultrasound biomicroscopy cannot be guaranteed or if extraocular disease is suspected.

**Acknowledgements** The authors would like to thank Susan Houghton for the data management and the editing of the manuscript

**Contributors** Conception and design: FLM and CS. Collection and assembly of data: FLM, CS and APM. Data analysis and interpretation: FLM, CS and APM. FLM is guarantor.

**Funding** The authors have not declared a specific grant for this research from any funding agency in the public, commercial or not-for-profit sectors.

**Competing interests** None declared.

**Patient consent for publication** Not applicable.

**Ethics approval** Institutional review board was obtained (authorisations #2016-00149 and #2018-00228) and the study complied with the tenets of the Declaration of Helsinki.

**Provenance and peer review** Not commissioned; externally peer reviewed.

**Data availability statement** All data relevant to the study are included in the article or uploaded as online supplemental information.

**Open access** This is an open access article distributed in accordance with the Creative Commons Attribution Non Commercial (CC BY-NC 4.0) license, which permits others to distribute, remix, adapt, build upon this work non-commercially, and license their derivative works on different terms, provided the original work is

properly cited, appropriate credit is given, any changes made indicated, and the use is non-commercial. See: <http://creativecommons.org/licenses/by-nc/4.0/>.

#### ORCID iD

Francis L Munier <http://orcid.org/0000-0002-8928-1050>

#### REFERENCES

- Munier FL. Classification and management of seeds in retinoblastoma. Ellsworth lecture Ghent August 24th 2013. *Ophthalmic Genet* 2014;35:193–207.
- Shields CL, Ghassemi F, Tuncer S, et al. Clinical spectrum of diffuse infiltrating retinoblastoma in 34 consecutive eyes. *Ophthalmology* 2008;115:2253–8.
- Jijelava KP, Grossniklaus HE. Diffuse anterior retinoblastoma: a review. *Saudi J Ophthalmol* 2013;27:135–9.
- Haik BG, Dunleavy SA, Cooke C, et al. Retinoblastoma with anterior chamber extension. *Ophthalmology* 1987;94:367–70.
- Jakati S, Kaliki S. Aqueous seeding in retinoblastoma: classification and clinicopathologic correlation. *Ophthalmol Retina* 2022;6:421–8.
- Kaliki S. Aqueous seeding in intraocular retinoblastoma: a review. *Clin Exp Ophthalmol* 2021;49:606–14.
- Linn Murphree A. Intraocular retinoblastoma: the case for a new group classification. *Ophthalmol Clin North Am* 2005;18:41–53.
- Shields CL, Ramasubramanian A, Thangappan A, et al. Chemoreduction for group E retinoblastoma: comparison of chemoreduction alone versus chemoreduction plus low-dose external radiotherapy in 76 eyes. *Ophthalmology* 2009;116:544–51.
- Kiratli H, Koç İrem, Varan A, et al. Intravitreal chemotherapy in the management of vitreous disease in retinoblastoma. *Eur J Ophthalmol* 2017;27:423–7.
- Pavlidou E, Burris C, Thaug C, et al. Anterior segment seeding in eyes with retinoblastoma failing to respond to intraophthalmic artery chemotherapy. *JAMA Ophthalmol* 2015;133:1455–8.
- Munier FL, Gaillard M-C, Decembrini S. Aqueous seeding: fall of the ultimate intraocular retinoblastoma sanctuary by a new in situ chemotherapy technique. *Investigative Ophthalmology & Visual Science* 2015;56:1663–63.
- Munier FL, Moulin A, Gaillard M-C, et al. Intracameral chemotherapy for globe salvage in retinoblastoma with secondary anterior chamber invasion. *Ophthalmology* 2018;125:615–7.
- Munier FL, Gaillard M-C, Decembrini S, et al. Intracameral chemotherapy (melphalan) for aqueous seeding in retinoblastoma: Bicameral injection technique and related toxicity in a pilot case study. *Ocul Oncol Pathol* 2017;3:149–55.
- Francis JH, Abramson DH, Gaillard M-C, et al. The classification of vitreous seeds in retinoblastoma and response to intravitreal melphalan. *Ophthalmology* 2015;122:1173–9.
- Mendelsohn ME, Abramson DH, Madden T, et al. Intraocular concentrations of chemotherapeutic agents after systemic or local administration. *Arch Ophthalmol* 1998;116:1209–12.
- Abramson DH, Frank CM, Chantada GL, et al. Intraocular carboplatin concentrations following intravenous administration for human intraocular retinoblastoma. *Ophthalmic Genet* 1999;20:31–6.
- Buitrago E, Höcht C, Chantada G, et al. Pharmacokinetic analysis of topotecan after intra-vitreous injection. Implications for retinoblastoma treatment. *Exp Eye Res* 2010;91:9–14.
- Rao R, Honavar SG, Mulay K, et al. Eye salvage in diffuse anterior retinoblastoma using systemic chemotherapy with periocular and intravitreal topotecan. *J Aapos* 2018;22:235–7.
- Shields CL, Lally SE, Manjandavida FP, et al. Diffuse anterior retinoblastoma with globe salvage and visual preservation in 3 consecutive cases. *Ophthalmology* 2016;123:378–84.
- Munier FL, Beck-Popovic M, Chantada GL, et al. Conservative management of retinoblastoma: Challenging orthodoxy without compromising the state of metastatic grace. "Alive, with good vision and no comorbidity". *Prog Retin Eye Res* 2019;73:100764.
- Baroni LV, Sampor C, Fandiño A, et al. Anterior segment invasion in retinoblastoma: is it a risk factor for extraocular relapse? *J Pediatr Hematol Oncol* 2014;36:e509–12.
- Sreelakshmi KV, Chandra A, Krishnakumar S, et al. Anterior chamber invasion in retinoblastoma: not an indication for adjuvant chemotherapy. *Invest Ophthalmol Vis Sci* 2017;58:4654–61.
- Tomar AS, Finger PT, Gallie B, et al. Metastatic death based on presenting features and treatment for advanced intraocular retinoblastoma: a multicenter registry-based study. *Ophthalmology* 2022;129:933–45.