



UNIL | Université de Lausanne

Unicentre

CH-1015 Lausanne

<http://serval.unil.ch>

Year : 2017

Study of tonotopic brain changes with functional MRI and FDG-PET in a patient with unilatéral objective cochlear tinnitus

Guinchard Anne-Claude

Guinchard Anne-Claude, 2017, Study of tonotopic brain changes with functional MRI and FDG-PET in a patient with unilatéral objective cochlear tinnitus

Originally published at : Thesis, University of Lausanne

Posted at the University of Lausanne Open Archive <http://serval.unil.ch>

Document URN : urn:nbn:ch:serval-BIB_BD00164BD3EB6

Droits d'auteur

L'Université de Lausanne attire expressément l'attention des utilisateurs sur le fait que tous les documents publiés dans l'Archive SERVAL sont protégés par le droit d'auteur, conformément à la loi fédérale sur le droit d'auteur et les droits voisins (LDA). A ce titre, il est indispensable d'obtenir le consentement préalable de l'auteur et/ou de l'éditeur avant toute utilisation d'une oeuvre ou d'une partie d'une oeuvre ne relevant pas d'une utilisation à des fins personnelles au sens de la LDA (art. 19, al. 1 lettre a). A défaut, tout contrevenant s'expose aux sanctions prévues par cette loi. Nous déclinons toute responsabilité en la matière.

Copyright

The University of Lausanne expressly draws the attention of users to the fact that all documents published in the SERVAL Archive are protected by copyright in accordance with federal law on copyright and similar rights (LDA). Accordingly it is indispensable to obtain prior consent from the author and/or publisher before any use of a work or part of a work for purposes other than personal use within the meaning of LDA (art. 19, para. 1 letter a). Failure to do so will expose offenders to the sanctions laid down by this law. We accept no liability in this respect.

UNIVERSITE DE LAUSANNE - FACULTE DE BIOLOGIE ET DE MEDECINE

Département des services de chirurgie et d'anesthésiologie
Service d'Otorhinolaryngologie et de chirurgie cervico-faciale

**Study of tonotopic brain changes with functional MRI and FDG-PET in a
patient with unilateral objective cochlear tinnitus**

THESE

préparée sous la direction du Docteur Raphaël Maire

et présentée à la Faculté de biologie et de médecine de
l'Université de Lausanne pour l'obtention du grade de

DOCTEUR EN MEDECINE

par

Anne-Claude GUINCHARD

Médecin diplômé de la Confédération Suisse
Originaire de l'Abbaye, Le Lieu (Vaud)

Lausanne

2017

UNIVERSITE DE LAUSANNE - FACULTE DE BIOLOGIE ET DE MEDECINE

Département des services de chirurgie et d'anesthésiologie
Service d'Otorhinolaryngologie et de chirurgie cervico-faciale

**Study of tonotopic brain changes with functional MRI and FDG-PET in a
patient with unilateral objective cochlear tinnitus**

THESE

préparée sous la direction du Docteur Raphaël Maire

et présentée à la Faculté de biologie et de médecine de
l'Université de Lausanne pour l'obtention du grade de

DOCTEUR EN MEDECINE

par

Anne-Claude GUINCHARD

Médecin diplômé de la Confédération Suisse
Originaire de l'Abbaye, Le Lieu (Vaud)

Lausanne

2017



UNIL | Université de Lausanne

Faculté de biologie
et de médecine

Ecole Doctorale
Doctorat en médecine

Imprimatur

Vu le rapport présenté par le jury d'examen, composé de

Directeur de thèse *Monsieur le Docteur **Raphael Maire***

Co-Directeur de thèse

Expert

**Vice-Directeur de
l'Ecole doctorale** *Monsieur le Professeur **John Prior***

la Commission MD de l'Ecole doctorale autorise l'impression de la thèse de

Madame Anne-Claude GUINCHARD

intitulée

***Study of tonotopic brain changes with functional MRI and FDG-
PET in a patient with unilateral objective cochlear tinnitus***

Lausanne, le 3 mars 2017

*pour Le Doyen
de la Faculté de Biologie et de Médecine*

*Monsieur le Professeur John Prior
Vice-Directeur de l'Ecole doctorale*

Rapport de synthèse

Study of tonotopic brain changes with functional MRI and FDG-PET in a patient with unilateral objective cochlear tinnitus

Etude des changements tonotopiques au niveau cérébral avec IRM fonctionnels et PET-CT chez un patient atteint d'un acouphène objectif cochléaire unilatéral

Nous avons étudié les changements possibles au niveau des voies auditives cérébrales, en particulier au niveau des aires auditives cérébrales chez un rare cas de patient avec un acouphène objectif d'origine cochléaire de haute intensité dans l'oreille gauche qui dure depuis plus de 10 ans, sans perte auditive associée.

Un acouphène objectif d'origine endo-cochléaire est dû à une anomalie des cellules ciliées externes ou de la membrane basilaire entraînant une activité spontanée des cellules ciliées externes de l'oreille interne. Cette activité peut être mesurée par des oto-émissions acoustiques spontanées (SOAEs). Les cas d'acouphènes objectifs de cette origine décrits dans la littérature sont très rares; 9 cas décrits depuis les années 1970.

Le patient a bénéficié d'un bilan ORL et par imagerie complet. L'acouphène cochléaire objectif a été mesuré par des oto-émissions acoustiques spontanées (SOAEs) et montrait une activité spontanée pathologique dans l'oreille gauche à 9689 Hz avec un pic de 57 dB, produisant un son audible pour le patient et pour son entourage.

Nous avons recherché une possible réorganisation au niveau du cortex auditif et du système limbique avec l'aide d'imagerie par IRM fonctionnelles (IRMf-3 Tesla et 7 Tesla) et par PET-CTscan chez ce patient et comparé les résultats à des sujets sains en nous basant sur des études animales et humaines trouvant une réorganisation et une plasticité cérébrale lors d'acouphènes subjectifs.

Nous avons réalisé trois expériences de neuro-imagerie avec ce patient. Une évaluation de la réponse du cerveau à la simulation sonore et à la fréquence de l'acouphène avec IRMf-3T, une évaluation en haute résolution de l'organisation tonotopique du cortex auditif primaire avec IRMf-7T, une évaluation de l'activité métabolique cérébrale avec un FDG-PET.

Les résultats de l'IRMf-3T ont montrés une activation bilatérale du gyrus de Heschl lors de comparaison entre une stimulation à la fréquence de l'acouphène versus des fréquences plus faibles. Cette observation est compatible avec une saturation de la réponse du cortex auditif mesurable à la fréquence de l'acouphène due à la stimulation corticale continue par cet acouphène. Aucune réorganisation n'a été observée au niveau du système limbique, contrairement à certains cas d'acouphènes subjectifs.

L'IRMf-7T a montré une organisation tonotopique du cortex auditif globale normale chez ce patient. La stimulation du cortex auditif a été effectuée par des fréquences dans un ordre croissant. Il a été démontré sur des cartographies antérieures l'importance de présenter des stimuli également dans le sens inverse, pour confirmer que les réponses ne dépendent pas uniquement de l'ordre des stimuli. Les futures expériences de cartographie tonotopique devraient idéalement appliquer les deux directions de stimuli.

En conclusion, l'imagerie fonctionnelle et métabolique chez notre patient atteint d'un acouphène objectif chronique cochléaire n'a pas montré de distorsion grossière dans l'organisation corticale auditive et/ou dans le système limbique, comme observé chez les patients atteints d'acouphènes chroniques subjectifs, malgré la présence d'un acouphène chronique de plus de 10 ans.

L'acouphène subjectif semble être maintenu par une réorganisation corticale due à une perte auditive neurosensorielle. Au contraire, l'acouphène cochléaire objectif est d'origine périphérique et, bien que des changements neuronaux plus fins puissent exister, les résultats de nos trois expériences suggèrent une résilience globale du système auditif central, malgré une exposition sonore pathologique à long terme.



Research Paper

Study of tonotopic brain changes with functional MRI and FDG-PET in a patient with unilateral objective cochlear tinnitus



A.-C. Guinchard^a, N. Ghazaleh^b, M. Saenz^{b,c}, E. Fornari^d, J.O. Prior^e, P. Maeder^d, S. Adib^e, R. Maire^{a,*}

^a Department of Otorhinolaryngology, Head and Neck Surgery, Lausanne University Hospital, Lausanne, Switzerland

^b Institute of Bioengineering, École Polytechnique Fédérale de Lausanne (EPFL), Lausanne, Switzerland

^c Department of Clinical Neurosciences, Lausanne University Hospital, Lausanne, Switzerland

^d Department of Radiology, Centre Imagerie Biomédicale, Lausanne University Hospital, Lausanne, Switzerland

^e Department of Nuclear Medicine and Molecular Imaging, Lausanne University Hospital, Lausanne, Switzerland

ARTICLE INFO

Article history:

Received 1 June 2015

Received in revised form

11 May 2016

Accepted 7 September 2016

Available online 20 September 2016

Keywords:

Objective tinnitus

Human neuroimaging

Auditory cortex

Tonotopy

ABSTRACT

We studied possible brain changes with functional MRI (fMRI) and fluorodeoxyglucose positron emission tomography (FDG-PET) in a patient with a rare, high-intensity “objective tinnitus” (high-level SOAEs) in the left ear of 10 years duration, with no associated hearing loss. This is the first case of objective cochlear tinnitus to be investigated with functional neuroimaging.

The objective cochlear tinnitus was measured by Spontaneous Otoacoustic Emissions (SOAE) equipment (frequency 9689 Hz, intensity 57 dB SPL) and is clearly audible to anyone standing near the patient. Functional modifications in primary auditory areas and other brain regions were evaluated using 3T and 7T fMRI and FDG-PET.

In the fMRI evaluations, a saturation of the auditory cortex at the tinnitus frequency was observed, but the global cortical tonotopic organization remained intact when compared to the results of fMRI of healthy subjects. The FDG-PET showed no evidence of an increase or decrease of activity in the auditory cortices or in the limbic system as compared to normal subjects.

In this patient with high-intensity objective cochlear tinnitus, fMRI and FDG-PET showed no significant brain reorganization in auditory areas and/or in the limbic system, as reported in the literature in patients with chronic subjective tinnitus.

© 2016 Elsevier B.V. All rights reserved.

1. Introduction

Tinnitus is characterized by the perception of auditory signals in the absence of any external sound source. It affects about 10–15% of the population (Rauschecker et al., 2010), and in 1–3% of adults it adversely affects quality of life. There are two types of tinnitus: objective and subjective. Subjective tinnitus is more common and

may contribute to depression, insomnia and anxiety. The pathophysiology of subjective tinnitus is still poorly understood, but is most often associated with sensorineural hearing loss of various origins. As a consequence of damage to the peripheral auditory system, reduced auditory input reaches the central auditory neurons within the affected frequency range, which in turn leads to compensatory changes in the central auditory system. Therefore, subjective tinnitus is a phantom perception of sound that may be due to aberrant plastic reorganization within the auditory centers of the brain. There is currently no standard treatment for the management of subjective tinnitus, however behavioral therapies are considered the most effective. Earlier studies of human brain imaging using fMRI in patients with subjective tinnitus have suggested reorganization in the auditory cortex (Rauschecker et al., 2010; Melcher et al., 2000; Lockwood et al., 1998; Plewnia et al., 2007; but see Langers et al., 2012). Furthermore, stress and emotion can modulate tinnitus with brain imaging studies showing

Abbreviations: BOLD, blood oxygenation level dependant; dB SPL, decibel sound pressure level; EPI, Echo Planar Imaging; FDG-PET, ¹⁸F-fluorodeoxyglucose positron emission tomography; Hz, Hertz; LYSO, lutetium-yttrium-orthosilicate; OHCs, Outer hair cells; OSEM, ordered-subset expectation maximization; PFL, paraflocculus of the cerebellum; SOAEs, Spontaneous otoacoustic emissions; SPM, Statistical parametric mapping; 3T fMRI, 3 T functional MRI; 7T fMRI, 7 T functional MRI

* Corresponding author.

E-mail address: raphael.maire@chuv.ch (R. Maire).

<http://dx.doi.org/10.1016/j.heares.2016.09.005>

0378-5955/© 2016 Elsevier B.V. All rights reserved.

functional and anatomical differences in the limbic system between tinnitus patients and controls (Rauschecker et al., 2010).

Objective tinnitus is much less common and corresponds to a physical noise produced in the body and is audible to others. The etiology is most often vascular and, more rarely, is related to other causes such as palatal myoclonus, myoclonus of the tensor tympani, tubal patency or cochlear damage. Objective tinnitus of cochlear origin is due to a highly localized anomaly of the basilar membrane at high frequencies with spontaneous activity of the outer hair cells (OHCs) and it can be measured by Spontaneous Otoacoustic Emissions (SOAEs). Some authors have described the correlation between tinnitus pitch and SOAEs frequency (Prasher et al., 2001; Roberts et al., 2010).

This article considers the case of a 30 year-old man who presented with a rare left ear objective cochlear tinnitus, of over 10 years duration, which is clearly audible to others standing near the patient as a continuous high-pitched tone. Using functional magnetic resonance imaging (fMRI) and ^{18}F -fluorodeoxyglucose positron emission tomography (FDG-PET), we investigated possible reorganization of the auditory cortex and limbic system in this patient, as compared to healthy control subjects. The results of three experiments (3T fMRI, 7T fMRI, and FDG-PET) showed no large-scale reorganization of auditory brain areas, revealing a case of overall resiliency to pathological sound exposure.

2. Materials and methods

2.1. Case report

The patient in this study was a 30-year-old male, in good general health, with no previous history of acoustic trauma, presenting with a left continuous objective tinnitus of over 10 years duration. The tinnitus was non-pulsatile and of high intensity and frequency. The patient was bothered by the symptom and looked for possible treatment. Validated French versions of the Subjective Tinnitus Severity Scale (STSS) (Meric et al., 1996), the Hospital Anxiety and Depression Scale (HADS) (Lepine et al., 1985), and the Tinnitus Handicap Inventory (THI) (Ghulyan-Bédikian et al., 2010), were used to evaluate the impact of the tinnitus. On the STSS, the patient's score was 8/16 indicating a moderate tinnitus discomfort. On the HADS, the global score was 23/42 revealing moderate anxiety (14/21) and slight depression (9/21) symptoms. The THI score was 74 points indicating a severe handicap (severe is more than 58 points). Finally, using a Visual Analogic Scale (VAS), the patient evaluated at 9/10 the intensity and suffering of his tinnitus.

The otoscopy showed normal tympanic membranes bilaterally. Weber's test was central and Rinne's test was positive on both sides. CT-scan of the temporal bone followed by a cerebral and angio-MRI failed to reveal any abnormality.

Otherwise, the patient underwent a complete neurovestibular evaluation including caloric testing, video-head impulse test and videonystagmography, which were normal.

2.2. Audiological assessment

2.2.1. Audiometry and impedancemetry

Pure tone audiograms were normal on both sides at all frequencies, except for a rapid drop on the left side of up to 50 dB at 8 kHz, probably due to the tinnitus interfering with hearing thresholds (Fig. 1).

Impedancemetry (objective test of middle-ear function evaluating the mobility of the tympanic membrane and ossicular chain) was normal (type A) on both sides.

2.2.2. Otoacoustic emissions recording

Otoacoustic emissions are produced by the outer hair cells activity in the cochlea, either spontaneously (Spontaneous Otoacoustic Emissions – SOAEs) or in response to an acoustic stimulus (Transitory Evoked Otoacoustic Emissions – TEOAEs) and can be recorded with an intra-auricular probe. To measure the otoacoustic emissions, we used the Madsen Celesta 503 device, Madsen Celesta logiciel, NOHA system 3.6, GN Otometrics. SOAEs were recorded bilaterally from 125 to 10,000 Hz and TEOAEs from 1000 to 4000 Hz. In the right ear, physiologic SOAEs were present with small peaks of 8 dB SPL recorded at 5200 Hz and 7500 Hz. In the left ear, pathological SOAEs were present with a highly abnormal significant peak of 57 dB SPL at 9689 Hz, producing an audible sound (Fig. 1).

2.2.3. Functional neuroimaging

To test for possible brain reorganization, we performed three neuroimaging experiments with the patient: (1) whole-brain assessment of response to sound stimulation at the tinnitus frequency with 3T-fMRI, (2) high-resolution assessment of the tonotopic organization of the primary auditory cortex with 7T fMRI, (3) evaluation of whole-brain metabolic activity with FDG-PET.

2.3. 3 T fMRI

We looked for changes in the activity in the auditory cortex bilaterally and in the limbic system by comparing sound stimulation at the SOAEs frequency with rest and with stimulation two octaves lower in a silent event-related design protocol (for details see Maeder et al., 2001).

2.3.1. Scanning methods and analysis

The MRI protocol was performed on a Siemens 3T Tim Trio scanner and included a sagittal T1-weighted gradient-echo sequence (MPRAGE, 160 contiguous slices, 1 mm isotropic voxel, TR = 2300 ms, TE = 2.98 ms, FoV = 256 mm) and the fMRI acquisition. Functional scans were acquired with an EPI sequence (TR = 1500 ms, TE = 30 ms, flip angle = 90°, FoV = 256 mm). The 28 axial slices (matrix size 128*128 with 4 mm slice thickness) were aligned with the anterior commissure-posterior commissure line. During the experiment, we collected 20 vol for each condition. MRI data were pre-processed and analyzed using Statistical Parametric Mapping (SPM8, Wellcome Department of Imaging Neuroscience, London, England; www.fil.ion.ucl.ac.uk/spm/software/spm8/). Functional images were corrected for motion along the experiment by means of rigid-body transformation and then co-registered to the high-resolution T1w acquisition. The anatomical images were then normalized to the MNI T1 template and the normalization parameters were applied to the functional images, which were finally smoothed with a 6-mm Gaussian kernel. All the pre-processing steps mentioned minimized the non task-related variability. Single-subject statistics were performed according to the General Linear Model and contrasts of interest were thresholded for peak height at $p = 0.001$ (uncorrected), with an extent threshold (k) of 50 voxels.

2.3.2. Sound stimulation methods

During the active condition, the patient received binaural stimulation (on/off) for 5 s followed by EPI acquisition (silent event-related paradigm, Hall, et al., 1999; Maeder et al., 2001) every 15 s. The 5 s stimulation included 16 pulsed sounds (pure tone bursts of 150 ms, the amplitude multiplied with half sine-wave function) either at the SOAEs frequency (9689 Hz, 90 dB SPL) or two octaves below (2422 Hz, 75 dB SPL, for a perception of similar loudness to the SOAEs frequency). The tone stimuli were sampled at 44.1 kHz

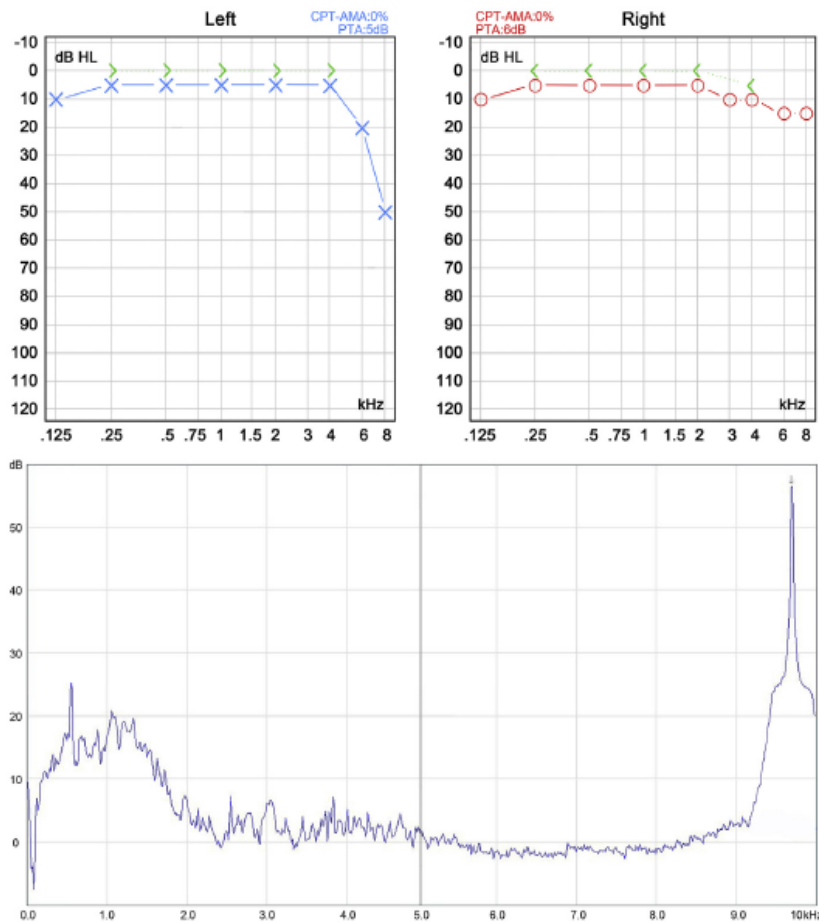


Fig. 1. Pure tone audiogram: Normal hearing on both sides except for a rapid fall in the very high frequency range on the left ear up to 50 dB at 8 kHz (Masking by the high-level SOAE is a probable explanation). Spontaneous otoacoustic emissions (SOAEs): left ear shows a pathological peak of 57 dB SPL at 9689 Hz (arrow) corresponding to the audible tinnitus.

and were delivered by MR-compatible earplug headphones (AudioSystem, Nordic NeuroLab Bergen, Norway). The 5 s stimulation was repeated 5 times for each condition and followed by five rest acquisitions; this cycle was repeated four times.

The stimulus was not masked by scanner noise. During fMRI, following the sparse sampling technique (Hall et al., 1999; Edmister et al., 1999), the stimulus was not presented during the scanner noise and the tinnitus could be heard normally. The use of stimulation earphones did not alter the perception of the tinnitus.

2.4. 7 T fMRI

High-resolution tonotopic maps of the primary auditory cortex were obtained with functional 7T MRI. Normally, neurons of primary auditory cortex are arranged in spatial gradients according to their preferred sound frequencies from low to high. Previous studies from our laboratory (Da Costa et al., 2011; Da Costa et al., 2013) have demonstrated the consistency with which we can measure cortical tonotopic maps with high-resolution 7T imaging in human subjects with normal hearing. The human primary auditory cortex is situated bilaterally on the transverse temporal plane centered on Heschl's gyrus. Moving from the posterior to the anterior end, we normally observe two complete tonotopic gradients ("high to low" followed by "low to high") that correspond to

the primary cortical regions A1 and R (Fig. 2). Both of these regions correspond to the primary core region and this organization is largely homologous to that observed in non-human primates (Saenz and Langers, 2014).

2.4.1. Scanning methods

Blood oxygenation level-dependent (BOLD) functional imaging was performed with an actively shielded 7T Siemens MAGNETOM scanner (Siemens Medical Solutions) located at the Centre d'Imagerie BioMedicale (CIBM) in Lausanne, Switzerland. fMRI data were acquired using an eight-channel head volume rf-coil (RAPID Biomedical) and an EPI pulse sequence with sinusoidal readout (1.5 × 1.5 mm in-plane resolution, slice thickness = 1.5 mm, TR = 2000 ms, TE = 25 ms, flip angle = 47°, slice gap = 0.07 mm, matrix size = 148 × 148, field of view 222 × 222, 30 oblique slices covering the superior temporal plane. The first three EPI images of each BOLD sequence were discarded).

BrainVoyager QX software v2.3 was used for standard fMRI data analysis. The tonotopic maps follow the convoluted cortical surface and are most easily viewed on cortical surface renderings. Cortical surface meshes were generated for the patient based on his own high-resolution 3D anatomical brain scan (1 × 1 × 1 mm, MPR2AGE T1-weighted sequence).

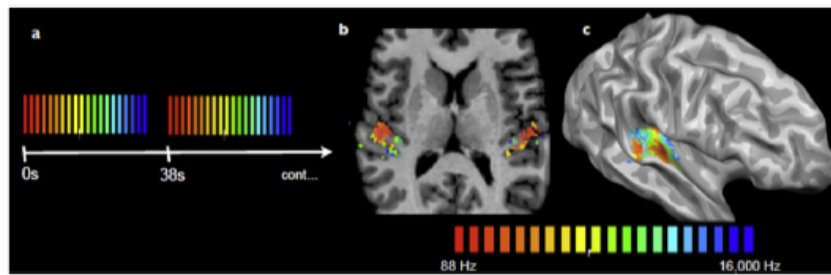


Fig. 2. Tonotopic mapping in auditory cortex with 7T fMRI. (a) Sound stimuli were pure tone bursts presented in cycled progressions from low to high frequencies: 88 to 16,000 Hz in half-octave steps. Each 32 s progression from low to high (red-to-blue color scale) was followed by a 4 s stimulus pause. Sound stimuli were designed to induce a traveling wave of response across cortical tonotopic maps: fMRI responses peak sooner in map regions preferring low frequencies and progressively later in regions preferring higher frequencies. (b and c) Resulting color-coded frequency maps are projected onto the subject's cortical surface meshes, as shown here in a normal hearing control subject. Surfaces were minimally inflated to expose the auditory cortex on the temporal plane (adapted from Da Costa et al., 2011). (For interpretation of the references to colour in this figure legend, the reader is referred to the web version of this article.)

2.4.2. Sound stimulation methods

The tonotopic mapping stimulus follows a “phase-encoded” mapping paradigm. Also known as the “traveling wave” technique, this paradigm has been shown to be highly efficient for mapping visual retinotopy and auditory tonotopy (Engel et al., 1994; Sereno et al., 1995; Talavage et al., 2004; Engel, 2012). Briefly, the mapping stimulus is designed to generate a wave of response across the tonotopic maps of the cortex, peaking earliest at low frequency endpoints and progressively later in parts of the map preferring higher sound frequencies. Hence, the time-to-peak of the response (i.e. the response phase) reveals the preferred frequency of each responsive voxel.

The auditory stimuli were pure tones of 16 distinct frequencies presented in increasing order from low to high: 88, 125, 177, 250, 354, 500, 707, 1000, 1414, 2000, 2828, 4000, 5657, 8000, 11,314, and 16,000 Hz (half-octave steps). The transition from low to high frequencies occurred over 32 s (2 s presentation of each frequency) followed by a 4 s of silence. This 36 s period was cycled 15 times during a continuous 9 min scan run. The tone stimuli were generated with a sampling rate of 44.1 kHz and were delivered via MRI-compatible headphones (AudioSystem, Nordic NeuroLab). The sound intensity of each frequency was chosen between 82 and 97 dB SPL to equate perceived loudness according to standard equal-loudness curves (ISO226, 85 phon). To minimize exposure to scanner noise, the patient (and controls) wore earplugs during the experiment which reduced background noise by about 24 dB. This means that a significant amount of scanner noise remains, of which it is difficult to assess the impact. However, it is controlled for in the sense that the background noise is the same for both the patient and the control subjects. According to the patient's self-report, the tinnitus remained hearable during the scanning session. Subjects (the patient and 5 normal hearing control subjects) were instructed to keep eyes closed during scanning. Linear cross-correlation analysis was used to determine the temporal delay that best fit the measured fMRI response time course of each voxel and to assign a corresponding best frequency. Briefly, the measured fMRI time courses were correlated with model time courses of 16 different delays corresponding to each sound frequency, and frequency-preferences were assigned according to the corresponding delay of highest correlation value. Model time courses were constructed by convolution with a standard two gamma hemodynamic response function (HRF) assuming a 5 s time to response-peak in the BOLD response (Glover, 1999). Response amplitudes (in % fMRI signal change) were determined as the maximal signal change of voxels assigned to each sound frequency, as in Da Costa et al., 2015. Response amplitudes were compared

between the patient and controls.

2.5. FDG-PET

A fasting period of more than 6 h was respected by the patient before the PET study. The patient received an intravenous injection of 200 MBq of ^{18}F -FDG after resting comfortably in a quiet, dimmed room. He was instructed not to speak or move. The patient wore earplugs and phonic isolation headphones during the initial resting phase (20 min) before radiotracer injection and PET acquisition starting immediately after. A PET/CT scanner (Discovery-690 time-of-flight scanner, GE Healthcare, Milwaukee, WI) combining lutetium-yttrium-orthosilicate (LYSO) block detectors with a 64-slice CT scanner was used for image acquisition and 3D iterative reconstruction was performed using ordered-subset expectation maximization (OSEM) using a 256×256 pixels matrix, with a final image resolution of about 4–6 mm FWHM. The PET data was analyzed with the 3D-Stereotactic Surface Projections Neurostat Software (3D-SSP, Department of Radiology, University of Washington, Seattle, WA, USA, <http://128.208.140.75/~Download/>). A subsequent analysis compared to a database of 20 healthy persons of the same mean age using SPM8 with a p-value < 0.001, corrected for cluster size (Guedj et al., 2010).

3. Results

In the patient, we identified pathological SOAEs on the left ear with a significant peak of 57 dB SPL recorded at 9689 Hz. This highly abnormal spontaneous activity of OHCs generates a continuous tonal tinnitus at 57 dB SPL that is clearly audible to others standing near the patient.

First, we looked for brain reorganization in the auditory pathways and the limbic system with 3T fMRI. Results did not reveal any activation of primary auditory cortex when comparing stimulation at the SOAEs frequency with rest. There was no asymmetry of the response to the stimulus at the tinnitus frequency since no response at all could be obtained. The comparison of the lower frequency (two octaves lower, see Method for details) with the SOAEs frequency showed bilateral activation of the middle Heschl's gyrus with a slight predominance in the left hemisphere (Fig. 3). No activation in the limbic areas was observed.

Secondly, we tested using 7T fMRI for a change in the tonotopic maps of primary auditory cortex, with the hypothesis that a long-term noise at the same frequency could create a change in the auditory area. We observed that the tonotopic mapping results of the patient were in the normal range (Fig. 4a) based on qualitative

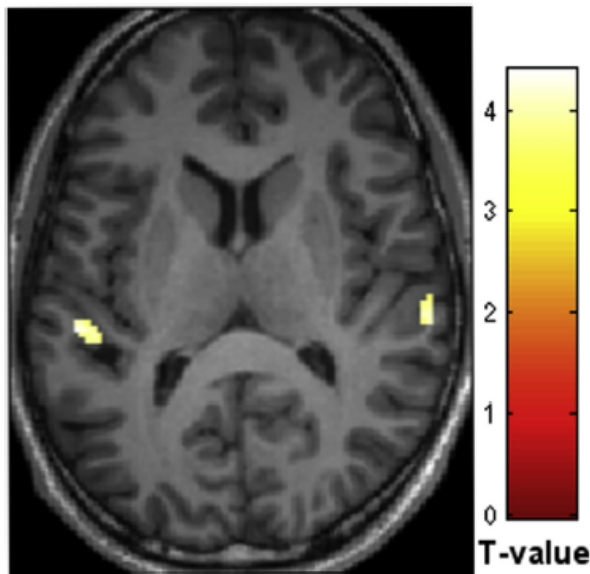


Fig. 3. 3T fMRI results. Image represents clusters more active during stimulation at 2422 Hz (two octaves lower than SOAE frequency) than at 9689 Hz (SOAE frequency). The slice is located at $z = 12$ mm in MNI space. Map is thresholded at $p < 0.001$, $k = 20$ voxels. Colorbar represents T-values.

comparison to 20 individual hemispheres of healthy young adults without tinnitus (Da Costa et al., 2011). In both left and right brain hemispheres of the patient, mappings of sound frequency preference (“high-to-low” followed by “low-to-high”) corresponding to primary auditory regions A1 and R appeared normal (see Da Costa

et al., 2011). These tonotopic maps appeared normal in terms of location (centered on Heschl’s gyrus of the temporal lobe of each hemisphere) and orientation (overall posterior-to-anterior). Fig. 4b displays the preferred frequency as a function of distance along the cortical surface in each hemisphere. Note the distinct “V-shape” indicative of the two continuous and gradual tonotopic transitions. We did not observe a gross overrepresentation of sound frequencies in any frequency range. The x,y,z Talairach coordinates of the patient’s estimated left and right map endpoints (left: [-39 -22 5], [-45 -25 3]; right: [40 -21 6], [46 -29 12]) were in the range of five normal-hearing control subjects (mean \pm sd; left: [-38.8 \pm 4.0–21.4 \pm 2.7 3.0 \pm 6.8], [-44.0 \pm 5.6–27.2 \pm 4.8 3.8 \pm 3.3]; right: [41.2 \pm 4.1–18.2 \pm 4.7 4.4 \pm 3.8], [49.0 \pm 4.7–28.2 \pm 6.2 9.2 \pm 4.1]). Fig. 5 shows response amplitudes to each sound frequency in the patient compared to the five normal-hearing control subjects. The response amplitudes of the patient were within the range of the control subjects and were not significantly different from controls at any frequency (t -tests, $p > 0.05$). Finally, we investigated for evidence of hypermetabolism in the brain with the FDG-PET. This examination revealed no abnormalities. Images were compared to a database of normal, age-matched control subjects using the 3D-Stereotactic surface projections software 3DSSP Neurostat, which showed no significant abnormalities. Furthermore, The PET data were subsequently compared to a database of 20 healthy persons of the same mean age using SPM8 and p -value < 0.001 , corrected for cluster size (Guedj et al., 2010). This analysis did not further identify any area of abnormally increased or decreased glucose metabolism.

4. Discussion

Spontaneous otoacoustic emissions (SOAEs) are thought to arise as a response to random perturbations in cochlear mechanisms due

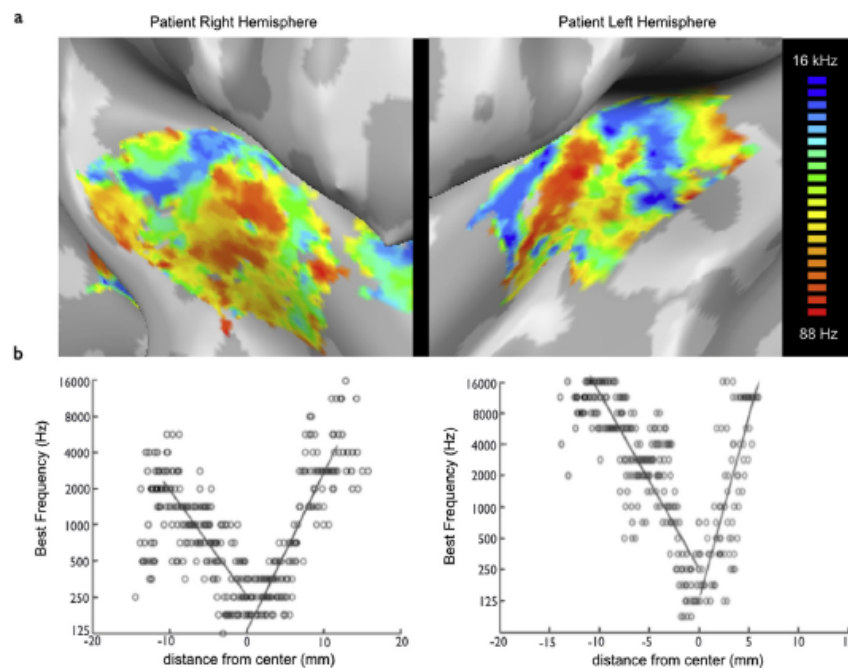


Fig. 4. (a) Tonotopic maps in the patient with objective tinnitus: tonotopic maps sound frequency preference (“high-to-low” followed by “low-to-high”) corresponding to primary auditory regions A1 and R were observed in each brain hemisphere. These tonotopic maps appeared normal in terms of location (centered on Heschl’s gyrus on the temporal plane of each hemisphere) and orientation (overall posterior-to-anterior), suggesting that the global tonotopic organization of the patient remains intact. (b) Plots of preferred frequency within a posterior-to-anterior strip across the surface Heschl’s gyrus in right and left hemispheres, respectively: the distinct “V-shape” shows two continuous and gradual tonotopic transitions in each hemisphere corresponding to regions A1 and R.

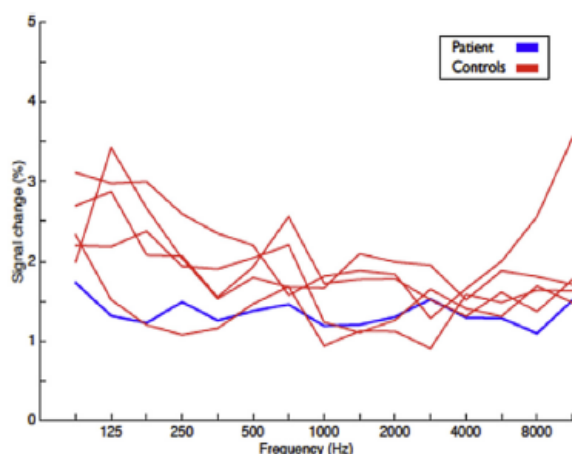


Fig. 5. Plot of response amplitudes (in % fMRI signal change) to each sound frequency in the patient compared to normal-hearing control subjects (no difference at any frequency, $p > 0.05$). Overall, the results suggest that the global tonotopic organization of the patient remains within the normal range.

to irregularities in the OHC arrangement or due to a highly localized anomaly of the basilar membrane at high frequencies (Prasher et al., 2001). Small peaks across the frequency spectrum in the cochlea (generally not exceeding 20 dB SPL) can be recorded, inconsistently, in normal hearing subjects. Very rarely and exceptionally, more severe SOAEs can be recorded as audible sounds classifiable as objective non-pulsatile tinnitus. Only nine cases of objective tinnitus measured by SOAE equipment have been previously described in the literature (Glanville et al., 1971; Huizing and Spoor, 1973; Mathys et al., 1991; Yamamoto et al., 1987), but the tinnitus frequency and loudness were lower than in our patient. In Glanville et al., there was a familial history of high frequency tinnitus and the authors suggested a genetic defect in the cochlea associated to a venous abnormalities at the base of the skull. The others studies described 6 people with high-intensity SOAEs measured in normally hearing ears and emission failed to synchronize to external click stimuli (TEOAEs). They hypothesized that high-intensity SOAEs are associated with damage to the cochlea. In these studies, the associated hearing loss observed in five patients was explained by a masking effect due to the high intensity SOAEs.

Here we studied a rare case of objective tinnitus associated with clearly audible SOAEs. Given the continuous tonal quality of our patient's objective tinnitus, we hypothesize that it is generated by activity of the outer hair cells, in contrast to myogenic or vascular origins which produce pulsatile, non-tonal sounds. In the cochlea, only outer hair cells are contractile and would appear to be capable of emitting pure tone sounds. To our knowledge, this is the first case report of objective tinnitus to be studied with neuroimaging. We considered the possibility of changes in auditory brain centers, particularly in the cortex and in the limbic system, based on the findings of previous studies of auditory plasticity and of subjective tinnitus in both humans and animal models.

Firstly, animal studies of auditory plasticity have shown that repeated exposure to a particular sound frequency can alter the tonotopic maps of auditory cortex, resulting in overrepresentation of that frequency (Recanzone et al., 1993). However, the map reorganization depended on pairing the sounds with an attentive task requiring the animal to focus on the frequency content (Recanzone et al., 1993; Polley et al., 2006). Tonotopic map alterations may also be possible following long-term passive sound exposure (Noreña et al., 2006). In our patient, the duration of sound exposure largely exceeds those studies and the specific attentional

state afforded to the sound is unknown.

Second, previous studies of subjective tinnitus in both animal models and humans report a number of associated changes in the auditory cortex. Subjective tinnitus is often associated with sensorineural hearing loss. Nerve deafferentation due to the destruction of hair cells induces changes in the central auditory pathways leading to the perception of a phantom tinnitus (Rauschecker et al., 1999). Usually, the pitch or the tinnitus corresponds to the hearing loss range (Roberts et al., 2010; Mühlau et al., 2006; Melcher et al., 2000, 2009). Animal models of subjective tinnitus consistently show elevated responses throughout the central auditory system including elevated spontaneous and stimulus driven activity, increased bursting and neural synchrony, as well as down-regulation of inhibition (Noreña and Eggermont, 2003; Mulders and Robertson, 2009; Seki and Eggermont, 2003). Others have reported tonotopic changes including expansion of lesion-edge frequency areas (Seki and Eggermont, 2003; Noreña and Eggermont, 2005) or more global distortion pervading the entire tonotopic map organization (Engineer et al., 2011; Yang et al., 2011). Earlier studies of human brain imaging with fMRI and FDG-PET have shown abnormal responses in central auditory brain regions in patients suffering from chronic subjective tinnitus (Rauschecker et al., 2010; Melcher et al., 2000; Lockwood et al., 1998; Plewnia et al., 2007) with some suggesting cortical tonotopic map distortion (Muhnickel et al., 1998; Wienbruch et al., 2006). However, in most studies of subjective tinnitus it is difficult to disentangle the effects of tinnitus from more general consequences of hearing loss. Notably, Langers et al., 2012 tested subjective tinnitus patients with only minimal hearing loss and, like us, reported a lack of macroscopic changes in the tonotopic maps.

Finally, neuroimaging studies have also described changes in the limbic-related brain areas in subjective tinnitus patients, including alterations in some parts of the limbic networks and significant grey matter decreases in the right inferior colliculus and in the left hippocampus, when compared to controls (Lockwood et al., 1998; Mühlau et al., 2006; Landgrebe et al., 2009; Schlee et al., 2009). Leaver et al., 2011, suggested that interactions between the limbic corticostriatal network and primary auditory cortex may be key to understanding the pathophysiology of chronic subjective tinnitus. This interaction may be an important gateway to centers mediating emotional control and memory. In addition, the limbic system may participate in the suppression of the tinnitus signal. If this "noise cancellation system" works properly, the tinnitus is transient (Rauschecker et al., 2010). If this mechanism fails, patients become aware of their tinnitus. Recently, functional imaging in rats with tinnitus showed evidence of elevated neural activity in the paraflocculus of the cerebellum (PFL), which was not observed in normal rats. This suggests that plastic changes in the PFL may also serve as a tinnitus generator (Bauer et al., 2013).

Based on these observations in animal models and in patients with subjective tinnitus, we investigated whether our objective tinnitus patient would have aberrant brain reorganization in the auditory cortex, reorganization in the tonotopy of the auditory cortex and/or activation in non-auditory areas (i.e. limbic and paralimbic areas), which would reflect an emotional reaction to tinnitus. Functional imaging and FDG-PET in this patient failed to reveal any major changes. The 3T fMRI experiment showed no activation in the primary auditory cortex when comparing stimulation at the SOAEs frequency with rest, but revealed bilateral activation of the Hechl's gyrus when comparing the SOAEs frequency with lower frequencies. This observation is compatible with a saturation of the measurable auditory cortex response at the tinnitus frequency due to continuous SOAE stimulation. Saturation effects have been previously described in fMRI responses in

auditory cortex (Talavage and Edmister, 2004). Except for this probable saturation effect in the primary auditory cortex at the SOAEs frequency, neither gross reorganization of the central auditory system nor changes in the limbic-related brain areas were observed.

Testing with 7T fMRI revealed overall normal tonotopic maps of primary auditory cortex in terms of location and orientation as shown in Fig. 4. While these findings do not exclude the possibility of finer scale reorganization, they do suggest that the global tonotopic organization of the patient's primary auditory cortex remained intact. It should be noted that a methodological limitation in our tonotopic mapping is that sound frequencies were presented only in increasing order. Previous applications of phase-encoded mapping emphasize the importance of presenting mapping stimuli also in the reverse direction, to confirm responses do not depend on stimulus order (Talavage et al., 2004). In particular, responses at map endpoints could be influenced by sound offsets and onsets, as opposed to strict frequency-dependence. In our previous tonotopic mapping study, both stimulus directions were applied and we observed that the two major gradients of primary auditory cortex were largely stable, irrespective of stimulus order (Da Costa et al., 2013, Fig. 3). Future tonotopic mapping experiments should ideally apply both stimulus directions each time.

The FDG-PET examination did not identify any abnormal metabolic activity in the auditory cortex and limbic areas, also suggested an absence of brain changes in this patient. A possible limitation of FDG-PET imaging is its intrinsic spatial resolution (4–6 mm), where low-intensity metabolic changes in small-sized brain structures could be missed due to partial volume effects. The difference in findings between our patient and those with subjective tinnitus may be due to the fact that objective cochlear tinnitus is peripheral in origin, producing a continuous neural excitation from the labyrinth, while subjective tinnitus might be maintained by cortical reorganization as a consequence of sensorineural hearing loss.

5. Conclusions

Functional and metabolic imaging in our patient with chronic cochlear objective tinnitus showed no gross distortions in auditory cortical organization and/or in limbic system responses, as observed in patients with chronic subjective tinnitus, despite the presence of chronic objective tinnitus of over 10 years duration. Subjective tinnitus seems to be maintained by cortical reorganization as a consequence of sensorineural hearing loss. On the contrary, objective cochlear tinnitus is peripheral in origin and, while finer-scale neural changes may exist, the results of our three experiments suggest an overall resilience of the central auditory system, despite long-term pathological sound exposure.

Conflicts of interest

No conflict of interest.

Financial disclosures

No financial disclosures.

Acknowledgments

This work was supported by Swiss National Science Foundation Grant 320030_143989 and by the Centre d'Imagerie BioMédicale (CIBM) of the Université de Lausanne, Université de Genève, Hôpitaux Universitaires de Genève, Lausanne University Hospital, École Polytechnique Fédérale de Lausanne, and the Leenaards and

Louis-Jeantet Foundations. We thank Sandra Da Costa and Wietske van der Zwaag for assistance with 7T fMRI data collection.

References

- Bauer, C.A., Kurt, W., Sybert, L.T., et al., 2013. The cerebellum as a novel tinnitus generator. *Hear Res.* 295, 130–139.
- Da Costa, S., Van der Zwaag, W., Marques, J., Saenz, M., et al., 2011. Human primary auditory cortex follows the sapes of Heschel's gyrus. *J. Neurosci.* 31 (40), 14067–14075.
- Da Costa, S., Van der Zwaag, W., Miller, L., Clarke, S., Saenz, M., 2013. Tuning in to sound: frequency-selective attentional filter in human primary auditory cortex. *J. Neurosci.* 33 (5), 1858–1863.
- Da Costa, S., Saenz, M., Clarke, S., Van der Zwaag, W., 2015. Tonotopic gradients in human primary auditory cortex: concurring evidence from high-resolution 7T and 3T fMRI. *Brain Topogr.* 28, 66–69.
- Edmister, W.B., Talavage, T.M., Ledden, P.J., Weisskoff, R.M., 1999. Improved auditory cortex imaging using clustered volume acquisition. *Hum. Brain Mapp.* 7, 89–97.
- Engel, S.A., Rumelhart, D.E., Wandell, B.A., Lee, A.T., Glover, G.H., Chichilnisky, E.J., Shadlen, M.N., 1994. fMRI of human visual cortex. *Nature* 369, 525.
- Engel, S.A., 2012. The development and use of phase-encoded functional MRI designs. *Neuroimage* 62, 373–382.
- Engineer, N.D., Riley, J.R., Seale, J.D., Vrana, W.A., Shetake, J.A., Sudanagunta, S.P., Borland, M.S., Kilgard, M.P., 2011. Reversing pathological neural activity using targeted plasticity. *Nature* 470, 101–106.
- Ghulyan-Bédikian, V., Paolino, M., Giorgetti-D'Esclercs, F., Paolino, F., 2010. Psychometric properties of french adaptation of tinnitus handicap inventory. *L'Encéphale* 36, 390–396.
- Glanville, J., Coles, R., Sullivan, B., 1971. A family with high-tonal objective tinnitus. *J. Laryngology Otolology.*
- Glover, G.H., 1999. Deconvolution of impulse response in event-related BOLD fMRI. *Neuroimage* 9, 416–429.
- Guedj, E., Aubert, S., McGonigal, A., Mundler, O., Bartolomei, F., 2010. Deja-vu in temporal lobe epilepsy: metabolic pattern of cortical involvement in patients with normal brain MRI. *Neuropsychologia* 48 (7), 2174–2181.
- Hall, D.A., Haggard, M.P., Akeroyd, M.A., Palmer, A.R., Summerfield, A.Q., Elliott, M.R., et al., 1999. "Sparse" temporal sampling in auditory fMRI. *Hum. Brain Mapp.* 7, 213–223.
- Huizing, E., Spoor, A., 1973. An Unusual Type of tinnitus. Production of a high tone by the ear. *Arch. Otolaryngol.* 98.
- Landgrebe, M., Langguth, B., Rosengarth, K., Braun, S., Koch, A., Kleinjung, T., May, A., de Ridder, D., Hajak, G., 2009. Structural brain changes in tinnitus: grey matter decrease in auditory and non-auditory brain areas. *Neuroimage* 46 (1), 213–218.
- Langers, D.R., de Klein, E., van Dijk, P., 2012. Tinnitus does not require macroscopic tonotopic map reorganization. *Front. Sys. Neurosci.* 6, 2.
- Leaver, A.M., Renier, L., Chevillet, M., et al., 2011. Dysregulation of limbic and auditory networks in tinnitus. *Neuron* 69 (1), 33–43.
- Lepine, J.P., Goldcheau, M., Brun, P., Lempérière, T., 1985. Evaluation de l'anxiété et de la dépression chez les patients hospitalisés dans un service de médecine interne. *Ann. Médico-psychologiques* 143 (2), 175–189.
- Lockwood, A.H., Salvi, R.J., Coad, M.L., et al., 1998. The functional neuroanatomy of tinnitus: evidence for limbic system links and neural plasticity. *Neurology* 50 (1), 114–120.
- Maeder, P.P., Meuli, R.A., Adriani, M., Bellmann, A., Fornari, E., Thiran, J.P., Pittet, A., Clarke, S., 2001. Distinct pathways involved in sound recognition and localization: a human fMRI study. *Neuroimage* 14 (4), 802–816.
- Mathys, A., Probst, R., De Min, N., Hauser, R., 1991. A child with an unusually high-level spontaneous otoacoustic emission. *Arch. Otolaryngol. Head. Neck Surg.* 117.
- Melcher, J., Sigalovsky, S., Guinan, J., et al., 2000. Lateralized tinnitus studied with functional magnetic resonance imaging: abnormal inferior Colliculus Activation. *AJP-JN Physiol.* 83 (2), 1058–1072.
- Melcher, J., Levine, R., Bergevin, C., et al., 2009. The auditory midbrain of people with tinnitus: abnormal sound-evoked activity revisited. *Hear Res.* 257, 63–74.
- Meric, C., Pham, E., Cery-Croze, S., 1996. Traduction et validation de l'échelle subjective de mesure de la sévérité de l'acouphène (Subjective Tinnitus Severity Scale, Halford, et al. 1991). *J. français d'oto-rhino-laryngologie* 45 (6), 409–412.
- Mühlau, M., Rauschecker, J., Oestreicher, E., et al., 2006. Structural brain changes in tinnitus. *Cereb. Cortex* 16, 1283–1288.
- Muhnicked, W., Elbert, T., Taub, E., Flor, H., 1998. Reorganization of auditory cortex in tinnitus. *PNAS* 95 (17), 10340–10343.
- Mulders, W.H., Robertson, D., 2009. Hyperactivity in the auditory midbrain after acoustic trauma: dependence on cochlear activity. *Neuroscience* 164 (2), 733–746.
- Noreña, A.J., Eggermont, J.J., 2003. Changes in spontaneous neural activity immediately after an acoustic trauma: implications for neural correlates of tinnitus. *Hear Res.* 183 (1–2), 137–153.
- Noreña, A.J., Eggermont, J.J., 2005. Enriched acoustic environment after noise trauma reduces hearing loss and prevents cortical map reorganization. *J. Neurosci.* 25, 699–705.
- Noreña, A.J., Gourévitch, B., Aizawa, N., Eggermont, J.J., 2006. Spectrally enhanced acoustic environment disrupts frequency representation in cat auditory cortex.

- Nat. Neurosci. 9 (7), 932–939.
- Plewania, C., Reimold, M., Najib, A., Brehm, B., Reischl, G., Plontke, S.K., Gerloff, C., 2007. Dose-dependent attenuation of auditory phantom perception (tinnitus) by PET-guided repetitive transcranial magnetic stimulation. *Hum. Brain Mapp.* 28 (3), 238–246.
- Polley, D.B., Steinberg, E.E., Merzenich, M.M., 2006. Perceptual learning directs auditory cortical map reorganization through top-down influences. *J. Neurosci.* 26 (18), 4970–4982.
- Prasher, D., Ceranic, B., Sulkowski, W., et al., 2001. Objective evidence for tinnitus from spontaneous emission variability. *Noise Health* 3, 61–73.
- Rauschecker, J., et al., 1999. Auditory cortical plasticity: a comparison with other sensory systems. *Trends Neurosci.* 22 (2), 74–80.
- Rauschecker, J., Leaver, A., Mühlan, M., 2010. Tuning out the noise: limbic-auditory interactions in tinnitus. *Neuron* 66 (6), 819–826.
- Recanzone, G.H., Schreiner, C.E., Merzenich, M.M., 1993. Plasticity in the frequency representation of primary auditory cortex following discrimination training in adult owl monkey. *J. Neurosci.* 13, 87–103.
- Roberts, L.E., Eggermont, J.J., Caspary, D.M., Shore, S.E., Melcher, J.R., Kaltenbach, J.A., 2010. Ringing ears: the neuroscience of tinnitus. *J. Neurosci.* 30 (45), 14972–14979.
- Saenz, M., Langers, D., 2014. Tonotopic mapping of human auditory cortex. *Hear. Res.* 307, 42–52.
- Schlee, W., Mueller, N., Hartmann, T., Keil, J., Lorenz, I., Weisz, N., 2009. Mapping cortical hubs in tinnitus. *BMC Biol.* 23, 7–8.
- Seki, S., Eggermont, J.J., 2003. Changes in spontaneous firing rate and neural synchrony in cat primary auditory cortex after localized tone-induced hearing loss. *Hear. Res.* 180 (1–2), 28–38.
- Sereno, M.I., Dale, A.M., Reppas, J.B., Kwong, K.K., Belliveau, J.W., Brady, T.J., Rosen, B.R., Tootell, R.B., 1995. Borders of multiple visual areas in humans revealed by functional magnetic resonance imaging. *Science* 268, 889–893.
- Talavage, T.M., Sereno, M.I., Melcher, J.R., Ledden, P.J., Rosen, B.R., Dale, A.M., 2004. Tonotopic organization in human auditory cortex revealed by progressions of frequency sensitivity. *J. Neurophysiol.* 91 (3), 1282–1296.
- Talavage, T.M., Edmister, W.B., 2004. Nonlinearity of fMRI responses in human auditory cortex. *Hum. Brain Mapp.* 22 (3), 216–228.
- Wienbruch, C., Paul, I., Weisz, N., Elbert, I., Roberts, L.E., 2006. Frequency organization of the 40-Hz auditory steady-state response in normal hearing and in tinnitus. *Neuroimage* 33 (1), 180–194.
- Yamamoto, E., Takagi, A., Hirono, Y., et al., 1987. A case of Spontaneous otoacoustic emission. *Arch. Otolaryngol. Head. Neck Surg.* 113.
- Yang, S., Weiner, B.D., Zhang, L.S., Cho, S.-J., Bao, S., 2011. Homeostatic plasticity drives tinnitus perception in an animal model. *PNAS* 108 (36), 14974–14979.