

Thomas Rossel, MD  
Anastasia Zekeridou, MD  
Francois Ochsner, MD  
Susanne Renaud, MD

*Neurol Neuroimmunol  
Neuroinflamm*  
2015;2:e103; doi: 10.1212/  
NXL.000000000000103

## AQUAPORIN-4-POSITIVE MYELITIS ASSOCIATED WITH SJÖGREN SYNDROME AND COLONIC ADENOCARCINOMA

### OPEN

Neuromyelitis optica (NMO) is an inflammatory disorder of the CNS with prominent involvement of the optic nerve and the spinal cord. An autoantibody against aquaporin-4 (AQP4), a water channel abundant on astrocytic foot processes, is the biomarker of the disease.<sup>1</sup>

The term neuromyelitis optica spectrum disorders (NMOSD) includes AQP4-IgG-positive syndromes that may only partially fulfill contemporary criteria for diagnosis of NMO.<sup>2</sup>

NMOSD are frequently associated with other autoimmune disorders and there are increasing reports of NMOSD in patients with cancer.<sup>3,4</sup>

**Case report.** We report a case of an 80-year-old nonsmoking Caucasian woman with a diagnosis of primary Sjögren syndrome 1.5 years prior to presentation (seropositive for SSA [Ro60 and Ro52 > 100 U/mL]; SSB-negative) confirmed by salivary gland biopsy and a positive Schirmer test. The diagnosis was established during workup for a sensory neuropathy; peroneal nerve biopsy showed involvement of both myelin and axons with perivascular T-lymphocytic infiltration (figure). She was treated with rituximab with an excellent clinical improvement.

The patient presented to the emergency department with sudden loss of strength in her left lower limb. The cerebral CT scan showed chronic microvascular leukoencephalopathy and she was admitted for suspicion of anterior cerebral artery stroke. The next day, symmetric paraparesis and bilateral hyperreflexia developed, with a T4 sensory level and loss of voluntary sphincter control. The spinal MRI showed a longitudinally extensive transverse myelitis with diffuse inhomogeneous gadolinium enhancement (figure). The CSF showed pleocytosis with monocytic predominance (387 cells/mm<sup>3</sup>), no atypical cells, slightly low glucose (40% of the serum), and elevated protein (2,989 mg/L) without any oligoclonal bands. CSF culture and viral PCR (herpes simplex virus 1 and 2) were negative. The cerebral MRI showed

chronic vascular leukoencephalopathy lesions. Serologies for Lyme disease, syphilis, HIV, and tuberculosis were negative. Detected non-organ-specific autoantibodies were SSA (Ro 52 > 240 U/mL and Ro 60 > 108 U/mL; normal < 5 U/mL). Neural autoantibodies were not detected (specifically acetylcholine receptor muscle and ganglionic type, voltage-gated calcium channel P/Q-type and N-type, GAD65, voltage-gated potassium channel, alpha-amino-3-hydroxy-5-methyl-4-isoxazolepropionic acid receptor,  $\gamma$ -aminobutyric acid B receptor, NMDA receptor, collapsin response-mediator protein 5, amphiphysin, anti-neuronal nuclear antibody 1 and 2, Purkinje cell cytoplasmic antibody type 1, and Ma1/Ma2) except for AQP4-IgG that was positive at 1:1,000 serum dilution by cell-binding assay (commercially available, M23 isoform). A serum specimen collected a year earlier that was retrospectively tested was also positive for AQP4-IgG at a lower dilution (1:500).

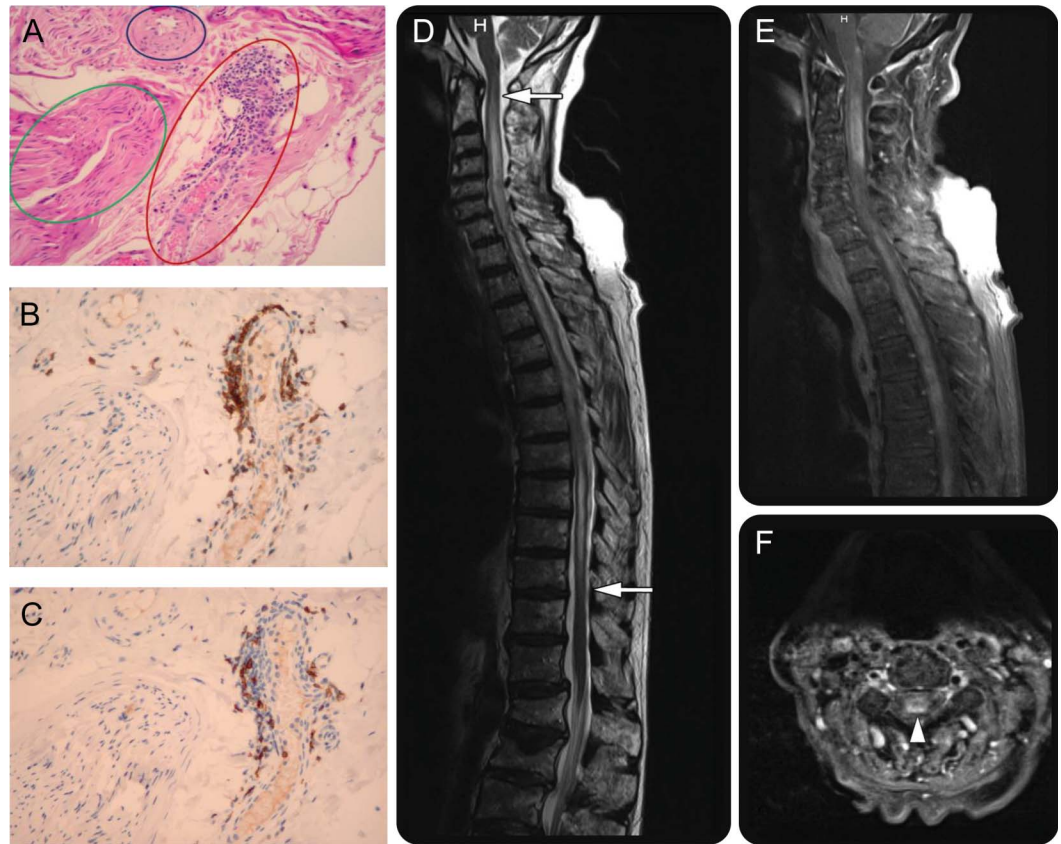
The patient was treated with high-dose methylprednisolone followed by oral tapering with prednisone. Plasma exchange was initiated because the patient developed tetraplegia; the patient's motor skills in lower extremities subsequently improved rapidly.

Due to the patient's age and history of diverticulitis in the previous year, total-body CT was performed in search of a tumor and revealed a perforated sigmoid mass.

The patient underwent exploratory laparotomy and left hemicolectomy. Histopathology confirmed a locally invasive colonic adenocarcinoma (pT4aN1aG2L1) without evidence of systemic metastasis. The patient died 2 days later from hemorrhagic shock. The family denied permission for autopsy.

**Discussion.** This is a case of an elderly woman presenting with AQP4-IgG-seropositive transverse myelitis in the context of primary Sjögren syndrome with sensory neuropathy and colonic adenocarcinoma.

In a cohort of 2,743 AQP4-IgG-seropositive patients with NMOSD, only 12.1% were older than 65 years.<sup>5</sup> However, the clinical presentation with longitudinally extensive transverse myelitis at disease onset, AQP4-IgG seropositivity, and severe



(A-C) Superficial peroneal nerve biopsy (hematoxylin & eosin stain). (A) Fibrous nerve fascicle without myelin reflecting myelino-axonal involvement (green circle) associated with slight vasculitic infiltrate (red circle) without arteriole lesion (blue circle). (B, C) Predominance of T-lymphocyte infiltration (CD3 staining, B) in comparison to B lymphocytes (CD20 staining, C). (D-F) Spinal MRI with predominantly central longitudinally transverse myelitis from C1 to T10 (T2-weighted image, D) with heterogeneous gadolinium enhancement (T1-weighted images, E and F).

neurologic impairment is similar to presentations reported in elderly women.<sup>5</sup>

AQP4 autoimmunity is strongly associated with Sjögren syndrome, representing the coexistence of 2 different disorders rather than NMOSD as a symptom of the systemic autoimmune disorder.<sup>3</sup>

This patient was positive for AQP4-IgG a year prior to the presentation of transverse myelitis, without any signs of an NMO-type clinical presentation. The existence of AQP4-IgG before NMO onset has been described in 4 patients with coexisting myasthenia gravis; higher AQP4-IgG levels were noticed at NMO clinical presentation, as in this patient.<sup>6</sup>

Cancer coexistence with NMOSD was 5% in large cohorts but up to 15% in cohorts with older patients. Breast, thymus, lung, nasopharynx, cervix, bladder, gastrointestinal tract, thyroid, pituitary gland, ovary, prostate, skin neoplasms, carcinoid tumors, and hematologic cancers are reported.<sup>4,7</sup> AQP4 is not expressed in colonic tissue, but to our knowledge colonic adenocarcinomas have not been

studied for AQP4 expression at the RNA or the protein level. As this patient's tumor was not tested for AQP4 expression, we can only speculate that the presence of AQP4-IgG a year prior to disease onset could be a marker of the underlying oncologic disease. A simple coexistence of the cancer and the NMOSD is also possible.

*From the Division of Neurology (T.R., A.Z., S.R.), Poutalès Hospital, Neuchâtel, Switzerland; and Department of Clinical Neurosciences (F.O.), University Hospital of Lausanne, Switzerland.*

*Author contributions: Thomas Rossel: concept and design of the paper, acquisition of data, analysis and interpretation, and drafting of the manuscript. Anastasia Zekeridou: concept and design of the paper, analysis and interpretation of the data, drafting of the manuscript, and critical revision for important intellectual content. François Ochsner: acquisition of data, analysis and interpretation, and critical revision for important intellectual content. Susanne Renaud: acquisition of data, analysis and interpretation, and critical revision of the draft for important intellectual content.*

*Acknowledgment: The authors thank Prof. Vanda Lennon, MD, PhD, Mayo Clinic, Rochester, MN, for revising the manuscript.*

*Study funding: No targeted funding reported.*

*Disclosure: The authors report no disclosures. Go to [Neurology.org/nn](http://Neurology.org/nn) for full disclosure forms.*

*This is an open access article distributed under the terms of the Creative Commons Attribution-Noncommercial No Derivative 3.0 License, which permits downloading and sharing the work provided it is properly cited. The work cannot be changed in any way or used commercially.*

*Received January 8, 2015. Accepted in final form March 9, 2015.*

*Correspondence to Dr. Zekeridou: anastasia.zek@gmail.com*

1. Lennon VA, Wingerchuk DM, Kryzer TJ, et al. A serum autoantibody marker of neuromyelitis optica: distinction from multiple sclerosis. *Lancet* 2004;364:2106–2112.
2. Wingerchuk DM, Lennon VA, Lucchinetti CF, Pittock SJ, Weinshenker BG. The spectrum of neuromyelitis optica. *Lancet Neurol* 2007;6:805–815.
3. Pittock SJ, Lennon VA, de Seze J, et al. Neuromyelitis optica and non organ-specific autoimmunity. *Arch Neurol* 2008;65:78–83.
4. Pittock SJ, Lennon VA. Aquaporin-4 autoantibodies in a paraneoplastic context. *Arch Neurol* 2008;65:629–632.
5. Quek AML, McKeon A, Lennon VA, et al. Effects of age and sex on aquaporin-4 autoimmunity. *Arch Neurol* 2012;69:1039–1043.
6. Leite MI, Coutinho E, Lana-Peixoto M, et al. Myasthenia gravis and neuromyelitis optica spectrum disorder: a multicenter study of 16 patients. *Neurology* 2012;78:1601–1607.
7. Ontaneda D, Fox RJ. Is neuromyelitis optica with advanced age of onset a paraneoplastic disorder? *Int J Neurosci* 2014;124:509–511.

# Neurology® Neuroimmunology & Neuroinflammation

## Aquaporin-4–positive myelitis associated with Sjögren syndrome and colonic adenocarcinoma

Thomas Rossel, Anastasia Zekeridou, Francois Ochsner, et al.  
*Neurol Neuroimmunol Neuroinflamm* 2015;2;  
DOI 10.1212/NXI.0000000000000103

**This information is current as of April 9, 2015**

<b>Updated Information &amp; Services</b>	including high resolution figures, can be found at: <a href="http://nn.neurology.org/content/2/3/e103.full.html">http://nn.neurology.org/content/2/3/e103.full.html</a>
<b>References</b>	This article cites 7 articles, 0 of which you can access for free at: <a href="http://nn.neurology.org/content/2/3/e103.full.html##ref-list-1">http://nn.neurology.org/content/2/3/e103.full.html##ref-list-1</a>
<b>Permissions &amp; Licensing</b>	Information about reproducing this article in parts (figures, tables) or in its entirety can be found online at: <a href="http://nn.neurology.org/misc/about.xhtml#permissions">http://nn.neurology.org/misc/about.xhtml#permissions</a>
<b>Reprints</b>	Information about ordering reprints can be found online: <a href="http://nn.neurology.org/misc/addir.xhtml#reprintsus">http://nn.neurology.org/misc/addir.xhtml#reprintsus</a>

*Neurol Neuroimmunol Neuroinflamm* is an official journal of the American Academy of Neurology. Published since April 2014, it is an open-access, online-only, continuous publication journal. Copyright © 2015 American Academy of Neurology. All rights reserved. Online ISSN: 2332-7812.

