

Validation of two echocardiographic indexes to improve the diagnosis of complex coarctations[☆]

Yvan Mivelaz^{*}, Stefano Di Bernardo, Erik Jan Meijboom, Nicole Sekarski

Paediatric Cardiology, Cardiovascular and Metabolic Diseases Centre, Centre Hospitalier Universitaire Vaudois and University of Lausanne, Lausanne, Switzerland

Received 8 February 2008; received in revised form 25 June 2008; accepted 14 July 2008; Available online 27 September 2008

Abstract

Objectives: Coarctation of the aorta is one of the most common congenital heart defects. Its diagnosis may be difficult in the presence of a patent ductus arteriosus, of other complex defects or of a poor echocardiographic window. We sought to demonstrate that the carotid-subclavian artery index (CSA index) and the isthmus–descending aorta ratio (I/D ratio), two recently described echocardiographic indexes, are effective in detection of isolated and complex aortic coarctations in children younger and older than 3 months of age. The CSA index is the ratio of the distal aortic arch diameter to the distance between the left carotid artery and the left subclavian artery. It is highly suggestive of a coarctation when it is <1.5 . The I/D ratio defined as the diameter of the isthmus to the diameter of the descending aorta, suggests an aortic coarctation when it is less than 0.64. **Methods:** This is a retrospective cohort study in a tertiary care children's hospital. Review of all echocardiograms in children aged 0–18 years with a diagnosis of coarctation seen at the author's institution between 1996 and 2006. An age- and sex-matched control group without coarctation was constituted. Offline echocardiographic measurements of the aortic arch were performed in order to calculate the CSA index and I/D ratio. **Results:** Sixty-eight patients were included in the coarctation group, 24 in the control group. Patients with coarctation had a significantly lower CSA index (0.84 ± 0.39 vs 2.65 ± 0.82 , $p < 0.0001$) and I/D ratio (0.58 ± 0.18 vs 0.98 ± 0.19 , $p < 0.0001$) than patients in the control group. Associated cardiac defects and age of the child did not significantly alter the CSA index or the I/D ratio. **Conclusions:** A CSA index less than 1.5 is highly suggestive of coarctation independent of age and of the presence of other cardiac defects. I/D ratio alone is less specific than CSA alone at any age and for any associated cardiac lesion. The association of both indexes improves sensitivity and permits diagnosis of coarctation in all patients based solely on a bedside echocardiographic measurement.

© 2008 European Association for Cardio-Thoracic Surgery. Published by Elsevier B.V. All rights reserved.

Keywords: Aortic coarctation; Ultrasonography; Paediatric; Infant; Neonate

1. Introduction

Coarctation of the aorta is a common congenital heart defect [1]. It is defined as a narrowing of the aorta, commonly occurring in the thoracic descending aorta, in the juxtaductal area just distal to the left subclavian artery. It results from a localised thickening of the aortic media, which protrudes into the lumen of the vessel and obstructs blood flow [2]. It is frequently associated with other cardiac lesions such as bicuspid aortic valve, hypoplastic aortic arch, patent arterial duct, ventricular septal defects, but it can also be encountered in more complex defects [3].

Associated anomalies of the aortic arch with isolated coarctation, in particular displacement of the left subclavian artery and narrowing of the distal transverse arch, have been

widely described [4–10]. Their presence, independent of haemodynamic repercussions of the coarctation, has not been used for the diagnosis until recently. Dodge-Khatami et al. have proposed the carotid-subclavian artery index (CSA index) in infants less than 3 months of age and Wu et al. the isthmus–descending aorta diameter ratio (I/D ratio) in newborns with patent ductus arteriosus (PDA) as a supplementary diagnostic tool for the detection of coarctation by 2D echocardiography (Fig. 1) [11,12].

The CSA index, defined as the ratio of the distal transverse aortic arch diameter (DTA) to the distance between the left carotid artery and the left subclavian artery, suggests a coarctation when it is below 1.5, whereas for the I/D ratio, defined as the ratio of isthmus (I) to descending aorta diameters (D), when it is below 0.64.

There are several advantages of these measurements. They can easily be obtained from a standard suprasternal view even if the aortic arch and a possible ductus are not in the same plane and are independent of a Doppler gradient. The presence of a PDA does not alter the accuracy of the indexes [13].

[☆] Abstract presented at the 42nd Annual Meeting of the Association for European Paediatric Cardiology in Warsaw, 16–19 May 2007.

^{*} Corresponding author. Address: Pediatric Cardiology, Centre Hospitalier Universitaire Vaudois, Rue du Bugnon 46, CH-1011, Lausanne, Switzerland. Tel.: +41 21 314 35 56; fax: +41 21 314 36 65.

E-mail address: yvan.mivelaz@chuv.ch (Y. Mivelaz).

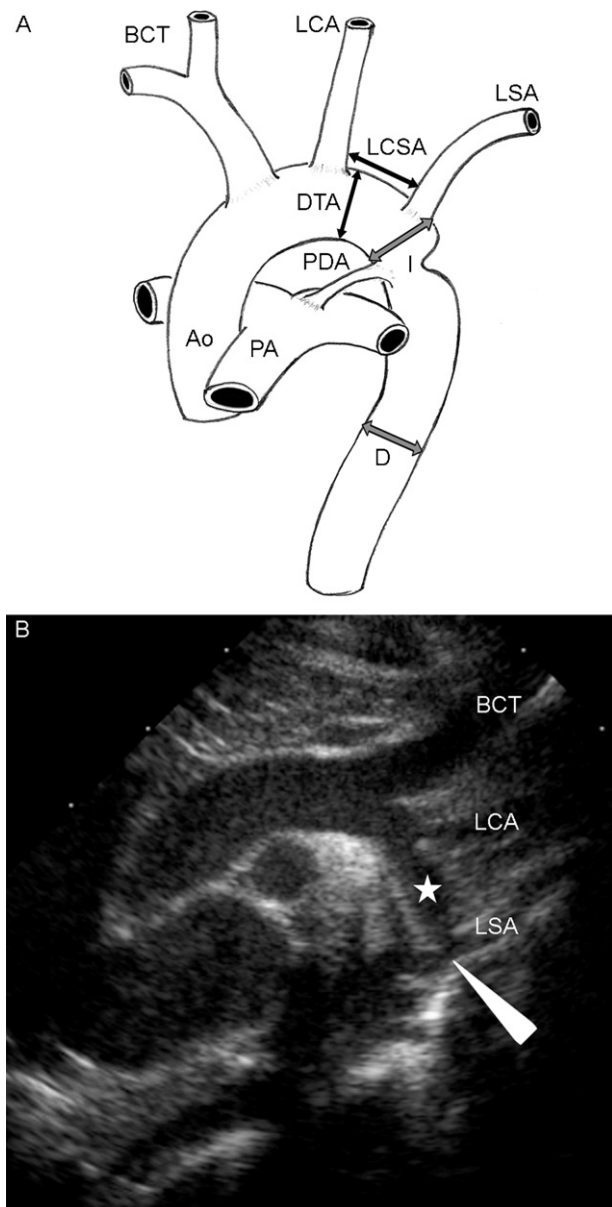


Fig. 1. (A) Diagram of the aortic arch. Echocardiographic parameters of the aortic arch measured were DTA, I and D diameters and the LCSA distance. CSA index is the ratio of LCSA to DTA. I/D ratio is the ratio of I to D. (B) Suprasternal aortic arch view by two-dimensional transthoracic echocardiography. Typical case of coarctation of the aorta (arrowhead) with distal displacement of the LSA, narrowed DTA (star) and I diameters.

DTA: distal transverse arch diameter; LCSA: distance between the left carotid artery and the left subclavian artery; I: aortic isthmus diameter; D: descending aorta diameter; Ao: aorta; BCT: brachiocephalic trunk; LCA: left carotid artery; LSA: left subclavian artery; PA: pulmonary artery; PDA: patent ductus arteriosus.

However, these indexes have only been validated for a very limited population. The CSA index was only published in infants less than 3 months of age and only in isolated coarctation. The I/D ratio has been described only in newborns with PDA. We hypothesised that the abnormal distal displacement of the left subclavian artery is characteristic of aortic coarctations whatever the associated cardiac defect is. The objectives of our study were to confirm the CSA index as a predictor of coarctation in patients with

complex coarctation and in patients older than 3 months old and to evaluate the benefit of calculating the I/D ratio for detecting coarctation in every aged patient and those without PDA. Finally we determined if performing both indexes in the same patient would improve the sensibility and specificity of predicting coarctation.

2. Methods

2.1. Patients

Patients were selected through a review of our institutional echocardiography database. The database contains prospectively entered data on all patients seen at our clinic at the Lausanne University Children's Hospital, a tertiary care children's hospital, from 1996 to 2006.

Children were included if they satisfied the following criteria: less than 18 years old at the time of echocardiography, confirmation of the diagnosis either by surgery or at autopsy, at least one technically adequate echocardiogram prior to surgery or death, and adequate two-dimensional imaging of the distal aortic arch in the suprasternal view to allow offline measurements. Children with anomalies of the head and neck vessels or interrupted aortic arch were excluded.

Patients were divided in subgroups according to the complexity of their cardiac defects: isolated coarctation (including children with PDA, bicuspid aortic valve or patent foramen ovale), coarctation and minor defects (VSD, ASD, aorto-pulmonary window) and coarctation belonging to a complex cardiopathy (transposition of great arteries, double outlet right ventricle, single ventricle or hypoplastic left heart). Another analysis was performed according to the age of the patients: infants less than 3 months of age and older than 3 months.

Eighty-six patients with a diagnosis of coarctation were identified. Of these, 18 were excluded because of the absence of good quality imaging of the aortic arch (7 patients), of interrupted aortic arch (6 patients), of head and neck vessels anomalies (4 patients) or because of death prior to surgery without necropsy examination (1 patient). All remaining 68 patients were included in the study. There were 44 patients less than 3 months of age and 24 patients older than 3 months. Videotapes and echocardiogram reports of every identified patient were reviewed. All echocardiograms were recorded by either Vingmed Sonotron CFM 800 (VingMed, Oslo, Norway) or Acuson Sequoia 256 (Siemens Acuson Co., Mountain View, CA, USA) echocardiograph (with 3.5, 5 and 7 MHz transducers).

An age- and sex-matched control group consisted of 24 children without heart defects requiring an echocardiogram at our clinic. Patients were excluded if they had anomalies of the head and neck vessels or an inadequate transthoracic window (Table 1). Seventeen infants were younger than 3 months and seven older than 3 months.

2.2. Variables

The following variables were recorded for each patient: age, height, weight, sex, and echocardiographic parameters of the aortic arch described below.

Table 1
Demographic data of patients in coarctation and control group

	Coarctation group, N = 68		Control group, N = 24		p value
	Mean	SD	Mean	SD	
	0.68 ^a		0.58 ^a		0.68 ^a
Age (months)	15.7	33.7	16.2	39.2	0.95
Weight (kg)	7.2	9.1	7.5	10.1	0.89
Height (cm)	64.0	28.2	62.1	29.2	0.77

^aSex ratio (M/M + F).

2.3. Measurements

Echocardiograms were all recorded on digital videotapes. They were reviewed by one observer. Echocardiographic parameters of the aortic arch described in Fig. 1 were measured with on-screen calibration of still frames from video recordings. Measurements were made from the suprasternal view, during end-systole in order to capture the largest inner diameter of the vessels from inner edge to inner edge and the largest distance between great vessels. From these measurements, we calculated the CSA index and the I/D ratio in all patients.

A second investigator remeasured the stored images of 10 randomly selected cases for calculation of interobserver variability.

2.4. Analysis

All data were analysed using the StatView for Windows statistical package version 5.0.1 (SAS, Institute Inc., Cary, NC, USA). The coarctation and control group were analysed as two independent groups. Each continuous measurement was summarised by its arithmetic mean and standard deviation (SD), and reported as mean (SD) in the tables. Comparisons were performed using the chi-square test or by unpaired Student's *t*-test. A value of $p < 0.05$ was considered as significant.

To test the agreement between measurements made by the two independent observers a one-way ANOVA was used to estimate the various components of variance required to calculate the intraclass correlation coefficient (ICC) [14,15].

3. Results

3.1. Study population

Demographic data of the patients are found in Table 1.

A total of 68 children with coarctation were included in the study and their echocardiogram reviewed. Thirty-three patients (49%) had an isolated coarctation. Twenty-six patients (38%) had minor associated defects: perimembranous ventricular septal defect ($n = 14$), muscular ventricular septal defect ($n = 4$), ventricular septal defect and atrial septal defect ($n = 3$), atrial septal defect ($n = 4$) and aortopulmonary window ($n = 1$). Nine patients (13%) had major associated defects: double outlet right ventricle \pm great vessel malposition ($n = 4$), hypoplastic left heart syndrome ($n = 2$), single ventricle ($n = 2$) and transposition of the great vessels ($n = 1$). A PDA was present in 25 patients (4 in the

Table 2
Echocardiographic measurements and calculation of CSA index and I/D ratio

	Coarctation group, N = 68		Control group, N = 24		p value
	Mean	SD	Mean	SD	
DTA diameter (mm)	5.4	2.4	11.9	16.3	0.0017
LCSA distance (mm)	7.0	3.4	5.1	9.1	0.14
I diameter (mm)	5.1	2.6	8.9	1.2	0.0167
D diameter (mm)	8.8	3.2	8.4	8.7	0.75
CSA index	0.84	0.39	2.65	0.82	<0.0001
I/D ratio	0.58	0.18	0.98	0.19	<0.0001

SD: standard deviation; DTA: distal transverse arch diameter; LCSA: distance between the left carotid artery and the left subclavian artery; I: aortic isthmus diameter; D: descending aorta.

isolated coarctation group, 14 in the coarctation with minor defects and 7 in the coarctation with major cardiac defects group), 22 of whom were younger than 3 months.

The control group included 24 children without coarctation or other cardiac defect. A PDA was found in six patients less than 3 months old, all newborns. PDA was considered physiological in newborns less than 2 days old.

3.2. Echocardiographic measurements

Echocardiographic parameters of the aortic arch, calculated CSA index and I/D ratio for the coarctation and the control group are provided in Table 2. CSA index was calculated for every patient, I/D ratio could not be calculated in two patients due to the lack of good quality imaging of the descending aorta. A significant difference was observed between both groups for the distal transverse aortic arch, the isthmus diameters, the CSA index and the I/D ratio.

Age at diagnosis had no influence on the CSA index. In the coarctation group, CSA indexes are identical before and after 3 months of age and are significantly lower than in the control group at the corresponding age (Fig. 2A, Table 3).

For the I/D ratio, the values obtained in the coarctation group before and after 3 months of age are similar. Both values are significantly lower than the values of the control group (Fig. 2B, Table 3).

Associated cardiac lesions did not affect the relation between CSA index and coarctation. CSA index showed a significant difference from the CSA index of the control group (Fig. 2C, Table 3).

For the I/D ratio, we obtained similar significant results between coarctation groups and the control group (Fig. 2D, Table 3).

With a cut-off of 1.5, sensitivity of the CSA index for the diagnosis of coarctation was 99% (95%CI: 92–100%) and specificity 96% (95%CI: 80–99%). For the I/D ratio specificity was 100% (95%CI: 86–100%), but sensitivity was poorer with 72% (95%CI: 61–80%). Association of both indexes (CSA index <1.5 OR I/D ratio <0.64 for the diagnosis of coarctation) improved the sensitivity to 100% (95%CI: 95–100%) and the specificity to 96% (95%CI: 80–99%).

3.3. False negatives

One patient in the coarctation group had a false negative CSA index (CSA index 3.13). This was a newborn with an

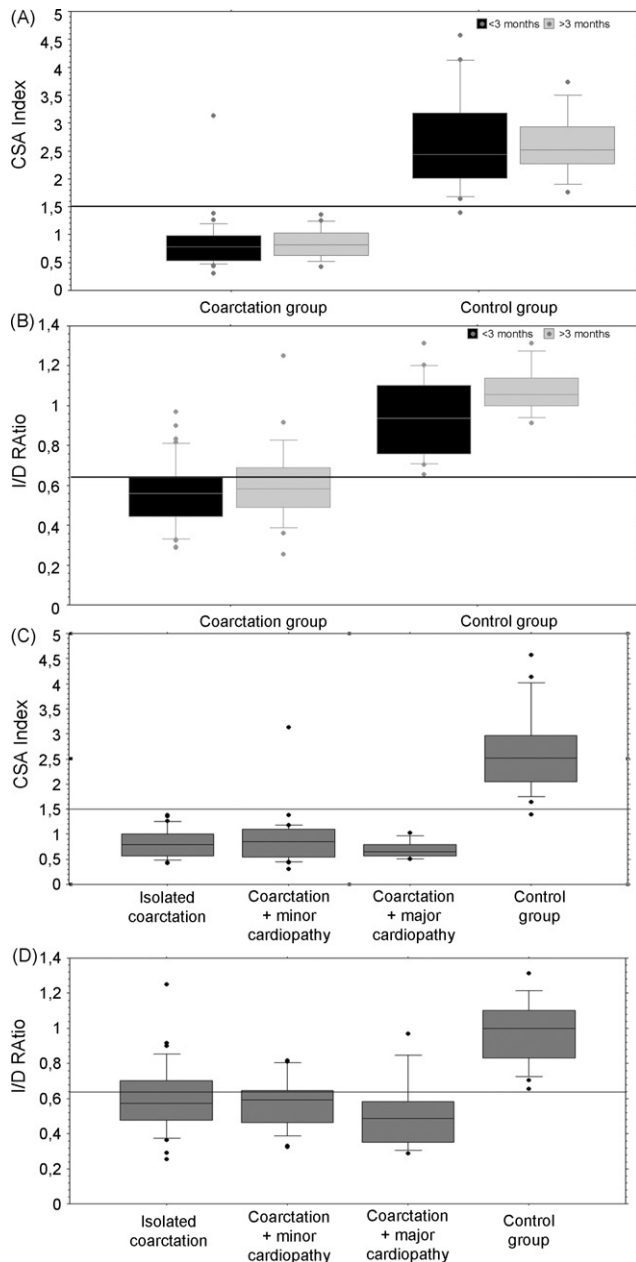


Fig. 2. Box plot diagrams of CSA index and I/D ratio in coarctation and control group with regards to age (A and B, respectively) and associated anomalies (C and D, respectively). (A) CSA index split by age (children less than 3 months old: black boxes, more than 3 months old: grey boxes) grouping by presence or not of a coarctation. The horizontal line represents the 1.5 cut-off. (B) I/D ratio split by age (children less than 3 months old: black boxes, more than 3 months old: grey boxes) grouping by presence or not of a coarctation. The horizontal line represents the 0.64 cut-off. (C) Box plot diagram for comparison of the CSA index when coarctation is associated to other cardiac defects. The horizontal line represents the 1.5 cut-off. Minor defects and major defects are detailed in the text. (D) Box plot diagram for comparison of the I/D ratio when coarctation is associated to other cardiac defects. The horizontal line represents the 0.64 cut-off.

In diagrams, the boxes represent the interquartile range, the horizontal line inside the box the median, and the 'I' bars the 10th and 90th percentiles of the values. Black dots are value above the 90th percentile or below the 10th percentile.

associated minor defect (perimembranous VSD and a small muscular VSD). He had a pathological I/D ratio of 0.44 and surgery confirmed the coarctation. Eighteen patients had a false negative I/D ratio, 10 of which were less than 3 months with 5 having a PDA. Ten had isolated coarctation, six had coarctation with minor defects and two had coarctation with major defects.

3.4. False positives

In the control group, one patient had a false positive CSA index (CSA index 1.39) close to the cut-off 1.5. None of the patients had a false positive I/D ratio.

3.5. Interobserver agreement

For the 10 randomly selected echocardiograms reviewed by two observers, the ICC range for aortic arch measurements and ratios is from 0.86 to 0.99, indicating good agreement (Table 4).

4. Discussion

During foetal life and shortly after birth, due to patency of the arterial duct and the parallel circulation, coarctation is haemodynamically well tolerated and could be missed clinically [16,17]. In case of clinical suspicion of aortic coarctation, echocardiography is the only bedside diagnostic tool available. For coarctation of the aorta imaging of the arch in the suprasternal view shows a posterior shelf after the left subclavian artery with narrowing of the isthmus. It can be associated with hypoplasia of the transverse arch. A Doppler gradient across the narrowing with diastolic run-off depending on the severity of the coarctation is usually found. Several reasons may make the echocardiographic diagnosis difficult. A large PDA may mask the isthmus narrowing and decreased ventricular function will underestimate the Doppler gradient [18–21]. A rapid diagnosis is crucial for critically ill newborns, as they may need therapy to maintain ductal patency and sustain cardiac function.

In older children the ductus arteriosus is closed but precise imaging of the isthmus in the suprasternal view can be challenging. Presence of an aortic coarctation in complex heart disease is an aggravating factor and may change the medical or surgical approach. For all these reasons an echocardiographic index, independent of cardiac function, presence of PDA or other lesions and based on 2D measurements of the transverse aortic arch would provide a simple tool to improve the accuracy of diagnosing coarctation.

In the literature two previous studies have introduced such indexes which were validated in a limited group of patients [11,12]. Dodge-Khatami et al. described for the first time the CSA index and at a cut-off point of 1.5 showed 97.7%/94.7% sensitivity and 92.3%/100% specificity for newborns/infants less than 3 months of age with coarctation. This study was a retrospective analysis of a cohort of 63 patients with a mean age of 12 days in the neonatal group and 75 days in the infant group. Forty-two percent of the study population had an associated VSD and 42% had a PDA. The

Table 3
Impact of age and concomitant cardiopathy on CSA index and I/D ratio

	Coarctation group, CSA index		Control group, CSA index		p value	Coarctation group, I/D ratio		Control group, I/D ratio		p value
	Mean	SD	Mean	SD		Mean	SD	Mean	SD	
<3 months	0.84	0.44	2.66	0.93	<0.0001	0.56	0.16	0.94	0.20	<0.0001
>3 months	0.84	0.27	2.62	0.59	<0.0001	0.61	0.20	1.08	0.12	<0.0001
Isolated coarctation	0.82	0.28	2.65 ^a	0.82	<0.0001	0.50	0.20	0.98 ^b	0.19	<0.0001
Coarctation + minor defects	0.90	0.54			<0.0001	0.58	0.14			<0.0001
Coarctation + major defects	0.70	0.17			<0.0001	0.52	0.21			<0.0001

^a Mean value of CSA index independently of age.

^b Mean value of the I/D ratio independently of age.

control group comprised 16 neonates and 7 infants. Wu et al. described the I/D ratio with the objective to have a tool to diagnose coarctation in newborns with PDA. They performed a retrospective analysis of 36 neonates with coarctation and PDA, 75% of whom had also associated intracardiac anomalies. The I/D ratio was below 0.64 in 32/36 neonates (89%). The control group comprised 19 neonates with PDA. In a subsequent prospective study in 162 neonates with PDA and I/D ratio below 0.64 together with the delineation of a posterior shelf and an arm-leg blood pressure discrepancy had a sensitivity of 91.7% and a specificity of 99.3%.

Our study showed that the CSA index is a reliable echocardiographic tool in detecting coarctation of the aorta in infants younger than 3 months as well as in patients older than 3 months. With the CSA index we also demonstrated that it is possible to predict the presence of aortic coarctation in a wide variety of complex cardiac malformations such as in double outlet right ventricle independent of the position of the aorta, single ventricle or transposition of the great arteries. Although we included in our study patients of all ages or with all types of cardiac malformations, we found almost the same sensitivity and specificity for CSA index as compared to the initial publication.

The I/D ratio in our study was less efficient in detecting aortic coarctation in all groups of patients. Several reasons might have played a role. Originally in Wu's paper, the I/D ratio was instituted only for newborns with PDA and simple coarctation. A high sensitivity was only achieved when adding two other parameters: the blood pressure difference between upper and lower extremities and the presence of a posterior shelf on echocardiography. In our study we tried to extend this first initial description to all age groups and to all associated cardiac malformations independent of the presence of a PDA and without taking into account the blood pressure and the presence of a posterior shelf. This most certainly decreased

the sensitivity in our study. The other reason could have been that for measurement of this ratio a perfect view of the isthmus and descending aorta is necessary, which is a limiting factor, especially in older children.

When using CSA index there was only one false negative patient, a newborn who had nevertheless a pathological I/D ratio. From this we can deduct that CSA index is a reliable tool in detecting coarctation and the adjunction of the I/D ratio is only helpful in newborns.

4.1. Limitations

This study was retrospective with its limitations. It required the review of videotapes, with subsequent off-line calibration for measurement of aortic arch structures. This may have induced some error in the measurement process, however, interobserver variability showed a strong correlation between observers. Exclusion of patients without good quality imaging of the aortic arch is another potential bias. Our numbers are relatively small, reducing the power of our findings, especially when analysing results in subgroups of the coarctation group. Only a prospective study with a greater population of newborn and infants, both with and without complex associated cardiac defects, could confirm the close relation between the CSA index and coarctation.

5. Conclusions

The CSA index is a simple screening echocardiographic parameter, easily calculated with two common measurements of the aortic arch in the suprasternal view. Our study confirms that a CSA index below 1.5 is highly suggestive of coarctation in every aged patient independent of associated anomalies. The addition of another echocardiographic index, the I/D ratio, might be useful for better confidence, especially in newborns, before ductus arteriosus closure. Based on this study a CSA index less than 1.5 and an I/D ratio less than 0.64 would suggest close monitoring of the patient until the PDA closes and in patients where the isthmus portion of the aortic arch is difficult to visualise performing further imaging to rule out coarctation.

Acknowledgement

Acknowledgements to Mrs Thi-Sang Nguyen for her help in retrieving video sequences.

Table 4
Agreement for aortic arch measurements made by two observers

	Mean \pm SD	ICC
Δ DTA (mm)	0.2 \pm 1.3	0.94
Δ LCSA (mm)	-0.1 \pm 0.8	0.99
Δ CSA index	0.16 \pm 0.54	0.91
Δ I (mm)	-0.5 \pm 1.5	0.92
Δ D (mm)	-0.3 \pm 1.5	0.96
Δ I/D ratio	-0.04 \pm 0.16	0.85

Mean difference, standard deviation and ICC for each measurements and ratios from both investigators. The intraclass correlation coefficient is expressed as a measure of agreement. ICC: intraclass correlation

References

- [1] Rothman A. Coarctation of the aorta: an update. *Curr Probl Pediatr* 1998;28(2):33–60.
- [2] Morris MJH, McNamara DG. Coarctation of the aorta and interrupted aortic arch. In: Garson A, Bricker JT, McNamara DG, editors. *The science and practice of pediatric cardiology*. 2nd ed., Baltimore: Lippincott Williams & Wilkins; 1998. p. 1313–47.
- [3] Aboulhosn J, Child JS. Left ventricular outflow obstruction: subaortic stenosis, bicuspid aortic valve, supraaortic stenosis, and coarctation of the aorta. *Circulation* 2006;114(22):2412–22.
- [4] Glancy DL, Morrow AG, Simon AL, Roberts WC. Juxtaductal aortic coarctation. Analysis of 84 patients studied hemodynamically, angiographically, and morphologically after age 1 year. *Am J Cardiol* 1983;51(3):537–51.
- [5] Bremer JL. Coarctation of the aorta and the aortic isthmuses. *Arch Pathol* 1948;45:425.
- [6] Kantoch M, Pieroni D, Roland JM, Gingell RL. Association of distal displacement of the left subclavian artery and coarctation of the aorta. *Pediatr Cardiol* 1992;13(3):164–9.
- [7] Smallhorn JF, Huhta JC, Adams PA, Anderson RH, Wilkinson JL, Macartney FJ. Cross-sectional echocardiographic assessment of coarctation in the sick neonate and infant. *Br Heart J* 1983;50(4):349–61.
- [8] Aluquin VP, Shutte D, Nihill MR, Lu AY, Chen L, Gelves J, Epstein ML, Forbes TJ. Normal aortic arch growth and comparison with isolated coarctation of the aorta. *Am J Cardiol* 2003;91(4):502–5.
- [9] Nihoyannopoulos P, Karas S, Sapsford RN, Hallidie-Smith K, Foale R. Accuracy of two-dimensional echocardiography in the diagnosis of aortic arch obstruction. *J Am Coll Cardiol* 1987;10(5):1072–7.
- [10] Morrow WR, Huhta JC, Murphy Jr DJ, McNamara DG. Quantitative morphology of the aortic arch in neonatal coarctation. *J Am Coll Cardiol* 1986;8(3):616–20.
- [11] Lu CW, Wang JK, Chang CI, Lin MT, Wu ET, Lue HC, Chen YS, Chiu IS, Wu MH. Noninvasive diagnosis of aortic coarctation in neonates with patent ductus arteriosus. *J Pediatr* 2006;148(2):217–21.
- [12] Dodge-Khatami A, Ott S, Di Bernardo S, Berger F. Carotid-subclavian artery index: new echocardiographic index to detect coarctation in neonates and infants. *Ann Thorac Surg* 2005;80(5):1652–7.
- [13] Jaquiss RD, Frommelt PC. Invited commentary. *Ann Thorac Surg* 2005;80(5):1657–8.
- [14] Bland M. Clinical measurement: repeatability and measurement error. In: *An introduction to medical statistics*, 3rd ed. Oxford, New York: Oxford University Press; 2000. p. 269–72.
- [15] Bland M. Regression and correlation: intraclass correlation. In: *An introduction to medical statistics*, 3rd ed. Oxford, New York: Oxford University Press; 2000. p. 204–5.
- [16] Franklin O, Burch M, Manning N, Sleeman K, Gould S, Archer N. Prenatal diagnosis of coarctation of the aorta improves survival and reduces morbidity. *Heart* 2002;87(1):67–9.
- [17] Sharland GK, Chan KY, Allan LD. Coarctation of the aorta: difficulties in prenatal diagnosis. *Br Heart J* 1994;71(1):70–5.
- [18] Grenadier E, Lima CO, Sahn DJ, Allen HD, Valdes-Cruz LM. Serial two-dimensional echocardiography for detection of coarctation of the aorta in the postnatal period. *Pediatr Cardiol* 1983;4(4):285–7.
- [19] Ho SY, Anderson RH. Coarctation, tubular hypoplasia, and the ductus arteriosus. Histological study of 35 specimens. *Br Heart J* 1979;41(3):268–74.
- [20] Head CE, Jowett VC, Sharland GK, Simpson JM. Timing of presentation and postnatal outcome of infants suspected of having coarctation of the aorta during fetal life. *Heart* 2005;91(8):1070–4.
- [21] Rosenthal E. Coarctation of the aorta from fetus to adult: curable condition or life long disease process? *Heart* 2005;91(11):1495–502.