

Images in cardio-thoracic surgery

Caught in the act

A. Delabays, P. Ruchat*, L.K. von Segesser, L. Kappenberger

Department of Cardiology and Cardio-thoracic Surgery, University Hospital, 1011 Lausanne, Switzerland

Received 5 August 1998; revised version received 7 August 1998; accepted 8 September 1998

A 59-year-old woman presented with acute pulmonary embolism. A routine echocardiography showed pulmonary hypertension, right ventricular dysfunction and a mass floating in the left atrium (Fig. 1).

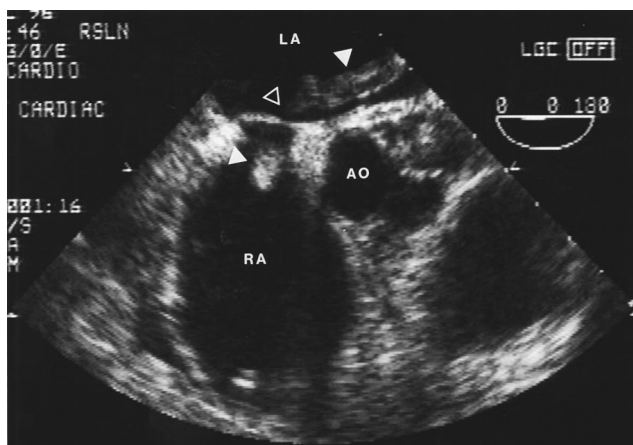


Fig. 1. Transesophageal view of an elongated thrombus crossing the interatrial septum with its major portion in the left atrium (LA, left atrium; RA, right atrium; AO, aorta).

Numerous clots could also be removed from the left pulmonary artery (Fig. 2). An inferior vena cava filter was inserted post-operatively and the patient recovered uneventfully. At the 6 months follow-up visit, she was asymptomatic.

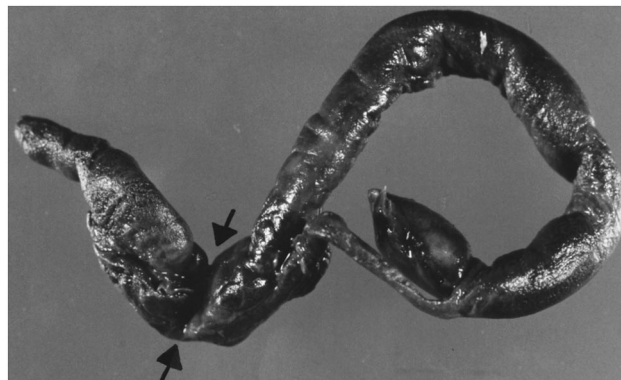

Fig. 2. Macroscopic view of the clot removed under cardio-pulmonary bypass. Arrows indicate inprint of the foramen ovale.

* Corresponding author. Tel.: +41 21 3142280; fax: +41 21 3142278;
e-mail: patrick.ruchat@chuv.hospvd.ch