

Patterns of ischemic posterior circulation strokes: A clinical, anatomical, and radiological review

Alexander Salerno¹ , Davide Strambo¹ , Stefania Nannoni¹ 
Vincent Dunet² and Patrik Michel¹ 

International Journal of Stroke
2022, Vol. 17(7) 714–722
© 2021 World Stroke Organization



Article reuse guidelines:
sagepub.com/journals-permissions
DOI: 10.1177/17474930211046758
journals.sagepub.com/home/wso



Abstract

Background: Posterior circulation and anterior circulation strokes share many clinical, pathogenetic and radiological features, although some clinical signs are highly specific to posterior circulation strokes. Arterial stenosis and occlusions occur in significant numbers in both acute posterior circulation and anterior circulation strokes, making them good candidates for endovascular treatment. Among posterior circulation strokes, basilar artery occlusions stand out because of the diagnostic and acute treatment challenges.

Methods: We reviewed the literature on clinical stroke syndromes and neuroimaging findings and systematically describe for each anatomical site of stroke the detailed clinical and radiological information (anatomical representation, diffusion weighted imaging and angiographic sequences). The principles of neuroimaging of posterior circulation strokes and the prognosis for each stroke localization are also discussed.

Review summary: Stroke syndromes in the territories of the vertebral, basilar, cerebellar, and posterior cerebral arteries are presented. Features typical of posterior circulation strokes are highlighted, including patterns of basilar artery occlusions. Clinical severity and prognosis of posterior circulation strokes are highly variable, and given that they are more difficult to detect on CT-based neuroimaging, magnetic resonance imaging is the technique of choice in suspected posterior circulation strokes. Rapid identification of arterial occlusion patterns may provide prognostic information and support acute revascularization decisions.

Conclusions: Posterior circulation stroke syndromes tightly reflect lesion localization and arterial occlusion patterns. Although many clinical and pathogenetic features are similar to anterior circulation strokes, notable differences exist in terms of clinical presentation, stroke mechanism, prognosis, and response to acute recanalization.

Keywords

Ischemic stroke, Vertebrobasilar insufficiency, Basilar artery, Magnetic Resonance Imaging, Prognosis

Received: 14 July 2021; accepted: 21 August 2021

Stroke mechanisms and general clinical features

Posterior circulation (PC) and anterior circulation (AC) strokes share many clinical and pathophysiological features, but there are notable differences mainly related to their respective cerebrovascular anatomy and brainstem functions. Whereas age and cerebrovascular risk factors seem similar, male sex appears more frequent in PC strokes.¹

Some clinical signs are highly specific to PC strokes because of the unique brainstem functions and vascularization (Figure 1). The basilar artery, in fact, gives origin to a peculiar network of perforating and circumferential arteries, which systematically repeats itself at

each anatomical level of the brainstem (Figure 2). Oculomotor deficits such as unilateral palsy of eye movements, internuclear ophthalmoplegia, and skew deviation are pathognomonic for brainstem locations of stroke.¹ This is also true for vertical nystagmus,

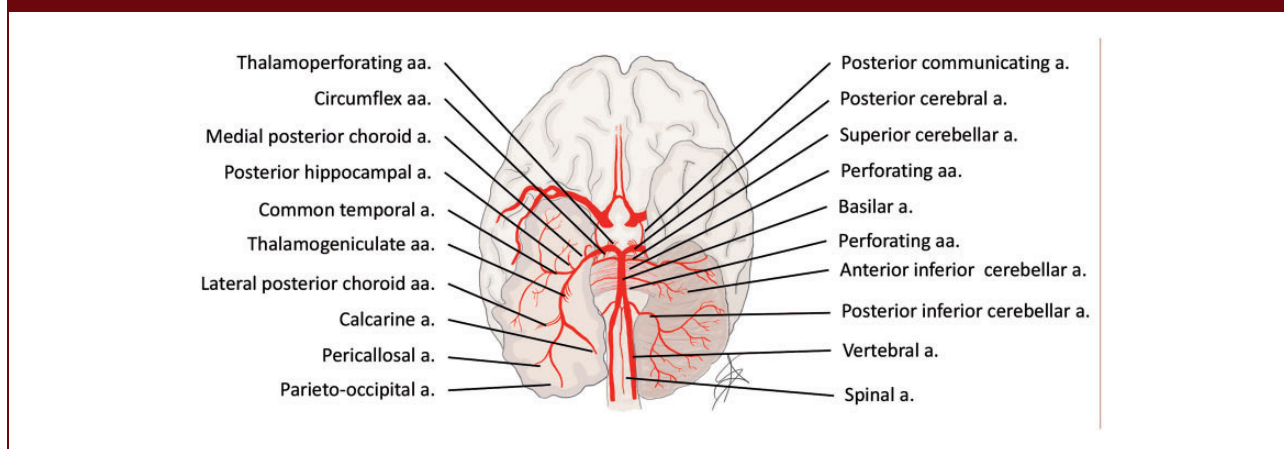
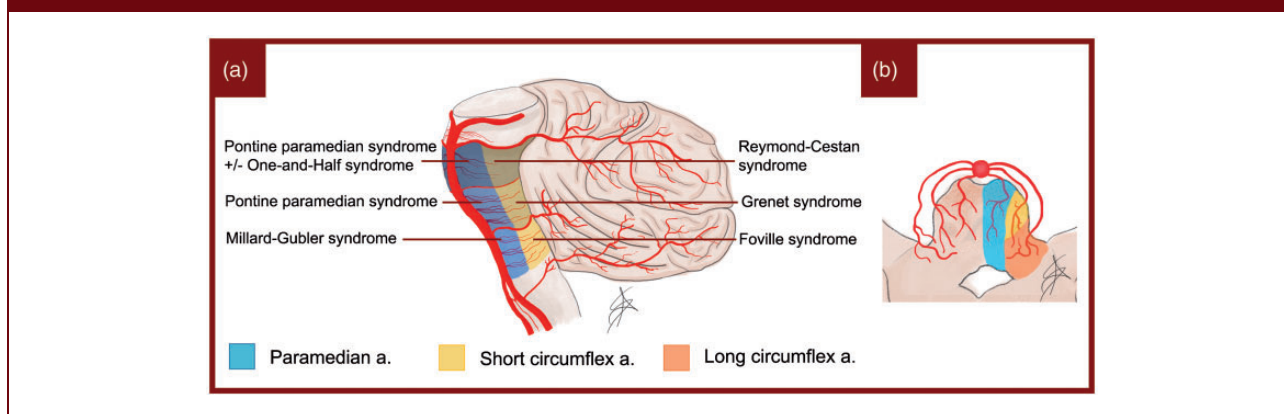
¹Stroke Center, Neurology Service, Department of Clinical Neurosciences, Lausanne University Hospital and University of Lausanne, Switzerland

²Department of Diagnostic and Interventional Radiology, Lausanne University Hospital and University of Lausanne, Switzerland

Corresponding author:

Alexander Salerno, Stroke Center, Neurology Service, Department of Clinical Neurosciences, CHUV, Rue du Bugnon, 46 1011 Lausanne, Switzerland.

Email: alexander.salerno@chuv.ch

Figure 1. Anatomy and vascularization of the vertebrobasilar system.**Figure 2.** (a) Schematization of pontine syndromes. (b) Pattern of perforating branches in the pons.

up- or down-gaze palsy and conjugate gaze paresis to one side. Crossed syndromes and bilateral long tract signs are highly specific because of the bilateral supply of the basilar artery to the posterior fossa structures, and the frequent crossing of fiber tracts in the brainstem. Central vestibular symptoms and signs such as nausea, vertigo, conjugate nystagmus in any direction, gait and hemi-ataxia are also characteristic of brainstem and cerebellar strokes.^{2,3} Lesions of the lower brainstem and cerebellum commonly cause true vertigo and conjugate horizontal/rotatory nystagmus, whereas strokes of the upper brainstem and cerebellum cause unsteadiness and gait ataxia. Infrequent but moderately specific signs are decreased level of consciousness and amnesic syndromes, which are often missed in the acute phase or mistaken for confusional state.

Hemispheric symptoms or signs such as aphasia, hemineglect, or conjugate eye deviation are rare in PC strokes, but may still occur due to the involvement of the thalamus; in this case, an important unilateral

posterior cerebral artery (PCA) stroke can even clinically mimic an AC stroke.³ Exceptionally, cerebellar stroke can also lead to cognitive dysfunction, related to bidirectional connections with the cortex (“diaschisis”).⁴

Contrary to general belief, dysarthria^{1,3} and homonymous visual field deficits¹ do not seem to be more frequent in PC than in AC strokes. However, PCA strokes more often cause *isolated* field deficits than middle cerebral artery (MCA) strokes.

The presence of multilevel lesions is peculiar to PC strokes. Symptoms may in fact be explained by the presence of two or more concomitant lesions. This feature is typical of PC strokes and is explained by the fact that the vertebrobasilar system stretches along multiple structures of the posterior fossa.

All mechanisms accounting for ischemic AC strokes also occur in the PC, and there are no consistent differences in their frequencies.^{1,5} In the largest comparative study, lacunar strokes seemed more frequent in the

PC,¹ which could be due to the high density of long tracts and cranial nerve structures in the brainstem. Therefore, small PC strokes may be more expressive than in the AC, which is less densely packed with neuronal and axonal structures.

For the same reason, acute neuroimaging (including MRI) may not show a clinical brainstem stroke (i.e. false-negative imaging). A negative MRI in face of a vascular brainstem syndrome should not preclude a stroke diagnosis. This is particularly true for patients with acute symptom onset, absence of alternative explanations, and cerebrovascular risk factors.

Finally, most studies show a lower initial stroke severity in PC strokes. This may be due to the more frequent lacunar strokes or an underrepresentation of clinical PC deficits (ataxia, gait, oculomotor signs, amnesia) in the NIHSS scale.⁶

The aim of this review is to present systematically the clinical–radiological correlations in PC strokes through the description of typical symptoms, anatomical drawings, and MRI-based examples.

Methods

We reviewed the literature for clinical stroke syndromes, anatomical vascular territories, and stroke patterns described from neuroimaging and autopsies. Examples of neuroradiological images were identified from the Acute STroke Registry and Analysis of Lausanne (ASTRAL). The first author realized anatomical drawings of territories using a Wacom Intuos© (Kazo, Japan) graphic tablet and Adobe Photoshop© (California, USA) software.

Vertebral artery strokes

Anatomy of the vertebral arteries

Vertebral arteries (VAs) constitute an essential part of the vertebrobasilar system, supplying almost 30% of the entire cerebral blood flow.⁷ Anatomically, each VA can be divided into an extracranial portion (V1–V3) and an intracranial portion (V4) (Figure 1). Vertebral artery hypoplasia, defined as an artery with a diameter of less than 2 mm, is observed in approximately 15% of cases.⁸ The main branches supplied by the vertebral arteries originate from V4: the anterior spinal artery, which vascularizes the anterior surface of the medulla and the spinal cord; and the posterior inferior cerebellar artery (PICA), which generally supplies the ipsilateral lower medulla, posterior-inferior cerebellum and inferior vermis. The size of the PICA varies and may be inversely proportional to the size of the ipsilateral anterior inferior cerebellar artery (AICA).⁹

Clinical presentation of vertebral artery strokes

VA stroke represents the most common kind of PC stroke and usually causes a bulbar lateral syndrome, historically known as *Wallenberg syndrome* (Supplementary Figure 1). The entity and clinical picture strongly depend on the vasculature diversification, with the lateral bulbar region being mainly supplied by the VA and PICA (Supplementary Figure 1). A branch of the VA, the posterior spinal artery, often overlaps with the PICA to vascularize the most dorsal segment of the medulla.¹⁰ This peculiar distinction reflects the clinical picture, with more or less extensive impairment of the lateral bulb at the rostro-caudal level. A severe infarct with extensive ischemic damage can cause a hemibulb syndrome, also known as *Babinski-Nageotte syndrome* (Supplementary Figure 1). In some cases, the clinical picture can be worsened by the appearance of a central alveolar hypoventilation syndrome known as *Ondine syndrome*.¹¹ This syndrome is characterized by failure of the breathing mechanisms during sleep, resulting in prolonged apneas.

Anterior spinal artery stroke causes median medullary syndrome, historically known as *Dejerine syndrome* (Supplementary Figure 1). A crossed syndrome results as a consequence of a lesion in the corticospinal tract above the decussation, a lesion of the medial lemniscus or a lesion of the fibers originating from the VIII nucleus. In addition, occlusion of this artery may result in an infarction of the anterior upper part of the cervical spinal cord, resulting in tetraparesis.

Basilar artery strokes

Anatomy of the basilar artery

The basilar artery (BA) originates from the conjunction of the two VAs at the intracranial level. Anatomically, it can be divided into three segments: proximal, middle, and distal. This division is reflected in the perforating branches originating from the BA, supplying the entire pons. We find the caudal group, from the juncture of the VAs to the anterior inferior cerebellar artery (AICA), the medium group, between the AICA and the posterolateral artery, and the rostral group from the posterolateral artery upwards (Figure 2(a)). Each group then gives origin to the perforating branches that enter the brainstem medio-laterally as the paramedian, short circumferential and long circumferential branches (Figure 2(b)).¹²

Clinical presentation of non-occlusive BA territory strokes

The clinical presentation of non-occlusive pontine strokes strongly depends on the pattern of involvement

of the perforating branches. Excluding the lateral territory of the pons, which is supplied mainly by the AICA, we can schematically divide the pons into six areas (Figure 2(a)): a medial-ventral group supported primarily by the paramedian branches of the BA and a tegmental or dorsal group supported partially by the paramedian but mostly by the circumflex branches. Each of these areas can be subdivided in caudal, mid, and rostral groups according to the craniocaudal distribution.

Detailed clinical, MRI, and angiographic presentations according to the site of lesion are provided in Supplementary Figure 2.

Clinical presentation of BA occlusions

BA ischemic strokes are caused by large-artery atheroembolism in about two-thirds of cases, which may explain their frequently progressive onset when compared to other strokes.¹³ Cardioembolisms account for one quarter of cases, and small vessel disease the rest. A few rare strokes are caused by arterial dissection.¹⁴

Occlusive thrombi can affect either the proximal, mid, or distal portion of the BA, resulting in very heterogeneous symptoms according to the extent of ischemic infarction. The rapidity of occlusion and the contribution of the collateral circulation account for a large part of this variability.

Occlusions involving the proximal and mid BA (Figure 3(a) and (b)) are for the most part caused by an atherothrombotic event and typically appear in combination with vertebral artery lesions.¹⁵ They usually result in large pontine infarcts with a combination of signs and symptoms that can be traced to the occlusion at the origin of the perforating branches as shown in Figures 2 and 3. In such lesions, vascularization of the distal BA and PCAs largely depends on the activation of a retrograde flow provided by the posterior communicating arteries (PComs). Symptoms range from milder cases of unilateral and crossed pontine syndromes to the worst-case scenario of bilateral involvement of pontine structures resulting in a “locked-in” syndrome.

Occlusions involving the distal BA are more often cardioembolic in nature.¹⁵ The resulting *top of the basilar* syndrome (Figure 3(c))¹⁶ may present with a wide range of symptoms, depending mainly on the length and position of the clot and on collateral flow provided by the PComs to vascularize the PCA territory. It may present with a sudden decreased level of consciousness due to the usually bilateral involvement of either the reticular formation or of the thalamus. Other features may consist of behavioral change and quadriplegia, followed by ataxia, oculomotor impairment seen as either vertical and/or horizontal gaze palsy, impairment of the

oculocephalic reflex, pupillary abnormalities, visual deficits, and sensory dysfunction.¹⁷

Cerebellar artery strokes

Anatomy of the cerebellar arteries

The cerebellum is composed of a midline vermis and two hemispheres. Blood is supplied by three pairs of arteries: the PICA, AICA, and superior cerebellar artery (SCA) (Supplementary Figure 3). The AICA originates from the middle segment of the BA and vascularizes the antero-inferior cerebellum. Its collateral branch, the internal auditory artery, supplies the vestibulocochlear nerve and inner ear. The SCA emerges from the distal segment of the BA. It splits into medial and lateral branches, which vascularizes the superior cerebellum and superior vermis. The cerebellar vascularization often presents variations such as a common trunk of the AICA and PICA, or bilateral vascularization by a unique artery.¹⁸

Clinical presentation of cerebellar artery strokes

Infarctions limited to the cerebellum present, in order of frequency, vertigo and dizziness, nausea and vomiting, gait unsteadiness, headache, dysarthria, and neurological signs such as limb or trunk ataxia, dysarthria or nystagmus, often absent or subtle.¹⁹ Upper cerebellar lesions generally present dysarthria, and lower, mostly vertigo, nausea, and vomiting. Cognitive symptoms (“diaschisis”) are possible but rare.⁴

The PICA is the territory frequently involved in cerebellar strokes, followed by the SCA and AICA. Approximately one third of cerebellar strokes involve multiple vascular territories, while 20–30% of cases present as borderzone strokes.²⁰

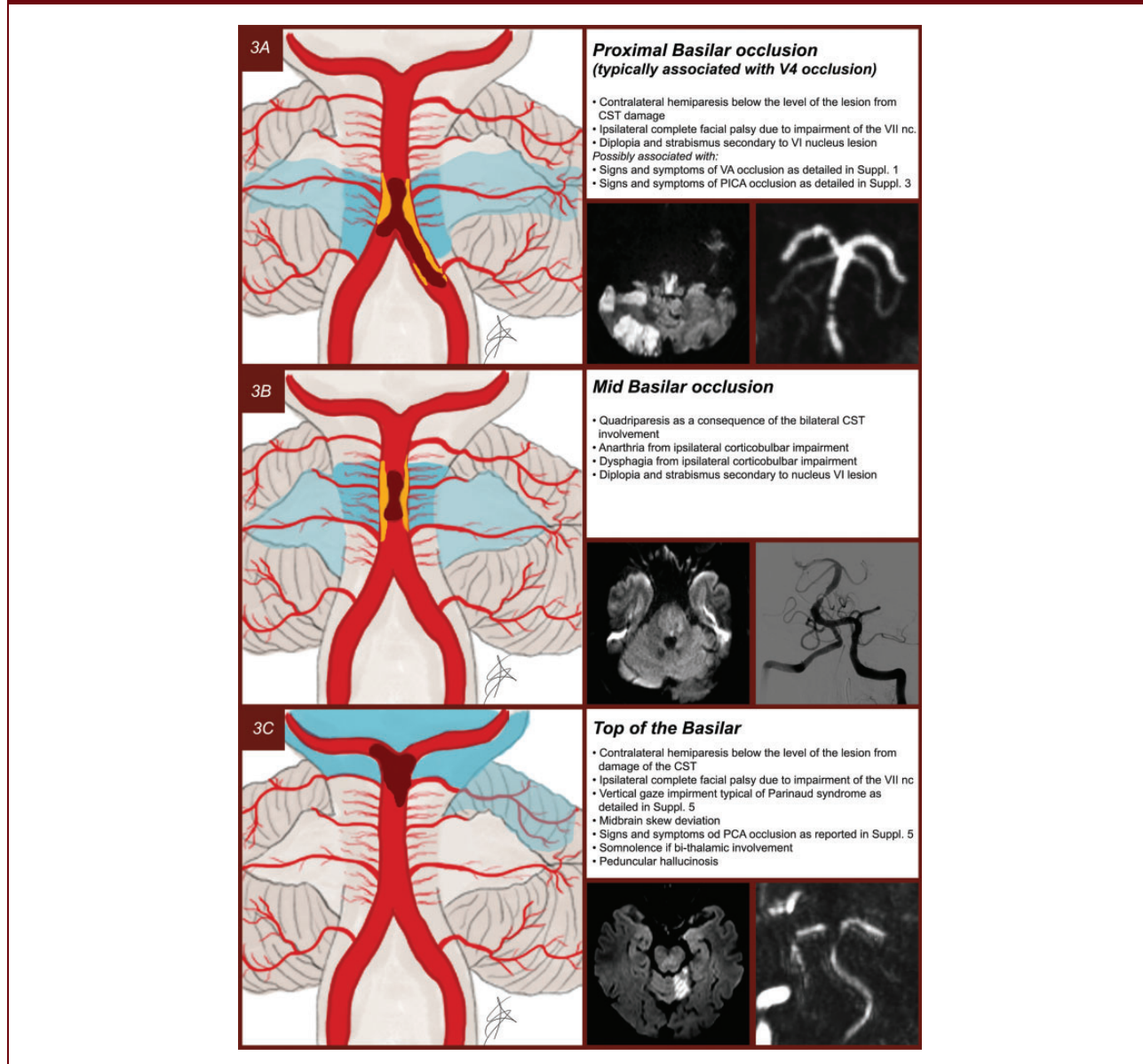
Posterior cerebral artery strokes

Anatomy of the PCA

The BA divides into two PCA terminal branches at the level of the ponto-mesencephalic junction. Each PCA is split into four segments: P1, from the termination of the BA to the origin of the PCom; P2, between the PComs and the posterior margin of the midbrain; P3, from the pulvinar to the anterior limit of the calcarine fissure and P4, the cortical segment within the calcarine fissure becoming the calcarine artery (Supplementary Figure 4).²¹

The PCAs supply blood to the rostral midbrain, the medial and posterolateral regions of the thalamus, the hippocampus and the occipital, temporal and partially the parietal lobes. Historically, we distinguish two main

Figure 3. (a) Proximal BA occlusion usually secondary to atheromathosis of the terminal portion of the VA. (b) Mid BA occlusion usually secondary to atheromathosis of the BA. (c) Top of the basilar occlusion usually secondary to cardioembolism.



territories of vascular supply: a proximal or deep PCA territory, including the thalamus, and a distal or superficial PCA territory, including the hemispheric occipital and temporo-parietal lobes.²²

Clinical presentation of PCA strokes

Infarctions of the PCA territory are usually associated with homonymous visual field defects, especially hemianopia. However, multiple additional symptoms and signs are often present, such as sensory and motor abnormalities and cognitive and neuropsychological

deficits.^{22–24} These infarcts can simulate MCA strokes, particularly in the presence of significant motor deficits.²⁵ The main types of PCA infarctions and their clinical-radiological correlations are summarized in Supplementary Figure 5.

Up to 40% of PCA strokes have concomitant infarcts elsewhere in the PC and sometimes in the carotid territory.²⁴ Among patients with isolated PCA occlusion, the involvement of deep structures varies between 34 and 64% across studies, with the ventrolateral thalamus being the most commonly affected structure.²⁴

Prognosis in posterior circulation strokes

There is little data on the overall prognosis of PC strokes; the largest analysis found comparable long-term outcomes to those of AC strokes after adjustment for the usual prognostic factors.¹ PC strokes arriving later than 4.5 h after last proof of good health seem to have a worse prognosis than late arriving AC strokes.²⁶

Because PC strokes have been underrepresented in randomized trials, their response to acute revascularization is less well known. Whereas the response to thrombolysis seems similar to AC strokes,^{27,28} an effect of EVT is not yet proven.^{29,30}

Prognosis after VA strokes is poorly known, but small studies have shown a high stroke recurrence risk in demonstrated bilateral VA strokes.³¹

Observational studies on cerebellar infarctions reported a rate of functional independence at three months of 69% and a mortality rate of 7%.³² The prognosis mainly depends on the severity of the associated brainstem lesions and on the initial threat of ischemic mass effect. The latter occurs in 10–20% of cases and nearly always involves the PICA territory.³³

Prognosis of BAOs stands out because of the several clinical challenges. Firstly, they may be initially missed clinically as an acutely decreased level of consciousness and absence of lateralizing signs are rather rare in acute stroke.³⁴ Secondly, BAOs have one of the most unfavorable prognoses of all strokes unless early recanalization treatment is associated with rapid clinical improvement. Finally, acute EVT of BAOs still lacks an unequivocal proof of effectiveness.^{29,30}

Clinical outcome after a PCA stroke is critically related to the involvement of the thalamic and brainstem structures, but also the contralateral PCA. PCA strokes are usually regarded as less troublesome than anterior strokes, primarily due to the lower incidence of motor deficits, less mass effect, and lower mortality.³⁵ However, in the long-term, patients with thalamic strokes may be affected by sensory-related sequelae or cognitive and neuropsychiatric disturbances.³⁶ Similarly, in patients with superficial PCA strokes, visual field defects and neuropsychological deficits may remain as disabling consequences. There are no controlled trials of revascularization treatments of the PCA. The largest retrospective study indicated a better cognitive and visual outcome with effective recanalization treatments like EVT.³⁷

Imaging basics of PC strokes

All patients with a suspicion of stroke require urgent brain imaging to confirm the diagnosis, to assess the extent of ischemic damage and to detect the level of vascular occlusion in order to begin adequate therapy.

Imaging can also add prognostic information. Imaging can be done using either computed tomography (CT) or better still, magnetic resonance imaging (MRI) given its higher sensitivity for detecting acute ischemic lesions. MRI is, however, subject to contraindications such as implanted devices or claustrophobia.

CT-based imaging

Non-contrast CT (NCCT) allows a reliable exclusion of hemorrhagic stroke. However, it has very low sensitivity for diagnosing AIS, mainly due to the smaller nature of the lesions and to the skull base-related beam hardening. If lesions are present, the extension of early ischemic changes on CT assessed by the PC Alberta Stroke Program Early CT score (pc-ASPECTs), has demonstrated independent predictive value of patients' outcomes.³⁸ The analysis of computed tomography angiography (CTA) source imaging significantly increases the performance of CT for detecting ischemic changes from 21–46% to 27–65%^{39,40} and improves the prognostic value of pc-ASPECTs.^{39,41} Similarly, adding CT perfusion (CTP) to NCCT and CTA increases the sensitivity and helps to identify patients with predicted worse outcomes.⁴²

MRI-based imaging

Non-contrast MRI with diffusion weighted imaging (DWI) is much more sensitive than NCCT for diagnosing AIS, in particular in the brainstem where lesions are often small.⁴³ The pc-ASPECTs may be performed on DWI and also helps in evaluating patient prognosis.⁴⁴ Still, DWI on the PC may be negative on initial imaging.⁴⁵ In patients initially presenting with acute dizziness/vertigo, PC stroke with negative DWI principally corresponded to ischemia of the medulla and pons followed by ischemia of the cerebellum and midbrain.⁴⁶ One can assume that most negative DWI corresponds to focal infarcts due to small-vessel disease, and some authors reported that the time course of diffusion imaging in brainstem infarct is more than twice as slow as in AC infarct.⁴⁷ Therefore, repeating DWI-imaging in the subacute phase may be useful if the cause of symptoms remains uncertain.

As for the initial CT imaging, adding perfusion weighted imaging (PWI) increases MRI sensitivity.^{45,46} Nonetheless, specific parameter cut-off values to define core, penumbra, and DWI-reversibility remain to be determined for the PC.

Arterial imaging

Beyond detection of cerebral ischemic changes, neuroimaging is required to demonstrate pathologies of the

vertebrobasilar cervical and intracranial arteries. This imaging should be performed in the hyperacute phase using CTA or MRA. To detect vertebral artery stenosis, MRA demonstrated higher sensitivity than CTA or Doppler ultrasound, along with higher specificity.⁴⁸ Moreover, high-resolution two-dimensional and three-dimensional non-contrast fat-sat spin echo T1-weighted sequences may help visualize cervical and intracranial stenosis,⁴⁹ intraplaque hemorrhage,⁵⁰ vertebral wall hematoma⁵¹ as well as determine dissection age.⁵² Contrast-enhanced 3D-BB sequences additionally help to differentiate common cervical arteriopathies such as dissection, atherosclerosis, and vasculitis with an excellent inter-reader reproducibility.⁵³

For BAO, several radiological scores have shown independent prognostic value: the posterior circulation-collateral score (PC-CS), the PC vascular score (pc-CTA), the basilar artery score (BATMAN), and PComs patency score on CTA, in addition to the hyperintense basilar artery sign score on FLAIR and the potential feeding artery score on MRA.^{54–56} Still, harmonization and external validation of these scores, and development of a PC occlusion score beyond BAOs are needed.

Acknowledgements

We would like to thank Melanie Price Hirt, PhD for proofreading.

Authors' contribution

AS was involved in the study concept and design, screened papers for the literature review, realized all anatomical drawings, identified neuroradiological images and prepared the article with input from PM. DS and SN screened papers for the literature review and contributed to preparing the manuscript. VD identified neuroradiological images, screened papers for the literature review, and contributed to preparing the manuscript. PM was involved in the study concept and design and revised the final version of the article.





Declaration of conflicting interests

The author(s) declare no potential conflicts of interest with respect to the research, authorship, and/or publication of this article.

Funding

The author(s) received no financial support for the research, authorship, and/or publication of this article.

ORCID iDs

Alexander Salerno  <https://orcid.org/0000-0001-8494-5527>
 Davide Strambo  <https://orcid.org/0000-0003-4429-2714>
 Stefania Nannoni  <https://orcid.org/0000-0002-1825-1874>
 Patrik Michel  <https://orcid.org/0000-0003-4954-7579>

Supplemental material

Supplemental material for this article is available online.

References

- Zurcher E, Richoz B, Faouzi M and Michel P. Differences in ischemic anterior and posterior circulation strokes: a clinico-radiological and outcome analysis. *J Stroke Cerebrovasc Dis* 2019; 28: 710–718.
- Searls DE, Pazdera L, Korbel E, Vysata O and Caplan LR. Symptoms and signs of posterior circulation ischemia in the new England medical center posterior circulation registry. *Arch Neurol* 2012; 69: 346–351.
- Tao WD, Liu M, Fisher M, et al. Posterior versus anterior circulation infarction: how different are the neurological deficits? *Stroke* 2012; 43: 2060–2065.
- Komaba Y, Mishina M, Utsumi K, Katayama Y, Kobayashi and Mori O. Crossed cerebellar diaschisis in patients with cortical infarction. *Stroke* 2004; 35: 472–476.
- Subramanian G, Silva J, Silver FL, et al. Risk factors for posterior compared to anterior ischemic stroke: an observational study of the Registry of the Canadian Stroke Network. *Neuroepidemiology* 2009; 33: 12–16.
- Inoa V, Aron AW, Staff I, Fortunato G and Sansing LH. Lower NIH stroke scale scores are required to accurately predict a good prognosis in posterior circulation stroke. *Cerebrovasc Dis* 2014; 37: 251–255.
- Zarrinkoob L, Ambarki K, Wahlin A, Birgander R, Eklund A and Malm J. Blood flow distribution in cerebral arteries. *J Cereb Blood Flow Metab* 2015; 35: 648–654.
- Szarazova AS, Bartels E, Bartels S and Turcani P. Possible morphological pathomechanisms of ischemic stroke in the posterior circulation of patients with vertebral artery hypoplasia. *J Neuroimaging* 2015; 25: 408–414.
- Fogwe DT, Sandhu DS, Goyal A, and Mesfin FB. *Neuroanatomy, anterior inferior cerebellar arteries*. Treasure Island, FL: StatPearls, 2020.
- Tatu L, Moulin T, Vuillier F and Bogousslavsky J. Arterial territories of the human brain. *Front Neurol Neurosci* 2012; 30: 99–110.
- Terao S, Miura N, Osano Y, Noda A and Sobue G. Rapidly progressive fatal respiratory failure (Ondine's curse) in the lateral medullary syndrome. *J Stroke Cerebrovasc Dis* 2004; 13: 41–44.
- Marinkovic SV and Gibo H. The surgical anatomy of the perforating branches of the basilar artery. *Neurosurgery* 1993; 33: 80–87.
- Schonewille WJ, Wijman CA, Michel P, et al. Treatment and outcomes of acute basilar artery occlusion in the Basilar Artery International Cooperation Study (BASICS): a prospective registry study. *Lancet Neurol* 2009; 8: 724–730.
- Baran G, Gultekin TO, Baran O, et al. Association between etiology and lesion site in ischemic brainstem infarcts: a retrospective observational study. *Neuropsychiatr Dis Treat* 2018; 14: 757–766.
- Mattle HP, Arnold M, Lindsberg PJ, Schonewille WJ and Schroth G. Basilar artery occlusion. *Lancet Neurol* 2011; 10: 1002–1014.

16. Caplan LR. "Top of the basilar" syndrome. *Neurology* 1980; 30: 72.
17. Ahn SH, Kim BJ, Kim YJ, Kang DW, Kwon SU and Kim JS. Patterns and outcomes of the top of the basilar artery syndrome: the role of the posterior communicating artery. *Cerebrovasc Dis* 2018; 46: 108–117.
18. Amarenco P, Hauw JJ and Gautier JC. Arterial pathology in cerebellar infarction. *Stroke* 1990; 21: 1299–1305.
19. Tohgi H, Takahashi S, Chiba K and Hirata Y. Cerebellar infarction. Clinical and neuroimaging analysis in 293 patients. The Tohoku Cerebellar Infarction Study Group. *Stroke* 1993; 24: 1697–1701.
20. Barth A, Bogousslavsky J and Regli F. The clinical and topographic spectrum of cerebellar infarcts: a clinical-magnetic resonance imaging correlation study. *Ann Neurol* 1993; 33: 451–456.
21. Percheron G. The anatomy of the arterial supply of the human thalamus and its use for the interpretation of the thalamic vascular pathology. *Z Neurol* 1973; 205: 1–13.
22. Brandt T, Steinke W, Thie A, Pessin MS and Caplan LR. Posterior cerebral artery territory infarcts: clinical features, infarct topography, causes and outcome. Multicenter results and a review of the literature. *Cerebrovasc Dis* 2000; 10: 170–182.
23. Kumral E, Bayulkem G, Atac C and Alper Y. Spectrum of superficial posterior cerebral artery territory infarcts. *Eur J Neurol* 2004; 11: 237–246.
24. Lee E, Kang DW, Kwon SU and Kim JS. Posterior cerebral artery infarction: diffusion-weighted MRI analysis of 205 patients. *Cerebrovasc Dis* 2009; 28: 298–305.
25. Maulaz AB, Bezerra DC and Bogousslavsky J. Posterior cerebral artery infarction from middle cerebral artery infarction. *ArchNeurol* 2005; 62: 938–941.
26. Sommer P, Posekany A, Serles W, et al. Is functional outcome different in posterior and anterior circulation stroke? *Stroke* 2018; 49: 2728–2732.
27. Schonewille WJ, Wijman CA, Michel P, et al. Treatment and outcomes of acute basilar artery occlusion in the Basilar Artery International Cooperation Study (BASICS): a prospective registry study. *Lancet Neurol* 2009; 8: 724–730.
28. Sarikaya H, Arnold M, Engelter ST, et al. Outcomes of intravenous thrombolysis in posterior versus anterior circulation stroke. *Stroke* 2011; 42: 2498–2502.
29. Liu X, Dai Q, Ye R, et al. Endovascular treatment versus standard medical treatment for vertebrobasilar artery occlusion (BEST): an open-label, randomised controlled trial. *Lancet Neurol* 2020; 19: 115–122.
30. Langezaal LCM, van der Hoeven E, Mont'Alverne FJA, et al. Endovascular therapy for stroke due to basilar-artery occlusion. *N Engl J Med* 2021; 384: 1910–1920.
31. Tariq N, Maud A, Shah QA, Suri MF and Qureshi AI. Clinical outcome of patients with acute posterior circulation stroke and bilateral vertebral artery occlusion. *J Vasc Interv Neurol* 2011; 4: 9–14.
32. Edlow JA, Newman-Toker DE and Savitz SI. Diagnosis and initial management of cerebellar infarction. *Lancet Neurol* 2008; 7: 951–964.
33. Jauss M, Krieger D, Hornig C, Schramm J and Busse O. Surgical and medical management of patients with massive cerebellar infarctions: results of the German-Austrian Cerebellar Infarction Study. *J Neurol* 1999; 246: 257–264.
34. Richoz B, Hugli O, Dami F, Carron PN, Faouzi M and Michel P. Acute stroke chameleons in a university hospital: Risk factors, circumstances, and outcomes. *Neurology* 2015; 85: 505–511.
35. Arboix A, Arbe G, Garcia-Eroles L, Oliveres M, Parra O and Massons J. Infarctions in the vascular territory of the posterior cerebral artery: clinical features in 232 patients. *BMC Res Notes* 2011; 4: 329.
36. Schmahmann JD. Vascular syndromes of the thalamus. *Stroke* 2003; 34: 2264–2278.
37. Strambo D, Bartolini B, Beaud V, et al. Thrombectomy and thrombolysis of isolated posterior cerebral artery occlusion: cognitive, visual, and disability outcomes. *Stroke* 2020; 51: 254–261.
38. Wu PH, Rodriguez-Soto AE, Rodgers ZB, et al. MRI evaluation of cerebrovascular reactivity in obstructive sleep apnea. *J Cereb Blood Flow Metab* 2020; 40: 1328–1337.
39. Puetz V, Sylaja PN, Coutts SB, et al. Extent of hypoattenuation on CT angiography source images predicts functional outcome in patients with basilar artery occlusion. *Stroke* 2008; 39: 2485–2490.
40. van der Hoeven EJ, Dankbaar JW, Algra A, et al. Additional diagnostic value of computed tomography perfusion for detection of acute ischemic stroke in the posterior circulation. *Stroke* 2015; 46: 1113–1115.
41. Puetz V, Khomenko A, Hill MD, et al. Extent of hypoattenuation on CT angiography source images in basilar artery occlusion: prognostic value in the Basilar Artery International Cooperation Study. *Stroke* 2011; 42: 3454–3459.
42. Pallesen LP, Lambrou D, Eskandari A, et al. Perfusion computed tomography in posterior circulation stroke: predictors and prognostic implications of focal hypoperfusion. *Eur J Neurol* 2018; 25: 725–731.
43. Chalela JA, Kidwell CS, Nentwich LM, et al. Magnetic resonance imaging and computed tomography in emergency assessment of patients with suspected acute stroke: a prospective comparison. *Lancet* 2007; 369: 293–298.
44. Yoon W, Kim SK, Heo TW, Baek BH, Lee YY and Kang HK. Predictors of good outcome after stent-retriever thrombectomy in acute basilar artery occlusion. *Stroke* 2015; 46: 2972–2975.
45. Simonsen CZ, Madsen MH, Schmitz ML, Mikkelsen IK, Fisher M and Andersen G. Sensitivity of diffusion- and perfusion-weighted imaging for diagnosing acute ischemic stroke is 97.5%. *Stroke* 2015; 46: 98–101.
46. Choi JH, Oh EH, Park MG, et al. Early MRI-negative posterior circulation stroke presenting as acute dizziness. *J Neurol* 2018; 265: 2993–3000.
47. Axer H, Grassel D, Bramer D, et al. Time course of diffusion imaging in acute brainstem infarcts. *J Magn Reson Imaging* 2007; 26: 905–912.
48. Khan S, Rich P, Clifton A and Markus HS. Noninvasive detection of vertebral artery stenosis: a comparison of

- contrast-enhanced MR angiography, CT angiography, and ultrasound. *Stroke* 2009; 40: 3499–3503.
49. Tian X, Tian B, Shi Z, et al. Assessment of intracranial atherosclerotic plaques using 3D black-blood MRI: comparison with 3D time-of-flight MRA and DSA. *J Magn Reson Imaging* 2021; 53: 469–478.
 50. Zhu C, Tian X, Degnan AJ, et al. Clinical significance of intraplaque hemorrhage in low- and high-grade basilar artery stenosis on high-resolution MRI. *AJNR Am J Neuroradiol* 2018; 39: 1286–1292.
 51. Takano K, Yamashita S, Takemoto K, Inoue T, Kuwabara Y and Yoshimitsu K. MRI of intracranial vertebral artery dissection: evaluation of intramural haematoma using a black blood, variable-flip-angle 3D turbo spin-echo sequence. *Neuroradiology* 2013; 55: 845–851.
 52. Habs M, Pfefferkorn T, Cyran CC, et al. Age determination of vessel wall hematoma in spontaneous cervical artery dissection: a multi-sequence 3T cardiovascular magnetic resonance study. *J Cardiovasc Magn Reson* 2011; 13: 76.
 53. Schwarz F, Strobl FF, Cyran CC, et al. Reproducibility and differentiation of cervical arteriopathies using in vivo high-resolution black-blood MRI at 3 T. *Neuroradiology* 2016; 58: 569–576.
 54. van der Hoeven EJ, McVerry F, Vos JA, et al. Collateral flow predicts outcome after basilar artery occlusion: the posterior circulation collateral score. *Int J Stroke* 2016; 11: 768–775.
 55. Alemseged F, Shah DG, Diomedes M, et al. The basilar artery on computed tomography angiography prognostic score for basilar artery occlusion. *Stroke* 2017; 48: 631–637.
 56. Goyal N, Tsivgoulis G, Nickle C, et al. Posterior circulation CT angiography collaterals predict outcome of endovascular acute ischemic stroke therapy for basilar artery occlusion. *J Neurointerv Surg* 2016; 8: 783–786.