

Surgical Management of Dysplasia and Cancer in Inflammatory Bowel Disease



James Ansell, MD^a, Fabian Grass, MD^a, Amit Merchea, MD^{b,*}

KEYWORDS

• Crohn • Ulcerative colitis • Cancer • Dysplasia

KEY POINTS

- Patients with inflammatory bowel disease (IBD) and high-grade dysplasia, multifocal low-grade dysplasia and nonadenoma dysplasia-associated mass or lesion, high-grade or invasive cancer should undergo total proctocolectomy.
- Segmental resection in IBD–colorectal cancer (CRC) has a limited role because of the risk of developing secondary malignancies in other areas of colon.
- Ileal pouch anal anastomosis (IPAA) surgery for ulcerative colitis restores intestinal continuity and is associated with a very small risk of pouch neoplasia. High-risk patients with a history of dysplasia or CRC before IPAA should undergo pouchoscopy with biopsy every 1 to 3 years.
- IPAA surgery should not be considered in patients with a history of pelvic radiation, and indications for pouch excision include biopsy-confirmed high-grade dysplasia or synchronous cancer.

INTRODUCTION

Chronic inflammatory bowel disease (IBD) is characterized by recurrent episodes of mucosal inflammation, which can lead to an increased risk of dysplasia and cancer.¹ It is nearly a century since Crohn and Rosenberg² published their data linking IBD with colorectal cancer (CRC). A 2001 meta-analysis reported the overall IBD–CRC risk was 3 per 1000 per year and 2%, 8% and 18% in the first, second, and third decades after diagnosis, respectively.³ More than a decade later, this risk has decreased to 1.69 per 1000 per year, possibly because of improved early detection and surveillance, earlier

Disclosure: The authors declare no relationship with a commercial company that has a direct financial interest in subject matter or materials discussed in the article or with a company making a competing product.

^a Division of Colon and Rectal Surgery, Mayo Clinic, 200 First Street Southwest, Rochester, MN 55905, USA; ^b Division of Colon and Rectal Surgery, Mayo Clinic, 4500 San Pablo Road South, Jacksonville, FL 32224, USA

* Corresponding author.

E-mail address: Merchea.Amit@mayo.edu

Surg Clin N Am 99 (2019) 1111–1121
<https://doi.org/10.1016/j.suc.2019.08.006>

surgical.theclinics.com

0039-6109/19/© 2019 Elsevier Inc. All rights reserved.

surgical intervention in medically refractory disease, and the introduction of chemoprotective aminosalicytes.^{4,5}

The overall incidence of IBD-CRC is 2.5%, but this varies based on the site of inflammation.^{4,6} Colonic Crohn's disease (CD) is associated with CRC (relative risk, 4.5 [1.3–14.9]), but ileal CD is not (relative risk, 1.1 [0.8–1.5]).^{4,6} The cumulative risk of CRC in CD at 10, 20, and 30 years after diagnosis is 2.9%, 5.6%, and 8.3%, respectively.

The cause and presentation of IBD-CRC differs from that of sporadic CRC. Sporadic disease is linked to the predictable adenoma-carcinoma sequence, but IBD-CRC is driven by cellular damage from chronic inflammation and does not follow in such an orderly fashion.^{7,8} IBD-CRC tends to present at a younger age compared with sporadic disease (mean, 40–50 years vs 60 years)⁹ and may arise in flat mucosa that is more difficult to visualize.¹⁰

Risk factors for IBD-CRC include a younger age at onset, duration greater than 8 years, extent of colitis, and the degree of endoscopic and histologic inflammation.^{11,12} Other risks include primary sclerosing cholangitis (PSC) (odds ratio, 4.8; 95% confidence interval [CI], 3.6–6.4)¹³ and a positive family history of CRC.¹⁴

Previous work by our group detailed the risk, pathogenesis, surveillance, and management of IBD dysplasia and CRC.¹⁵ This article focuses on the surgical approach to IBD dysplasia and CRC.

COLORECTAL CANCER SCREENING

Current data on the survival benefit for screening in IBD are sparse, with a Cochrane Review failing to show a benefit,¹⁶ so our review focuses on expert panel consensus.¹²

Most current guidelines recommend starting surveillance colonoscopy 6 to 10 years after the diagnosis of IBD, with surveillance colonoscopy every 1 to 2 years.^{17–21} In the presence of coexisting PSC, patients should undergo colonoscopy followed by yearly surveillance.¹⁷ Of note, PSC may be an indication for prophylactic colectomy, although the relative risk of IBD-CRC is lower in CD than in ulcerative colitis (UC).²²

Surveillance technique normally involves 2 sets of 4-quadrant biopsies in each colon segment (right, transverse, left, rectosigmoid), producing more than 32 random biopsies, providing an 80% to 90% sensitivity for dysplasia.^{23–25} Directed biopsies of polypoid lesions, masses, strictures, or irregular mucosa should also be performed.^{23,26,27}

Recent research has shown that dysplasia may be better identified with advanced endoscopic imaging and targeted biopsies rather than random biopsies.^{28–30}

Advanced Endoscopic Imaging

Chromoendoscopy (CE) uses a dye agent such as indigo carmine or methylene blue to enhance the detection of mucosal lesions.^{30,31} This technique improves flat dysplastic lesion detection by 27%.^{32,33} At present, most expert societies recommend the use of CE with targeted biopsies whenever the technology and expertise are available, particularly for high-risk patients.³³

Digital or optical imaging technology, such as narrow band imaging (NBI; Olympus, Tokyo, Japan), uses specific light wavelengths that penetrate only the superficial mucosa to better delineate mucosal vasculature without the use of dyes,^{34,35} but this has not been shown to provide a benefit in neoplasia detection rates.³⁶ Compared with chromoendoscopy, NBI is associated with a higher miss rate for neoplasia, and is not recommended for IBD surveillance.³⁵

High-resolution endoscopy and endocytoscopy are emerging areas of interest for endoscopic surveillance, but have yet to show improved detection of neoplasia compared with conventional endoscopy.^{37–43}

MANAGEMENT OF INFLAMMATORY BOWEL DISEASE–RELATED DYSPLASIA, CANCER, AND STRICTURES

Dysplasia can be microscopically classified into low-grade dysplasia (LGD), high-grade dysplasia (HGD), or indefinite for dysplasia depending on the degree of preservation or loss of cellular polarity reflected by nuclear stratification.⁴⁴ Dysplasia identified on random biopsies must be confirmed by 2 gastrointestinal pathologists. One of the most important determinants in managing patients with raised dysplastic lesions is whether the dysplasia is completely resectable.⁴⁴ If a lesion is nonresectable because of size, fixation, or adjacent dysplasia, it is referred to as a dysplasia-associated lesion or mass (DALM). DALMs can be further divided into adenomalike (polypoid) and nonadenomalike (nonpolypoid).⁴⁵

Adenomalike DALMs tend to behave like sporadic adenomas and can be safely treated with polypectomy, tattoo, and continued surveillance,⁴⁶ a strategy associated with a low risk of progression to CRC (2.4% of patients after an average follow-up of 54 months).⁴⁷ However, if biopsy of the surrounding tissue identifies dysplasia, colectomy is recommended because of the high risk of associated CRC.^{10,29,47}

Nonadenomalike DALMs can appear as velvety patches, plaques, irregular bumps and nodules, wartlike thickenings, stricturing lesions, or broad-based masses.⁴⁵ These flat DALMs are usually not amenable to endoscopic removal, and they have a 9-fold risk of developing cancer and a 12-fold risk of developing any advanced lesion,⁴⁸ so surgical resection is usually warranted.

Low-Grade Dysplasia

The management of unifocal, flat LGD in the setting of IBD remains controversial. Historically, the literature reports widely variable rates of progression to HGD, ranging from 0% to 53%.¹⁰ Studies performed in the era of chromoendoscopy show that most patients with LGD do not progress to HGD over 3 to 4 years of follow-up.

Areas of LGD that are nonpolypoid, endoscopically invisible, 1 cm or larger, or preceded by indefinite dysplasia are at increased risk for progression and should be considered for colectomy.²⁰ Other considerations for colectomy include metachronous LGD after endoscopic removal and multifocal disease.²⁰

High-Grade Dysplasia

In HGD the risk of harboring an underlying invasive malignancy can be greater than 40%.⁴⁹ Therefore, HGD has traditionally warranted surgical resection. However, there are emerging data suggesting that discrete areas of HGD can be safely removed via endoscopy, avoiding major surgery.^{50,51} In 2015, the Surveillance for Colorectal Endoscopic Neoplasia Detection and Management in Inflammatory Bowel Disease Patients: International Consensus Recommendations (SCENIC) panel stated that, if dysplasia is not detected on follow-up, a decision regarding surveillance or colectomy can be individualized.⁵² This statement is in contrast with the European Crohn's and Colitis Organization and The American Society for Gastrointestinal Endoscopy, which state that HGD without an associated endoscopically visible lesion is an indication for surgery.²¹

Strictures

Colonic strictures develop in 5% to 10% of patients with IBD and should be routinely biopsied because of an increased risk of CRC (hazard ratio, 18.8).^{23,53,54} A negative biopsy may not completely rule out this risk because of sampling error and the more infiltrative nature of colitis-associated malignancies. All IBD strictures require surveillance and those that cannot be traversed and biopsied should be considered for surgical resection.⁵⁵

SURGICAL OPTIONS

As with any cancer, when an IBD-CRC is found during screening or surveillance colonoscopy, preoperative staging is performed to inform appropriate treatment strategies.⁵⁶

Ulcerative Colitis

In the elective setting, findings of IBD-CRC, a nonadenoma DALM, or HGD are almost uniformly accepted as indications for proctocolectomy with or without ileal pouch anal anastomosis (IPAA),²³ because 43% to 50% have associated malignancy at the time of colectomy.^{49,57,58} The technical aspects of surgery for IBD-CRC mirror the approach to sporadic disease, and include high ligation of major colonic vessels and total mesorectal excision.⁵⁹

In select cases, the rectum can be spared, and an ileorectal anastomosis can be performed. Although this surgery is usually less extensive, the risk of anastomotic leak is up to 13% in some studies.⁶⁰ A further issue is the cumulative risk of developing dysplasia in the retained rectum (5, 10, 15, 20 years is 7%, 9%, 20%, 25% respectively) and cancer (5, 10, 15, 20 years is 0%, 2%, 5%, 14% respectively).^{61,62}

Segmental resection also has a limited role in UC because of the risk of developing secondary malignancies in other areas of colon.¹⁰ Previous reports have shown that 12% to 55% of patients have an occult or synchronous cancer and 48% have synchronous dysplasia.^{10,63,64}

Ileal Pouch Anal Anastomosis in Inflammatory Bowel Disease Colorectal Cancer

In 1978, Parks and Nicholls⁶⁵ published the technique of ileoanal pouch surgery in the *British Medical Journal*.⁶⁶ This technique is usually accomplished in either a 2-stage or 3-stage procedure. The ultimate result with IPAA involves forming a J-shaped pouch from the terminal ileum in order to replace the function of the rectum. The presence of UC-related dysplasia or cancer is not a contraindication to IPAA.

The most common method of creating an IPAA is a double-stapled technique with a distal rectal anastomosis, preserving the anal transition zone (ATZ)⁶⁶ (**Fig. 1**). This method leaves a cuff of residual columnar mucosa at the ATZ, which theoretically has the potential risk of future malignancy. The alternative method of IPAA creation involves performing a mucosectomy of the anal canal and a hand-sewn ileoanal anastomosis (**Fig. 2**). A double-stapled technique has better functional outcomes compared with a hand-sewn IPAA⁶⁷; 2 randomized trials have shown reduced levels of nocturnal fecal incontinence with the double-stapled technique. Furthermore, occasional or frequent episodes of incontinence have been reported in 64% of hand-sewn groups compared with 38% of the stapled groups.^{67–69}

With either technique, there is a small risk of subsequent dysplasia. A 2003 study of 289 patients undergoing a double-stapled IPAA found a 4.5% incidence of dysplasia in the residual ATZ at 10 years.⁷⁰ One 2011 review showed 43 known cases of dysplasia and cancer, including 30 patients with mucosectomy and 13 with a stapled

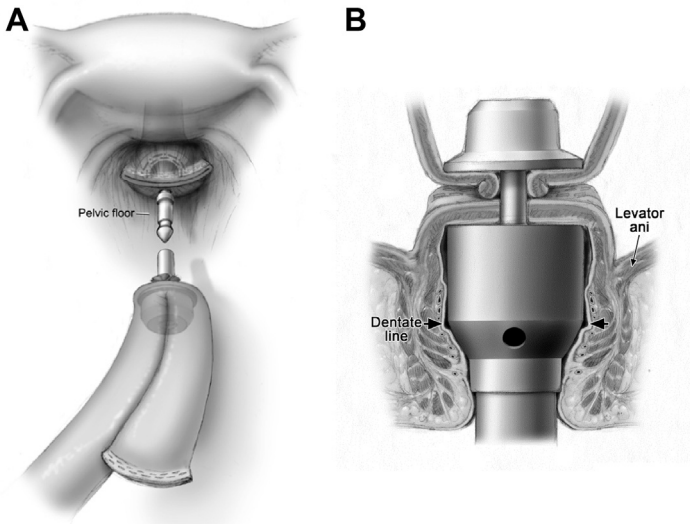


Fig. 1. Double-stapled technique for IPAA creation. (A) Intraabdominal view; (B) coronal anal of view IPAA creation with circular stapler. (Used with permission of Mayo Foundation for Medical Education and Research, all rights reserved.)

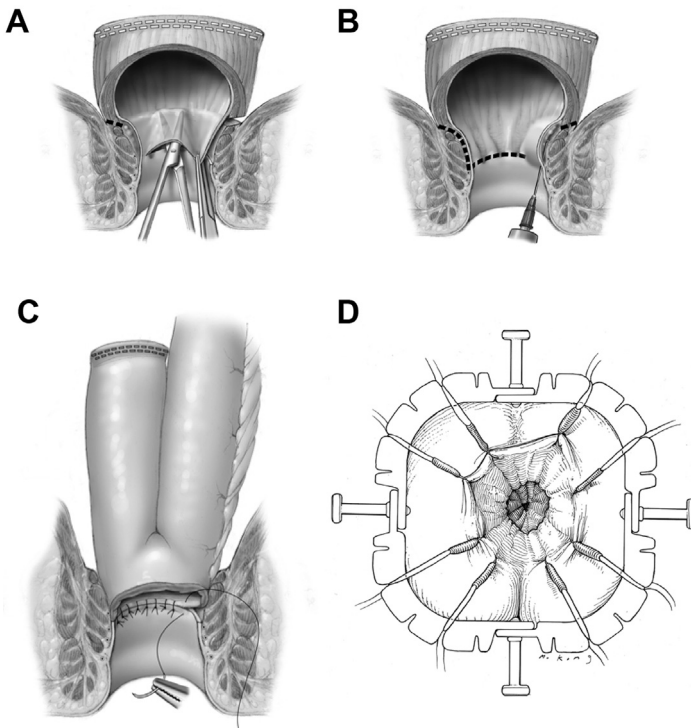


Fig. 2. Mucosectomy and hand-sewn ileoanal anastomosis. (A) Raising submucosal plain; (B) excision of mucosa; (C) suturing of pouch-anal anastomosis; (D) external view of hand-sewn pouch-anal anastomosis. (Used with permission of Mayo Foundation for Medical Education and Research, all rights reserved.)

anastomosis.⁷¹ Another study of 1200 patients with IBD-related IPAA found that 1.83% developed pouch neoplasia, including 16 adenocarcinomas.⁷² A similar review from Cleveland Clinic of 3202 patients reported that the cumulative incidences for pouch neoplasia at 5, 10, 15, and 20 years were 0.9%, 1.3%, 1.9%, and 4.2%.^{10,73} Eleven (0.36%) patients developed adenocarcinoma of the anal canal or pouch.⁷³ The only independent risk factor for pouch neoplasia was a history of dysplasia or CRC before IPAA.⁷³

Ileal Pouch Anal Anastomosis in Inflammatory Bowel Disease Colorectal Cancer and Radiation

Special consideration should be taken for patients with UC with locally advanced rectal cancer. Preoperative pelvic radiation can affect pouch-related sepsis and long-term pouch function.⁷⁴ Wu and colleagues⁷⁴ studied 63 IPAA patients with IBD-CRC and found that preoperative radiation was associated with chronic pouchitis. In the same study, pouch failure occurred in 13 patients after a median follow-up of 66.4 months.⁷⁴ The investigators showed a strong association between preoperative pelvic radiation and the risk for pouch failure ($P < .001$), but there was no correlation between pelvic radiation and pouch/anal transitional zone neoplasia, pouch stricture, pelvic abscess, and pouch fistula/sinus.⁷⁴

Postoperative pelvic radiation after IPAA is even more significant and rarely allows acceptable pouch function. In 2012, Merchea and colleagues⁷⁵ published on 41 patients with UC and rectal cancer, which included 11 patients undergoing IPAA. Two patients had a failed pouch, 1 of which was secondary to radiation enteritis.⁷⁵ The conclusion of this study was that rectal cancer not requiring neoadjuvant chemoradiotherapy can safely undergo restorative proctocolectomy with good functional results.⁷⁵ Patients who require pelvic radiation or who have stage IV disease may be better served with proctocolectomy and end ileostomy.⁷⁵

Crohn's Disease

Patients with CD and HGD, multifocal LGD, a nonadenoma DALM, or invasive cancer should undergo total proctocolectomy.⁷⁶ Approximately 40% of patients with CD undergoing segmental resection or subtotal colectomy develop metachronous cancers.⁷⁶ Approximately 44% of patients with known malignancy have multifocal disease in the final specimen and 40% have evidence of dysplasia remote from the cancer site.⁷⁶ In general, IPAA formation in the setting of CD is not recommended because it is associated with poor function and high failure rates. In highly selected patients who are not willing to have a permanent end ileostomy and have so-called rectal sparing with no active inflammation or dysplasia within the rectum, a total abdominal colectomy with ileorectal anastomosis can be considered as long as there is intense postoperative surveillance.

LONG-TERM OUTCOMES

As with sporadic CRC, in IBD-CRC the prognosis and survival depend on stage of disease and response to treatment. A study from the Mayo Clinic in 2006 comparing IBD-CRC ($n = 290$) and sporadic CRC ($n = 290$) over 20 years showed comparable 5-year survival (54% in IBD-CRC and 53% in sporadic CRC).^{10,76} Several more recently published articles have also confirmed that IBD-associated CRCs have comparable rates of tumor recurrence and survival following postoperative chemotherapy with patients with CRC without IBD.⁷⁷ For metastatic disease, the situation may be different. Recent work from Memorial Sloan Kettering Cancer Center case matched 18 patients with

metastatic IBD-CRC with sporadic cases. Median overall survival was significantly worse in the IBD-related group (15 months vs 34 months).⁷⁸

SUMMARY

Patients with IBD are at an increased risk of cancer secondary to long-standing intestinal inflammation. Surgical options must take into account the significant risk of synchronous disease at other colonic sites. IPAA is a viable option for patients with UC but this should be restricted to early cancers that are unlikely to require preoperative or postoperative radiation treatment.

REFERENCES

1. Dulai PS, Sandborn WJ, Gupta S. Colorectal Cancer and Dysplasia in Inflammatory Bowel Disease: A Review of Disease Epidemiology, Pathophysiology, and Management. *Cancer Prev Res (Phila)* 2016;9(12):887–94.
2. Crohn BB, Rosenberg B. The sigmoidoscopic picture of chronic ulcerative colitis (nonspecific). *Am J Med Sci* 1925;170:220–7.
3. Eaden JA, Abrams KR, Mayberry JF. The risk of colorectal cancer in ulcerative colitis: a meta-analysis. *Gut* 2001;48:526–35.
4. Wang ZH, Fang JY. Colorectal Cancer in Inflammatory Bowel Disease: Epidemiology, Pathogenesis and Surveillance. *Gastrointest Tumors* 2014;1(3):146–54.
5. Castaño-Milla C, Chaparro M, Gisbert JP. Systematic review with meta-analysis: the declining risk of colorectal cancer in UC. *Aliment Pharmacol Ther* 2014;39(7):1001–2.
6. Canavan C, Abrams KR, Mayberry J. Meta-analysis: colorectal and small bowel cancer risk in patients with Crohn's disease. *Aliment Pharmacol Ther* 2006;23:1097–104.
7. Grivennikov SI. Inflammation and colorectal cancer: colitis-associated neoplasia. *Semin Immunopathol* 2012;35(2):229–44.
8. Fearon ER, Vogelstein B. A genetic model for colorectal Tumorigenesis. *Cell* 1990;61(5):759–67.
9. Munkholm P. Review article: the incidence and prevalence of colorectal cancer in inflammatory bowel disease. *Aliment Pharmacol Ther* 2003;18(Suppl 2):1–5.
10. Althumairi AA, Lazarev MG, Gearhart SL. Inflammatory bowel disease associated neoplasia: a surgeon's perspective. *World J Gastroenterol* 2016;22(3):961–73.
11. Kim ER, Chang DK. Colorectal cancer in inflammatory bowel disease: the risk, pathogenesis, prevention and diagnosis. *World J Gastroenterol* 2014;20(29):9872–81.
12. Mattar MC, Lough D, Pishvaian MJ, et al. Current management of inflammatory bowel disease and colorectal cancer. *Gastrointest Cancer Res* 2011;4(2):53–61.
13. Andersen NN, Jess T. Has the risk of colorectal cancer in inflammatory bowel disease decreased? *World J Gastroenterol* 2013;19(43):7561–8.
14. Askling J, Dickman PW, Karlén P, et al. Family history as a risk factor for colorectal cancer in inflammatory bowel disease. *Gastroenterology* 2001;120(6):1356–62.
15. Huang LC, Merchea A. Dysplasia and Cancer in Inflammatory Bowel Disease. *Surg Clin North Am* 2017;97(3):627–39.
16. Mpopfu C, Watson AJM, Rhodes JM. Strategies for detecting colon cancer and/or dysplasia in patients with inflammatory bowel disease. *Cochrane Database Syst Rev* 2004;(2). John Wiley & Sons, Ltd, CD000279.
17. Guagnozzi D, Lucendo AJ. Colorectal cancer surveillance in patients with inflammatory bowel disease: What is new? *World J Gastrointest Endosc* 2012;4(4):108–16.

18. Itzkowitz SH, Present DH. Consensus conference: Colorectal cancer screening and surveillance in inflammatory bowel disease. *Inflamm Bowel Dis* 2005;11:314–21.
19. Bae SI, Kim YS. Colon cancer screening and surveillance in inflammatory bowel disease. *Clin Endosc* 2014;47(6):509–15.
20. Choi CH, Ignjatovic-Wilson A, Askari A, et al. Low-grade dysplasia in ulcerative colitis: risk factors for developing high-grade dysplasia or colorectal cancer. *Am J Gastroenterol* 2015;110(10):1461–71.
21. Huguet JM, Suárez P, Ferrer-Barceló L, et al. Endoscopic recommendations for colorectal cancer screening and surveillance in patients with inflammatory bowel disease: Review of general recommendations. *World J Gastrointest Endosc* 2017;9(6):255–62.
22. Broomé U, Löfberg R, Veress B, et al. Primary sclerosing cholangitis and ulcerative colitis: evidence for increased neoplastic potential. *Hepatology* 1995;22:1404–8.
23. Ross H, Steele SR, Varma M, et al. Practice Parameters for the Surgical Treatment of Ulcerative Colitis. *Dis Colon Rectum* 2014;57:5–22.
24. Awais D, Siegel CA, Higgins PD. Modelling dysplasia detection in ulcerative colitis: clinical implications of surveillance intensity. *Gut* 2009;58:1498–503.
25. Rubin CE, Haggitt RC, Burmer GC, et al. DNA aneuploidy in colonic biopsies predicts future development of dysplasia in ulcerative colitis. *Gastroenterology* 1992;103:1611–20.
26. Blonski W, Kundu R, Lewis J, et al. Is dysplasia visible during surveillance colonoscopy in patients with ulcerative colitis? *Scand J Gastroenterol* 2008;43:698–703.
27. Rubin DT, Rothe JA, Hetzel JT, et al. Are dysplasia and colorectal cancer endoscopically visible in patients with ulcerative colitis? *Gastrointest Endosc* 2007;65:998–1004.
28. Watanabe T, Ajioka Y, Mitsuyama K, et al. Comparison of Targeted vs Random Biopsies for Surveillance of Ulcerative Colitis-Associated Colorectal Cancer. *Gastroenterology* 2016;151:1122–30.
29. Rutter MD, Saunders BP, Wilkinson KH, et al. Most dysplasia in ulcerative colitis is visible at colonoscopy. *Gastrointest Endosc* 2004;6:334–9.
30. Trivedi PJ, Braden B. Indications, stains and techniques in chromoendoscopy. *QJM* 2012;106(2):117–31.
31. Barkin JA, Sussman DA, Abreu MT. Chromoendoscopy and advanced imaging technologies for surveillance of patients with IBD. *Gastroenterol Hepatol (N Y)* 2012;8(12):796–802.
32. Subramanian V, Mannath J, Ragunath K, et al. Meta-analysis: the diagnostic yield of chromoendoscopy for detecting dysplasia in patients with colonic inflammatory bowel disease. *Aliment Pharmacol Ther* 2011;33(3):304–12.
33. Shukla R, Salem M, Hou JK. Use and barriers to chromoendoscopy for dysplasia surveillance in inflammatory bowel disease. *World J Gastrointest Endosc* 2017;9(8):359–67.
34. Cho WY, Jang JY, Lee DH, Endoscopic Technology and Investigation Study Group. Recent Advances in Image-enhanced Endoscopy. *Clin Endosc* 2011;44(2):65–75.
35. Pellisé M, López-Cerón M, Rodríguez de Miguel C, et al. Narrow-band imaging as an alternative to chromoendoscopy for the detection of dysplasia in long-standing inflammatory bowel disease: a prospective, randomized, crossover study. *Gastrointest Endosc* 2011;74(4):840–8.

36. Dekker E, van den Broek FJ, Reitsma JB, et al. Narrow-band imaging compared with conventional colonoscopy for the detection of dysplasia in patients with long-standing ulcerative colitis. *Endoscopy* 2007;39:216–21.
37. Galli J, Cammarota G, Rigante M, et al. High resolution magnifying endoscopy: a new diagnostic tool also for laryngeal examination? *Acta Otorhinolaryngol Ital* 2007;27(5):233–6.
38. Kiesslich R, Goetz M, Neurath MF. Confocal laser endomicroscopy for gastrointestinal diseases. *Gastrointest Endosc Clin N Am* 2008;18:451–66.
39. Kim ES. Role of Advanced Endoscopic Imaging Techniques in the Management of Inflammatory Bowel Disease. *Clin Endosc* 2017;50(5):424–8.
40. Beintaris I, Rutter M. Advanced imaging in colonoscopy: contemporary approach to dysplasia surveillance in inflammatory bowel disease. *Frontline Gastroenterol* 2016;7(4):308–15.
41. Günther U, Kusch D, Heller F, et al. Surveillance colonoscopy in patients with inflammatory bowel disease: comparison of random biopsy vs. targeted biopsy protocols. *Int J Colorectal Dis* 2011;26:667–72.
42. Freire P, Figueiredo P, Cardoso R. Surveillance in ulcerative colitis: is chromoendoscopy-guided endomicroscopy always better than conventional colonoscopy? A randomized trial. *Inflamm Bowel Dis* 2014;20:2038–45.
43. Wanders LK, Kuiper T, Kiesslich R. Limited applicability of chromoendoscopy-guided confocal laser endomicroscopy as daily-practice surveillance strategy in Crohn's disease. *Gastrointest Endosc* 2016;83:966–71.
44. Harpaz N, Polydorides AD. Colorectal Dysplasia in IBD. *Arch Pathol Lab Med* 2010;134:876–95.
45. Fogt F, Urbanski SJ, Sanders ME, et al. Distinction between dysplasia-associated lesion or mass (DALM) and adenoma in patients with ulcerative colitis. *Hum Pathol* 2000;31(3):288–91.
46. Quinn AM, Farraye FA, Naini BV, et al. Polypectomy is adequate treatment for adenoma-like dysplastic lesions (DALMs) in Crohn's disease. *Inflamm Bowel Dis* 2013;19(6):1186–93.
47. Wanders LK, Dekker E, Pullens B, et al. Cancer risk after resection of polypoid dysplasia in patients with longstanding ulcerative colitis: A Meta-analysis. *Clin Gastroenterol Hepatol* 2014;12:756–64.
48. Thomas T, Abrams KA, Robinson RJ, et al. Meta-analysis: cancer risk of low-grade dysplasia in chronic ulcerative colitis. *Aliment Pharmacol Ther* 2007;25:657–68.
49. Bernstein CN, Shanahan F, Weinstein WM. Are we telling patients the truth about surveillance colonoscopy in ulcerative colitis? *Lancet* 1994;343:71–4.
50. Blonski W, Kundu R, Furth EF, et al. High-grade dysplastic adenoma-like mass lesions are not an indication for colectomy in patients with ulcerative colitis. *Scand J Gastroenterol* 2008;43:817.
51. Smith LA, Baraza W, Tiffin N, et al. Endoscopic resection of adenoma-like mass in chronic ulcerative colitis using a combined endoscopic mucosal resection and cap assisted submucosal dissection technique. *Inflamm Bowel Dis* 2008;14:1380.
52. Laine L, Kaltenbach T, Barkun A, et al. SCENIC international consensus statement on surveillance and management of dysplasia in inflammatory bowel disease. *Gastroenterology* 2015;148(3):639–51.
53. Lashner BA, Turner BC, Bostwick DG, et al. Dysplasia and cancer complicating strictures in ulcerative colitis. *Dig Dis Sci* 1990;35:349–52.

54. Lovasz BD, Lakatos L, Golovics PA, et al. Risk of Colorectal Cancer in Crohn's Disease Patients with Colonic Involvement and Stenosing Disease in a Population-based Cohort from Hungary. *J Gastrointest Liver Dis* 2013;22(3): 265–8.
55. Hwang JM, Varma MG. Surgery for inflammatory bowel disease. *World J Gastroenterol* 2008;14(17):2678–90.
56. Wu JS. Rectal cancer staging. *Clin Colon Rectal Surg* 2007;20(3):148–57.
57. Blackstone MO, Riddell RH, Rogers BH, et al. Dysplasia-associated lesion or mass (DALM) detected by colonoscopy in long-standing ulcerative colitis: an indication for colectomy. *Gastroenterology* 1981;80:366–74.
58. Riddell RH, Goldman H, Ransohoff DF. Dysplasia in inflammatory bowel disease: standardized classification with provisional clinical applications. *Hum Pathol* 1983;14:931–68.
59. Yao HW, Liu YH. Re-examination of the standardization of colon cancer surgery. *Gastroenterol Rep (Oxf)* 2013;1(2):113–8.
60. Segelman J, Mattsson I, Jung B, et al. Risk factors for anastomotic leakage following ileosigmoid or ileorectal anastomosis. *Colorectal Dis* 2018;20(4): 304–11.
61. Juviler A, Hyman N. Ulcerative colitis: the fate of the retained rectum. *Clin Colon Rectal Surg* 2004;17(1):29–34.
62. Scoglio D, Ahmed Ali U, Fichera A. Surgical treatment of ulcerative colitis: ileorectal vs ileal pouch-anal anastomosis. *World J Gastroenterol* 2014;20(37): 13211–8.
63. Beaugerie L, Svrcek M, Seksik P, et al. Risk of colorectal high-grade dysplasia and cancer in a prospective observational cohort of patients with inflammatory bowel disease. *Gastroenterology* 2013;145:166–75.
64. Jayaram H, Satsangi J, Chapman RW. Increased colorectal neoplasia in chronic ulcerative colitis complicated by primary sclerosing cholangitis: fact or fiction? *Gut* 2001;48:430–4.
65. Parks AG, Nicholls RJ. Proctocolectomy without ileostomy for ulcerative colitis. *BMJ* 1978;2:85–8.
66. Carne PW, Pemberton JH. Technical aspects of ileoanal pouch surgery. *Clin Colon Rectal Surg* 2004;17(1):35–41.
67. Deen KI, Williams JG, Grant EA, et al. Randomized trial to determine the optimum level of pouch-anal anastomosis in stapled restorative proctocolectomy. *Dis Colon Rectum* 1995;38(2):133–8.
68. Reilly WT, Pemberton JH, Wolff BG, et al. Randomized prospective trial comparing ileal pouch-anal anastomosis performed by excising the anal mucosa to ileal pouch-anal anastomosis performed by preserving the anal mucosa. *Ann Surg* 1997;225(6):666–76.
69. Hallgren TA, Fasth SB, Oresland TO, et al. Ileal pouch anal function after endoanal mucosectomy and handsewn ileoanal anastomosis compared with stapled anastomosis without mucosectomy. *Eur J Surg* 1995;161(12):915–21.
70. Remzi FH, Fazio VW, Delaney CP, et al. Dysplasia of the anal transitional zone after ileal pouch-anal anastomosis: results of prospective evaluation after a minimum of ten years. *Dis Colon Rectum* 2003;46(1):6–13.
71. Um JW, M'Koma AE. Pouch-related dysplasia and adenocarcinoma following restorative proctocolectomy for ulcerative colitis. *Tech Coloproctol* 2011; 15(1):7–16.

72. Derikx LA, Kievit W, Drenth JP, et al. Prior colorectal neoplasia is associated with increased risk of ileoanal pouch neoplasia in patients with inflammatory bowel disease. *Gastroenterology* 2014;146(1):119–28.
73. Kariv R, Remzi FH, Lian L, et al. Preoperative colorectal neoplasia increases risk for pouch neoplasia in patients with restorative proctocolectomy. *Gastroenterology* 2010;139:806–12.
74. Wu XR, Kiran RP, Remzi FH, et al. Preoperative pelvic radiation increases the risk for ileal pouch failure in patients with colitis-associated colorectal cancer. *J Crohns Colitis* 2013;7(10):e419–26.
75. Merchea A, Wolff BG, Dozois EJ, et al. Clinical features and oncologic outcomes in patients with rectal cancer and ulcerative colitis: a single-institution experience. *Dis Colon Rectum* 2012;55(8):881–5.
76. Delaunoy T, Limburg PJ, Goldberg RM, et al. Colorectal cancer prognosis among patients with inflammatory bowel disease. *Clin Gastroenterol Hepatol* 2006;4:335–42.
77. Dugum M, Lin J, Lopez R, et al. Recurrence and survival rates of inflammatory bowel disease-associated colorectal cancer following postoperative chemotherapy: a comparative study. *Gastroenterol Rep (Oxf)* 2016;5(1):57–61.
78. Yaeger, Hersch J, Bates D, et al. Outcomes for matched patients with metastatic colitis-associated cancers versus sporadic colorectal cancer receiving chemotherapy. *J Clin Oncol* 2018;36(15S):e15534.