

Video-assisted Thoracoscopic Resection of a Small Pulmonary Nodule after Computed Tomography-guided Localization with a Hook-wire System

Experience in 45 Consecutive Patients

Olivier Pittet, MD,¹ Michel Christodoulou, MD,¹ Edgardo Pezzetta, MD,¹
Sabine Schmidt, MD,² Pierre Schnyder, MD,² Hans-Beat Ris, MD¹

¹Division of Thoracic Surgery, Centre Hospitalier Universitaire Vaudois, 1011 Lausanne, Switzerland

²Department of Radiology, Centre Hospitalier Universitaire Vaudois, 1011 Lausanne, Switzerland

Abstract

Background: This study is a single-institution validation of video-assisted thoracoscopic (VATS) resection of a small solitary pulmonary nodule (SPN) previously localized by a CT-guided hook-wire system in a consecutive series of 45 patients.

Methods: The records of all patients undergoing VATS resection for SPN preoperatively localized by CT-guided a hook-wire system from January 2002 to December 2004 were assessed with respect to failure to localize the lesion by the hook-wire system, conversion thoracotomy rate, duration of operation, postoperative complications, and histology of SPN.

Results: Forty-five patients underwent 49 VATS resections, with simultaneous bilateral SPN resection performed in 4. Preoperative CT-guided hook-wire localization failed in two patients (4%). Conversion thoracotomy was necessary in two patients (4%) because it was not possible to resect the lesion by a VATS approach. The average operative time was 50 min. Postoperative complications occurred in 3 patients (6%), one hemothorax and two pneumonia. The mean hospital stay was 5 days (range: 2–18 days). Histological assessment revealed inflammatory disease in 17 patients (38%), metastasis in 17 (38%), non-small-cell lung cancer (NSCLC) in 4 (9%), lymphoma in 3 (6%), interstitial fibrosis in 2 (4%), histiocytoma in one (2%), and hamartoma in one (2%).

Conclusions: Histological analysis of resected SPN revealed unexpected malignant disease in more than 50% of the patients indicating that histological clarification of SPN seems warranted. Video-assisted thoracoscopic resection of SPN previously localized by a CT-guided hook-wire system is related to a low conversion thoracotomy rate, a short operation time, and few postoperative complications, and it is well suited for the clarification of SPN.

diagnosed with increasing frequency since the advent of computed tomography.^{2,3} Because about 50% of SPN are related to malignancy, the necessity for rapid and precise histological diagnosis of SPN has been stressed.³⁻⁵ Transthoracic or transbronchial fine-needle biopsy may be considered in selected cases; however, the diagnostic yield for SPN has been reported to be rather low in general. Excisional biopsy of SPN may be considered but requires invasive access, such as thoracotomy. With the advent of video-assisted thoracoscopic surgery (VATS), a minimally invasive procedure has emerged that allows complete resection of SPN with minimal morbidity.⁶ However VATS is limited because the surgeon is unable to palpate the lung tissue during operation, which may render the intraoperative identification of SPN difficult.⁷ Thus, failure to visualize or palpate SPN has resulted in conversion thoracotomy rates of up to 46%.⁷ Various techniques designed to localize SPN precisely during VATS resection have been reported, among them, preoperative CT-guided marking of the lesion by methylene blue,^{8,9} Lipidol, or radionuclides,^{10,11} or intraoperative VATS-guided ultrasound.^{12,13} Recently, a hook-wire marking system has been proposed that involves preoperative CT-guided introduction under local anesthesia and anchorage in the lesion. In this report, we present our experience with VATS resection of SPN previously marked by a CT-guided hook-wire system in a consecutive series of 45 patients.

PATIENTS AND METHOD

All patients undergoing VATS resection of SPN previously marked by use of the hook-wire system at our institution from 2002 to 2004 are the subject of this report. Patients with infracentimetric SPN underwent preoperative CT-guided localization of their lesion by use of the hook-wire system. Small pulmonary nodules in direct contact with the pleura or larger than 1 cm and at a distance of less than 1 cm beneath the pleural surface were not considered for hook-wire implantation. Smokers with solitary spiculated lesions on CT-scan compatible with primary non-metastatic lung cancer underwent lobectomy and formal mediastinal lymph node dissection by thoracotomy.

A commercially available hook-wire system (Ariadne's Thread; Biosphere Medical, Louvres, France) was used. This system consists of a circular hook-wire of 8 mm diameter connected to a 50-cm-long suture thread. The hook is contained within a 20-gauge, 10-cm-long needle and regains its circular configuration after deployment.

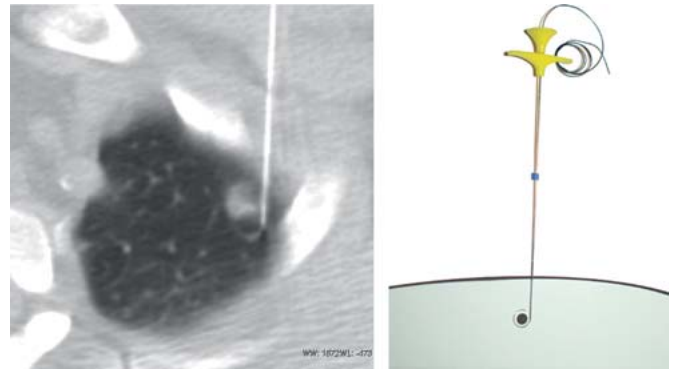


Figure 1. The hook-wire, attached to a long suture thread, is deployed under computed tomographic (CT) control into the nodule and anchored to the adjacent lung parenchyma. CT-scan documentation is performed after deployment.

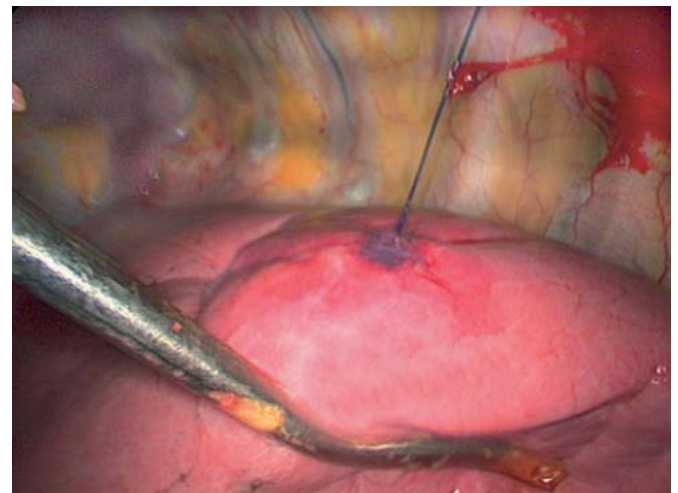


Figure 2. Intraoperative photograph of SPN previously marked by CT-guided deployment of the hook-wire device. Light traction on the suture thread during video-assisted thoracoscopic (VATS) resection renders deep-seated lesions more superficial and facilitates excision by endo-staplers.

The hook-wire was deployed within the nodule under CT-guided control¹⁴ (Fig. 1). A control CT-scan after hook-wire implantation was performed to verify correct positioning. Video-assisted thoracoscopic resection of the lesion was performed using 3 thoraco-ports and endoscopic stapler devices (EndoGIA® Autosuture; Endopath® Ethicon). The surgical specimen was extracted by use of an Endobag® (Autosuture) to prevent chest wall implantation of malignant disease (Fig. 2; Video 1). The specimen was processed by frozen examination during the operation, and lobectomy and mediastinal lymph node dissection were carried out when it was established that the lesion was non-small-cell lung cancer (NSCLC).

The files of the patients were analyzed with respect to patient demographics, underlying diseases, histology of SPN, and procedure-related characteristics such as failure to localize the lesion by the hook-wire system, conversion thoracotomy rate, duration of operation, and postoperative complications.

RESULTS

Forty-five patients underwent 49 VATS resections of SPN previously marked by the hook-wire system at our institution from 2002 to 2004. Four patients underwent simultaneous bilateral procedures for bilateral SPN. There were 23 men and 22 women with an average age at operation of 58 years (range: 22–79 years). Small pulmonary nodules were localized in the left and right lung in 45% and 55% of the patients, respectively. During the same time period, we performed a total of 320 VATS procedures and 20 VATS resections for SPN without using a hook-wire device.

Computed tomography (CT)-guided hook-wire implantation was performed without complications in all but 2 patients (4%). One patient developed an important pneumothorax requiring immediate preoperative chest tube drainage. One patient underwent misplaced hook-wire implantation requiring repositioning of the hook-wire before operation.

Video-assisted thoractomy resection of SPN was feasible in all but 2 patients (4%) who required conversion thoracotomy. Both patients revealed a too centrally localized lesion with respect to accessibility and resection properties of the endoscopic stapler device. Four additional patients had conversion thoracotomy for lobectomy and mediastinal lymph node dissection for NSCLC. A hook-wire system was noted to be in place during VATS exploration in all patients. The operation times were less than 60 min, 60–90 min, and 90–120 min in 56%, 28%, and 16% of the patients, respectively. Longer operation times were mainly recorded in patients undergoing the bilateral procedure for SPN. Postoperative complications were recorded in 3 patients (6%), pneumonia in two (4%) and hemothorax requiring reoperation and hemostasis in one (2%). Retrospectively, this patient was found to have hemophilia.

Table 1 summarizes results of the histological examination of the excised SPN. The size of SPN varied between 2 and 20 mm and measured < 10 mm in 68% of the patients. Malignant disease was found in 53% of the patients, and primary NSCLC in 9%.

Table 1.
Histological findings of the pulmonary nodules

Histological finding	Number of patients	Percent
Inflammatory diseases	17	38
Metastatic disease	17	38
Non-small-cell lung cancer	4	9
Lymphoma	3	7
Lung fibrosis	2	4
Histiocytoma	1	2
Hamartoma	1	2

Comment

The recent advent of VATS resection for SPN has allowed rapid and precise diagnosis of SPN by use of a minimally invasive procedure while avoiding the drawbacks of formal thoracotomy. Video-assisted thoracoscopic resection of SPN has become widely accepted, but conversion thoracotomy was frequently necessary because preoperative SPN localization was inadequate. This holds true especially for small subpleural lesions seated deeply in the parenchyma. Several techniques have been developed to facilitate intraoperative localization of SPN during VATS resection such as preoperative CT-guided injection of methylene blue or intraoperative ultrasound localization of the lesion.^{8,9,12,13} Methylene blue injection carries the risk of spreading the colorant on the pleural surface and the chest cavity during application, which renders subsequent intraoperative VATS-guided localization of SPN difficult. Intraoperative VATS-guided ultrasound localization of SPN is operator dependent and requires complete collapse of the assessed lung, which is difficult to obtain in emphysematous lungs.

The CT-guided hook-wire system allows precise and quick preoperative localization of SPN. It is also well-suited for the localization of small and deep-seated lesions. Light traction on the suture thread during VATS resection renders deep-seated lesions more superficial and facilitates complete excision by endo-staplers. Because the hook-wire is placed before the operation with local anaesthesia, the duration of general anaesthesia and operation is considerably reduced, and this may translate into reduced procedure-related costs.

Our results confirm low morbidity associated with the procedure and demonstrated the feasibility of preoperative CT-guided hook-wire implantation in all but one patient. One patient with marked emphysema developed a pneumothorax after hook-wire implantation requiring chest tube drainage. In fact, caution is indicated in patients with marked emphysema undergoing preoperative hook-wire implantation for SPN localization, and

preoperative insertion of chest tubes should be liberally performed in these situations. In a few other patients, a small pneumothorax was noticed on control CT after hook-wire implantation without clinical impact. However, prompt surgical intervention is advocated after hook-wire implantation in order to reduce the risk of a symptomatic pneumothorax.

The CT-guided hook-wire localization of SPN yields an excellent accuracy, with all SPN in our patients being correctly marked. In contrast to other reports, no dislodgement of the hook-wire was noted, even if traction was exerted during VATS resection. We speculate that this was due to the flexibility of this hook-wire system because of the long suture thread. However, two patients (4%) required a conversion thoracotomy because it was impossible to completely resect their deep-seated lesions by use of endo-staplers.

The histological analysis of SPN confirms the high percentage of malignant disease and endorses the previously reported results in this respect. Video-assisted thoracoscopic resection of SPN offers an elegant minimally invasive alternative to thoracotomy for this purpose. Preoperative CT-guided hook-wire marking of SPN is a rapid and efficient technique that facilitates intraoperative localization of small, deep-seated lesions. However, because of the additional costs, we considered hook-wire implantation for deep-seated lesions (> 10 mm from pleural surface) and small infra-centri-metric lesions not in contact with the pleural surface, as suggested by Suzuki *et al.*⁷

REFERENCES

1. Fraser RG, Sanders C, Barnes GT, *et al.* Digital imaging of the chest. *Radiology* 1989;171:297–307.
2. Kaneko M, Eguchi K, Ohmatsu H, *et al.* Peripheral lung cancer: screening and detection with low-dose spiral CT versus radiography. *Radiology* 1996;201:798–802.
3. Lillington GA. Management of solitary pulmonary nodules. *Dis Mon* 1991;37:271–318.
4. Lillington GA, Caskey CI. Evaluation and management of solitary and multiple pulmonary nodules. *Clin Chest Med* 1993;14:111–119.
5. Viggiano RW, Swensen SJ, Rosenow EC III. Evaluation and management of solitary and multiple pulmonary nodules. *Clin Chest Med* 1992;13:83–95.
6. Allen MS, Deschamps C, Lee RE, *et al.* Video-assisted thoracoscopic stapled wedge excision for indeterminate pulmonary nodules. *J Thorac Cardiovasc Surg* 1993;106:1048–1052.
7. Suzuki K, Nagai K, Yoshida J, *et al.* Video-assisted thoracoscopic surgery for small indeterminate pulmonary nodules: indications for preoperative marking. *Chest* 1999;115:563–568.
8. Lenglinger FX, Schwarz CD, Artmann W. Localization of pulmonary nodules before thoracoscopic surgery: value of percutaneous staining with methylene blue. *AJR Am J Roentgenol* 1994;163:297–300.
9. Wicky S, Mayor B, Cuttat JF, *et al.* CT-guided localizations of pulmonary nodules with methylene blue injections for thoracoscopic resections. *Chest* 1994;106:1326–1328.
10. Chella A, Lucchi M, Ambrogi MC, *et al.* A pilot study of the role of TC-99 radionuclide in localization of pulmonary nodular lesions for thoracoscopic resection. *Eur J Cardiothorac Surg* 2000;18:17–21.
11. Nomori H, Horio H, Naruke T, *et al.* Fluoroscopy-assisted thoracoscopic resection of lung nodules marked with lipiodol. *Ann Thorac Surg* 2002;74:170–173.
12. Gruppioni F, Piolanti M, Coppola F, *et al.* [Intraoperative echography in the localization of pulmonary nodules during video-assisted thoracic surgery]. *Radiol Med (Torino)* 2000;100:223–228.
13. Sortini D, Feo CV, Carcoforo P, *et al.* Thoracoscopic localization techniques for patients with solitary pulmonary nodule and history of malignancy. *Ann Thorac Surg* 2005;79:258–262.
14. Wicky S, Dusmet M, Doenz F, *et al.* Computed tomography-guided localization of small lung nodules before video-assisted resection: experience with an efficient hook-wire system. *J Thorac Cardiovasc Surg* 2002;124:401–403.