



OPEN ACCESS

CASE REPORT

Repair of displaced thyroid cartilage fracture using miniplate osteosynthesis

Bassel Hallak, Sonia Von Wihl, Franciscus Boselie, Salim Bouayed

Department of
Otorhinolaryngology, Hospital of
Sion, Sion, Switzerland

Correspondence to
Dr Bassel Hallak,
bassel2004@hotmail.com

Accepted 14 November 2018

SUMMARY

Acute laryngeal trauma is estimated to occur in approximately one patient per 14 500 to 42 500 emergency room admissions. If the larynx is injured, its vital functions are affected and can be threatened in case of severe injury. Soft cartilage offers no protective advantage, which is the reason why young as well as older individuals are at risk of thyroid cartilage fracture. Experimentation on cadaver larynx has demonstrated that virtually all laryngeal fractures are longitudinally oriented. Furthermore, muscular pull can contribute to a misalignment of the fractures. As stated by Bent and Porubsky, a fracture is considered severely rather than moderately displaced, if it is freely mobile on physical examination, has more than two fracture lines or demonstrates a displacement greater than the width of the thyroid cartilage on CT imaging. We present two cases of severely displaced thyroid cartilage fracture treated in our department by open reduction and internal fixation using miniplates. Functional and radiological outcomes were excellent.

BACKGROUND

When laryngeal fractures occur, stenosis and deformity may occur in the airway and vocal tract unless proper repair is undertaken. The importance of restoring this normal laryngeal framework configuration has been demonstrated in earlier studies.¹

The most effective approach in repairing laryngeal fracture remains controversial, and little research has addressed the subject directly.

Traditionally, laryngeal fractures have been repaired with stainless steel wire or sutures.²

Hirano *et al*³ have recommended the use of vocal function tests preoperatively and postoperatively in assessing the impact of the laryngeal trauma on the voice function.

We consider that the use of miniplates in the management of severely displaced thyroid cartilage fractures of the larynx is a very good option and can offer multiples advantages in terms of restoration of the anatomical structures of the larynx with a good functional outcomes.

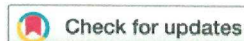
Case presentation

Our first case was a 54-year-old Caucasian man, admitted to the emergency department 4 hours after a fall from horseback with severe dysphonia and bloody sputum, without dyspnoea or any respiratory distress. He suffered severe blunt trauma to the head and neck by the horse stepping on his

throat. He had no previous medical or surgical history. He was haemodynamically stable. Clinical examination showed a mild oedema with cutaneous haematoma and subcutaneous crepitation in the cervical region. Examination of the oral cavity and oropharynx was normal. The fibre endoscopic examination of the larynx showed a bulge at the level of the posterior wall of the hypopharynx, fresh blood in both piriform sinuses with no laryngeal oedema or paralysis of the vocal folds. A CT scan showed an extensive emphysema from the skull base to the level of the mediastinum and a displaced fracture of the thyroid cartilage on the left side (figure 1). Endoscopic examination of the upper aerodigestive tract under general anaesthesia showed no lesion of the oesophagus or the trachea, but a mucosal laceration of the left aryepiglottic fold with exposure of the thyroid cartilage as well as obstructive laryngeal oedema was observed. The patient underwent immediate surgical exposure of the neck via an anterior horizontal incision. Exploration of the larynx showed a displaced fracture in the left para—median part of the thyroid cartilage. Open reduction of the displaced cartilage fragments and their fixation was done using two miniplates fixed to the cartilage with four screws of 1.5 mm (figure 2). A tracheotomy was performed because of the laryngeal oedema.

Antibiotic treatment was introduced (co-amoxicillin 1.2 g intravenous three times per day) associated with corticotherapy for 5 days. Nutrition by a nasogastric tube was followed by progressive introduction of oral feeding. Postoperative CT scan 3 days later showed a regression of the emphysema and symmetric alignment of the thyroid cartilage (figure 1). The tracheotomy was removed after 6 days with a total regression of the laryngeal oedema. The patient was hospitalised for 7 days. Antibiotic treatment was continued orally for a total of 14 days. Follow-up at 1, 3, 6 and 12 months after surgery showed no complication or persisting sequelae. A subjective assessment of the voice by using the Voice Handicap Index-10 (VHI-10) showed a score of 3 out of 40. The fibre endoscopic control showed normal vocal fold mobility and good healing of the laryngeal mucosa without exposure of the screws into the larynx (figure 1). No respiratory problems or any swallowing difficulties were observed.

Our second case is 60-year-old Caucasian man in good general health presented to the emergency department with cervical trauma by direct reception of a burst disk of a grinder into the throat.



© BMJ Publishing Group Limited 2018. Re-use permitted under CC BY-NC. No commercial re-use. See rights and permissions. Published by BMJ.

To cite: Hallak B, Von Wihl S, Boselie F, *et al*. *BMJ Case Rep* 2018;**11**:e226677. doi:10.1136/bcr-2018-226677

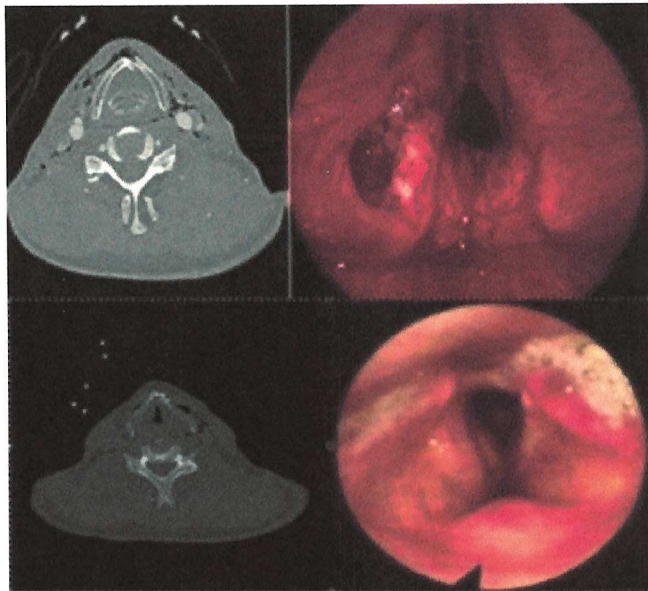


Figure 1 (Up) Preoperative CT scan and fibre endoscopic examination (case 1) show a displaced fracture of the thyroid cartilage on the left side with extensive emphysema and a laceration of the mucosa. (Down) Postoperative CT scan and 1-month postoperative fibre endoscopic examination (case 1) show symmetric alignment of the thyroid cartilage with regression of the emphysema and good healing of the laryngeal mucosa with normal vocal fold mobility and no endolaryngeal exposure of the miniplates or screws.

He presented hoarseness with dysphagia, without dyspnoea or any respiratory symptoms. Clinical examination showed a deep cervical wound in the anterior neck with the presence of a metallic foreign body, without oedema or subcutaneous crepitation. The fibroendoscopic examination showed a mild oedema of the right vocal fold with traces of blood in the right piriform sinus (figure 3). The mobility of the vocal cords was normal. The patient underwent immediate surgical exploration of the wound under general anaesthesia with removal of the foreign body. The exploration of the larynx showed a double displaced horizontal and vertical fracture in the right thyroid cartilage. Open reduction of the double fractures and fixation of the cartilaginous fragments was done using two miniplates fixed to the cartilage with six screws of 1.5 mm (figure 4). A tracheotomy was not necessary. Intravenous antibiotic treatment was introduced (co-amoxicillin 1.2 g intravenous three times per day) associated with corticotherapy for 5 days. Oral nutrition

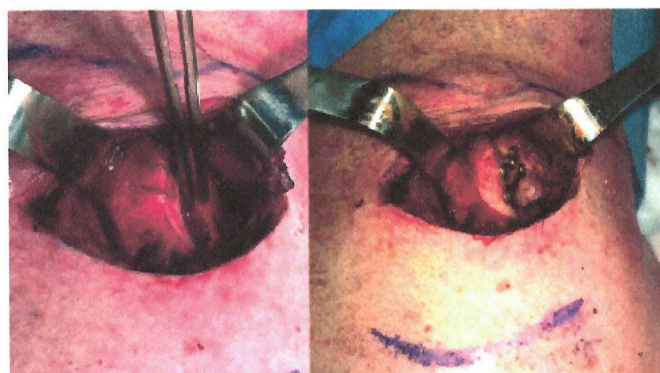


Figure 2 Intraoperative images of the larynx before and after reduction and fixation by using miniplates (case 1).

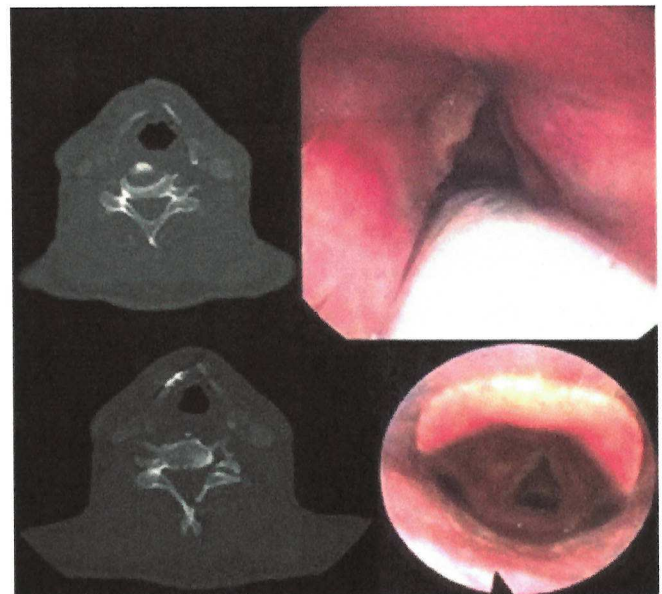


Figure 3 (Up) Preoperative CT scan and fibre endoscopic examination (case 2) show a displaced fracture of the thyroid cartilage on the right side with extensive emphysema and normal laryngeal mucosa. (Down) Postoperative CT scan and 1-month postoperative fibre endoscopic examination (case 2) show symmetric alignment of the thyroid cartilage and no affection of the laryngeal mucosa with normal vocal fold mobility and no endolaryngeal exposure of the miniplates or screws.

was possible without any difficulties. The postoperative CT scan 3 days later showed symmetric alignment of the right thyroid cartilage (figure 3). The patient could be discharged after 5 days. Antibiotic treatment was continued orally for a total of 14 days. Follow-up at 1, 3 and 6 months showed no complication or persisting sequelae. A subjective assessment of the voice by using the VHI-10 showed a score of 2 out of 40. The fibroendoscopic status showed normal vocal fold mobility and good healing of the laryngeal mucosa without exposure of the screws into the larynx (figure 3). No respiratory problems or any swallowing difficulties were observed.

OUTCOME AND FOLLOW-UP

First case: follow-up at 1, 3, 6 and 12 months after surgery showed no complication or persisting sequelae. A subjective assessment of the voice by using the VHI-10 showed a score of 3 out of 40. The fibre endoscopic control showed normal vocal

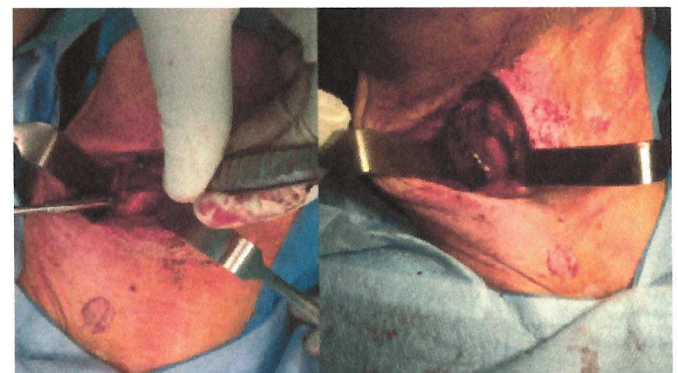

Figure 4 Intraoperative images of the larynx before and after reduction and fixation by using miniplates (case 2).

fold mobility and good healing of the laryngeal mucosa without exposure of the screws into the larynx. No respiratory problems or any swallowing difficulties were observed.

Second case: follow-up at 1, 3 and 6 months showed no complication or persisting sequelae. A subjective assessment of the voice by using the VHI-10 showed a score of 2 out of 40. The fibroendoscopic status showed normal vocal fold mobility and good healing of the laryngeal mucosa without exposure of the screws into the larynx. No respiratory problems or any swallowing difficulties were observed.

DISCUSSION

There is consensus that minor trauma with no airway compromise can be treated conservatively. Significant laryngeal trauma requires securing the airway in the acute phase and afterwards restoring the anatomy which permits the larynx to retain its functions after healing.

In the past, different methods of repair have been described such as the use of non-restorable sutures, stainless steel wires and endolaryngeal stents. The main disadvantage of these traditional techniques is that they fail to achieve accurate three-dimensional reduction and stable fixation of the fractured cartilage.⁴ Schaefer and Close recommended open repair for all displaced fractures.⁵

Studies from the 1990s, reflecting techniques preceding miniplates, report that a good laryngeal airway was achieved in over 90% but a good voice in only 70%, as discussed by Jewett *et al.*⁶

Woo² reported on his success using miniplates for laryngeal reconstruction. His stated advantage of miniplates fixation was the immediate and sustained rigid stability of the framework with restoration of the laryngeal airway.

An interesting rabbit study by Dray *et al.*⁷ found cartilaginous healing of fractures fixed with plates, but fibrous healing in those fixed with wire. de Mello-Filho and Carrau⁸ reviewed 20 patients who have had repairs of laryngeal fractures with miniplates. They reported that 19 of the 20 patients had a good airway, recovered their voice and were able to swallow without aspiration.

Reconstruction screws can be used in thyroid cartilage, and its fixation strength is maximised by larger screw/screw hole ratios than in bone.⁹ Maximum strength is achieved using a 1.5 mm titanium adaption screw in a 0.76 mm drill hole.

Regarding the two clinical cases described above, the functional outcomes in terms of respiration, swallowing and phonation were excellent. No complications or any bulky effect related to the miniplates was observed. The quality of voice as assessed during follow-up showed a subjective improvement without any voice compromising.

An objective evaluation of the restoration quality of the various internal anatomical structures of the larynx, especially the vocal cords, showed a perfectly symmetrical appearance and good alignment of the vocal cords with a perfectly preserved mobility. This restoration had an important impact on the post-operatively voice outcomes.

Learning points

- The repair of laryngeal trauma with thyroid cartilage fractures by using miniplates can offer more advantages when compared with other methods.
- The technique is easy to apply and offers a more rigid fixation, an immediate stabilisation with accurate alignment and cartilaginous healing.
- These findings confirm the outcomes regarding our patients.

Contributors BH and SB: reporting. SVW: conception and design. FB: acquisition of data.

Funding The authors have not declared a specific grant for this research from any funding agency in the public, commercial or not-for-profit sectors.

Competing interests None declared.

Patient consent Obtained.

Provenance and peer review Not commissioned; externally peer reviewed.

Open access This is an open access article distributed in accordance with the Creative Commons Attribution Non Commercial (CC BY-NC 4.0) license, which permits others to distribute, remix, adapt, build upon this work non-commercially, and license their derivative works on different terms, provided the original work is properly cited and the use is non-commercial. See: <http://creativecommons.org/licenses/by-nc/4.0/>

REFERENCES

- 1 Stanley RB, Cooper DS, Florman SH. Phonatory effects of thyroid cartilage fractures. *Ann Otol Rhinol Laryngol* 1987;96:493–6.
- 2 Woo P. Laryngeal framework reconstruction with miniplates. *Ann Otol Rhinol Laryngol* 1990;99:772–7.
- 3 Hirano M, Kurita S, Terasawa R. Difficulty in high-pitched phonation by laryngeal trauma. *Arch Otolaryngol* 1985;111:59–61.
- 4 Islam S, Shorafa M, Hoffman GR, *et al.* Internal fixation of comminuted cartilaginous fracture of the larynx with mini-plates. *Br J Oral Maxillofac Surg* 2007;45:321–2.
- 5 Schaefer SD, Close LG. Acute management of laryngeal trauma. Update. *Ann Otol Rhinol Laryngol* 1989;98:98–104.
- 6 Jewett BS, Shockley WW, Rutledge R. External laryngeal trauma analysis of 392 patients. *Arch Otolaryngol Head Neck Surg* 1999;125:877–80.
- 7 Dray TG, Coltrera MD, Pinczower EF. Thyroid cartilage fracture repair in rabbits: comparing healing with wire and miniplate fixation. *Laryngoscope* 1999;109:118–22.
- 8 de Mello-Filho FV, Carrau RL. The management of laryngeal fractures using internal fixation. *Laryngoscope* 2000;110:2143–6.
- 9 Plant RL, Pinczower EF. Pullout strength of adaption screws in thyroid cartilage. *Am J Otolaryngol* 1998;19:154–7.

Copyright 2018 BMJ Publishing Group. All rights reserved. For permission to reuse any of this content visit <https://www.bmj.com/company/products-services/rights-and-licensing/permissions/>
BMJ Case Report Fellows may re-use this article for personal use and teaching without any further permission.

Become a Fellow of BMJ Case Reports today and you can:

- Submit as many cases as you like
- Enjoy fast sympathetic peer review and rapid publication of accepted articles
- Access all the published articles
- Re-use any of the published material for personal use and teaching without further permission

For information on Institutional Fellowships contact consortiasales@bmjgroup.com

Visit casereports.bmj.com for more articles like this and to become a Fellow