



## Original Article

# Myositis and acute kidney injury in bacterial atypical pneumonia: Systematic literature review



Chiara Simoni<sup>a,1</sup>, Pietro Camozzi<sup>b,1</sup>, Pietro B. Faré<sup>c</sup>, Mario G. Bianchetti<sup>a</sup>,  
Lisa Kottanattu<sup>d</sup>, Sebastiano A.G. Lava<sup>e</sup>, Gregorio P. Milani<sup>f,g,\*</sup>

<sup>a</sup> Università della Svizzera Italiana, Lugano, Switzerland

<sup>b</sup> Department of Internal Medicine, Ente Ospedaliero Cantonale, Bellinzona, Switzerland

<sup>c</sup> Department of Internal Medicine, Ente Ospedaliero Cantonale, Locarno, Switzerland

<sup>d</sup> Pediatric Institute of Southern Switzerland, Ospedale San Giovanni, Bellinzona, Switzerland

<sup>e</sup> Pediatric Cardiology Unit, Department of Pediatrics, Centre Hospitalier Universitaire Vaudois, and University of Lausanne, Lausanne, Switzerland

<sup>f</sup> Pediatric Unit, Fondazione IRCCS Ca' Granda Ospedale Maggiore Policlinico, Milan, Italy

<sup>g</sup> Department of Clinical Sciences and Community Health, Università degli Studi di Milano, Milan, Italy

## ARTICLE INFO

## Article history:

Received 18 May 2020

Received in revised form

25 September 2020

Accepted 12 October 2020

## Keywords:

*Mycoplasma*

Chlamydia

Rhabdomyolysis

Acute kidney injury

Acute renal failure

## ABSTRACT

**Background:** Bacterial community-acquired atypical pneumonia is sometimes complicated by a myositis or by a renal parenchymal disease. Available reviews do not mention the concurrent occurrence of both myositis and acute kidney injury.

**Methods:** In order to characterize the link between bacterial community-acquired atypical pneumonia and both myositis and a renal parenchymal disease, we reviewed the literature (United States National Library of Medicine and Excerpta Medica databases).

**Results:** We identified 42 previously healthy subjects (35 males and 7 females aged from 2 to 76, median 42 years) with a bacterial atypical pneumonia associated both with myositis (muscle pain and creatine kinase  $\geq 5$  times the upper limit of normal) and acute kidney injury (increase in creatinine to  $\geq 1.5$  times baseline or increase by  $\geq 27 \mu\text{mol/L}$  above the upper limit of normal). Thirty-six cases were caused by *Legionella* species ( $N = 27$ ) and by *Mycoplasma pneumoniae* ( $N = 9$ ). Further germs accounted for the remaining 6 cases. The vast majority of cases ( $N = 36$ ) presented a diffuse myalgia. Only a minority of cases ( $N = 3$ ) were affected by a calf myositis. The diagnosis of rhabdomyolysis-associated kidney injury was retained in 37 and that of acute interstitial nephritis in the remaining 5 cases.

**Conclusion:** Bacterial atypical pneumonia may occasionally induce myositis and secondary kidney damage.

© 2020 The Authors. Published by Elsevier Ltd on behalf of King Saud Bin Abdulaziz University for Health Sciences. This is an open access article under the CC BY-NC-ND license (<http://creativecommons.org/licenses/by-nc-nd/4.0/>).

## Introduction

Bacterial community-acquired atypical pneumonia is usually caused by non-zoonotic pathogens such as *Chlamydophila pneumoniae*, *Legionella* species or *Mycoplasma pneumoniae*. More rarely, this pneumonia is caused by zoonotic pathogens such as *Chlamydophila psittaci*, *Coxiella burnetii* or *Francisella tularensis* [1,2].

There are cases of atypical pneumonia that are associated with a myositis and present with muscle weakness, pain or swelling and elevated muscle enzymes [3,4]. A renal parenchymal disease may also occasionally occur in bacterial community-acquired atypical pneumonia [1,2].

Myositis releases intracellular muscle constituents into the circulation and may subsequently cause an acute kidney damage [5]. Available reviews on atypical pneumonia, however, do not or only marginally mention the concurrent occurrence of both myositis and acute kidney injury [1,2]. To investigate the possible association between myositis and acute kidney injury in patients affected by bacterial atypical pneumonia, we systematically reviewed the literature.

\* Corresponding author at: Pediatric Unit, Fondazione IRCCS Ca' Granda, Ospedale Maggiore Policlinico, via della Commenda 9, 20122 Milan, Italy.

E-mail addresses: [milani.gregoriop@gmail.com](mailto:milani.gregoriop@gmail.com), [gregorio.milani@unimi.it](mailto:gregorio.milani@unimi.it) (G.P. Milani).

<sup>1</sup> Contributed equally to this work.

## Methods

### Literature search strategy

We recently (April 2020) realized a systematic literature review on myositis, acute kidney injury and bacterial community-acquired atypical pneumonia, as per Preferred Reporting Items for Systematic Reviews and Meta-Analyses standards. The United States National Library of Medicine and Excerpta Medica databases were searched using the Medical Subject Heading terms: (atypical pneumonia OR *Chlamydomphila* OR Chlamydia OR *Coxiella* OR *Francisella* OR Legionella OR *Mycoplasma*) AND (myalgia OR myositis OR rhabdomyolysis OR acute kidney injury OR acute renal failure).

The literature search was carried out independently by two investigators (CS, PC). Conflicts in study identification were resolved in conjunction with a third investigator (MGB).

### Selection criteria

Original articles published up to March 31, 2020 that reported on cases of community-acquired atypical pneumonia caused by *Chlamydomphila* (Chlamydia) pneumoniae, *C. psittaci*, *C. burnetii*, *F. tularensis*, *Legionella* species or *M. pneumoniae* associated both with new-onset myositis and acute kidney injury were sorted. Patients with a pre-existing pulmonary, muscular or renal condition or without an acute respiratory disease were not included. Cases characterized by an impairment of more than two systems (e.g.: brain, cardiovascular, hematology, and liver) in addition to the respiratory, muscle and kidney were also excluded to avoid the possible inclusion of individuals affected by multiple organ dysfunction [6].

“Myositides” possibly triggered by intense exercise or potentially myotoxic drugs were not included. Cases with findings consistent with a glomerulonephritis (including Henoch-Schönlein purpura nephritis), with a thrombotic microangiopathy syndrome, or with acute kidney disease induced by hemolysis or drugs [7] were excluded. Cases associated with an atypical pneumonia of viral origin (including among others Coronavirus disease 2019) were also excluded.

The diagnosis of bacterial community-acquired atypical pneumonia was based on a distinctive presentation and an appropriate microbiology laboratory testing. The diagnosis of myositis [3–5] was made in subjects with acute onset of muscle weakness, pain or swelling and a total creatine kinase level at least five times the upper limit of normal and no signs consistent with an ischemic myocardial disease. Because the reference range for creatine kinase depends on sex, age, and laboratory’s own normal values, the measured level was divided by the upper limit of normal to calculate the creatine kinase ratio [3–5]. Circulating creatinine was used to define acute kidney injury using the criteria definition proposed by the KDIGO Acute Kidney Injury Work Group [8].

### Data extraction and case assessment

From each included case, following information was sought using a piloted form and transcribed into an ad-hoc database: demographics; pre-existing chronic conditions; hematologic, hepatic, cardiac, cerebral or cutaneous compromise and multiple organ dysfunction; clinical and laboratory features with emphasis on the temporal relationship between respiratory symptoms and onset of muscular disease, the respiratory, the muscular and the renal disease (investigations such as muscle ultrasound, electromyography and muscle or renal biopsy were also excerpted); and outcome. If needed, attempts were also made to contact authors of original reports to provide additional information.

The temporal relationship between respiratory symptoms and onset of muscular disease was used to classify myositis as intra-

(myositis developed concurrently with the respiratory symptoms) or post-infectious (myositis developed after clinical resolution). The muscular disease was classified [3,4] as calf myositis (cases with pain and tenderness affecting exclusively the calves) or diffuse myositis (cases with widespread myalgia or muscular weakness). The remaining cases were considered unclassified.

Circulating creatinine was used to classify acute kidney injury as stage 1, stage 2 or stage 3 as suggested by the KDIGO Acute Kidney Injury Work Group [8]. Urine output was not used for kidney injury staging. The diagnosis of acute kidney injury associated with rhabdomyolysis [5] was made in cases with one or more of the following: creatine kinase ratio  $\geq 100$ , dark brown urine with a positive ( $\geq +++$ ) orthotolidine test for “blood” but without pathological hematuria on microscopy, dark brown urine with a myoglobin level  $\geq 1000 \mu\text{g/L}$ , pigmented granular casts in urine or in a kidney biopsy specimen (also disclosing an acute tubular injury with normal glomeruli). The diagnosis of kidney injury associated with acute interstitial nephritis was made in cases not fulfilling the above-mentioned criteria for rhabdomyolysis-associated kidney disease and in cases with a kidney biopsy disclosing the characteristic features of an interstitial nephritis.

The possible occurrence of the following compromise was also addressed: hemolytic anemia, leukopenia ( $\leq 4.5 \times 10^9/\text{L}$ ), thrombocytopenia ( $\leq 150 \times 10^9/\text{L}$ ), cardiac, cerebral, hepatic or cutaneous involvement [9].

### Statistical analysis

Continuous variables are given as median and interquartile range ( $\geq 6$  cases) or as individual values ( $< 6$  cases), and categorical variables as frequency. The Cohen coefficient was used to assess the agreement between investigators on the application of exclusion and inclusion criteria, the two-tailed Kruskal-Wallis test (with the Dunn post-test) to compare continuous variables, and the two-tailed Fisher exact test for categorical variables. Statistical significance was set at  $P < 0.05$ .

## Results

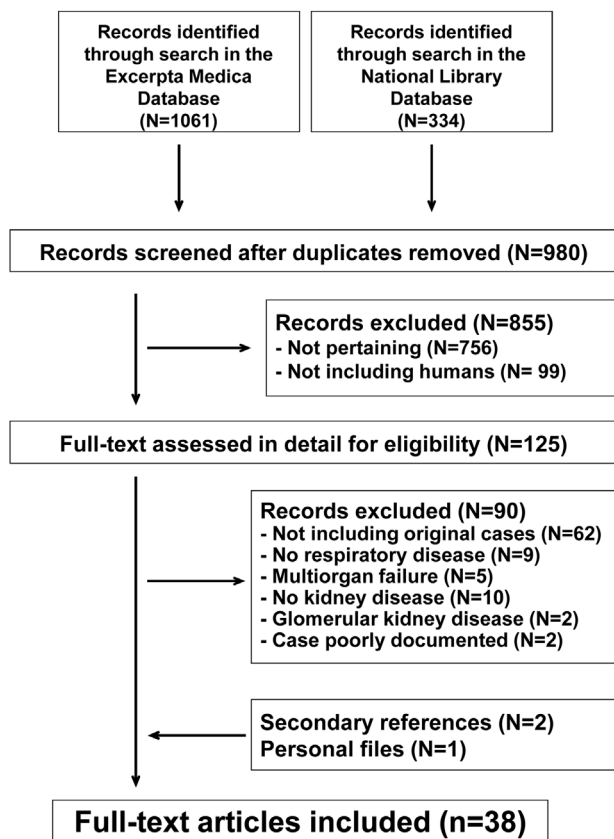
### Search results

The literature search process is presented in Fig. 1. The agreement between the two investigators on the application of the inclusion and exclusion criteria was 0.88. Nine cases presenting with myositis and kidney injury associated with a positive microbiology laboratory testing were not included because they did not present any respiratory disease (*M. pneumoniae*,  $N = 6$ ; *C. pneumoniae*,  $N = 1$ ; *F. tularensis*,  $N = 1$ ; *Legionella pneumoniae*,  $N = 1$ ). For the final analysis, we retained 38 reports [10–47] published between 1974 and 2019 in English ( $N = 34$ ), French ( $N = 2$ ) and Spanish ( $N = 2$ ). They had been reported from the following countries: United States of America ( $N = 16$ ), France ( $N = 3$ ), Australia ( $N = 2$ ), Japan ( $N = 2$ ), the Netherlands ( $N = 2$ ), Spain ( $N = 2$ ), Turkey ( $N = 2$ ), Austria ( $N = 1$ ), Belgium ( $N = 1$ ), China ( $N = 1$ ), Croatia ( $N = 1$ ), Greece ( $N = 1$ ), India ( $N = 1$ ), South Africa ( $N = 1$ ), Tunisia ( $N = 1$ ) and United Kingdom ( $N = 1$ ).

### Findings

#### Demographics – microbiological studies – acute respiratory disease

The aforementioned communications included 42 previously healthy subjects (35 males and 7 females aged from 2 to 76, median 42 years) with a bacterial community-acquired atypical pneumonia associated both with myositis and acute kidney injury (Table 1). Thirty-six cases (85%) of pneumonia were caused by Legionella



**Fig. 1.** Myositis and acute kidney injury associated with bacterial atypical pneumonia. Flowchart of the literature search process.

**Table 1**  
Characteristics of 42 patients, 2–76 years of age, with bacterial community-acquired atypical pneumonia complicated by myositis and acute kidney injury.

	All cases	Legionella species <sup>a</sup>	<i>Mycoplasma pneumoniae</i>	Further germs <sup>b</sup>	Significance
N	42	27	9	6	
Males:females	35:7	24:3	7:2	4:2	Not significant
Age					
Years	42 [27–56]	50 [39–61]	21 [12–24]	42 [34–48]	P < 0.01
≤18 years	5	0	5	0	P < 0.01
Temporal relationship with respiratory disease					
Intra-infectious	41	27	8	6	Not significant
Post-infectious	1	0	1	0	Not significant
Clinical pattern of myositis					Not significant
Calf myositis	3	1	2	0	
Diffuse myalgia	36	24	6	6	
Unclassified	3	2	1	0	
Creatine kinase					
Ratio	165 [60–611]	136 [30–461]	187 [109–732]	383 [92–864]	Not significant
Ratio ≥100	30	18	8	4	
Acute kidney injury					Not significant
Stage I	6	3	2	1	
Stage II	3	0	3	0	
Stage III	33	24	4	5	
Underlying kidney disease					
Rhabdomyolysis associated kidney injury	37	22	9	6	
Tubulointerstitial nephritis	5	5	0	0	Not significant
Further involvement					
Thrombocytopenia	5	4	0	1	Not significant
Leukopenia	1	0	0	1	Not significant
Hemolytic anemia	1	0	1	0	Not significant
Liver involvement	10	7	0	3	Not significant
Central nervous system involvement	5	2	3	0	Not significant
Death	4	3	0	1	Not significant

<sup>a</sup> *Legionella pneumophila* (N = 26), *Legionella longbeachae* (N = 1).

<sup>b</sup> *Francisella tularensis* (N = 3), *Coxiella burnetii* (N = 2), *Chlamydomphila psittaci* (N = 1).

species (N = 27; *Legionella pneumophila*, N = 26; *Legionella longbeachae*, N = 1) and by *M. pneumoniae* (N = 9). Further germs (*F. tularensis*, N = 3; *C. burnetii*, N = 2; *C. psittaci*, N = 1) accounted for the remaining 6 (15%) cases.

The diagnosis of *L. pneumophila* infection (N = 26) was made by means of a positive urinary antigen test (N = 12), a consistent increase in immunoglobulin G antibody titer in paired blood samples (N = 9), a positive sputum or tissue culture (N = 4), or both an increase in antibody titer in blood and a positive urinary antigen test (N = 1). The diagnosis of *M. pneumoniae* infection (N = 9) was made by means of an increase in antibody titer in paired blood samples (N = 6) or a positive *Mycoplasma* testing in a respiratory tract sample (N = 2). No detailed information was available for the remaining *Mycoplasma* case. Finally, the diagnosis of *F. tularensis* (N = 3), *C. burnetii* (N = 2), *C. psittaci* (N = 1), and *L. longbeachae* (N = 1) infection was made by means of an increase in antibody titer in paired blood samples.

The respiratory and the muscular disease presented concurrently in 98% of cases. Patients with myositis and acute kidney injury caused by *M. pneumoniae* were significantly (P < 0.01) younger than the remaining patients.

### Myositis

The creatine kinase ratio was ≥100 in two thirds of cases and similar in patients with pneumonia caused by *Legionella* species, *M. pneumoniae* or the remaining germs. The vast majority of cases (84%) presented a diffuse myalgia. Only a small minority of cases (6.7%) were affected by a calf myositis (Table 1).

A muscle biopsy was performed in four *Mycoplasma* [36,39] and three *Legionella* [10,25,31] cases. Inflammatory muscle lesions were detected in all [10,25,31,36] but one [39] cases. *L. pneumophila* was found to have invaded skeletal muscle tissue in a 65-year-old woman with legionnaires' disease complicated by myositis [31]. No *L. pneumophila* was detected in the case reported by Brivet et al. [10]. No attempt to detect microorganisms in the muscle tissue was

**Table 2**

Documented and, at least so far, unreported (but reasonable) causes of acute kidney injury in patients with bacterial atypical pneumonia (as detected by a focused narrative literature review performed by the authors).

	<i>Mycoplasma pneumoniae</i>	<i>Legionella</i> species	Further germs
Hemodynamically mediated renal dysfunction	+	+	+
Tubulointerstitial nephritis	+	+	(+)
Glomerular kidney disease			
Henoch-Schönlein purpura nephritis	+	+	(+)
Immunoglobulin A glomerulonephritis	+	(+)	(+)
Further glomerular kidney diseases	+	(+)	(+)
Thrombotic microangiopathy syndrome	+	+	(+)
Rhabdomyolysis-associated kidney injury	+	+	+
Hemolysis-associated kidney injury	+	(+)	(+)
Drug-induced kidney disease	+	+	+

+ documented association; (+) reasonable association, so far unreported.

performed in the remaining cases. Testing for immune deposits was never reported to be positive.

A needle-electromyography evaluation, performed in the case of *Mycoplasma* associated disease reported by Bennett et al. [36], disclosed a myopathic pattern. A muscle ultrasound evaluation was never performed.

#### Kidney disease

The severity of kidney disease was similar in the three groups of patients: *Legionella*, *Mycoplasma* and the one associated with further germs (Table 1). The creatine kinase ratio was similar in patients with acute kidney injury stage 1 (149 [62–742]) stage 2 (10, 95, 946) and stage 3 (175 [66–538]). A renal biopsy, performed in two *Legionella* cases, disclosed the distinctive features of an interstitial nephritis [26,33]. The microorganism was identified in the biopsy specimens of the mentioned two cases [26,33].

Using the criteria defined above, the diagnosis of rhabdomyolysis-associated kidney injury was retained in 37 (88%) cases. The mentioned diagnosis was based on a creatine kinase ratio  $\geq 100$  in 30, on urinary findings in five and on a renal biopsy in two cases. Acute interstitial nephritis was diagnosed in the remaining five (12%) cases. Acute interstitial nephritis was always associated with *Legionella* pneumonia (a tubulointerstitial nephritis was never observed in cases caused by *Mycoplasma*, *Francisella*, *Coxiella* or *Chlamydomphila*).

#### Further involvement

In addition to the pulmonary, muscular and renal disease, a further non-pulmonary compromise was observed in more than half of the cases (Table 1).

**Outcome.** Three patients with legionnaires' disease [10,25,33] and one with *Francisella* infection [44] died. The remaining patients recovered without sequelae.

#### Discussion

Like in influenza, mild muscle aches (with normal muscle enzymes) are common in atypical pneumonia [1,2]. Muscle symptoms or signs and a significant increase in creatine kinase level sometimes occur in atypical pneumonia caused by *Legionella* species or *M. pneumoniae* (but are likely very rare in cases caused by *F. tularensis*, *C. burnetii*, *C. pneumoniae* or *C. psittaci*). On the other hand, atypical pneumonia is occasionally associated with an intrinsic kidney disease. The results of this careful analysis suggest that in bacterial community-acquired atypical pneumonia, myositis may cause rhabdomyolysis associated kidney injury. Furthermore, the analysis points out that in *Legionella* pneumonia complicated by myositis, acute kidney injury may also result from

interstitial nephritis without any rhabdomyolysis-associated kidney injury [31].

The clinical spectrum of acute myositis complicating atypical pneumonia ranges from calf myositis, which is more common and is usually associated with a mildly elevated creatine kinase ratio, to diffuse myositis, which is uncommon and may be associated with a severely elevated creatine kinase ratio ( $\geq 100$ ). The mechanisms underlying acute myositis in atypical pneumonia are still unknown and deserve some discussion. First, bacterial atypical pneumonia and myositis develop concurrently in the vast majority ( $\geq 95\%$ ) of cases. Second, a muscle biopsy, performed in a minority of cases, sometimes disclosed the direct invasion of the microorganism in the skeletal muscle [31]. Finally, testing for immune deposits was always negative. Thus, it is tempting to assume that muscle damage does not result from an autoimmune reaction, but directly from the pathogen or from the release of myotoxic cytokines [9]. Only a few cases of myositis included in this analysis presented with calf myositis, the most frequent infection-associated myositis [3,4]. This is likely related to the fact that the release of intracellular muscle constituents into the circulation is rather mild in calf myositis and, subsequently, does not cause any kidney injury. Of note, benign calf myositis is generally associated with Influenza infection and shows a stereotypical presentation [3,4], distinct from the myositis associated with bacterial atypical pneumonia.

Like many other infections, also atypical pneumonia may lead to a number of hemodynamic derangements that cause acute kidney injury. Kidney injury may also result either from an acute tubulointerstitial nephritis, from a glomerulonephritis (including among others Henoch-Schönlein purpura nephritis and thrombotic microangiopathy syndrome) or from severe intravascular hemolysis [48–55]. The possible causes of acute kidney disease in patients affected by an acute kidney injury associated with bacterial atypical pneumonia are summarized in Table 2. Autoimmune conditions such as ANCA-associated systemic diseases or Goodpasture syndrome should also be considered in patients presenting both with an acute kidney disease and with a microbiologically unclear pulmonary disease [56].

The results of this report must be viewed with an understanding of the inherent limitations of the analysis process, which is based on the scanty available literature. Furthermore, available information does not allow documenting the prevalence of acute kidney injury caused by myositis in atypical pneumonia.

#### Conclusion

There are several potential causes of rhabdomyolysis including muscle compression, trauma, exertion, hyperthermia, inborn errors of metabolism, dyselectrolytemias, toxins, drugs and infections. The present analysis points out that the germs underlying bacterial atypical pneumonia may occasionally invade the mus-

cle tissue thereby inducing both myositis and secondary kidney damage.

### Funding

This research did not receive any specific grant from funding agencies in the public, commercial, or not-for-profit sectors.

### Competing interests

None declared.

### Ethical approval

Not required.

### References

- Cunha BA. Atypical pneumonias. Clinical diagnosis and empirical treatment. *Postgrad Med* 1991;90:89–101.
- Sharma L, Losier A, Tolbert T, Dela Cruz CS, Marion CR. Atypical pneumonia: updates on *Legionella*, *Chlamydia*, and *Mycoplasma pneumoniae*. *Clin Chest Med* 2017;38:45–58.
- Ferrarini A, Lava SA, Simonetti GD, Ramelli GP, Bianchetti MG. Influenzavirus B-associated acute benign myalgia cruris: an outbreak report and review of the literature. *Neuromuscul Disord* 2014;24:342–6.
- Capoferri G, Milani GP, Ramelli GP, Ferrarini A, Bianchetti MG, Lava SAG. Sporadic acute benign calf myositis: systematic literature review. *Neuromuscul Disord* 2018;28:443–9.
- Bosch X, Poch E, Grau JM. Rhabdomyolysis and acute kidney injury. *N Engl J Med* 2009;361:62–72.
- Johnson D, Mayers I. Multiple organ dysfunction syndrome: a narrative review. *Can J Anaesth* 2001;48:502–9.
- Schetz M, Dasta J, Goldstein S, Golper T. Drug-induced acute kidney injury. *Curr Opin Crit Care* 2005;11:555–65.
- Kidney Disease: Improving Global Outcomes (KDIGO) Acute Kidney Injury Work Group. KDIGO clinical practice guideline for acute kidney injury. *Kidney Int Suppl* 2012;2:1–138.
- Poddighe D. Extra-pulmonary diseases related to *Mycoplasma pneumoniae* in children: recent insights into the pathogenesis. *Curr Opin Rheumatol* 2018;30:380–7.
- Brivet F, Pham Van T, Petitpretz P, Delfraissy JF. Rhabdomyolysis, acute renal failure and Legionnaires' disease. *Chest* 1984;86:943–4.
- Byrd Jr RP, Roy TM. Rhabdomyolysis and bacterial pneumonia. *Respir Med* 1998;92:359–62.
- Clark BM, Boan P, Kulkarni HA. A case of *Legionella longbeachae* pneumonia complicated by rhabdomyolysis and acute renal failure requiring hemodialysis. *Infect Dis Clin Pract* 2010;18:413–6.
- Erdogan H, Yilmaz A, Kal O, Erdogan A, Arslan H. Rhabdomyolysis-induced acute renal failure associated with Legionnaires' disease. *Scand J Urol Nephrol* 2006;40:345–6.
- Friedman HM. Legionnaires' disease in non-legionnaires. A report of five cases. *Ann Intern Med* 1978;88:294–302.
- Gutiérrez A, Arriaga I, Varona M, Javier Mazo F. Rhabdomyolisis asociada a neumonía por *Legionella pneumophila*. *Enferm Infecc Microbiol Clin* 1997;15:43–4.
- Hall SL, Wasserman M, Dall L, Schubert T. Acute renal failure secondary to myoglobinuria associated with Legionnaires' disease. *Chest* 1983;84:633–5.
- Johnson DA, Etter HS. Legionnaires' disease with rhabdomyolysis and acute reversible myoglobinuric renal failure. *South Med J* 1984;77:777–9.
- Kaufman D, Weber K, Graddon JD. *Legionella pneumoniae*: an unusual cause of rhabdomyolysis and acute renal failure. *South Med J* 2002;95:660.
- Koufakis T, Gabranis I, Chatzopoulou M, Margaritis A, Tsiakalou M. Severe Legionnaires' disease complicated by rhabdomyolysis and clinically resistant to moxifloxacin in a splenectomised patient: too much of a coincidence? *Case Rep Infect Dis* 2015;2015:793786.
- Labidi J, Fdhila W, Battikh R, Ellouze S, Ben Abdelhafidh N, Louzir B, et al. Pneumonie à *Legionelle* compliquée d'une insuffisance rénale aiguë par rhabdomyolyse: à propos d'un cas. *Méd Mal Infect* 2006;36:476–8.
- Lavivier C, Bleuze MO, Hantson P, Devos J. Extreme rhabdomyolysis, acute renal failure, and protracted ileus in a case of *Legionella pneumoniae*. *Case Rep Crit Care* 2019;2019:3472627.
- Luckoor P, Salehi M, Kunadu A. Exceptionally high creatine kinase (CK) levels in multicausal and complicated rhabdomyolysis: a case report. *Am J Case Rep* 2017;18:746–9.
- Malvy D, Dessalles PH, Monseu Y, Bonheure JB. Legionnaire's disease and rhabdomyolysis. *Intensive Care Med* 1992;18:132–3.
- McConkey J, Obeius M, Valentini J, Beeson MS. *Legionella pneumoniae* presenting with rhabdomyolysis and acute renal failure: a case report. *J Emerg Med* 2006;30:389–92.
- Posner MR, Caudill MA, Brass R, Ellis E. Legionnaires' disease associated with rhabdomyolysis and myoglobinuria. *Arch Intern Med* 1980;140:848–50.
- Shah A, Check F, Baskin S, Reyman T, Menard R. Legionnaires' disease and acute renal failure: case report and review. *Clin Infect Dis* 1992;14:204–7.
- Shahzad MA, Fitzgerald SP, Kanhere MH. *Legionella pneumoniae* with severe rhabdomyolysis. *Med J Aust* 2015;203:399–400.e1.
- Shimura C, Saraya T, Wada H, Takata S, Mikura S, Yasutake T, et al. Pathological evidence of rhabdomyolysis-induced acute tubulointerstitial nephritis accompanying *Legionella pneumophila pneumoniae*. *J Clin Pathol* 2008;61:1062–3.
- Smeal WE, Schenfeld LA, Hauger W. *Legionella* causing rhabdomyolysis and renal failure. *Postgrad Med* 1985;78:42–4.
- van Tol KM, Sluiter HE. Legionnaires' disease with rhabdomyolysis and acute renal failure. *Neth J Med* 1998;53:43–4.
- Warner CL, Fayad PB, Heffner Jr RR. *Legionella myositis*. *Neurology* 1991;41:750–2.
- Wiegele M, Krenn Cg. Cytosorb™ in a patient with *Legionella pneumoniae*-associated rhabdomyolysis: a case report. *ASAIO J* 2015;61:e14–6.
- Williams ME, Watanakunakorn C, Baird IM, Gerald SE. Legionnaires' disease with acute renal failure. *Am J Med Sci* 1980;279:177–83.
- Soni AJ, Peter A. Established association of legionella with rhabdomyolysis and renal failure: a review of the literature. *Respir Med Case Rep* 2019;28:100962.
- Alaygut D, Torun Bayram M, Kasap B, Soylu A, Türkmen M, Kavukcu S. Rhabdomyolysis with different etiologies in childhood. *World J Clin Pediatr* 2017;6:161–8.
- Bennett MR, O'Connor HJ, Neuberger JM, Elias E. Acute polymyositis in an adult associated with *Mycoplasma pneumoniae* infection. *Postgrad Med J* 1990;66:47–8.
- Berger RP, Wadowksy RM. Rhabdomyolysis associated with infection by *Mycoplasma pneumoniae*: a case report. *Pediatrics* 2000;105:433–6.
- Gosselt A, Olijhoek J, Wierema T. Severe asymptomatic rhabdomyolysis complicating a *Mycoplasma pneumoniae*. *BMJ Case Rep* 2017;2017:bcr-2016-217752.
- Gupta R, Gupta A, Goyal V, Guleria R, Kumar A. *Mycoplasma pneumoniae* associated with rhabdomyolysis and the Guillain-Barre syndrome. *Indian J Chest Dis Allied Sci* 2005;47:305–8.
- Khan FY, Sayed H. Rhabdomyolysis associated with *Mycoplasma pneumoniae* pneumonia. *Hong Kong Med J* 2012;18:247–9.
- Minami K, Maeda H, Yanagawa T, Suzuki H, Izumi G, Yoshikawa N. Rhabdomyolysis associated with *Mycoplasma pneumoniae* infection. *Pediatr Infect Dis J* 2003;22:291–3.
- Steinmann AF, Aks C. Myositis related to mycoplasma infection. *Postgrad Med J* 1993;69:959–60.
- Sullivan P, Brewin A. Evidence of skeletal muscle involvement in psittacosis. *West J Med* 1974;121:232–4.
- Kaiser AB, Rieves D, Price AH, Gelfand MR, Parrish RE, Decker MD, et al. Tularemia and rhabdomyolysis. *JAMA* 1985;253:241–3.
- Gago E, Saavedra J, Gómez Huertas E, Solano A, Martínez Gutiérrez A, Alvarez Grande J, et al. Rhabdomyolysis y fracaso renal agudo. *Nefrología* 1989;9:437–9.
- Chemlal K, Launay O, Carbon C. Infection à *Chlamydia pneumoniae*: une cause exceptionnelle de rhabdomyolyse. *Presse Méd* 1996;25:2049.
- Ljutic D, Radovnikovic G, Kurir TT. Acute renal failure associated with rhabdomyolysis in acute Q fever. *Ren Fail* 2007;29:743–6.
- Schulman P, Piemonte TC, Singh B. Acute renal failure, hemolytic anemia, and *Mycoplasma pneumoniae*. *JAMA* 1980;244:1823–4.
- Riggs SA, Wray NP, Waddell CC, Rossen RD, Gyorkey F. Thrombotic thrombocytopenic purpura complicating Legionnaires' disease. *Arch Intern Med* 1982;142:2275–80.
- Bull PW, Scott JT, Breathnach SM. Henoch-Schönlein purpura associated with Legionnaires' disease. *Br Med J (Clin Res Ed)* 1987;294:220.
- Andrews PA, Lloyd CM, Webb MC, Sacks SH. Acute interstitial nephritis associated with *Mycoplasma pneumoniae* infection. *Nephrol Dial Transplant* 1994;9:564–6.
- Kaneko K, Fujinaga S, Ohtomo Y, Nagaoka R, Obinata K, Yamashiro Y. *Mycoplasma pneumoniae*-associated Henoch-Schönlein purpura nephritis. *Pediatr Nephrol* 1999;13:1000–1.
- Said MH, Layani MP, Colon S, Faraj G, Glastre C, Cochat P. *Mycoplasma pneumoniae*-associated nephritis in children. *Pediatr Nephrol* 1999;13:39–44.
- Bar Meir E, Amital H, Levy Y, Kneller A, Bar-Dayana Y, Shoenfeld Y. *Mycoplasma pneumoniae*-induced thrombotic thrombocytopenic purpura. *Acta Haematol* 2000;103:112–5.
- Wang JJ, Xu Y, Liu FF, Wu Y, Samadli S, Wu YF, et al. Association of the infectious triggers with childhood Henoch-Schönlein purpura in Anhui province, China. *J Infect Public Health* 2020;13:110–7.
- von Vigier RO, Trummler SA, Laux-End R, Sauvain MJ, Truttmann AC, Bianchetti MG. Pulmonary renal syndrome in childhood: a report of twenty-one cases and a review of the literature. *Pediatr Pulmonol* 2000;29:382–8.