



## Demonstration of HLA-DR antigens in normal human brain.

N De Tribolet, M F Hamou, J P Mach, et al.

*J Neurol Neurosurg Psychiatry* 1984 47: 417-418

doi: 10.1136/jnp.47.4.417

---

Updated information and services can be found at:

<http://jnp.bmj.com/content/47/4/417.citation>

---

### References

*These include:*

Article cited in:

<http://jnp.bmj.com/content/47/4/417.citation#related-urls>

### Email alerting service

Receive free email alerts when new articles cite this article. Sign up in the box at the top right corner of the online article.

---

### Notes

---

To order reprints of this article go to:

<http://jnp.bmj.com/cgi/reprintform>

To subscribe to *Journal of Neurology, Neurosurgery & Psychiatry* go to:

<http://jnp.bmj.com/subscriptions>

## Letters

### Demonstration of HLA-DR antigens in normal human brain

Sir: HLA-DR antigens are coded by genes of the major histocompatibility complex

and are expressed on B-lymphocytes and mononuclear phagocytes. They are known to be involved in immune recognition.<sup>1</sup> These antigens have also been identified on cells from some non-haematopoietic tumours and recently we have identified and characterised HLA-DR antigens in human glioma cell lines.<sup>2</sup> In this report, we

show that HLA-DR antigens are expressed by cells present in the white matter of normal adult brain.

Normal brain was obtained from three patients during surgical approach to deep seated meningiomas where normal tissue had to be resected to avoid excessive retraction of the brain. The tissue was

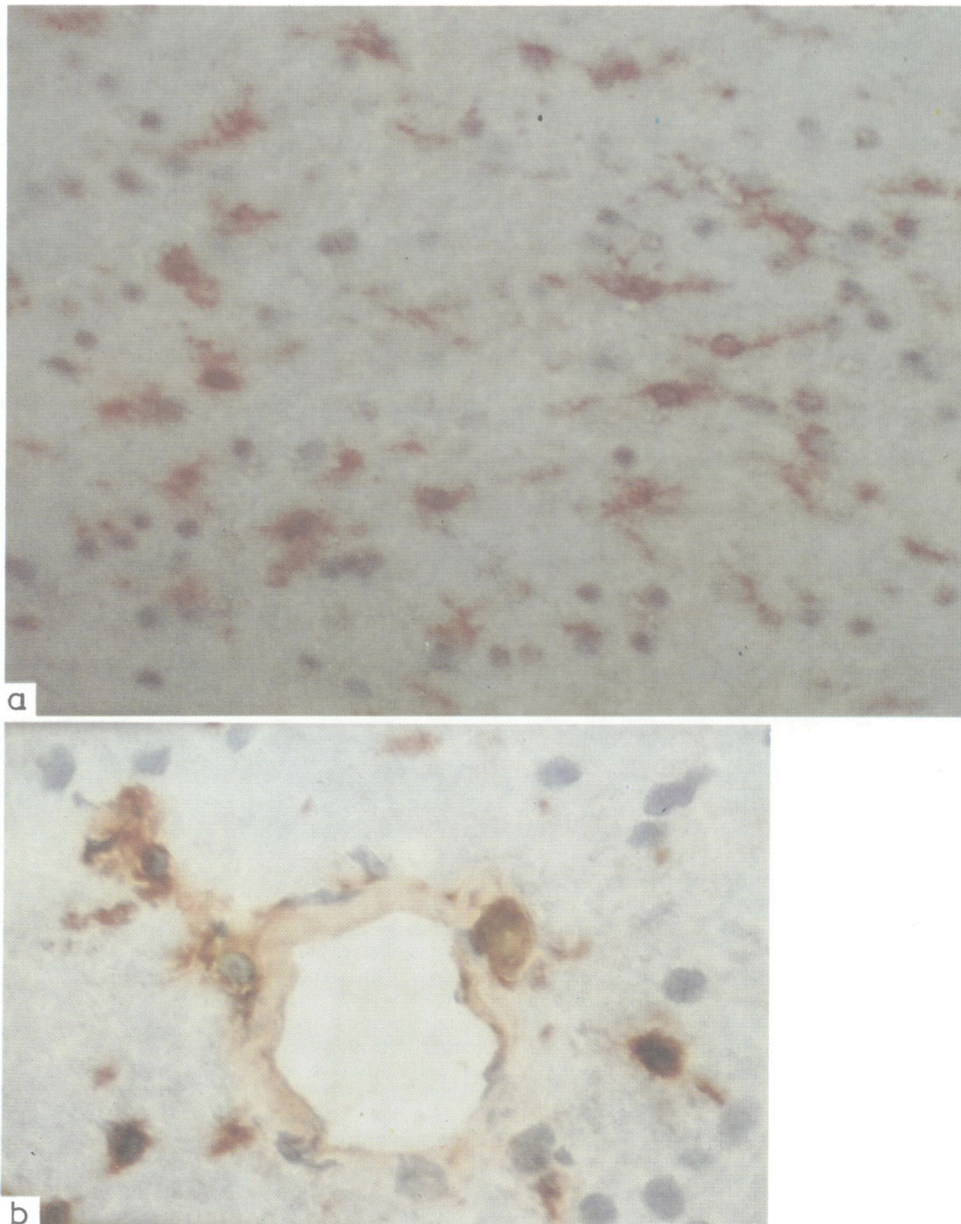


Fig 1 Immunoperoxidase staining for HLA-DR antigen of normal human white matter (A  $\times 200$ ) and (B  $\times 400$ ). Indirect immunoperoxidase was performed using the avidin-biotin system.

immediately frozen in liquid nitrogen. Indirect immunoperoxidase<sup>3</sup> was performed on cryostat sections using a monoclonal antibody D1-12, which reacts with a monomorphic determinant of the HLA-DR molecule.<sup>4</sup> Figure (A) shows the intense HLA-DR staining of cells in the white matter; about 20–30% of the cells are stained. In some of these cells rather long processes can clearly be seen. The stained cells are scattered throughout the white matter. Perivascular cells, and possibly endothelial cells are also stained (fig (B)). As a control, monoclonal antibodies raised against CEA were used and no staining could be seen (data not shown), demonstrating that the binding of D1-12 is not merely nonspecific binding of immunoglobulin to oligodendrocytes. We think that the HLA-DR positive cells may be astrocytes and this is based on the following: (a) the stained cells are not restricted to the area around blood vessels and they have processes; (b) cultured glioma cells, positive for glial fibrillary acidic protein (GFAP), also express HLA-DR;<sup>2</sup> (c) tissue around a brain metastasis with numerous reactive astrocytes, but no lymphoid cells, was very strongly stained for HLA-DR. These are not definitive proofs that the HLA-DR positive cells are astrocytes and some of them may be microglial cells. We plan to perform double staining with anti-GFAP and anti-HLA-DR antibodies in order to clarify this point.

The expression of Ia antigens in the murine brain has been reported,<sup>5</sup> and very recently in the white matter of the temporal lobe of two children who underwent temporal lobectomy for epilepsy.<sup>6</sup> It is not yet clear whether the HLA-DR positive cells in the brain may play a role in the induction of immune responses, but we feel that this possibility should be seriously considered as a mechanism for the development of autoimmune diseases of the central nervous system. Recent experimental work showing that mouse astrocytes present myelin basic protein to encephalitogenic T cell lines *in vitro* strongly favours this hypothesis.<sup>8</sup>

N DE TRIBOLET  
MF HAMOU  
*Neurosurgical Department,  
University Hospital CH-1011 Lausanne,  
Switzerland*  
J-P MACH  
S CARREL  
M SCHREYER  
*Ludwig Institute for  
Cancer Research, Lausanne Branch,  
CH-1066 Epalinges, Switzerland*

## References

- Winchester RJ, Kunkel HG. The human Ia system. *Adv Immunol* 1979;28:221–89.
- Carrel S, de Tribolet N, Gross N. Expression of HLA-DR and common acute lymphoblastic leukemia antigens on glioma cells. *Eur J Immunol* 1982;12:354–7.
- Guesdon JL, Ternynck T, Avrameas S. The use of avidine-biotin interaction in immunoenzymatic techniques. *J Histochem Cytochem* 1979;27:1131–39.
- Carrel S, Tosi R, Gross N, Tanigali N, Carmagnola AL, Accolla RS. Subsets of human Ia-like molecules defined by monoclonal antibodies. *Mol Immunol* 1981;18:403–11.
- Ting JPY, Shigekawa BL, Linthicum DS, Wiener LP, Frelinger JA. Expression and synthesis of murine immune response-associated (Ia) antigens by brain cells. *Proc Natl Acad Sci USA* 1981;78:3170–4.
- Hauser SL, Bhan AK, Gilles FH *et al*. Immunohistochemical staining of human brain with monoclonal antibodies that identify lymphocytes, monocytes, and the Ia antigen. *J Neuroimmunology* 1983;5:197–205.
- Fontana A, Fierz W, Wekerle H. Astrocytes present myelin basic protein to encephalitogenic T cell lines: a step in multiple sclerosis plaque formation? *Nature* (in press).

Accepted 28 October 1983

## Unusual CT scan findings in pseudohypoparathyroidism

Sir: Pseudohypoparathyroidism is a rare hereditary disorder characterised by symptoms and signs of hypoparathyroidism in association with distinctive skeletal and developmental defects.<sup>1</sup> We report a patient with the classical features of pseudohypoparathyroidism with extensive intracranial calcification in the CT scan. Such findings have not to our knowledge been reported previously.

An 18-year-old boy was admitted for uncontrolled generalised seizures from the age of 6 years. He was mentally retarded, short in stature, with a short neck and short stubby fingers and toes. When the hands were closed dimples were seen over the fourth knuckles. There were dense cataracts in both eyes and the teeth were poorly formed. The serum calcium was 1.50 mmol/l phosphorous 3.2 mmol/l and creatinine 88  $\mu$ mol/l. Radiographs of the hand showed short fourth metacarpals in both hands, and short second, third and fourth metatarsals in the feet, the third being the shortest. Radiographs of the skull showed bilateral basal ganglia calcification. CT scan without contrast showed extensive

## Letters

calcification involving the basal ganglia, and the white matter of the frontal, parietal and occipital lobes bilaterally (fig). There was also striking calcification in both cerebellar hemispheres. He was given vitamin D3 in a dose of 600,000 iu orally every week with oral calcium. After 9 months the serum calcium level reached 2.2 mmol/l. He has now been followed up for 24 months and his seizures are well controlled with phenytoin sodium 200 mg/day.

Radiographs of the hands and feet of the patient's mother, elder sister and elder brother also showed short metacarpals and metatarsals. Their serum calcium and phosphorous levels were normal.

Since the first three cases were reported by Albright 40 years ago,<sup>2</sup> the biochemical and endocrine aspects of pseudohypoparathyroidism have been extensively studied.<sup>3</sup> Sixty per cent of these patients show subcutaneous soft tissue calcification and 50% show basal ganglia calcification.<sup>1</sup> However such extensive calcification of the white matter of the cerebral hemispheres and cerebellar parenchyma have not to our knowledge been reported previously. However, CT scan findings in idiopathic hypoparathyroidism have been reported.<sup>4</sup> It is important to note that basal ganglia calcification alone sometimes occurs in normal persons.<sup>5</sup> We are grateful to Professor Sir John N Walton, for his helpful comment and for reading through the manuscript.

We thank Dr K Jagadeesan, Director KJ Hospital, Madras, for the CT scan.

K GOPALAKRISHNA  
*Department of Neurology,  
VHS Medical Centre,  
Madras 600 113*

TS SRINIVASAN  
*Department of Clinical  
Neurology and Research,  
Public Health Centre,  
Madras 600 033, India*

K SRINIVAS  
PK SARAVANAN  
J RAMACHANDRAN  
UMA SHIVAN  
K RAMASEKAR

## References

- Potts JT Jr. Pseudohypoparathyroidism. In: Stanbury JB, Wyngaarden JB, Fredrickson DS, eds. *The Metabolic Basis of inherited Disease*. 4th ed. New York: McGraw-Hill, 1978;1350–65.