

Bifidobacterium longum Bacteremia in Preterm Infants Receiving Probiotics

Claire Bertelli,^{1,2} Trestan Pillonel,^{1,2} Anaïs Torregrossa,³ Guy Prod'homme,⁴ Céline Julie Fischer,³ Gilbert Greub,^{1,4,5,a} and Eric Giannoni^{3,a}

¹Laboratory of Microbial Genomics, Institute of Microbiology, University Hospital Center and University of Lausanne, ²SIB Swiss Institute of Bioinformatics, ³Service of Neonatology, ⁴Laboratory of Bacteriology, Institute of Microbiology, and ⁵Infectious Diseases Service, Centre Hospitalier Universitaire Vaudois and University of Lausanne, Switzerland

Administration of probiotics to premature newborns has been shown to prevent necrotizing enterocolitis and reduce all-cause mortality. In our hospital, we documented 2 cases of *Bifidobacterium longum* subspecies *infantis* bacteremia in newborns receiving probiotics. By comparative genomics, we confirmed that the strains isolated from each patient originated from the probiotics.

Keywords. probiotics; *Bifidobacterium*; genome sequence; newborn; sepsis.

Enteral supplementation of premature newborns with probiotics has been associated with a significant reduction of necrotizing enterocolitis (NEC) and all-cause mortality [1]. Therefore, probiotic products containing bacteria such as *Bifidobacterium longum* subspecies *infantis* (hereafter called *Bifidobacterium infantis*) are increasingly used in clinical practice. Yet, the possibility of probiotics-associated sepsis remains a concern [2]. Indeed, other *Bifidobacterium* species have been documented as agents of bacteremia [3], although generally among patients with significant underlying disease, such as neutropenia. We report 2 cases of *B. infantis* bacteremia in very preterm infants receiving probiotics and compare the genome of both strains recovered from blood cultures with strains recovered from commercial preparations of the probiotics.

Received 5 September 2014; accepted 14 November 2014; electronically published 3 December 2014.

^aG. G. and E. G. equally contributed to this work.

Correspondence: Gilbert Greub, MD, PhD, Institute of Microbiology, Centre Hospitalier Universitaire Vaudois, 1011 Lausanne, Switzerland (gilbert.greub@chuv.ch).

Clinical Infectious Diseases® 2015;60(6):924–7

© The Author 2014. Published by Oxford University Press on behalf of the Infectious Diseases Society of America. All rights reserved. For Permissions, please e-mail: journals.permissions@oup.com.

DOI: 10.1093/cid/ciu946

CASE REPORTS

Case 1

A female infant was born at 26 2/7 weeks of gestation by spontaneous vaginal delivery following premature rupture of membranes. Birthweight was 867 g. She required nasal continuous positive airway pressure with a maximum of 28% of oxygen. A patent ductus arteriosus was closed using indomethacin treatment. Enteral feeding was initiated on the first day of life (DOL) with her mother's own milk. Amoxicillin and gentamicin were started at birth and discontinued on DOL 3 due to a negative blood culture. Infloran (*Lactobacillus acidophilus* 5×10^8 colony-forming units [CFU] and *B. infantis* 5×10^8 CFU twice daily) was administered enterally from DOL 5 to DOL 14. On DOL 14, she developed symptoms suggestive of sepsis with tachycardia, desaturation, and ileus. A complete blood count revealed leukocytosis ($28.5 \times 10^9/L$) with a left shift. Abdominal radiographs were nonspecific with moderately dilated bowel loops. The patient was treated with ceftazidime and vancomycin for 7 days for suspected central venous line-related sepsis. Due to a second episode of feeding intolerance and intestinal distension, she received a 7-day course of imipenem, starting from DOL 21. The anaerobic blood culture taken on DOL14 came back positive for *B. infantis*. Clinical status improved for 2 weeks before a third episode of ileus. A contrast enema was consistent with small bowel obstruction. A laparotomy performed on DOL 40 revealed ileoileal intussusception requiring resection of 15 cm of ileum and primary anastomosis. Histopathology confirmed the diagnosis of intussusception with intestinal necrosis. The patient recovered postoperatively and was discharged home at a postmenstrual age of 40 4/7 weeks.

Case 2

A female infant was born at 28 6/7 weeks of gestation by cesarian section for spontaneous labor following a dizygotic twin pregnancy. Birthweight was 1090 g. She required nasal continuous positive airway pressure with 21% oxygen. Enteral feeding was initiated on DOL 2 with her mother's own milk. Amoxicillin and gentamicin were started at birth and discontinued on DOL 3 due to a negative blood culture. Infloran was administered enterally from DOL 5 to DOL 9. She presented on DOL 10 with abdominal distention, tenderness, ileus, and rapid clinical deterioration with hypotension, lactic acidosis, thrombocytopenia, and coagulopathy requiring intubation and multiple transfusions with fresh frozen plasma, platelets, and blood. A complete blood count revealed leukopenia ($2.0 \times 10^9/L$) with a left shift, and C-reactive protein increased to

240 mg/L. The clinical presentation together with radiologic evidence of pneumatosis intestinalis and portal venous gas was consistent with NEC stage III according to Bell's criteria. The patient was treated with ceftazidime, amikacin, and metronidazole. Blood cultures taken on DOL 10 were positive for *B. infantis*. Enteral feeding was reintroduced on DOL 22. Due to persistent feeding intolerance, a laparotomy was performed on DOL 42, which revealed intestinal necrosis and jejunal perforation requiring resection of 25 cm of small intestine and a primary anastomosis. The patient recovered from surgery and was discharged home at a postmenstrual age of 40 4/7 weeks.

BACTERIAL GENOMICS

Eight bacterial strains were sequenced ([Supplementary Data](#)) to ascertain that the 2 *B. infantis* strains causing bacteremia in these neonates originated from the Infloran capsules, and to investigate the occurrence of mutations that could have triggered an increased virulence. Two *B. infantis* strains were isolated from blood cultures, and 6 strains were retrieved directly from capsules of Infloran (Figure 1A).

Average nucleotide identity confirmed that all strains belonged to the species *B. longum* subspecies *infantis* ([Supplementary Table 1](#)). All strains were highly similar and no region was uniquely found in the strains that caused bacteremia (BIC1206122787 and BIC1401111250) compared with strains retrieved from Infloran capsules. Most of the differences observed between genomic sequences were apparently due to the assembly software that stops elongating contigs at slightly different positions.

To confirm the clonality of patient strains and probiotics strains, an analysis of single-nucleotide polymorphisms (SNPs) was carried out using kSNP V2.1.2 software on all complete genomes of *B. longum* available in public databases as well as on the draft genomes of all strains sequenced in the present study (Figure 1B). SNP calling by mapping reads of each strain against strain BIC1307292462 identified between 4 and 8 SNPs (Figure 1A and [Supplementary Table 2](#)). Although one could have expected that strains recovered from the same capsule (BIC1401212621a and BIC1401212621b, BIB1401272845a and BIB1401272845b) would be more similar, no common SNP was found between these pairs of genomes. In addition, in 2 cases, common SNPs were found between a capsule strain and a patient strain ([Supplementary Table 2](#)). The strains BIC1206122787 from case 1 and BIC1401111250 from case 2 presented 2 and 3 unique SNPs, respectively, but did not have any SNP in common ([Supplementary Table 2](#)).

DISCUSSION

Among the >5000 premature newborns who have been included in trials of probiotics prophylaxis, no cases of probiotics-

associated sepsis have been reported [1]. A recent review of the literature [4] identified 2 cases of bacteremia associated with probiotics in premature newborns [5, 6]. Therefore, probiotic-associated sepsis is likely to be a rare event in premature newborns. However, the true incidence could be underestimated, as anaerobic blood cultures are not always obtained in newborns with suspected infection. Moreover, as underlined by Tena et al, when identified from other sources, *Bifidobacterium* may be overlooked, since they are generally considered as non-pathogenic bacteria [7]. Indeed, these anaerobic gram-positive nonsporulating rods are part of the physiological oral, vaginal, and intestinal flora [8].

In our first patient, intussusception was diagnosed 3 weeks after the episode of *Bifidobacterium* sepsis. Because intussusception is extremely rare in premature newborns and presents with unspecific symptoms that often lead to a delayed diagnosis [9], we cannot confirm or refute a causal relationship between *Bifidobacterium* sepsis and intussusception. The second patient was affected by advanced NEC, which could not be prevented by administration of probiotics. We speculate that the presence of *Bifidobacterium* in blood cultures is likely to be the consequence of intestinal necrosis rather than the cause of NEC. However, *Bifidobacterium* translocation could have an impact on intestinal necrosis and systemic inflammation in premature newborns who develop NEC despite probiotic therapy.

The small number of SNPs identified between both strains isolated from blood culture and all strains recovered from probiotics suggests that the strains involved in bacteremia were originating from probiotics. Moreover, the pattern of SNPs observed indicates that the probiotic capsules contain mixed but stable populations of *B. longum* strains all belonging to the *infantis* subspecies, but exhibiting few mutations in their genomes. Bacterial culture was minimized to a single passage for clone picking followed by a second culture to obtain sufficient DNA for subsequent analysis. The occurrence of mutation during culture at the bacteriology diagnostic laboratory should thus be insignificant and the variant should not have reached fixation in the bacterial population. The 2 strains that caused bacteremia do not share a particular SNP, but each strain presents some unique SNPs. Although to our knowledge these mutations arose in various proteins that were not previously linked to increased virulence, mutations observed in the type IV secretory pathway virB4 component, in a transcriptional regulator, or in a hypothetical protein might have provided an increased virulence to the bacterium.

CONCLUSIONS

We identified 2 cases of bacteremia in very preterm infants that likely resulted from the administration of probiotics. Thus, the

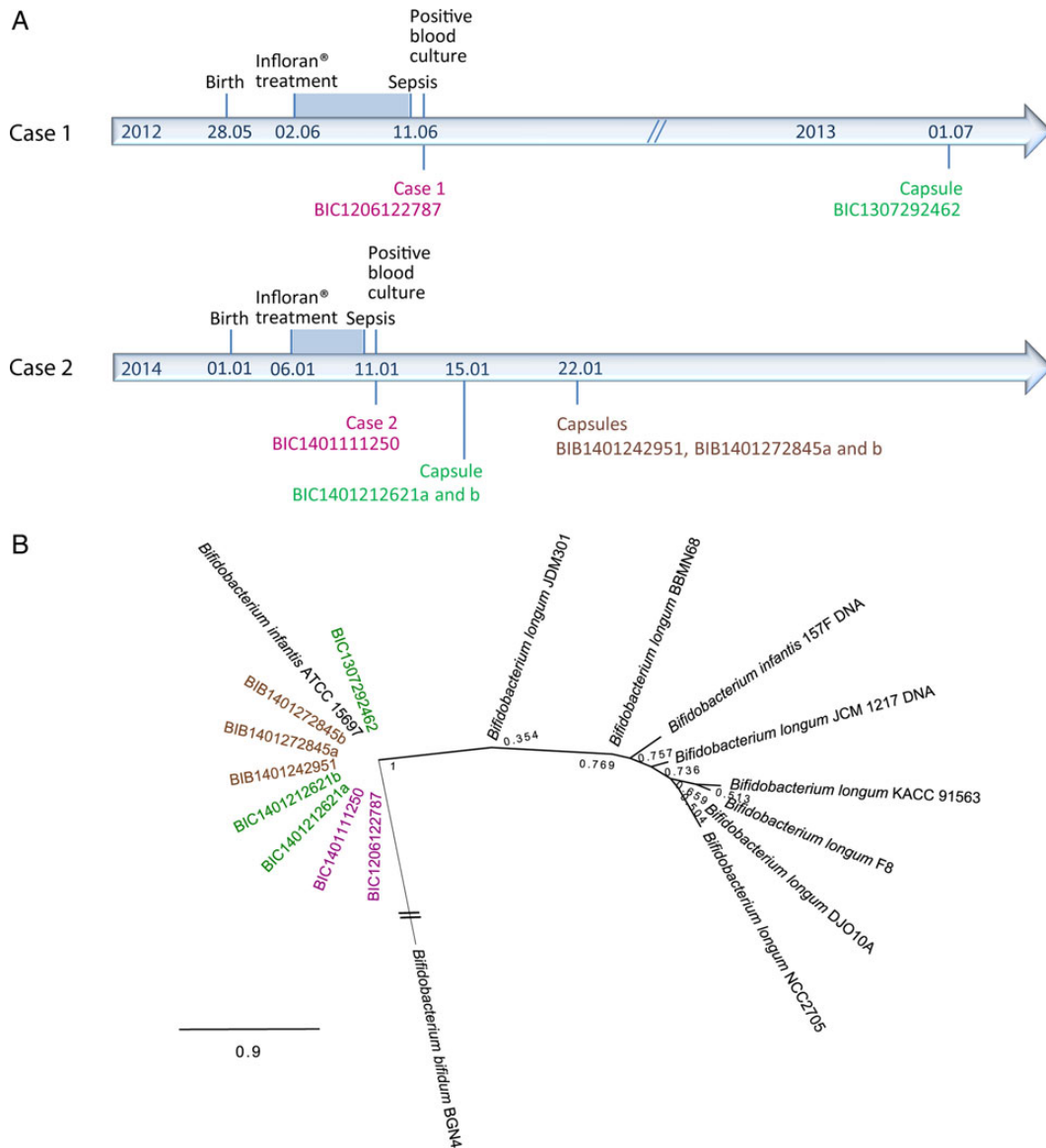


Figure 1. Timeline of events and phylogeny. *A*, Timeline of events for clinical cases and strain retrieval. Clinical information is shown in black. Strains retrieved from blood culture are shown in purple. Strain BIC1206122787 was retrieved from blood culture of case 1 in 2012. Strain BIC140111250 was retrieved from blood culture of case 2 in 2014. Strains retrieved from Infloran capsules of the University Hospital of Lausanne are shown in green. Strain BIC1307292462 was isolated by culture of an Infloran capsule in 2013 and is unrelated to any of the previously mentioned cases. Strains BIC1401212621a and BIC1401212621b were grown from 2 colonies isolated from a single Infloran capsule recovered at our institution in 2014, at the time of case 2 bacteremia. The capsule likely belongs to the same lot as the Infloran capsules administered to case 2, even though the lot number of the capsule administered to patient 2 was not recorded. Strains cultured from Infloran capsules obtained from the neonatal intensive care unit of the Charité University Hospital Berlin (Germany) are shown in brown (BIB1401242951, BIB1401272845a, and BIB1401272845b). The Charité University Hospital Berlin claims no case of bacteremia due to *B. infantis*. BIB1401272845a and BIB1401272845b are 2 colonies grown from the same capsule of Infloran. *B*, Phylogenetic relatedness of *Bifidobacterium longum* strains. This figure represents the phylogenetic tree of all *B. longum* strains available as full genome sequences in public databases as well as the 8 strains investigated in this study. The tree was inferred using maximum likelihood as part of the software kSNP. Similar to (*A*), strains retrieved from blood culture are shown in purple, and strains retrieved from Infloran capsules are shown in green. Capsules from the Charité University Hospital Berlin are displayed in brown. The support is shown next to each node.

safety of routine clinical use of probiotics is questioned in this population. Future clinical trials should include surveillance of blood cultures aimed at detecting anaerobic bacteria and long-

term follow-up of infants with probiotic-associated bacteremia. This work also underlines the usefulness of rapid bacterial genome sequencing to explore the relatedness of different strains,

in such settings, with a much better resolution than multilocus sequence typing or pulsed-field gel electrophoresis.

Supplementary Data

Supplementary materials are available at *Clinical Infectious Diseases* online (<http://cid.oxfordjournals.org>). Supplementary materials consist of data provided by the author that are published to benefit the reader. The posted materials are not copyedited. The contents of all supplementary data are the sole responsibility of the authors. Questions or messages regarding errors should be addressed to the author.

Notes

Acknowledgments. We thank S. Aeby for his technical help.

Financial support. This work was supported by a matching grant to G. G. provided by the General Direction of the University Hospital of Lausanne and by the Department of Laboratories, supporting an institutional project of genomics of medical importance.

Potential conflicts of interest. All authors: No potential conflicts of interest.

All authors have submitted the ICMJE Form for Disclosure of Potential Conflicts of Interest. Conflicts that the editors consider relevant to the content of the manuscript have been disclosed.

References

1. AlFaleh K, Anabrees J. Probiotics for prevention of necrotizing enterocolitis in preterm infants. *Cochrane Database Syst Rev* **2014**; 4:CD005496.
2. Hempel S, Newberry S, Ruelaz A, et al. Safety of probiotics used to reduce risk and prevent or treat disease. *Evid Rep Technol Assess* **2011**; 200:1–645.
3. Bourne KA, Beebe JL, Lue YA, Ellner PD. Bacteremia due to *Bifidobacterium*, *Eubacterium* or *Lactobacillus*; twenty-one cases and review of the literature. *Yale J Biol Med* **1978**; 51:505–12.
4. Luedtke SA, Yang JT, Wild HE. Probiotics and necrotizing enterocolitis: finding the missing pieces of the probiotic puzzle. *J Pediatr Pharmacol Ther* **2012**; 17:308–28.
5. Guenther K, Straube E, Pfister W, Guenther A, Huebler A. Severe sepsis after probiotic treatment with *Escherichia coli* NISSLE 1917. *Pediatr Infect Dis J* **2010**; 29:188–9.
6. Jenke A, Ruf EM, Hoppe T, Heldmann M, Wirth S. *Bifidobacterium* septicemia in an extremely low-birthweight infant under probiotic therapy. *Arch Dis Child Fetal Neonatal Ed* **2012**; 97:F217–8.
7. Tena D, Losa C, Medina MJ, Sáez-Nieto JA. Peritonitis caused by *Bifidobacterium longum*: case report and literature review. *Anaerobe* **2014**; 27:27–30.
8. Mahlen SD, Clarridge JE 3rd. Site and clinical significance of *Alloscardovia omnicolens* and *Bifidobacterium* species isolated in the clinical laboratory. *J Clin Microbiol* **2009**; 47:3289–93.
9. Avansino JR, Bjerke S, Hendrickson M, Stelzner M, Sawin R. Clinical features and treatment outcome of intussusception in premature neonates. *J Pediatr Surg* **2003**; 38:1818–21.