

Mémoire de Maîtrise en médecine No 908

Tension-band wiring of olecranon fractures - Biomechanical analysis of different fixation techniques

Etudiant

Philipp Suter

Tuteur

Prof. Dr. med. Emanuel Gautier
Médecin chef

Clinique orthopédique, HFR Hôpital cantonal Fribourg

Expert

Prof. Dr. med. Alain Farron
Médecin chef de service, orthopédie et traumatologie, CHUV

Lausanne, 24. novembre 2012

Content

1. Abstract.....	p. 3
2. Introduction	p. 3
3. Fracture classification	p. 4
4. Fixation methods.....	p. 5
4.1. Plate fixation	p. 6
4.2. Intramedullary fixation	p. 7
4.3. Olecranon excision	p. 7
4.4. Polyester or polyethylene tension suture.....	p. 8
4.5. Tension-band wiring and its complications.....	p. 8
5. Aim of the study	p. 13
6. Materials and methods.....	p. 13
6.1. First model.....	p. 13
6.2. Second model.....	p. 17
6.3. Third model.....	p. 17
6.4. Fourth model	p. 18
6.5. Final model.....	p. 19
7. Biomechanical testing	p. 21
8. Results	p. 22
9. Discussion.....	p. 24
10. Conclusion	p. 26
11. References.....	p. 26

1. Abstract

Tension-band wiring is a recognised standard treatment for fixation of olecranon fractures. The classical operation technique is well known and widespread among the orthopaedic surgeons.

Nevertheless complications like K-wire migration or skin perforation and difficult technical as well as anatomical prerequisites require better-adapted operation fixation methods.

In older female patients a cut through of the Kirschner wires with concomitant secondary displacement was observed. We intent to develop a new, better adapted operation technique for olecranon fractures in the old patients, in order to decrease complications and follow-up procedures.

In this study we compare two different K-wire positions: 10 models of the classical AO tension-banding to 10 models with adapted K-wire insertion.

In this group the K-wire passes from the tip of the olecranon to the posterior cortical of the distal fragment of the ulna. We tested maximal failure load, maximal opening angle as well as maximal work to achieve maximal force.

In either technique we were able to determine different variables: a maximal failure load of more than 600N ($p = 0.94$) for both fixation methods and a maximal opening angle for both techniques of about 10° ($p = 0.86$). To achieve the maximal force our modified technique required a slightly increased work ($p = 0.16$).

In this study no statistical significant differences between the two fixation techniques was shown. This leads to the conclusion that the modified version is comparable to the classical operation technique considering the stability, but due to the adaption of the angle in the modified procedure, less lesions of neurovascular structures on the volar side can be expected. To support our findings cadaver studies are needed for further investigations.

2. Introduction

Transverse olecranon fractures are one of the most common fractures of the upper extremity: Rommens et al. showed that this kind of fractures account for 10% of all

upper extremity fractures. (1) A surgical intervention is indicated after both, high- and low-energy injury, or when the fracture is displaced. (2–6)

Three main types of injury can cause an olecranon fracture: 1. direct violence, e.g. a fall on the tip of the elbow 2. indirect violence, e.g. a fall on the outstretched arm with the elbow in its flexed position and contracted triceps or 3. a combination of direct and indirect violence. This combination of direct and indirect force is known to cause, in the majority of the cases, a displaced and comminuted fracture. (7,8)

The transverse or oblique fractures involve the semilunar notch, the pull of the triceps muscle on the olecranon defines the spatial separation of the bone fragments. Limited separation of these fragments may be due to the presence of an intact triceps aponeurosis and periosteum of the olecranon, which, in addition to the lateral ligaments and capsule of the elbow joint, resist displacement of the fracture. (7)

Olecranon fractures usually unable the patient to move its elbow and are accompanied by strong pain and discomfort. The skin is swollen, bruised or contused. Additional to primary investigations, radiography is required to assess the degree of the injury: in a lateral view, the fracture line is clearly visible; therefore a lateral radiography is essential to clarify the degree of articular impact, displacement and fragmentation. Complex fractures are often associated with an anterior dislocation of the forearm, a so-called transolecranon fracture dislocation, or a posterior type II Monteggia lesion. But even simple transverse or oblique fractures can lead to dislocations. (9)

3. Fracture classification

Many different classifications exist for the olecranon fractures, known are the AO classification, Mayo-clinic classification, Schatzker classification modified by Schmeling, Horne and Tanzer or the Wadsworth system. Here mentioned will be the AO (Arbeitsgemeinschaft für Osteosynthesefragen) classification and the Mayo clinic classification, which are the most widely used classifications in the clinic and in the published articles. The AO classification of proximal radius and ulna fractures is divided into three broad groups. Type A are extra-articular fractures either of the ulna or the radius and type B are intra-articular fractures while the type B1

specifically an intra-articular fracture of the ulna. In addition the type C are intra-articular fractures of the ulna and the radius. (10–13)

After the Mayo classification the olecranon transverse fractures can be classified into different groups. Type I fractures have less than 2 mm of displacement, type II fractures are displaced by more than 2 mm, but the joint is stable, and type III fractures are displaced and associated with concomitant subluxation or dislocation of the elbow joint. Every fracture can furthermore be subdivided into noncomminuted (A) or comminuted (B). (10,12)

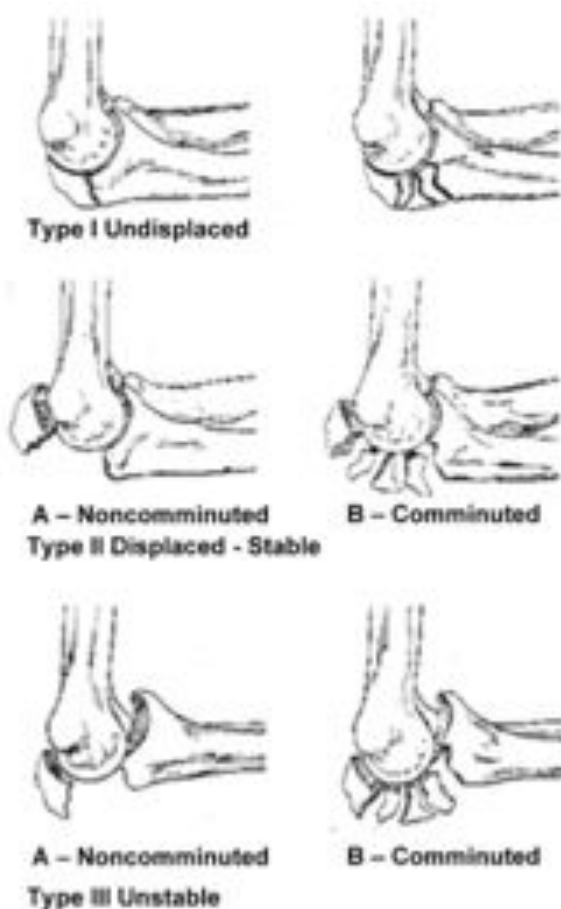


Fig. 1: The Mayo classification

The diagram shows the Mayo classification for olecranon fractures. Type I fractures with less than 2 mm of displacement, type II fractures with displaced by more than 2 mm with a stable joint, type III fracture with displaced and associated concomitant subluxation or dislocation of the elbow joint. Every fracture type is furthermore subdivided into noncomminuted (A) and comminuted (B).

Modified to Newman *et al.*, Olecranon fractures. *Injury*. 2009 Juni;40(6):575–81. (10)

4. Fixation methods

Many methods of internal fracture-fixations have been described: on one hand, the treatment depends on the complexity of the fracture on the other hand it depends on the patient's comorbidities. But at any rate, complete anatomical restoration of the joint is the principal purpose of the definitive treatment. (14) Non-displaced fractures

can be treated with short period immobilization, followed by a gradually increasing range of motion. (15) In old people, with a poor quality of bone making osteosynthesis difficult, conservative treatment gives good functional results and doesn't reduce the daily activities of the patient. Old people possibly easier accept worse results than people with full level of physical activity; this should be considered when this treatment is chosen. (16,17) But in most instances a prompt surgical intervention is required due to the instability of the bone-structure, the fracture itself and the involvement of the joint. The instability of the fracture can be explained by the displacement of the bone-fragments that, in turn, is caused by the tension of the triceps muscle onto the bony prominences of the (fractured) olecranon. The surgery must be precise since any residuals irregularity of the articular surface causes limited motion, elbow articular disability, residual stiffness, delayed recovery or a posttraumatic osteoarthritis. (7,18)

The fixation should be strong enough to allow a gentle passive and active mobilisation. Exercises should already be started on the first day post-operatively, well before radiograms show evidence for complete union. The reason for such an early mobilisation is the tension-band principle, on which the whole stabilization is based: the aim is to create a gentle dynamic compression across the fracture plane. (9,12,18,19) Its recommended that the active movements should not pass 8 kg weight of loading. (20,21)

In the past many operation techniques were suggested: the double K-wires in combination with a figure of eight tension-band wiring, cancellous screws, cancellous nailing with tension-band wiring, plate fixation, screws, olecranon sleds and partial excision of the olecranon fragment. (22) Some of the experts would even go for combination of different fixation methods, e.g. the medullary fixation combined with a tension-band wiring. (18) But till now none of this operation methods is perfect yet, concerning the side effects and complications. There exists much space to ameliorate and improve the actually used methods.

4.1. Plate fixation

Plate fixation is gaining more and more recognition for treating displaced olecranon fractures. A grand variety of plate fixations has been reported since the first description by Zuelzer in 1951. (23) This fixation is a safe and effective option, with a low rate of hardware removal and which allows an early unrestricted

rehabilitation. (11) The plate fixation requires a longer operation time, but did not lead to an increased complication rate, compared to the tension-band fixation. (24) The non-union rate of this technique is around 10%. The high healing rate of 90% is due to a high static interfragmentary compression and high fixation stability. (25) The biomechanical stability of the fracture after plate fixation is comparable or even slightly superior compared to the tension-band fixation. (26) Plate fixation can be used for every type of olecranon fractures but is most appropriate for severely comminuted fractures, distal fractures involving the coronoid process, oblique fractures distal to the midpoint of the trochlear notch, Monteggia fracture-dislocations of the elbow and nonunions. (15)

4.2. Intramedullary fixation

Another commonly used technique is the intramedullary fixation using screws or nails. (27) Rush and Rush published the first forms of intramedullary treatments with rods in 1937. In 1986 Johnson published the use of the AO cancellous bone screws. (11) Currently, this rigid fixation is an attractive treatment option, because almost every screw system can be used and a low complication rate can be observed. (15,28) The intramedullary screws may also be combined with a tension-band. (29) On one hand, this technique has a superior clinical performance, a better patient outcome and lower health care costs than the plate technique. (30) On the other hand despite having lower primary stability, the screw fixation showed in the clinical outcome comparable results to the tension-band wiring. These results were confirmed in several biomechanical studies. (26,28,29,31–34) Intramedullary nailing has about the same indication than the tension-band wiring and includes simple, non-comminuted transverse fracture patterns. (11)

4.3. Olecranon excision

Olecranon excision and triceps advancement still is a viable treatment option: in this method at about 50% of the articular surface can be excised, which allows the elbow joint to remain stable. This operation is only possible when the medial collateral ligament, the interosseous membrane, the distal radioulnar joint and specially the coronoid are intact; otherwise there is a risk that the joint becomes unstable. (11,35) The outcome after excision of the distal fragment is variable, because frequently the joint loses its stability and a potential triceps power loss may occur. Fragment excision and triceps advancement is appropriate in selected cases

in which open reduction seems unlikely to be successful, such as in osteoporotic elderly patients, with severely comminuted fractures or in low-demand patients. (11,35–37)

4.4. Polyester or polyethylene tension suture

Another proposition for olecranon fractures in patients with osteoporotic bones is the polyester or polyethylene tension suture, combined with the classical K-wire positioning. (38–40) Elderly people, or people with osteoporotic bones have weaker muscular forces and weaker bone mass. Therefore tension-band wiring with stainless steel seems to be less appropriate, due to the increased risk of suffering from complications like K-wire migration. (11,12,15,38–41) The results for this alternative tension-band constructs are variable: whilst some studies showed comparable results concerning the fracture stability, others showed less good results compared to the classic tension-band wiring. (38–40,42)

4.5. Tension-band wiring

The most commonly used techniques for surgically managing olecranon fractures is the tension-band wiring. In fact, a study referred to this technique as the “gold standard” for treatment of displaced, minimally comminuted olecranon fractures. (43) This operation with an open reduction of a transverse olecranon fracture is the AO technique with a figure of eight loop tension-band wiring. One of the first to describe an operative treatment of a displaced olecranon fracture was Lister in 1883, when he used aseptic conditions and “loop wire” fixation to internally fix the fracture. (44) Pauwels in 1935 and Knight in 1949 made Adjustments of this technique. (11) Afterwards Weber and Vasey originally introduced the figure of eight tension loop technique in 1963. (45) The simple loop, the previous method of choice, is not as satisfactory as the figure of eight loops. (18) The technique consists of two K-wires inserted from the tip of the olecranon through the long axis of the ulna and a tension-band wire loop. (13) In the classical technique only two locking devices were used, which, after Molloy *et al.* is enough. (27) Other studies showed that the amount of locking devices used, correlates with the prevention of wire-migration. (46)

In our classical model two K-wires were used. They were placed in a parallel, antegrade manner at a distance from the tip of the olecranon to the anterior cortex

of the coronoid process of the ulna, to prevent wire migration. (10,47) The K-wires are obliged to pass as close as possible by the humeroulnar joint, without penetrating into the articulation. (10) It is recommended to introduce the K-wires trans-cortically instead of introducing them intramedullary, thus leading to a decreased complication rate and a five times reduced need to remove the hardware. Other biomechanical fixation-studies confirm that the transcortical method offers an increase in resistance to displacement of the K-wires. (47,48) It is important, to not advance these wires far beyond the cortex, otherwise, the anterior neurovascular bundle is at risk. (49) The tension-band wire has a transosseous anchorage in the distal part of the ulna and reaches a trans-tendinous anchorage proximally at the triceps insertion. One should make sure to grasp the triceps tendon as close as possible to the bone surface of the ulna in order to increase the stability. (12,15) Both wires of the figure of eight loop have to be tightened separately, to produce a symmetrical tension, one twist over the ulna and the other twist over the radius. (26,50)

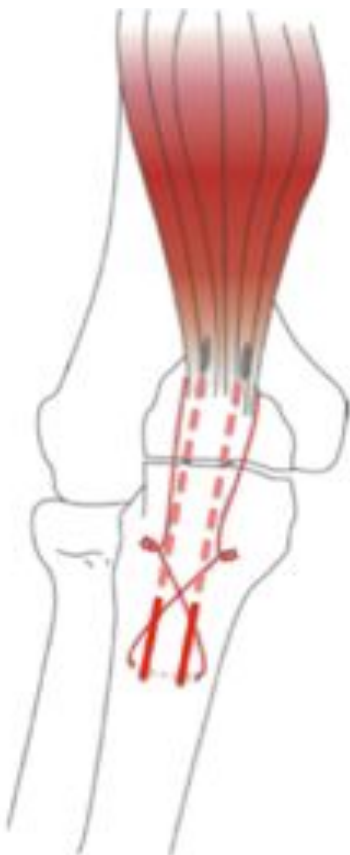


Fig. 2: Antero-posterior view of the classic AO technique tension band wiring construct.

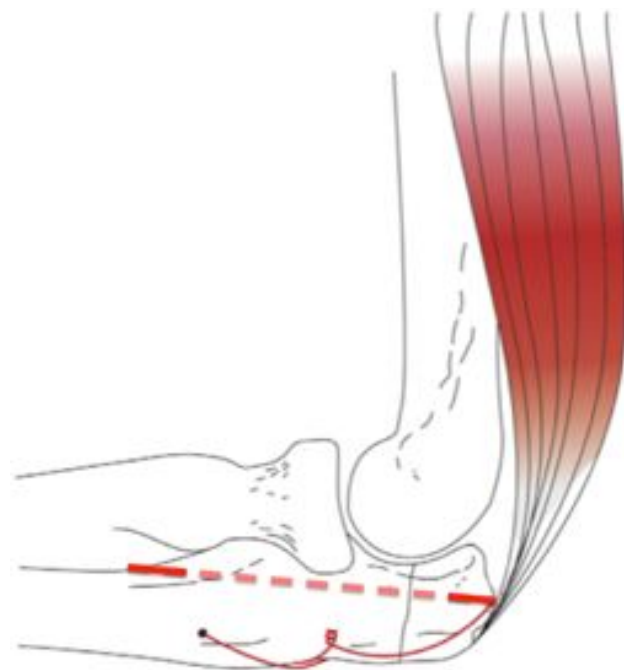


Fig. 3: Lateral view of the classic AO technique tension band wiring construct.

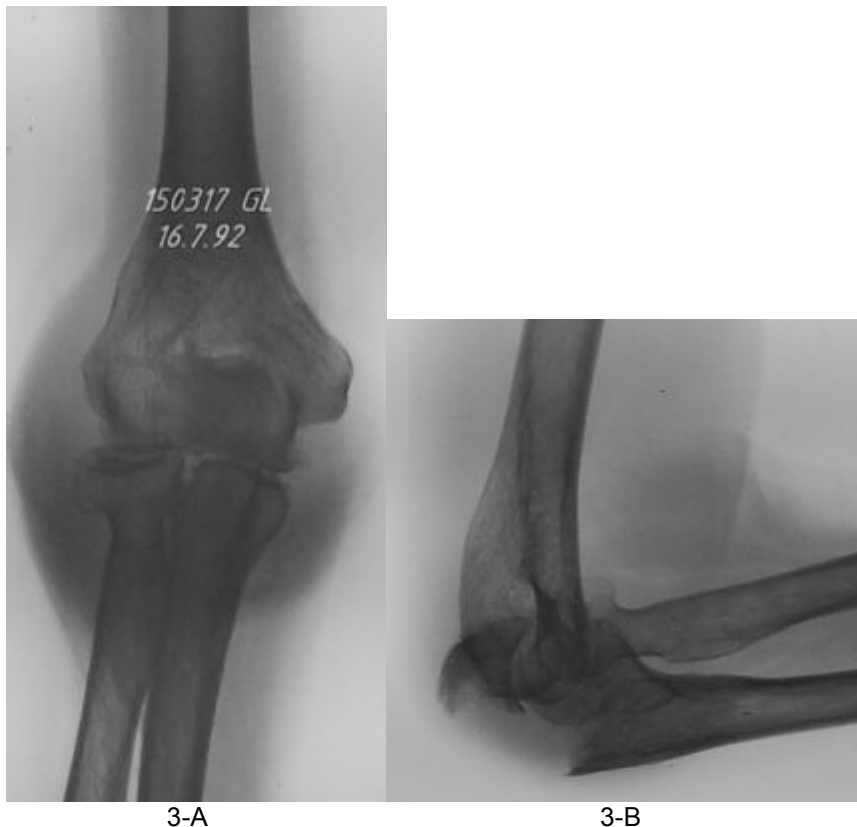
Modified to Newman *et al.*, Olecranon fractures. Injury. 2009 Juni;40(6):575–81. (10)

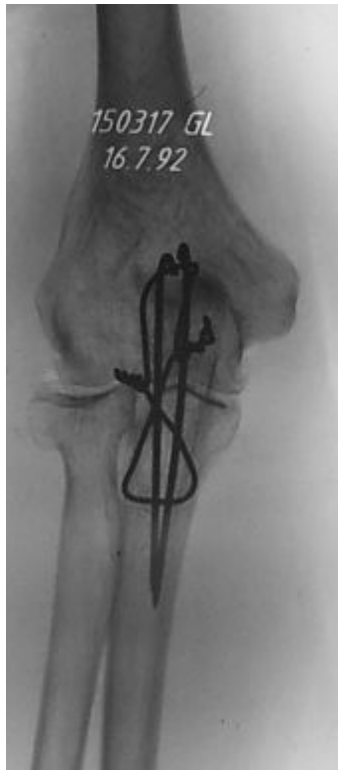This particular tension-band wiring construct converts the tensile force, generated by the triceps muscle contraction, into compressive force along the fracture plane with the trochlea functioning as a fulcrum. (12,18,48) By bending the elbow, an intermittent dynamic compression at the fracture gap is achieved, thereby promoting the healing-process. (5,31,32)

Many modifications of the standard tension-band wiring fixation and other alternative fixation methods have been developed in the past. All with regard of the same intention: to improve the stability of fixations of olecranon fractures and to reduce the complications of the operation. (51,52)

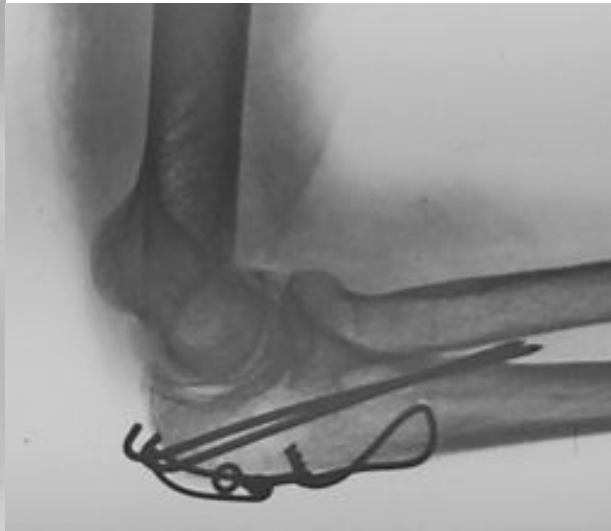Complications of tension-band wiring

Unfortunately there are many problems accompanying the fixation of the fractured olecranon by the tension-band wiring technique. The most investigated and problematic step is the cutting-out of the K-wires with subsequent secondary displacement of the fracture.

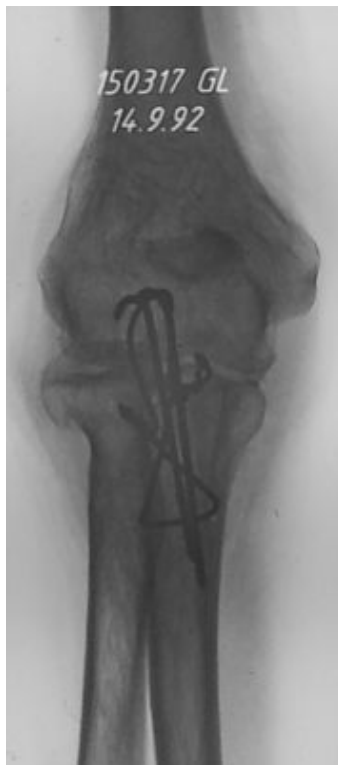



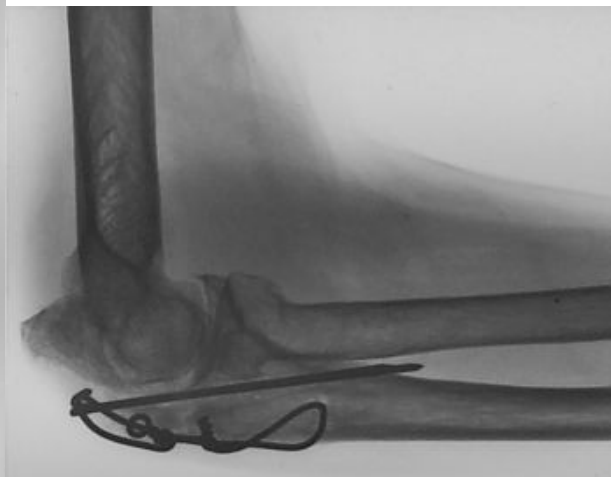3-C



3-D



3-E



3-F

Fig. 3: Radiographs of a noncomminuted, stable, displaced olecranon fracture of a 75 years old female patient. Classic AO technique.

Fig. 3-A: Antero-posterior view, before treatment.

Fig. 3-B: Lateral view, before treatment.

Fig. 3-C: Antero-posterior view after treatment with the classic AO technique.

Fig. 3-D: Lateral view after treatment with the classic AO technique.

Fig. 3-E: Antero-posterior view after failure.

Fig. 3-F: Lateral view after failure.

Other known complications are delayed union or non-union of the fracture. In addition postoperative hematoma, skin break down with a superficial infection or the prominence of the K-wire at the insertion-site with residual pain can occur. Lesions of the ulnar nerve, the neurovascular bundles on the anterior part of the ulna or the median nerve palsy are other well described complications of open reduction of internal fixations of olecranon fractures. The K-wires don't even necessarily need to penetrate into the soft tissue of the deep flexor compartment of the forearm to cause such lesions.

To exclude nerve damage caused by the surgical intervention, after every olecranon operation the anterior interosseous nerve has to be tested with respect to its sensory and motor function. If the nerve is lesioned one would be unable to form actively a complete circle using the thumb and the index finger. (49,53) Furthermore heterotopic ossification, post-traumatic osteoarthritis or impaired forearm rotation can be observed after the operation. (5,8,13,15,43,44,47,54–59)

K-wire migration with olecranon fragment dislocation is a frequent mechanical complication. The instability of K-wires can lead to opening of the fracture gap, with the risk of bony non-union. (13) Furthermore, the K-wire migration often leads to skin irritation and wound-healing problems.

This grave complication can probably be eliminated by the proper fixation-technique and by keeping in mind the following rules and findings: (44) 1. If the figure-of-eight loop insertion in the ulna is too distal, an opening of the fracture in the focus centre can be observed. 2. If the transosseous passage of the wires is too superficial, the bone bridge can break and secondary instability occurs. 3. If the anchorage of the wires in the triceps tendon is insufficient, a posterior displacement of the olecranon can occur. If the K-wires are cutting out, a secondary surgical intervention is indicated. (1,54,56)

Helm *et al.* reported that 82% of the patients in his study population needed hardware removal after tension-band wiring and in the study of Romero *et al.* up to 70% needed this second intervention. (56,59) Hume and Wiss performed a randomised prospective trial with 41 patients suffering from displaced olecranon fractures. (24) They were treated either with tension-band wiring or plating. Eight patients in the tension-band wiring group (42%) complained of hardware problems, compared to one patient in the plating group. Hardware removal is not necessarily

negatively influencing the fracture's stability. Van der Linden *et al.* and other studies (Rommens) showed a remarkable better long-term outcome and a better range of motion after hardware removal compared to patients with hardware remaining in place. (1,13) Therefore it is even recommended to remove the osteosynthetic material after fracture healing.

Tension-band wiring however is not recommended for unstable, oblique fractures, due to the higher incidence of loss of fixation and subsequent mal-union or non-union. These fractures require different treatment options. (9)

Variable other publications state that with supplementary added Kirschner wires for the control of rotational stability, an AO technique can even be applied to treat comminuted olecranon fractures. (48,60)

5. Aim of the study

Using a biomechanical model we compared the stability of fixation for two different tension-band wiring techniques for olecranon fractures. The different tension-band wirings were compared to the traditional AO tension-band wiring technique, the gold standard for olecranon fracture fixations. (33) We hypothesize that the new technique provides equal or better stability compared to the traditional tension-band fixation and lower risk of secondary displacement and K-wire cut through. A modified K-wire insertion angle is compared with the classical insertion technique as gold standard.

6. Materials and methods

During the study different models were elaborated to allow the assessment of stability of fixation and the risk of cut through.

6.1. First model

The first model tested was the AO tension-band wiring on an artificial ulna model: the ulna models (Synbone, Malans, Switzerland) reflect the exact proportions and anatomical dimensions of the human ulna. In the human anatomy, the humerus is the thrust bearing in the elbow joint. To replace the humerus, we used a thrust bearing out of medical high viscosity low-heat cement, which was perfectly adapted

to the synbone ulna. (Copal spacem, Heraeus, Wehrheim, Deutschland)

A small medial transverse arthrotomy on the olecranon articulation was introduced to ensure a complete reduction of the osteotomy. A sagittal saw was used to create an osteotomy in the mid-portion of the semilunar notch to simulate an olecranon fracture.

The osteotomy was reduced with two Kirschner wires 1.6 mm in diameter. They were inserted from the tip of the olecranon to the anterior ulnar cortex, where they penetrate the cortex distal to the coronoid process. A precise positioning of the drill holes can be achieved by stabilizing the drill through a guidance rail. (14) So every K-wire was placed identically. Perioperative control radiographies have to be executed to ensure the correct position of the K-wires. In addition to the long drill holes a 2mm transverse drill hole was placed 3,5 cm distal to the fracture site in the posterior cortex of the distal fragment. One stainless steel wire (SS316L, Synthes, Switzerland) is inserted in the drill hole, whilst another wire surrounds the humerus and penetrates the triceps tendon. For the creation a figure of eight tension-band, the ends of the stainless steel wire that pas the drill hole is have to be twirled with an end of the wires that penetrates the triceps tendon opposite side. (picture) They are tightened by a two-knot technique by placing twists in each knot.

In the modified version we changed the angle of insertion of the Kirschner wires. The Kirschner wires perforate the posterior cortical of the distal fragment of the ulna, distal to the coronoid process. They were introduced at the tip of the olecranon. The tension-band wire was placed identical to the traditional osteosynthesis.

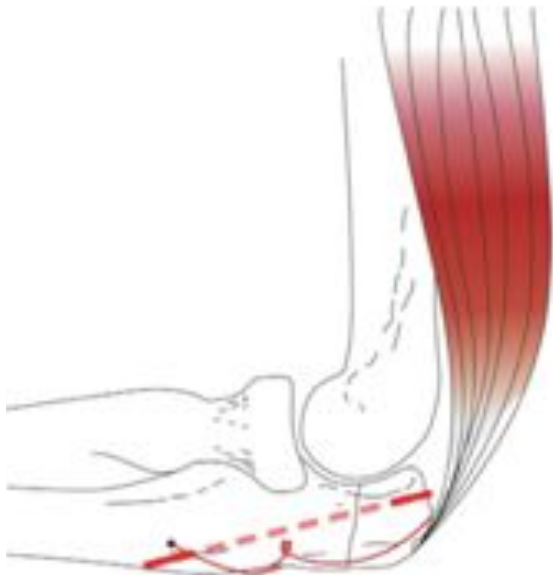


Fig. 4: Lateral view of the modified tension band wiring construct.

Modified by Newman *et al.*, Olecranon fractures. *Injury*. 2009 Juni;40(6):575–81. (10)

The ulna specimens were fixed in a cement rail with a metal clamp. The thrust bearing part, in the human anatomy corresponding to the trochlea of the humerus, was directly integrated into the rail. A screw was drilled into the tip of the olecranon, where in the human body the insertion point of the triceps tendon is located. With an Instron servohydraulic material testing machine (Zwick 1475, Ulm, Germany) an orthogonal pressure was applied on the screw. The pressure thereby simulated an active pull of the tendon in a flexed elbow.




Fig. 5: First model of the classic AO technique.

We were faced with several problems linked to the artificial synbone model we used: The K-wire didn't cut through in the synbone like we expected, because the

synbone was too dense and solid. We were therefore unable to imitate a cut through of the K-wires and measurements showed only elastic deformation of the hardware.

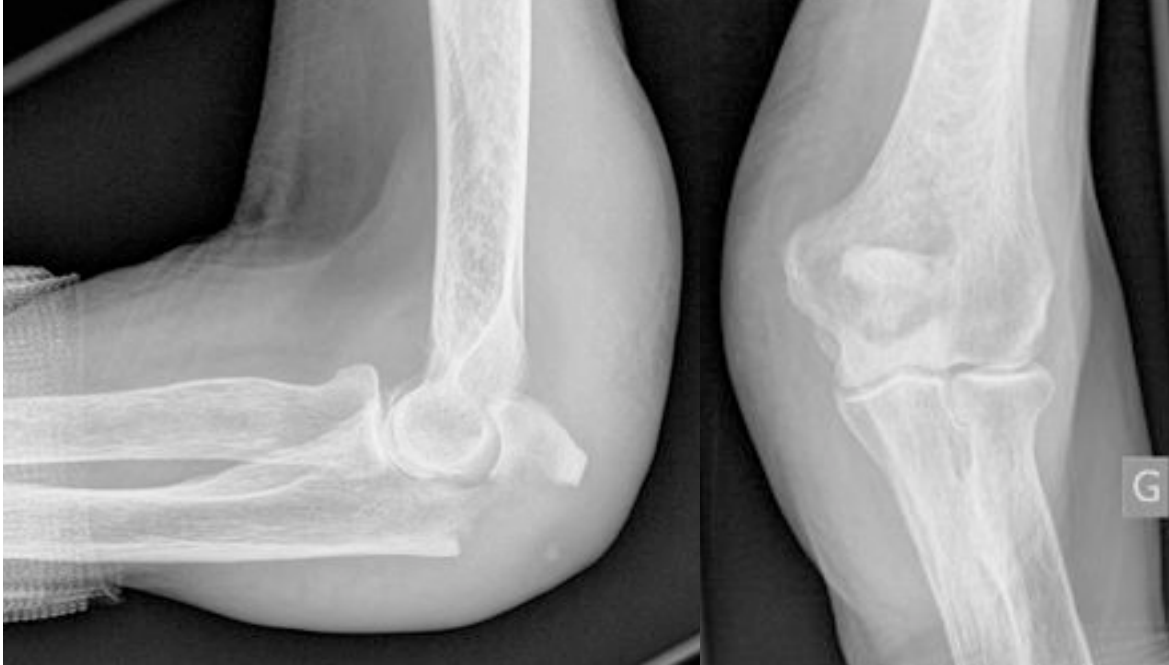

Fig. 6-A

Fig. 6-B

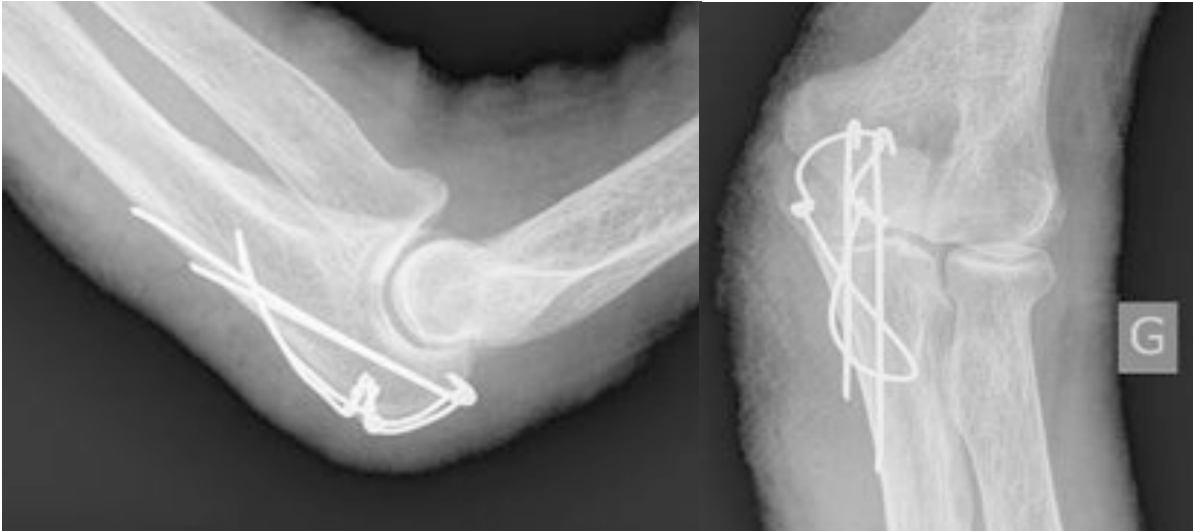

Fig. 6-C

Fig. 6-D

Fig. 6: Radiographs of a noncomminuted, stable, displaced olecranon fracture of a 86 years old patient. Modified technique.

- Fig. 6-A: Lateral view, before treatment.
- Fig. 6-B: Antero-posterior view, before treatment.
- Fig. 6-C: Lateral view, after treatment with the modified technique.
- Fig. 6-D: Antero-posterior view, after treatment with the modified technique.

6.2. Second model

In the second model we thought to increase the stiffness of the K-wires by increasing its diameter up to 2 mm. But even with this revised experiment protocol with the increase of the K-wire's diameter we couldn't observe a cut-out of the Kirschner wires. Horne *et al.* already described this problem in a study with eighty-eight olecranon fractures. They were unable to show a relationship between the placement of the tension-band wiring and the thickness of the Kirschner wires. (4)

6.3. Third Model

In the third model we replaced the synbone by a polyurethane bone, which offers more similar mechanical characteristics compared to a human ulna. But unfortunately it was impossible to construct an anatomically correct ulnar model out of polyurethane material, so we had to revise and adapt our model again.

The aim of the study is to reveal a difference in biomechanical stability of two distinct tension-band models. Therefore we created a new, theoretically correct, but anatomically different model: the olecranon bone was replaced by a cubic polyurethane block (LAST-A-FOAM® FR-6715, General Plastics Manufacturing Company, Tacoma, WA 98409, USA) and the humerus by a thrust block out of aluminium. The polyurethane foam density is 240 kg/m³.

The fixation method of the traditional AO tension-band wiring model and the modified fixation model with the different angle in the K-wire fixation remains unchanged like for all models used. As described in Molony *et al.* we used specialised jig guidance for passing the tension-band wiring into the polyurethane olecranon cube. By applying the jig guide, a better result is expected. (14) The thrust bearing was a perfectly shape-adapted aluminium reel. In this model, the K-wires will cut-out in the polyurethane cube, because the olecranon part is as strong as described in a physiological model in the human body. But in both models the cerclage cut in the edge of the polyurethane cube.




Fig. 7: Classic AO technique cube with cut in the upper edge of the polyurethane cube.




Fig. 8: Modified technique with the cerclage, which cut in the edge of the polyurethane cube on the lateral side.

6.4. Fourth model

In the fourth model we decided to adapt our model and replace the figure of eight tension-band wiring with Dall-Miles, because we were unable to measure the tension on the wire loop. (1.6mm SS Dall-Miles™, Stryker, USA) The figure of eight cerclage miles were tightened with a force measurement device. This clamping set. This clamping set also measures the tension on the cable, to achieve equal tensions on both sides of the osteotomy and to provide consistency of fixation between specimens. Kozin *et al.* declared that there wasn't any statistically significant increased stability between multifilament cable and normal cerclage wires. (61) Contrary, a cadaveric study by Prayson *et al.* showed in their fixation

study that a braided cable produces a more stable construct compared to a monofilament wire. (48) In our model we realized, that the Dall-Miles were too rigid and that the screw, on which we exerted the orthogonal force, cut out. We got away from the screw load transmission and constructed a disc on the upper side of the olecranon cube, on which we applied the force to simulate the triceps tension. With this disc, we disposed of an increased load transmission zone without cutting-out of the screw.

Another problem we observed was that the Dall-Miles cut in the edge of the polyurethane cube, because the compression on the edge was too high. Even additional aluminium coverage couldn't solve this problem.




Fig. 9: Modified technique with Dall-Miles wiring with additional aluminium coverage.

6.5. Final model

In the fifth model we maintained the polyurethane cubic olecranon part, the aluminium ulna and the K-wires and came back to the traditional stain-less steel tension-band wiring. The figure of eight tension-band was correctly applicable, even when the olecranon fragment material was different from the anatomical correct structure. We couldn't observe any cutting-in in the edge of the polyurethane cube. Nevertheless we kept the aluminium coverage in the modified model and omitted the coverage in the traditional AO model because there was no loading between cerclage and polyurethane cube. In this final model we couldn't detect any cutting-in of the K-wires and the aluminium plate on the cubic olecranon didn't sink in.

The same operator performed all instrumentations and operations, to minimize the interpersonal differences.




Fig. 10-A

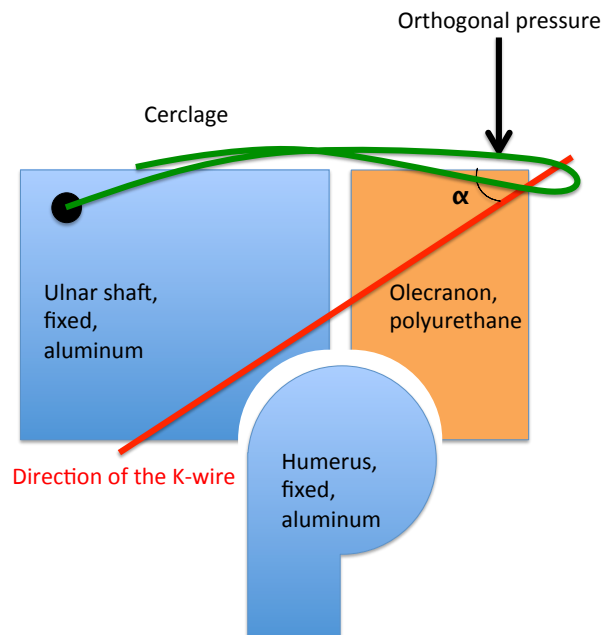


Fig. 10-B

Fig. 10-A: The figure shows the classic AO technique after the force application.

Fig. 10-B: Theoretical model of the classic AO technique.




Fig. 11-A

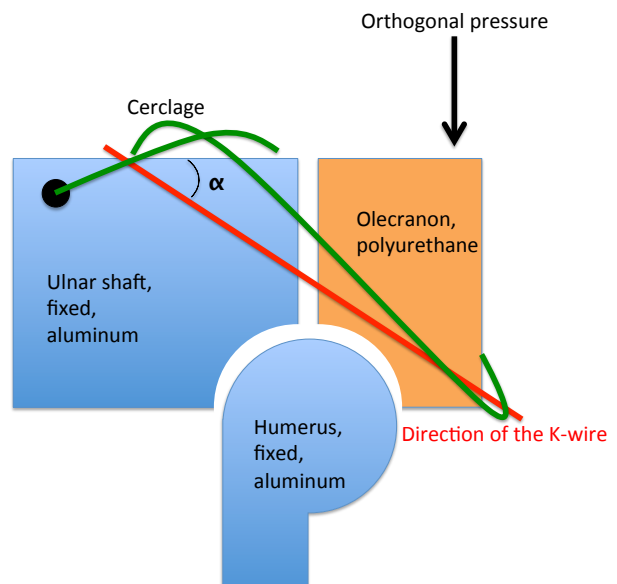


Fig. 11-B

Fig. 11-A: The figure shows the modified technique after the force application.

Fig. 11-B: Theoretical model of the modified technique.

7. Biomechanical testing

In the current study the tension-band wiring was exposed to a static single cycle load-to-failure test, after the testing model of Molloy *et al.* or Koslovsky *et al.* (27,33)

Each ulna was mounted in a uniaxial Zwick 1475 testing machine (Ulm, Germany) for mechanical load testing. The ulnar shaft was kept fixed in a horizontal position and stable with supporting devices. The humerus was in vertical position thus 90° to the ulna. The aluminium reinforcements wasn't fixed, only kept and stabilized by the vertical force on itself. Triceps muscle tension was simulated via application of a vertical force on the proximal tip of the olecranon process. Thus a three-point bending test was performed. We started with a preload of 0 N, the testing speed was 2mm/minute and the force was measured.

A linear variable displacement transducer (WI/5mm-T, HBM, Darmstadt, Deutschland) was attached on the posterior part of the aluminium ulna model and pointed on a pad, fixed proximal to the osteotomy with supporting devices.




Fig. 12: The linear displacement transducer

The linear variable displacement transducer (WI/5mm-T) fixed on the posterior part of the ulna and measured the distance to a pad, fixed on the olecranon part.

The osteotomy side will open first on the posterior part, due to the thrust bearing, which inhibits the opening on the anterior side. The opening of the osteotomy was measured with a precision of 0.001 mm. Maximum load at failure was defined as the

maximum load recorded up to the point of fixation failure. The fixation failure was defined as a fracture gap of 2 mm of the proximal fragment relative to the shaft of the ulna or if 600 N was achieved before. This definition was chosen because more than 2 mm of intraarticular step-off was shown by Murphy *et al.* to be associated with a higher incidence of posttraumatic osteoarthritis. (32)

We applied a force on the aluminium disc on the olecranon part and measured the displacement at the osteotomy according to the applied force. After the test, we examined the polyurethane cube, to detect any possible cutting-in and the K-wire to detect any hardware failure.

8. Results

We compared 10 models of the standard classical AO tension-band wiring fixation against 10 models with modified technique, as described in the point 6.5. In our study we couldn't detect any significant difference between the two techniques, neither for maximal failure load, maximal opening angle nor for the maximal work for maximal force. The maximal failure load of either technique was more than 600 N ($p = 0.94$). The maximal opening angle for both techniques is about 10° ($p = 0.86$). The modified technique showed that more maximal work is required to achieve the maximal force, but again, no significant difference ($p = 0.16$) was detected.

To achieve a divergence of 2 mm at the osteotomy site, the standard AO technique needed a mean force of 100 N, the modified technique a force of about 120N. But in the AO technique much more important variation of the values was observable, but a significant difference wasn't detectable. ($p = 0.479$)

A 1-way-Anova test was used for statistical comparison, and $p < 0.05$ considered as the statistical significance level.

In both groups, no fracture of the K-wires and no cut through of the K-wires could be revealed.

	AO technique	Modified technique	p-value
Maximal failure load	> 600 N	> 600 N	p = 0.94
Maximal opening angle	10°	10°	p = 0.86
Maximal work for maximal force	0.9 J	1.1 J	p = 0.16
Force to 2 mm	100 N	120N	p = 0.479

Tab. 1: Comparison of the two techniques

Maximal failure load, maximal opening angel, maximal work for maximal force and force to 2 mm in the two different techniques.

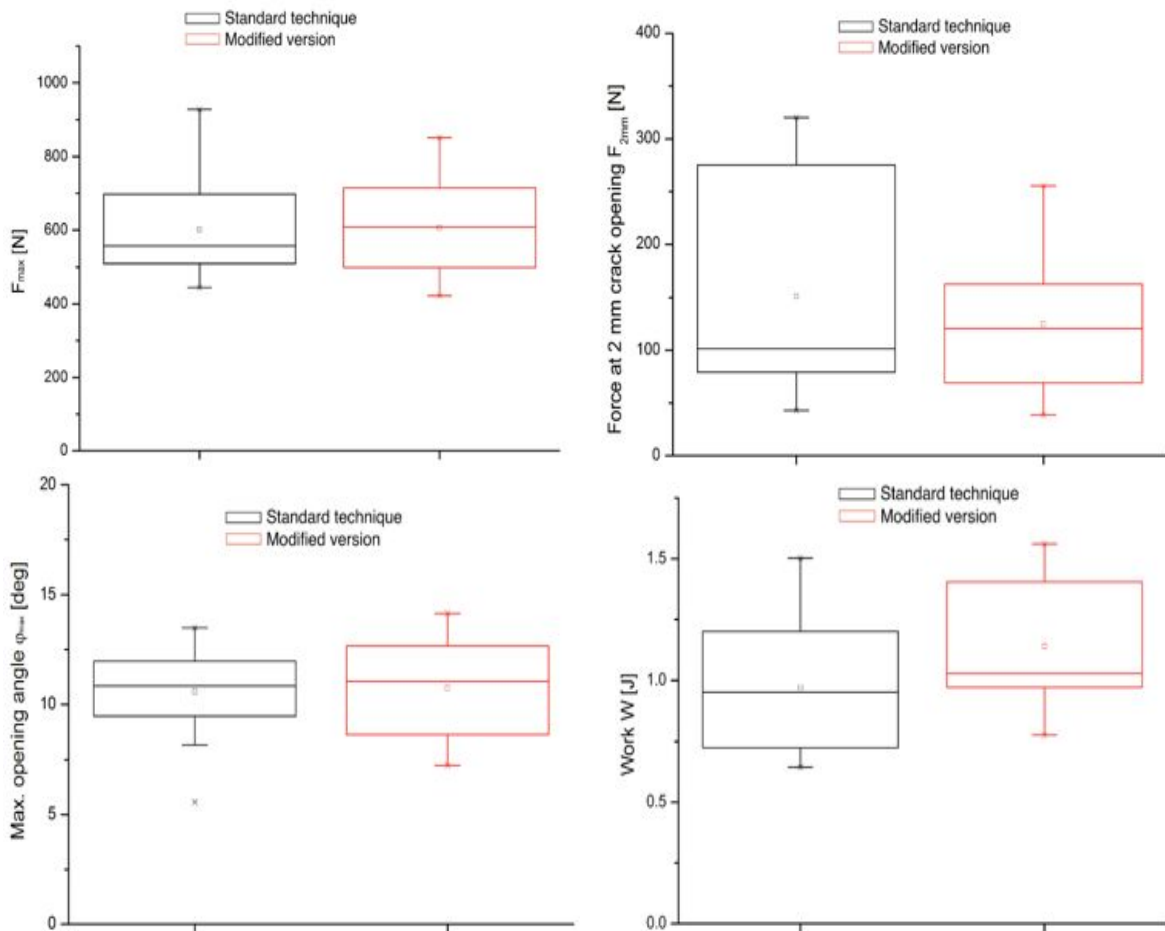


Fig. 13: Evaluation graphs

Maximal failure load, maximal opening angle, maximal work for maximal force and force to 2 mm in the two different techniques.

9. Discussion

Tension-band wiring is successful for internal fixations a valuable option for ORIF of transverse olecranon fractures. Alternatives however, can be olecranon fractures may be treated with excision, screw, pin, or plate fixation. The AO tension-band wiring technique is the most popular method and remains the gold standard for the treatment of transverse non-comminuted olecranon fractures. (3,4,6,32,36,43,44) For classic tension-band wiring, Villanueva *et al.* reported good and excellent results in 86% of the patients and Karlsson *et al.* reported in a long-term study good and excellent results in 96% of the interventions. (55,62) Through the intermittent dynamic compression, which is achieved by bending the elbow, the healing process can be promoted. (5,31,32)

Our study compared the classical AO tension-band wiring with stainless steel wire and a modified tension-band wiring with modified angle of K-wire insertion. Our aim was to achieve a better stability of the fixation and lower risk of cut through of the K-wires. Both of the models (classical AO tension-band wiring and modified technique) showed the same results concerning the maximal failure load and the maximal opening angle. A small difference between the two models is shown for the work that needs to be applied for the fracture gap opening. In many studies, the force was measured at a fracture gap of 2 mm, because more than 2 mm of intraarticular step is associated with a higher incidence of posttraumatic osteoarthritis. (27,32,42) In our study, both models needed about the same force to open up the fracture gap to more than 2mm. The relatively small number of models tested in each group and the materials we used may explain the absence of a significant difference between the two models. Because the material we used isn't human bone and so a stability difference is possible as well as the physical properties. The used artificial material (polyurethane) was probably too strong to make differences visible.

Bending and cut through of the K-wires lead in both techniques to opening at the fracture plane and thus to failure. The different angle of K-wire insertion in the two set-ups leads also to a different angle of the cerclage wiring. This modification can possibly influence the tightness of the fixation, the tension on the fracture gap and the capacity of resistance of the cerclage. In the modified technique we have a longer passage of the K-wires in the olecranon fragment, there a higher tension is attained until the K-wires break in the polyurethane fragment. To achieve a better

stability, it is important to pass the K-wires as close as possible to the articular surface. To exclude any lesion of the joint, the elbow should be manipulated before closing; this to ensure that there is no impingement of flexion/extension or supination/pronation. (10)

With help of the completely different K-wire angle in the new method, we succeeded in decreasing the classical complications, which is an enormous advantage for the clinical outcome of such a surgical intervention. The K-wires penetrate the olecranon and the triceps tendon more proximal; this results in less prominent wires under the surface of the skin and therefore less skin irritation. Other complications, like neurovascular damage, can be avoided by penetrating the distal end of the ulna on the posterior side, as applied in our new study model: palsy of the ulnar or the medial nerve can be prevented, lesion of the ulnar artery or the brachial artery on the anterior side of the ulna can be eliminated. (49,57). Like this, any vascular injury and sensitive or motor loss can be excluded.

This study has shown that there exist many other operation methods with an easier access to the operation site. If we can insert the K-wire from the tip of the olecranon to the posterior site of the ulna, the access of the two ends is much easier. We don't penetrate nor injure the extensor muscles of the hand, which results in decreased complications at the operations side and faster convalescence.

The potential limitations of our study model are largely associated to the use of a model with different materials. We worked with a very theoretical model designed to fulfil dimensional criterias with regard of the normal anatomical structures. Nevertheless we have to keep in mind that a synbone-fracture model does not represent all qualities of human bone.

Additionally, we were working with aluminium covering to stabilize and secure the polyurethane cube and to avoid cut-in of the cerclage. The extended force was only applied on the site of the triceps insertion - the surrounding tissue, skin as well as the supination force have been neglected, which could influence the operation side. Because it is an artificial model, we cannot simulate the healing process or the follow-up of the patient. (46) Furthermore we are not able to observe or test any long time complications or outcomes of the operation.

A next step would be a paired cadaveric test under simulated loading conditions, as

this is the standard for biomechanical analysis of fracture fixation devices. Comparison of our data to other biomechanical studies should be done carefully because many characteristics of our model could account for any discrepancies in results.

An advantage of our study is that every comorbidity can be excluded and we could work independently of patient's collaboration.

However, blinding of the operator was not possible and all the results are reliant on the operator's performance. All procedures are on the same level of technical skills and for all tests we worked with the same technical standard operation equipment. All the technical handles and fixations were performed by the same operator.

10. Conclusion

Tension-band wiring is an excellent technique for fixation of olecranon fractures. A high success rate can generally be achieved, but there are many complications known. Our new developed model is comparable to the classic model with regard of its stability of fixation, combined with a decreased complication rate with respect to neurovascular injury to the wire perforation at the volar side of the ulna.

The authors did receive grants of 18'000 Swiss Francs of the of RMS foundation, Bettlach, Switzerland in support of their research. They didn't receive any payments or personal benefits.

11. References

1. Rommens PM, Kühle R, Schneider RU, Reuter M. Olecranon fractures in adults: factors influencing outcome. *Injury*. 2004 Nov;35(11):1149–57.
2. Huang T-W, Wu C-C, Fan K-F, Tseng I-C, Lee P-C, Chou Y-C. Tension-band wiring for olecranon fractures: relative stability of Kirschner wires in various configurations. *J Trauma*. 2010 Jan;68(1):173–6.
3. Rettig AC, Waugh TR, Evanski PM. Fracture of the olecranon: a problem of management. *J Trauma*. 1979 Jan;19(1):23–8.
4. Horne JG, Tanzer TL. Olecranon fractures: a review of 100 cases. *J Trauma*. 1981 Jun;21(6):469–72.

5. Macko D, Szabo RM. Complications of tension-band wiring of olecranon fractures. *J Bone Joint Surg Am*. 1985 Dez;67(9):1396–401.
6. Johnson RP, Roetker A, Schwab JP. Olecranon fractures treated with AO screw and tension-bands. *Orthopedics*. 1986 Jan;9(1):66–8.
7. Bucholz RW, Heckman JD, Court-Brown CM, Tornetta P. *Rockwood and Green's Fractures in Adults: Two Volumes Plus Integrated Content Website (Rockwood, Green, and Wilkins' Fractures)*. Lippincott Williams & Wilkins; 2009.
8. Papagelopoulos PJ, Morrey BF. Treatment of nonunion of olecranon fractures. *J Bone Joint Surg Br*. 1994 Juli;76(4):627–35.
9. Ruedi TP, Murphy WM. *Ao Principles of Fracture Management*. Thieme; 2000.
10. Newman SDS, Mauffrey C, Krikler S. Olecranon fractures. *Injury*. 2009 Juni;40(6):575–81.
11. Donegan RP, Bell J-E. Olecranon Fractures. *Operative Techniques in Orthopaedics*. 2010 März;20(1):17–23.
12. Morrey BF. Current concepts in the treatment of fractures of the radial head, the olecranon, and the coronoid. *Instr Course Lect*. 1995;44:175–85.
13. van der Linden SC, van Kampen A, Jaarsma RL. K-wire position in tension-band wiring technique affects stability of wires and long-term outcome in surgical treatment of olecranon fractures. *J Shoulder Elbow Surg*. 2012 März;21(3):405–11.
14. Molony DC, Kennedy J, Gheiti A, Mullett JH. Free-hand versus novel specialised jig guidance for the passing of intramedullary wires in olecranon fracture fixation: a comparative study. *Injury*. 2010 Juli;41(7):959–62.
15. Hak DJ, Golladay GJ. Olecranon fractures: treatment options. *J Am Acad Orthop Surg*. 2000 Aug;8(4):266–75.
16. Veras Del Monte L, Sirera Vercher M, Busquets Net R, Castellanos Robles J, Carrera Calderer L, Mir Bullo X. Conservative treatment of displaced fractures of the olecranon in the elderly. *Injury*. 1999 März;30(2):105–10.
17. Parker MJ, Richmond PW, Andrew TA, Bewes PC. A review of displaced olecranon fractures treated conservatively. *J R Coll Surg Edinb*. 1990 Dez;35(6):392–4.
18. Crenshaw AH. *Campbell's operative orthopaedics*. St. Louis, Washington

- D.C., Toronto: Mosby; 1987.
19. Hölzl A, Verheyden AP. [Operative treatment of isolated fractures of the olecranon]. *Unfallchirurg*. 2008 Sep;111(9):735–9.
 20. Wilson J, Bajwa A, Kamath V, Rangan A. Biomechanical comparison of interfragmentary compression in transverse fractures of the olecranon. *J Bone Joint Surg Br*. 2011 Feb;93(2):245–50.
 21. Wu CC, Tai CL, Shih CH. Biomechanical comparison for different configurations of tension-band wiring techniques in treating an olecranon fracture. *J Trauma*. 2000 Juni;48(6):1063–7.
 22. Dieterich J, Kummer FJ, Ceder L. The olecranon sled--a new device for fixation of fractures of the olecranon: a mechanical comparison of two fixation methods in cadaver elbows. *Acta Orthop*. 2006 Juni;77(3):440–4.
 23. Zuelzer WA. Fixation of small but important bone fragments with a hook plate. *J Bone Joint Surg Am*. 1951 Apr;33-A(2):430–6.
 24. Hume MC, Wiss DA. Olecranon fractures. A clinical and radiographic comparison of tension-band wiring and plate fixation. *Clin. Orthop. Relat. Res*. 1992 Dez;(285):229–35.
 25. Tejwani NC, Garnham IR, Wolinsky PR, Kummer FJ, Koval KJ. Posterior olecranon plating: biomechanical and clinical evaluation of a new operative technique. *Bull Hosp Jt Dis*. 2002 2003;61(1-2):27–31.
 26. Fyfe IS, Mossad MM, Holdsworth BJ. Methods of fixation of olecranon fractures. An experimental mechanical study. *J Bone Joint Surg Br*. 1985 Mai;67(3):367–72.
 27. Molloy S, Jasper LE, Elliott DS, Brumback RJ, Belkoff SM. Biomechanical evaluation of intramedullary nail versus tension-band fixation for transverse olecranon fractures. *J Orthop Trauma*. 2004 März;18(3):170–4.
 28. Hutchinson DT, Horwitz DS, Ha G, Thomas CW, Bachus KN. Cyclic loading of olecranon fracture fixation constructs. *J Bone Joint Surg Am*. 2003 Mai;85-A(5):831–7.
 29. Ahmed A, Sweed T, Wanas A. The role of cancellous screw with tension-band fixation in the treatment of displaced olecranon fractures, a comparative study. *European Journal of Orthopaedic Surgery & Traumatology*. 2008;18(8):571–6.
 30. Argintar E, Martin BD, Singer A, Hsieh AH, Edwards S. A biomechanical

- comparison of multidirectional nail and locking plate fixation in unstable olecranon fractures. *Journal of shoulder and elbow surgery / American Shoulder and Elbow Surgeons ... [et al.] [Internet]*. 2011 Dez 9 [zitiert 2012 Juni 13]; Available von: <http://www.ncbi.nlm.nih.gov/pubmed/22154306>
31. Murphy DF, Greene WB, Dameron TB Jr. Displaced olecranon fractures in adults. Clinical evaluation. *Clin. Orthop. Relat. Res.* 1987 Nov;(224):215–23.
 32. Murphy DF, Greene WB, Gilbert JA, Dameron TB Jr. Displaced olecranon fractures in adults. Biomechanical analysis of fixation methods. *Clin. Orthop. Relat. Res.* 1987 Nov;(224):210–4.
 33. Koslowsky TC, Mader K, Dargel J, Schadt R, Koebke J, Pennig D. Olecranon fracture fixation with a new implant: biomechanical and clinical considerations. *Injury.* 2009 Juni;40(6):618–24.
 34. Nowak TE, Burkhart KJ, Mueller LP, Mattyasovszky SG, Andres T, Sternstein W, u. a. New intramedullary locking nail for olecranon fracture fixation--an in vitro biomechanical comparison with tension-band wiring. *J Trauma.* 2010 Nov;69(5):E56–61.
 35. Bell TH, Ferreira LM, McDonald CP, Johnson JA, King GJW. Contribution of the olecranon to elbow stability: an in vitro biomechanical study. *J Bone Joint Surg Am.* 2010 Apr;92(4):949–57.
 36. Gartsman GM, Sculco TP, Otis JC. Operative treatment of olecranon fractures. Excision or open reduction with internal fixation. *J Bone Joint Surg Am.* 1981 Juni;63(5):718–21.
 37. Moed BR, Ede DE, Brown TD. Fractures of the olecranon: an in vitro study of elbow joint stresses after tension-band wire fixation versus proximal fracture fragment excision. *J Trauma.* 2002 Dez;53(6):1088–93.
 38. Lalonde JA Jr, Rabalais RD, Mansour A, Burger EL, Riemer BL, Lu Y, u. a. New tension-band material for fixation of transverse olecranon fractures: a biomechanical study. *Orthopedics.* 2005 Okt;28(10):1191–4.
 39. Assom M, Lollino N, Caranzano F, Rossi R, Castoldi F. Polyester tension-band wiring of olecranon fractures of elderly people: a simple technique. *Injury.* 2008 Dez;39(12):1474–6.
 40. Carofino BC, Santangelo SA, Kabadi M, Mazzocca AD, Browner BD. Olecranon fractures repaired with FiberWire or metal wire tension-banding: a biomechanical comparison. *Arthroscopy.* 2007 Sep;23(9):964–70.

41. Sadri H, Stern R, Singh M, Linke B, Hoffmeyer P, Schwieger K. Transverse fractures of the olecranon: a biomechanical comparison of three fixation techniques. *Arch Orthop Trauma Surg.* 2011 Jan;131(1):131–8.
42. Lalliss SJ, Branstetter JG. The use of three types of suture and stainless steel wire tension-banding for the fixation of simulated olecranon fractures: a comparison study in cadaver elbows. *J Bone Joint Surg Br.* 2010 Feb;92(2):315–9.
43. Chalidis BE, Sachinis NC, Samoladas EP, Dimitriou CG, Pournaras JD. Is tension-band wiring technique the „gold standard“ for the treatment of olecranon fractures? A long term functional outcome study. *J Orthop Surg Res.* 2008;3:9.
44. Wolfgang G, Burke F, Bush D, Parenti J, Perry J, LaFollette B, u. a. Surgical treatment of displaced olecranon fractures by tension-band wiring technique. *Clin. Orthop. Relat. Res.* 1987 Nov;(224):192–204.
45. Weber BG, Vasey H.. Osteosynthesis in olecranon fractures. *Z Unfallmed Berufskr.* 1963;56:90–6.
46. Nowak TE, Mueller LP, Burkhart KJ, Sternstein W, Reuter M, Rommens PM. Dynamic biomechanical analysis of different olecranon fracture fixation devices--tension-band wiring versus two intramedullary nail systems: an in-vitro cadaveric study. *Clin Biomech (Bristol, Avon).* 2007 Juli;22(6):658–64.
47. Mullett JH, Shannon F, Noel J, Lawlor G, Lee TC, O'Rourke SK. K-wire position in tension-band wiring of the olecranon - a comparison of two techniques. *Injury.* 2000 Juli;31(6):427–31.
48. Prayson MJ, Williams JL, Marshall MP, Scilaris TA, Lingenfelter EJ. Biomechanical comparison of fixation methods in transverse olecranon fractures: a cadaveric study. *J Orthop Trauma.* 1997 Nov;11(8):565–72.
49. Parker JR, Conroy J, Campbell DA. Anterior interosseus nerve injury following tension-band wiring of the olecranon. *Injury.* 2005 Okt;36(10):1252–3.
50. Müller ME, Perren SM, Allgöwer M. *Manual of Internal Fixation: Techniques Recommended by the Ao-Asif Group.* Springer; 1991.
51. Rowland SA, Burkhart SS. Tension-band wiring of olecranon fractures. A modification of the AO technique. *Clin. Orthop. Relat. Res.* 1992 Apr;(277):238–42.

52. Paremain GP, Novak VP, Jinnah RH, Belkoff SM. Biomechanical evaluation of tension-band placement for the repair of olecranon fractures. *Clin. Orthop. Relat. Res.* 1997 Feb;(335):325–30.
53. Thumroj E, Jianmongkol S, Thammaroj J. Median nerve palsy after operative treatment of olecranon fracture. *J Med Assoc Thai.* 2005 Okt;88(10):1434–7.
54. Candal-Couto JJ, Williams JR, Sanderson PL. Impaired forearm rotation after tension-band wiring fixation of olecranon fractures: evaluation of the transcortical K-wire technique. *J Orthop Trauma.* 2005 Aug;19(7):480–2.
55. Villanueva P, Osorio F, Commessatti M, Sanchez-Sotelo J. Tension-band wiring for olecranon fractures: analysis of risk factors for failure. *J Shoulder Elbow Surg.* 2006 Juni;15(3):351–6.
56. Romero JM, Miran A, Jensen CH. Complications and re-operation rate after tension-band wiring of olecranon fractures. *J Orthop Sci.* 2000;5(4):318–20.
57. Prayson MJ, Iossi MF, Buchalter D, Vogt M, Towers J. Safe zone for anterior cortical perforation of the ulna during tension-band wire fixation: a magnetic resonance imaging analysis. *J Shoulder Elbow Surg.* 2008 Feb;17(1):121–5.
58. Finsen V, Lingaas PS, Storrø S. AO tension-band osteosynthesis of displaced olecranon fractures. *Orthopedics.* 2000 Okt;23(10):1069–72.
59. Helm RH, Hornby R, Miller SW. The complications of surgical treatment of displaced fractures of the olecranon. *Injury.* 1987 Jan;18(1):48–50.
60. Holdsworth BJ, Mossad MM. Fractures of the adult distal humerus. Elbow function after internal fixation. *J Bone Joint Surg Br.* 1990 Mai;72(3):362–5.
61. Kozin SH, Berglund LJ, Cooney WP, Morrey BF, An KN. Biomechanical analysis of tension-band fixation for olecranon fracture treatment. *J Shoulder Elbow Surg.* 1996 Dez;5(6):442–8.
62. Karlsson MK, Hasserius R, Besjakov J, Karlsson C, Josefsson PO. Comparison of tension-band and figure-of-eight wiring techniques for treatment of olecranon fractures. *J Shoulder Elbow Surg.* 2002 Aug;11(4):377–82.