

Endoscopy-guided pharyngoesophageal stent fixation after total laryngectomy

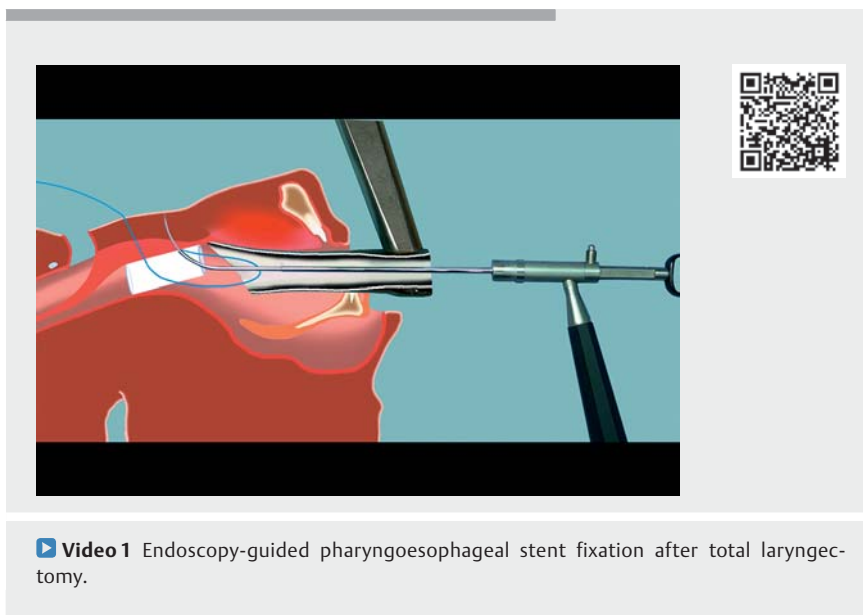


The incidence of pharyngoesophageal stricture after total laryngectomy is reported in up to 27% of cases, in whom 92.5% require endoscopic dilatations to improve oral intake [1]. The management of benign strictures of the pharynx and cervical esophagus is challenging because of the high incidence of recurrence despite repeated dilatations [2]. Stenting after dilatation reduces recurrence and improves oral feeding but with a migration rate of up to 28.6% [2, 3].

As shown, pharyngoesophageal stents were secured with an anterior, inside-to-outside, transcervical stitch using an endo-extralaryngeal needle carrier (► Video 1) [4]. After dilatation, either a silicone salivary bypass tube or an auto-expandable metallic stent was deployed under suspension micropharyngoscopy using a distending operating laryngoscope. The proximal end of the device was secured with an inside-out stitch of a 3–0 non-absorbable monofilament surgical suture below the base of the tongue and above the tracheostoma. Sutures were recovered at the skin level and tightened around a sterile button.

The technique was used for 6 stents in 3 patients who had previous stent migration. One migration occurred secondary to a stitch rupture. Patients resumed a mixed diet with the stent without any adverse suture-related events. The external access to the fixing stitch allowed quick removal. Stenting of the hypopharynx in laryngectomized patients can be done safely without the risk of airway compression or aspiration, and as the anterior neck is composed of soft tissues only, transcervical stitching is safe. Endoscopic transcervical suturing allows a deep anchoring of the stent under visual control. Compared to endoscopic clips and partially coated self-expandable metal stents, transcervical anchoring is less dependent on the mucosal grasp.

Endoscopy_UCTN_Code_TTT_1AO_2AZ



► Video 1 Endoscopy-guided pharyngoesophageal stent fixation after total laryngectomy.

Competing interests

The authors declare that they have no conflict of interest.

The authors

Victoria Salati, Kishore Sandu, François Gorostidi

Department of Otorhinolaryngology Head and Neck Surgery, Lausanne University Hospital, University of Lausanne, Lausanne, Switzerland

Corresponding author

François Gorostidi, MD

Service d'otorhinolaryngologie et de chirurgie cervico-faciale, Centre Hospitalier Universitaire Vaudois (CHUV), Rue du Bugnon 46, 1011 Lausanne, Switzerland
francois.gorostidi@chuv.ch

References

- [1] Grasl S, Schmid E, Heiduschka G et al. A new classification system to predict functional outcome after laryngectomy and laryngopharyngectomy. *Cancers* 2021; 13: 1474

outcomes following stent placement in refractory benign esophageal stricture: a systematic review and meta-analysis. *Endoscopy* 2016; 48: 141–148

- [2] Conio M, Filiberti RA, Siersema PD et al. A new designed self-expandable metal stent for the management of benign radiotherapy-induced hypopharyngeal or cervical esophageal strictures. *Surg Endosc* 2021; 36: 2290–2299
- [3] Lichtenberger G, Toohill RJ. The endo-extralaryngeal needle carrier. *Otolaryngol Neck Surg* 1991; 105: 755–756

Bibliography

Endoscopy 2022; 54: E864
DOI 10.1055/a-1841-5428
ISSN 0013-726X
published online 3.6.2022
© 2022. The Author(s).

This is an open access article published by Thieme under the terms of the Creative Commons Attribution-NonDerivative-NonCommercial License, permitting copying and reproduction so long as the original work is given appropriate credit. Contents may not be used for commercial purposes, or adapted, remixed, transformed or built upon. (<https://creativecommons.org/licenses/by-nc-nd/4.0/>)

Georg Thieme Verlag KG, Rüdigerstraße 14, 70469 Stuttgart, Germany

