

Apical access and closure devices for transapical transcatheter heart valve procedures

Enrico Ferrari^{a, b}

^a Cardiac Surgery Unit, Cardiocentro Ticino Foundation, Lugano, Switzerland

^b Cardiovascular Research Unit, University of Lausanne, Switzerland

Summary

The majority of transcatheter aortic valve implantations, structural heart procedures and the newly developed transcatheter mitral valve repair and replacement are traditionally performed either through a transfemoral or a transapical access site, depending on the presence of severe peripheral vascular disease or anatomic limitations. The transapical approach, which carries specific advantages related to its antegrade nature and the short distance between the introduction site and the cardiac target, is traditionally performed through a left anterolateral mini-thoracotomy and requires rib retractors, soft tissue retractors and reinforced apical sutures to secure, at first, the left ventricular apex for the introduction of the stent-valve delivery systems and then to seal the access site at the end of the procedure.

However, despite the advent of low-profile apical sheaths and newly designed delivery systems, the apical approach represents a challenge for the surgeon, as it has the risk of apical tear, life-threatening apical bleeding, myocardial damage, coronary damage and infections. Last but not least, the use of large-calibre stent-valve delivery systems and devices through standard mini-thoracotomies compromises any attempt to perform transapical transcatheter structural heart procedures entirely percutaneously, as happens with the transfemoral access site, or via a thoracoscopic or a miniaturised video-assisted percutaneous technique.

During the past few years, prototypes of apical access and closure devices for transapical heart valve procedures have been developed and tested to make this standardised successful procedure easier. Some of them represent an important step towards the development of truly percutaneous transcatheter transapical heart valve procedures in the clinical setting.

Key words: *transapical aortic valve implantation; aortic valve replacement; mitral valve replacement; apical closure device*

Introduction

During recent years, transcatheter heart valve procedures and percutaneous transcatheter procedures for structural heart diseases have emerged as excellent alternatives to standard medical therapy and to standard open-heart surgery for inoperable patients or patients at high risk for surgery, or in redo procedures [1, 2]. In recently published clinical papers, the well-established and standardised transcatheter aortic valve implantation (TAVI) technique was confirmed to be associated with very good hospital outcomes and mid-term clinical results, with noninferiority compared with standard aortic valve surgery in a prospective randomised clinical trial including elderly patients with very high surgical risk profiles [1–3].

With regard to the upcoming transcatheter mitral valve procedures, mitral valve replacement (with Edwards SapienTM THV in calcified native mitral valves, and Neovasc TiaraTM and Edwards FortisTM in regurgitant native mitral valves), the valve-in-valve technique for degenerated bioprostheses, and promising mitral valve repairs (Abbott Vascular MitraClipTM, NeochordTM system) have already shown good preliminary clinical results and will probably become, in the near future, valid minimally invasive alternatives to standard open-heart surgery in selected patients [4, 5].

Structural heart diseases such as mitral or aortic paravalvular leaks and left ventricular pseudoaneurysms can also be addressed percutaneously in patients at high risk for surgery: teams of interventional cardiologists have already employed muscular ventricular septal defect occluders, AmplatzerTM ductal occluders and AmplatzerTM vascular plug II occluders (off-label use) to treat intracardiac diseases successfully and fully percutaneously [6, 7].

Concerning the preferred access site, most of these innovative transcatheter procedures are easily performed percutaneously through peripheral arteries or veins, but in the case of severe peripheral vascular disease or patients with unfavourable thoracoabdominal vascular anatomy the left ventricular apical access site reached through a left anterolateral mini-thoracotomy (7–10 cm) at the fifth intercostal space remains a valid alternative, with well-known technical advantages as a result of the very short distance between the apex and the intracardiac anatomical structures. Never-

theless, despite the advent of low-profile delivery systems, the left ventricular apical access site remains a challenge for the surgeon when large-size introducer sheaths are employed (risk of intraoperative complications) and the standard technique still limits the development of closed-chest transapical transcatheter valve procedures such as video-assisted thoracoscopic TAVI or truly percutaneous transapical TAVI [8].

Described here are new devices engineered for apical access and closure that have been developed and tested during recent years in order to support, simplify and standardise minimally invasive transapical heart valve procedures: the Apica™ ASC device (Apica Cardiovascular Limited, Galway, Ireland) CE-marked in August 2013, the CardioClose™ device (Entourage Medical Technologies, CA, USA), the CardiApex™ device (Cardiapex Ltd, Or Akiva, Israel), the Permaseal™ device (Micro International Device, PA, USA), and the Safex™ device (Comed, Bolsward, The Netherlands) [9–16].

Transapical access and closure devices

Most of the following apical access and closure devices are still under evaluation in feasibility tests in an animal setting, or have just entered pre-commercial clinical trials with preliminary tests in humans. Only one device has acquired, in 2013, the European Union mark (CE mark) for commercial and clinical use in Europe.

The Apica™ device

The Apica™ system (Apica Cardiovascular Limited, Galway, Ireland) is, at the moment, the only commercially available apical access and closure device and it received the CE-mark in 2013. It is a closure system of three parts: the introducer, a left ventricular coil and the closure cap (fig. 1A and B). The introducer and the coil are one part and are surgically placed in the left ventricular apex over a stiff wire and through a standard anterolateral mini-thoracotomy.

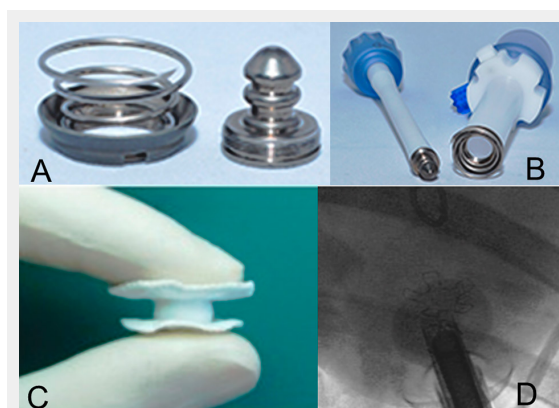

Figure 1

(A) and (B) The Apica™ access and closure device is composed of three parts: the introducer, the coil and the cap (reprinted with permission from Thoratec™ Corporation). (C) and (D) The CardiApex™ device is an apical delivery and plug allowing for full-percutaneous transapical valve procedures (reprinted with permission from Benad Goldwasser, former CEO of Cardiapex Ltd.).

cotomy. The fixation system consists of a screw-like distal part of the coil that is inserted in the left ventricular myocardium by rotating the system. Through the introducer, the transcatheter valve procedure is performed, while the haemostasis is guaranteed by the coil screwed in the myocardium. Following the procedure, when the stent-valve delivery system is removed, the closure cap is placed into the introducer and fixed to the coil for final sealing of the apical access site. Then the introducer is disconnected. At the moment, the current version of the Apica™ device allows transapical valve procedures without rib-spreading but it does not support fully percutaneous transapical TAVI [10–12].

The CardioClose™ device

CardioClose™ (Entourage Medical Technology, Menlo Park, CA, USA) is a device that mimics a surgical purse-string suture in the cardiac apex and is placed through a standard surgical mini-thoracotomy for cardiac exposure. The device is composed of two double helical needles with sutures, and small endocardial nitinol anchors. The device is placed, over the wire, against the apex and the two helical needles with sutures are screwed into the myocardium until the nitinol anchors self-deploy in the ventricular cavity. The external ends of the sutures are controlled by specific suture-locking buttons that can be manually adjusted at the end of the transcatheter procedure: after the valve implantation and after the removal of the delivery system, the two sutures of the CardioClose™ are tightened by locking the two buttons. At the moment, the device is being tested in a clinical setting after acute and chronic animal tests demonstrated promising preliminary results.

The CardiApex™ device

The CardiApex™ device (Cardiapex Ltd, Or Akiva, Israel) was designed to be employed in truly percutaneous transapical heart valve procedures and consists of two main parts: an apical plug and a catheter with introducer sheath (fig. 1C and D). It is a sutureless apical closure device not requiring a standard mini-thoracotomy. Through a transfemoral arterial puncture, a catheter equipped with a puncturing needle is retrogradely advanced into the left ventricle: the ventricular apex is punctured from inside to outside the pericardium, and a stiff wire is advanced outside the pericardium. At the same time, a 10-mm trocar is placed, percutaneously, into the sixth intercostal space and the stiff wire is snared and used to convey the CardiApex™ sheath into the pericardium and through the left ventricular apex. Two balloons surrounding the sheath are inflated inside and outside the ventricle to guarantee haemostasis and to allow for the stent-valve delivery device to be advanced through the sheath. Once the transapical procedure is complete, an umbrella-like plug is deployed at the apex. Preliminary feasibility tests in an animal setting have been performed and clinical data are pending.

The Permaseal™ device

Permaseal™ (Micro Interventional Device, Newton, PA, USA) is a device that implants eight biocompatible V-stays at the apex of the left ventricle for apical sealing (fig. 2A and B). The device still requires a left mini-thoracotomy.

cotomy and is not designed to support percutaneous closed-chest transapical procedures. After wire access is obtained, the gun-shaped delivery system is placed, over the wire, against the epicardium at the level of the cardiac apex. Then the system is manually activated and eight polypropylene anchors with a 2-0 braided polyester suture perforate the myocardium and create a series of V-stays. This creates a channel in which stent-valve delivery systems are placed after the gun-shaped Permaseal™ delivery system has been removed: transapical valve procedures can be easily performed without active bleeding. Following valve deployment, all catheters and wires are removed and the device closes spontaneously by pulling the pre-tied sutures in order to seal the apical access site. The Permaseal™ has entered the clinical test phase in a human setting to receive CE mark approval for commercial use in Europe (STASIS multicentre study enrolling, at this time, 34 patients).

The Safex™ device

The new apical closure device from Comed (Comed, Bolsward, The Netherlands) has recently passed preliminary tests of safety and feasibility in an acute animal model. The Safex™ is a self-expanding, self-anchoring, self-sealing modified ventricular septal defect occluder and is made of woven nitinol wires into two self-expandable round retention disks with a connecting extendable and flexible waist 10 mm in diameter (fig. 2C). The inner and outer disks present two membranes made of expanded polytetrafluoroethylene (ePTFE) that guarantee mechanical occlusion of large-size apical access sites, and guarantee blood clotting for long-term haemostasis. Thanks to its adaptability, the device is expected to occlude apical access sites ranging from 20 Fr to 35 Fr, and is specifically designed for closed-chest percutaneous transapical valve procedures. In fact, the Safex™ apical closure device is at first connected

to its wire, then folded and inserted into a 10 Fr delivery system. This delivery system is placed into the left ventricle through the large-size transapical introducer sheath used for the placement of the stent-valve. Then the plug is deployed with a simple two-step manoeuvre: the inner disk is deployed first, the systems are pulled back towards the apex and then the outer disk is deployed while the sheaths are pulled out (fig. 2D) [13–16]. Haemodynamic tests and chronic animal tests are planned.

Conclusion

Transapical access through the apex of the left ventricle is a safe approach with a low rate of access-site related complications, and it carries the advantage of a short pathway between the introduction site and the intracardiac target. Moreover, apical access facilitates a wide range of intracardiac procedures allowing for the use of relatively large size apical sheaths carrying all sorts of biological valves and devices.

However, the standard surgical apical approach through a left mini-thoracotomy limits the development of true percutaneous or video-assisted thoracoscopic apical procedures and is still perceived as a more invasive technical/surgical procedure compared with the less invasive percutaneous transfemoral access site. Therefore, the development of new apical access and closure devices represents an important step towards further development of this technique: it will simplify and standardise the transapical transcatheter technique and it will allow for the development of less invasive transapical valve procedures. Other important advantages will be the flattening of the initial learning curve and the introduction of transapical transcatheter heart valve procedures in low-volume cardiac centres not very familiar with this useful approach. However, at the moment only one device is available for commercial use in Europe, and it still requires a left anterior mini-thoracotomy.

Interestingly, among the cited closure devices the CardiApex™, and the Safex™ device are specifically designed and developed to work in a closed-chest truly percutaneous transapical setting. If clinical human tests confirm the successful results of the preliminary animal tests, this noninvasive percutaneous transapical approach will probably represent a new milestone in the era of transcatheter heart valve procedures.

Disclosure statement: No financial support and no other potential conflict of interest relevant to this article was reported.

Correspondence: Enrico Ferrari, MD, Cardiocentro Ticino, Via Tesserete 48, CH-6900 Lugano, [enricoferrari\[at\]bluewin.ch](mailto:enricoferrari[at]bluewin.ch)

References

- Mack MJ, Leon MB, Smith CR, Miller DC, Moses JW, Tuzcu EM, et al.; PARTNER 1 trial investigators, Akin J. 5-year outcomes of transcatheter aortic valve replacement or surgical aortic valve replacement for high surgical risk patients with aortic stenosis (PARTNER 1): a randomised controlled trial. *Lancet*. 2015 Mar 15. pii: S0140-6736(15)60308-7. doi: 10.1016/S0140-6736(15)60308-7. [Epub ahead of print]

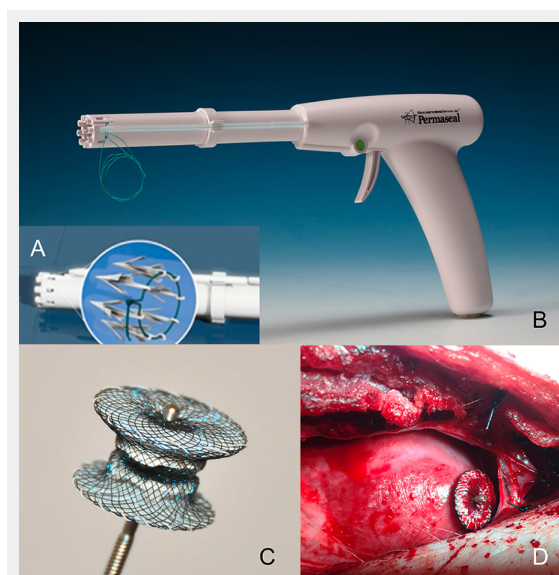
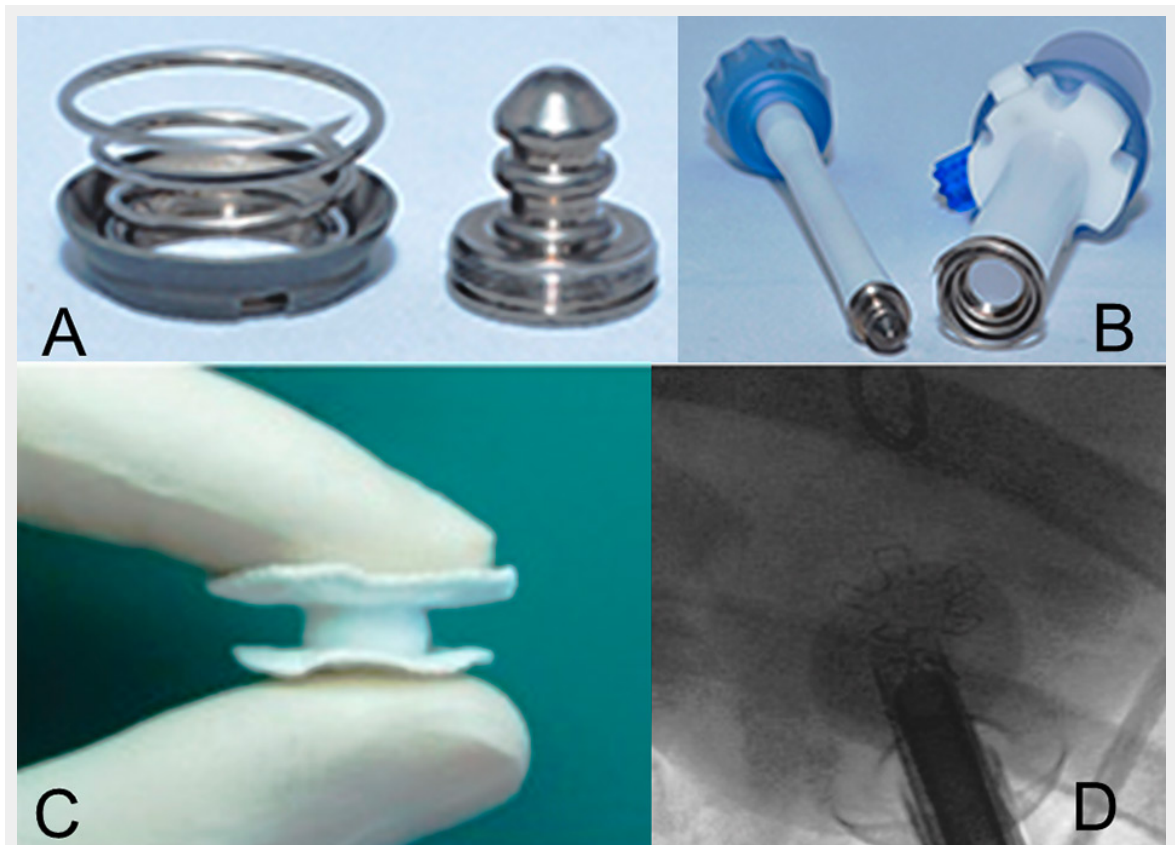


Figure 2

(A) The Permaseal™ device is made of eight polypropylene V-stays inserted in the left ventricular apex. (B) The gun-shaped Permaseal™ delivery system (Source: courtesy of Micro Interventional Devices). (C) The Safex™ is a self-expandable, self-anchoring and self-sealing flexible device. (D) Surgical view of the Safex™ device.

- 2 Kapadia SR, Leon MB, Makkar RR, Tuzcu EM, Svensson LG, Kodali S, et al.; PARTNER trial investigators, Akin JJ, Davidson MJ. 5-year outcomes of transcatheter aortic valve replacement compared with standard treatment for patients with inoperable aortic stenosis (PARTNER 1): a randomised controlled trial. *Lancet*. 2015 Mar 15. pii: S0140-6736(15)60290-2. doi: 10.1016/S0140-6736(15)60290-2. [Epub ahead of print]
- 3 Blackstone EH, Suri RM2, Rajeswaran J, Babaliaros V, Douglas PS, Fearon WF, et al. Propensity-matched comparisons of clinical outcomes after transapical or transfemoral transcatheter aortic valve replacement: a placement of aortic transcatheter valves (partner)-i trial substudy. *Circulation*. 2015;131:1989–2000.
- 4 Conradi L, Lubos E, Treede H, Pietzsch JB, Weber S, Pietzsch M, et al. Evolution of mitral valve procedural volumes in the advent of endovascular treatment options: Experience at an early-adopting center in Germany. *Catheter Cardiovasc Interv*. 2015 Apr 28. doi: 10.1002/ccd.25962. [Epub ahead of print]
- 5 Maisano F, Alfieri O, Banai S, Buchbinder M, Colombo A, Falk V, et al. The future of transcatheter mitral valve interventions: competitive or complementary role of repair vs. replacement? *Eur Heart J*. 2015 Apr 12. pii: ehv123. [Epub ahead of print]
- 6 Kliger C, Eiros R, Isasti G, Einhorn B, Jelnin V, Cohen H, et al. Review of surgical prosthetic paravalvular leaks: diagnosis and catheter-based closure. *Eur Heart J*. 2013;34:638–49.
- 7 Dudy Y, Kliger C, Jelnin V, Elisabeth A, Kronzon I, Ruiz CE. Percutaneous transapical access: current status. *Eurointervention*. 2014;10(suppl U):U84–89.
- 8 von Segesser LK, Gerosa G, Borger MA, Ferrari E. Prevention and management of potential adverse events during transapical aortic valve replacement. *J Heart Valve Dis*. 2013;22:276–86.
- 9 Blumenstein J, Kempfert J, Kim W, Liebertrau C, Mollmann H, Walther T. Transapical access and closure devices: rationale and current status. *Expert Rev Cardiovasc Ther*. 2013;11:1613–7.
- 10 Blumenstein J, Van Linden A, Arsalan M, Voss S, Moellmann H, Liebertrau Ch, et al. Experimental Evaluation of a New Apical Access and Closure Device. *Ann Thorac Surg*. 2012;94:1706–9.
- 11 Blumenstein J, Kempfert J, Van Linden A, Arsalan M, Schmidt SK, Mollmann H, et al. First-in-man evaluation of the transapical APICA ASC™ access and closure device: the initial 10 patients. *Eur J Cardiothorac Surg*. 2013;44:1057–62.
- 12 Conradi L, Seiffert M, Shimamura K, Schirmer J, Blankenberg S, Reichenspurner H, et al. Successful use of a left ventricular apical access and closure device for second-generation transapical aortic valve implantation. *Thorac Cardiovasc Surg*. 2014;62:498–502.
- 13 Tozzi P, Pawelec-Wojtalic M, Bukowska D, Argitis V, von Segesser LK. Endoscopic off-pump aortic valve replacement: does the pericardial cuff improve the sutureless closure of left ventricular access? *Eur J Cardiothorac Surg*. 2007;31:22–5.
- 14 Tozzi P, Pawelec-Wojtalic M, Bukowska D, Ferrari E, Siniscalchi G, von Segesser LK. Endoscopic access closure for direct implantation of valved stents. *Swiss Med Wkly*. 2007;137:182–4.
- 15 Ferrari E, Locca D, Berdajs D, Marcucci C, Gronchi F, Lavanchy J, et al. Use of a VSD occluder for apical closure in transapical aortic valve replacement. *Innovations*. 2015;10:68–70.
- 16 Ferrari E, Berdajs D, Tozzi P, Siniscalchi G, von Segesser LK. Apical closure device for transapical valve procedures. *Interact Cardiovasc Thorac Surg*. 2015;21:561–4.

Figures (large format)

**Figure 1**

(A) and (B) The Apica™ access and closure device is composed of three parts: the introducer, the coil and the cap (Source: courtesy of Thoratec™ Corporation). (C) and (D) The CardiApex™ device is an apical plug allowing for full-percutaneous transapical valve procedures (Source: courtesy of Professor Hendrik Treede, University Heart Center Hamburg, Germany).

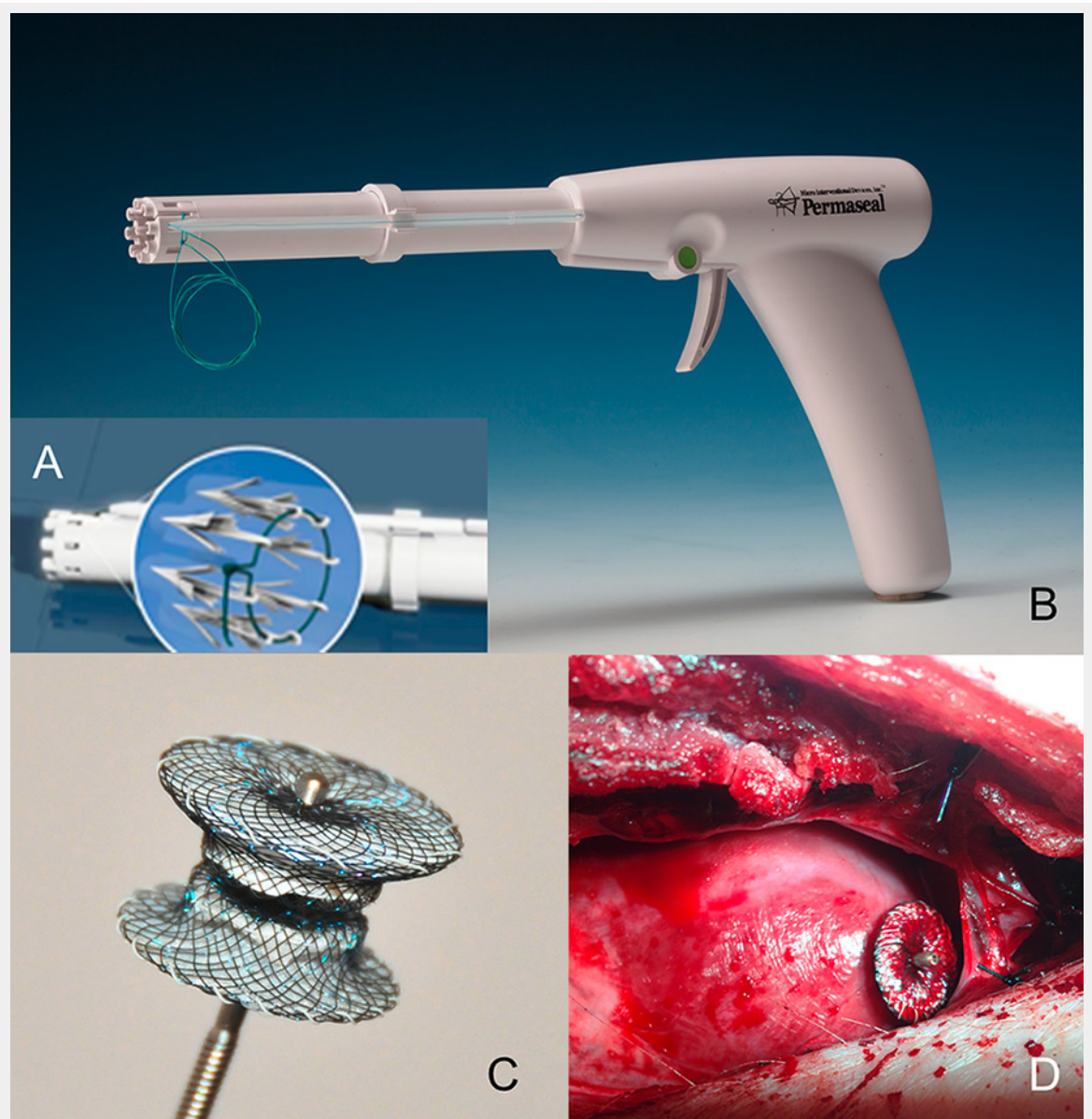


Figure 2

(A) The Permaseal™ device is made of eight polypropylene V-stays inserted in the left ventricular apex. (B) The gun-shaped Permaseal™ delivery system (Source: courtesy of Micro Interventional Devices). (C) The Safex™ is a self-expandable, self-anchoring and self-sealing flexible device. (D) Surgical view of the Safex™ device.