

European Neuroendocrine Tumor Society (ENETS) 2023 guidance paper for colorectal neuroendocrine tumours

Anja Rinke¹  | Valentina Ambrosini^{2,3} | Clarisse Dromain⁴  |
 Rocio Garcia-Carbonero⁵ | Aryn Haji⁶ | Anna Koumariou⁷  |
 Els Nieveen van Dijkum⁸ | Dermot O'Toole⁹ | Guido Rindi¹⁰  |
 Jean-Yves Scoazec¹¹ | John Ramage¹² 

¹Department of Gastroenterology, University Hospital Marburg and Philipps University Marburg, Marburg, Germany

²Nuclear Medicine, Alma Mater Studiorum University of Bologna, Bologna, Italy

³IRCSS, Azienda Ospedaliero-Universitaria di Bologna, Bologna, Italy

⁴Department of Radiology, CHUV Lausanne University Hospital and University of Lausanne, Lausanne, Switzerland

⁵Department of Oncology, Hospital Universitario 12 de Octubre, Madrid, Spain

⁶Department of Colorectal Surgery, King's College Hospital, London, UK

⁷Hematology Oncology Unit, Fourth Department of Internal Medicine, Attikon University Hospital, National and Kapodistrian University of Athens, Athens, Greece

⁸Department of Surgery, Amsterdam UMC, Amsterdam, Cancer Center Amsterdam, University of Amsterdam, Amsterdam, The Netherlands

⁹NET Center of Excellence, St Vincent's University Hospital and St James Hospital Dublin 8 and Trinity College Dublin, Dublin, Ireland

¹⁰Section of Anatomic Pathology, Department of Life Sciences and Public Health, Università Cattolica del Sacro Cuore; Unit of Head and Neck, Thoracic and Endocrine Pathology, Department of Woman and Child Health and Public Health, Fondazione Policlinico Universitario A. Gemelli IRCCS; Roma European NeuroEndocrine Tumor Society (ENETS) Center of Excellence, Rome, Italy

¹¹Department of Pathology, Gustave Roussy Cancer Campus, Villejuif, France, Université Paris Saclay, Faculté de Médecine, Le Kremlin-Bicêtre, Villejuif, France

¹²Department of Gastroenterology, Hampshire Hospitals and ENETS Center, Kings Health Partners London, London, UK

Correspondence

Anja Rinke, UKGM Marburg, Department of Gastroenterology and Philipps University Marburg, Baldinger Straße, D 35043 Marburg, Germany.

Email: sprengea@uni-marburg.de

Abstract

This ENETS guidance paper, developed by a multidisciplinary working group, provides an update on the previous colorectal guidance paper in a different format. Guided by key clinical questions practical advice on the diagnosis and management of neuroendocrine tumours (NET) of the caecum, colon, and rectum is provided. Although covered in one guidance paper colorectal NET comprises a heterogeneous group of neoplasms. The most common rectal NET are often small G1 tumours that can be treated by adequate endoscopic resection techniques. Evidence from prospective clinical trials on the treatment of metastatic colorectal NET is limited and discussion of patients in experienced multidisciplinary tumour boards strongly recommended. Neuroendocrine carcinomas (NEC) and mixed neuroendocrine non-neuroendocrine neoplasms (MiNEN) are discussed in a separate guidance paper.

KEYWORDS

colorectal, endoscopic treatment, guideline, neuroendocrine tumour, rectal carcinoid

This is an open access article under the terms of the [Creative Commons Attribution-NonCommercial-NoDerivs](https://creativecommons.org/licenses/by-nc-nd/4.0/) License, which permits use and distribution in any medium, provided the original work is properly cited, the use is non-commercial and no modifications or adaptations are made.

© 2023 The Authors. *Journal of Neuroendocrinology* published by John Wiley & Sons Ltd on behalf of British Society for Neuroendocrinology.

1 | INTRODUCTION - GENERAL BACKGROUND

The purpose of this guidance paper is to update the previous colorectal guidelines,¹ but in a different format by providing expert opinion on the most important clinical questions. The opinions are supported by the grade of evidence and the strength of the recommendation. This paper will cover neuroendocrine tumours (NET) of the caecum, colon, and rectum.

Though grouped anatomically, in reality this is a heterogeneous group of neoplasms. Tumours of the caecum are often of intermediate grade neuroendocrine tumours (NET) and can behave in a similar way to their ileal counterparts (see question 1). Tumours of the main part of the colon are often neuroendocrine carcinomas (NEC) more than NET G3, and can be mixed neuroendocrine non-neuroendocrine neoplasms (MiNEN) with an adenocarcinoma/adenoma component.² Rectal tumours are commonly small and most often G1, and the main issue is how these can be resected without recurrence. A NET can rarely occur within an adenoma at any colorectal site.^{2,3} Anal canal neuroendocrine neoplasm (NEN) are usually NEC and often MiNEN

with a squamous carcinoma component.⁴ NEC and MiNEN are discussed in a separate guidance paper.⁵

1.1 | Pathology

NEN of the large intestine are classified and staged according to the current WHO classification of digestive tumours, 2022 update and 2017 AJCC Cancer Staging system.^{3,6,7} Below are summarised the major features (Tables 1 and 2) and the link to the ENETS proposal for synoptic reporting:⁸

https://www.enets.org/standardised-reports.html?file=files/enets/customer/media/Standardised%20reports/Standard%20Report%20Pathology_ColoRectal%20NEN_V4.pdf&cid=2784.

The incidence of colorectal NEN has increased over the last 20 years in all sites, but rectal tumours have increased more than others which is likely to be related to increased recognition because of the more frequent use of endoscopy.¹⁰⁻¹² The median OS of rectal NEN is good (>20 years), while for the colon it is poor (approx. 1 year) and caecum intermediate (about 9 years).¹⁰

TABLE 1 NEN of the large intestine: Features and grading.

Category	Type	IHC	Subtype	Grade	Ki-67 (MIB1)
NEN	NET	CgA, Syn , INSM1, CDX2, 5HT, PP/PYY/glicentin	L-cell ^a	G1	<3
			EC-cell	G2	3–20
				G3	>20
	NEC	CgA, Syn , INSM1, CDX2, TTF1	Large cell Small cell	G3	>20
	MiNEN	NET/NEC	NET/NEC	See above	See above
		Adenocarcinoma	na	G1–G3	na
		Squamous cell carcinoma	na		na

Note: Not all immunohistochemical stains are routinely available (e.g., PYY, 5HT, glicentin), the essential stains characterised in⁸ appear in bold. Abbreviations: 5HT, 5-hydroxytryptamine; APP, acid prostatic phosphatase; CDX2, caudal type homeobox 2; CgA, chromogranin A; Syn, synaptophysin; IHC, recommended/useful immunohistochemistry; INSM1, Insulinoma associated protein 1; MiNEN, mixed neuroendocrine non-neuroendocrine neoplasm; NEC, neuroendocrine carcinoma; NEN, neuroendocrine neoplasm; NET, neuroendocrine tumour; PP, pancreatic polypeptide; PYY, peptide YY; TTF1, thyroid transcription factor 1.

^aL-cell NET are often negative or only focally positive for CgA, while positive for L-cell hormones. Non-L-cell type NET has been associated with risk of metastasis.⁹

TABLE 2 Staging of NET of the large intestine.

T	N	M
TX Not assessed	NX Not assessed	
T0 No evidence	N0 No metastasis	M0 No metastasis
T1 Lamina propria/submucosa invasive AND <2 cm	N1 Metastasis	M1 Metastasis
T1a <1 cm		M1a Liver metastasis only
T1b 1–2 cm		M1b Extrahepatic metastasis
T2 Muscularis propria invasive OR >2 cm lamina propria/submucosa invasive		M1c Liver and extrahepatic metastasis
T3 Through muscularis propria subserosa invasive (no penetration of serosa)		
T4 Serosa/other organs invasive		

Abbreviations: T, primary tumour; N, locoregional lymph nodes; M, distant metastases inclusive of non-locoregional lymph-nodes; NET, neuroendocrine tumour.

1.2 | The main new issues addressed in this guidance paper

- Whether caecal NET can be treated as per ileal NET (which is the subject of a separate guidance paper)
- What are the best ways of managing metastatic colonic and rectal NET
- What are the best ways of managing low grade rectal NET, which has become a common problem for endoscopists and colorectal surgeons

Table 3 summarises the clinical questions discussed in this paper.

We will try to provide a balanced approach to these issues by involving representatives from all specialties that manage these tumours.

2 | MAIN CLINICAL QUESTIONS

2.1 | Are there differences between NET of the right colon and ileal NET?

2.1.1 | Incidence

Background: The incidence of right colon NET is difficult to assess, since most epidemiological studies have pooled all colon NET, or even

all colorectal NET, in one group. When information about the precise location is given, right-sided colon NET are constantly more frequent than left-sided NET, with the caecum as the most frequent site.^{10,13} In Western countries, the incidence of right colon NET is 0.11 to 0.2/100,000/year, much lower than that of ileal NET, 0.25 to 1.2/100,000/year; the incidence in both sites is much lower in Asian countries.^{8,11} As for other NET, there seems to be a trend towards an increased incidence in colon NET over the last 20 years, but this is much less obvious than for ileal NET.⁸ In contrast to ileal NET, there is no known familial syndrome for colon NET.

Conclusion: Right colon NET are much rarer than ileal NET, even if they are the most frequent site of colonic NET.

Level of evidence/grade of recommendation: Level 2a grade B.

2.1.2 | Histopathology

Background: According to the conventional classification of the digestive tract, right colon NET are midgut tumours like ileal NET while left colon NET are hindgut tumours like rectal NET. However, there are substantial differences between right colon and ileal NET. In contrast to ileal NET, which are frequently multiple, right colon NET are usually single; most are large, highly invasive tumours. G3 NET, rare in the ileum, have more often been described in the right colon. While almost all ileal NET are enterochromaffin (EC), serotonin-producing tumours, right colon NET are much more

TABLE 3 Main questions on the management of patients with colorectal NET.

Main clinical question	Paragraph
Are there differences between NET of the right colon and ileal NET?	2.1
• Incidence	2.1.1
• Histopathology	2.1.2
• Prognosis	2.1.3
• Clinical management	2.1.4
What is the surgical strategy in colonic NET? Is there room for endoscopic management of colonic NET?	2.2
When is imaging in rectal NET (in addition to endoscopic ultrasound) indicated, and which imaging is needed at the initial diagnosis?	2.3
Which endoscopic/surgical techniques are appropriate to treat rectal NETs (including indication for oncological resection)?	2.4
Is there need for a second resection in patients with R1-resected rectal NET?	2.5
Is there a role for surgery in metastatic rectal NET?	2.6
Which systemic treatments should be selected in patients with metastatic colonic and rectal NET?	2.7
Role of SSA?	2.7.1
Role of everolimus?	2.7.2
Role of TKI?	2.7.3
Role of chemotherapy?	2.7.4
Role of PRRT?	2.7.5
Neoadjuvant treatment?	2.7.6
What is the recommended follow-up in rectal or colonic NET?	2.8
Follow-up in rectal NET?	2.8.1
Follow-up in colonic NET?	2.8.2

Abbreviations: NET, neuroendocrine tumour; PRRT, peptide receptor radionuclide therapy; SSA, somatostatin analogue; TKI, tyrosine kinase inhibitor.

heterogeneous, including EC-cell tumours, L-cell tumours and others. The genetic landscape of colon NET is poorly known, but none of the abnormalities described in ileal NET (such as chr18 loss or CDKN1B mutations) have been reported so far. The so-called “ileocaecal” tumours are usually large, distal ileal tumours overlapping the ileocaecal valve.

Conclusion: Right colon NET are macroscopically and histologically different from ileal NET.

Level of evidence/grade of recommendation: Level 2a grade A.

2.1.3 | Prognosis

Background: In the SEER publications, caecal NET are documented as a separate primary tumour localisation, whereas the rest of the large bowel is divided into colon and rectum. Median overall survival (mOS) in metastatic NET G1 and G2 small intestinal NET patients, diagnosed between 2000 and 2012, was 103 months, as compared to 98 months in caecal NET,¹⁰ and in colonic NET only 14 months. Cancer specific survival of right-sided colonic NET is better than in left-sided NET with similar mOS.¹⁴ In the Spanish Registry publication,¹⁵ the mOS for all jejunal and ileal NET was 12.9 years and all colonic NET 11.9 years without separation of right and left primary site. In a Canadian publication, the 5 year OS rate as well as the disease specific survival of colonic NET (with the majority located in the right colon) did not differ significantly from the survival figures for small bowel NET.¹⁶

Conclusion: Prognosis of patients with NET of the right colon is comparable to that of small intestinal NET patients.

Level of evidence/grade of recommendation: Level 4 grade C.

2.1.4 | Clinical management

Background: There is a lack of specific treatment data for metastatic NET of the right colon. Carcinoid syndrome (CS) occurs rarely compared to ileal NET and, if present, antisecretory treatment for symptom control should follow the recommendations for CS as discussed in a separate guidance paper.¹⁷ Although the concept of management according to embryologic origin (foregut, midgut, hindgut) has largely been dropped, historically NET of the right colon were treated as “midgut NET” like small intestinal NET. Patients with NET G1/ G2 of the right colon were included in therapeutic “midgut” trials such as the PROMID study¹⁸ and the NETTER-1 trial,¹⁹ and also in the “midgut subgroup” of the CLARINET trial²⁰ without a reported outcome for this small subcohort. A subgroup analysis of the RADIANT-2 trial²¹ supports a possible role for everolimus in patients with NET G1 / G2 of the colon, see below section 2.7.2. NET G3 of the right colon is rare, the management does not differ from other colorectal NET G3 cases (see 2.7 and Figure 2).

Recommendation: In the absence of specific data for patients with NET G1 and G2 of the right colon it is justified to treat according to the algorithm for small intestinal NET G1/ G2.

Level of evidence/grade of recommendation: Level 4 grade C.

2.2 | What is the surgical strategy in colonic NET? Is there room for endoscopic management of colonic NET?

2.2.1 | Background

There are no prospective data supporting endoscopic resection of colonic NET and data here are taken from published case reports, small retrospective case series and extrapolation of data from larger databases.

Our prior dogma was that NETs involving the colon are more aggressive than rectal NET and are felt to present at a later stage with metastases to regional lymph nodes. With this in mind, surgical resection with regional lymphadenectomy as in adenocarcinoma has been considered the mainstay of treatment. However, trends are now evolving showing that detection of earlier stage and less aggressive colonic NETs (largely via colonoscopy screening programmes) may provide evidence to support local excision for colonic NET.²² This recent study aimed at predicting colonic NET that may be suitable for local excision by assessing risk of lymph node metastases. Using the SEER database, 929 patients with localised NET of the colon diagnosed from 1973 to 2006 were identified. Firstly, the diagnosis of tumours involving regional lymph nodes decreased from 71% to 46% during the period of this study. Intramucosal tumours <1 cm had a 4% rate of lymph node metastasis, while all other subgroups had rates $\geq 14\%$. Hence, local or endoscopic resection of colon NET <1 cm in size and confined to the mucosa without formal lymphadenectomy may be appropriate.²²

In a large US National Cancer Database analysis of 7967 colonic and 11,929 rectal NET between 2004 and 2014 who underwent resection, 525 (6.6%), colon NET were treated using local excision (vs. 89.1% of local excision for rectal NET).²³ They found that endoscopic excision for colonic NET is increasing over time as stage and tumour size are reducing.

Similarly, a Dutch study found that local excisions increased both for rectal (87% in 2006 vs. 95% in 2016) and colonic NET (7% in 2006 vs. 52% in 2016).¹²

Several authors have described successful endoscopic excision of colonic NET, and in the main use of endoscopic resection techniques are reserved for smaller lesions (often <10 mm).^{24–26}

Techniques such as en bloc endoscopic submucosal dissection (ESD) resections or using devices to achieve full thickness resection have also been described, but only limited data are available.^{27,28}

Recommendation: Endoscopic resection may be appropriate in selected cases for small (usually 10 mm or less) colonic NET G1. Since there are little useful data on follow-up, discussion at a dedicated multidisciplinary team (MDT) post resection is warranted to decide on follow-up or further resection on a case-by-case basis.

In all other cases as well as after incomplete endoscopic resection (R1), surgical resection is recommended.

Level of evidence/grade of recommendation: Level 4 grade C.

2.3 | When is imaging in rectal NET (in addition to endoscopic ultrasound) indicated and which kind of imaging at the initial diagnosis?

2.3.1 | Background

The need for magnetic resonance imaging (MRI) in locoregional staging of rectal NET (rNET) is related to the risk of metastatic disease after endoscopic resection. The technical aspects of local preparation and sequences for rectal MRI should follow the recommendations of those for rectal adenocarcinoma.

There is general agreement between studies to consider tumour size ≥ 10 mm as the major parameter to determine the risk for metastatic disease in rNET.^{22,29–33} An analysis of the national cancer database (NCDB) cohort of 17,448 rNET identified an incidence of lymph node metastasis of 2.5% for tumours ≤ 10 mm versus 12.8% for tumours 11–20 mm.³⁴ Another study evaluating 788 patients from the SEER database with T1 rNET reported an incidence of lymph node metastases of 1.1% for tumours ≤ 10 mm versus 6.6% in tumours 11–20 mm.³³

In another study with 132 rectal NET ≤ 10 mm, the mean rate of lymph node metastases was 3% ranging from 0% in tumours ≤ 6 mm to 10.3% in tumours 7–10 mm.³⁰ Similarly, Soga et al. showed a rate of metastases of 24/247 (9.7%) for 6–10 mm tumour size and 2/153 (1.3%) for < 5 mm tumours.

Other risk factors for metastatic disease such as the presence of lymphovascular invasion, the presence of muscular invasion, histological non-L cell-type and a high tumour grade have also been reported in different studies.^{9,29,31,35,36} Correlation between tumour size and lymphovascular invasion has also been demonstrated with a tumour size ≥ 5 mm at higher risk of lymphovascular involvement than in tumours with a size < 5 mm,³⁶ and predictive scores taking into account both, the tumour size and the lymphovascular involvement have been shown to provide an accurate assessment of the risk of metastatic lymph node involvement.^{37,38}

Computed tomography (CT) has limited value for the detection and characterisation of regional metastatic lymph nodes in patients with rNET.³⁹ Similarly to rectal adenocarcinoma, MRI with diffusion-weighted imaging (DWI) is considered as the most sensitive imaging method for regional lymph node detection, detection of residual disease after incomplete resection, and the involvement of pelvic structures in more advanced tumours.⁴⁰

Recommendation:

Baseline locoregional staging by pelvic MRI should be recommended in patients with

- rNET with a tumour size ≥ 10 mm
- All G2-G3 rNET
- rNET with suspected involvement of lymph nodes on EUS

If the rNET has been already resected (in addition to previous recommendation)

- rNET with incomplete resection (in R1 without risk factors only if a second endoscopic resection with the result of R0 is not done)
- rNET with a tumour size of 5–10 mm and lymphovascular involvement or invasion of the muscularis propria.

Level of evidence/grade of recommendation: Level 4 grade C.

Concerning distant metastases, the liver is the most common metastatic site (58%) followed by bone (9.4%), mesentery, peritoneum (8.4%) and lung (8%).³⁵ As for metastatic lymph nodes, the tumour size is the major parameter for the risk of developing distant non-nodal metastases. Data from a large American cohort of 3880 patients from the National Cancer Database (NCDB) showed that the optimal cut-off of tumour size for the presence of distant metastases was 11.5 mm with an incidence of distant metastases reported at 13.8% in tumours ≥ 11.5 mm.⁴¹

Similar to other digestive NEN, abdominopelvic CT and ⁶⁸Ga-SSR-PET/CT (¹¹¹In-DTPA scintigraphy if PET/CT not available) are the imaging modalities of choice for distant metastases staging. Due to the superiority of MRI over CT and ⁶⁸Ga-SSR-PET/CT for liver metastasis detection, liver MRI including DWI is recommended in cases of liver metastases depicted or suspected on CT and/or SRI. Injection of a hepatospecific contrast agent at MRI is preferred to extracellular contrast agent for liver metastases detection and characterisation, particularly if liver surgery is being discussed.⁴²

The role of PET-CT is mainly to assess the presence of metastatic spread or to assess eligibility/usefulness of subsequent treatment lines in metastatic disease. Most well-to-moderately differentiated NET retain high expression of somatostatin receptors (SST) and therefore they can be studied by ⁶⁸Ga-SSR-PET/CT ([⁶⁸Ga]Ga-DOTATOC-, [⁶⁸Ga]Ga-DOTATATE-, [⁶⁸Ga]Ga-DOTANOC- PET/CT) for both primary (if dimensionally feasible) and metastatic sites detection (especially at liver and nodal level). ⁶⁸Ga-SSR-PET/CT is a fundamental pre-requisite to assess eligibility for peptide receptor radionuclide therapy (PRRT) in advanced inoperable tumours showing significant SST expression. EANM guidelines⁴³ also recommend the use of [¹⁸F]FDG PET/CT (¹⁸F-FDG PET/CT) to assess glucose metabolic activity, often increased in these tumours. FDG-derived data may help guide choices of chemotherapy as well as to provide prognostic data. However, since FDG use in NEN is not standardised and grade strongly influences the pretest probability of FDG-positivity, even in the setting of rectal NET, ¹⁸F-FDG PET/CT is generally considered in cases of metastatic higher-grade G2 ($> 10\%$), or NET G3. For PET-CT it is important to take its limitations into account (in particular, spatial resolution of approximately 5 mm; potential false positivity at sites of infection/inflammation), so appropriate timing after surgery should be adopted.

Recommendation: Distant metastases staging with chest CT and abdominal CT/MRI and ⁶⁸Ga-SSR-PET/CT is recommended in patients with

- Tumour size ≥ 10 mm
- Any grade 2–3 rNET

Level of evidence/grade of recommendation: Level 4 grade C.

2.4 | Which endoscopic/surgical techniques are appropriate to treat rectal NETs (including indication for oncological resection)?

2.4.1 | Background

Risk factors for more malignant behaviour/metastases are size (as above) but also endoscopic features (depression or ulceration), imaging features (suspicious lymph nodes on EUS or MRI) and pathological features (grade >1 and or lymphangiogenesis).^{44,45} Comparing 515 G1 and 86 G2 rNET, the incidence of lymph nodes and distant metastases was 5.2% and 2.1% in G1 NETs compared to 44.2 and 31.4% in G2 tumours, respectively.⁴⁶

As mentioned above risk for lymph node or distant metastases is very low after endoscopic removal of T1/G1-NET <10 mm.^{33,47} However, there is no definite lower limit of size that excludes lymph node spread.⁴⁸

Techniques that are used to remove rectal NETs:

1. Simple polypectomy
2. Endoscopic mucosal resection (EMR) (lift and snare, with or without diathermy) piecemeal or in one specimen⁴⁹
3. Cap-EMR⁵⁰
4. Underwater EMR⁵¹
5. Endoscopic submucosal dissection (ESD)
6. Transanal minimally invasive surgery (TAMIS) or transanal endoscopic microsurgery (TEMS).
7. Endoscopic full thickness resection (eFTR) with specific device or “over the scope clip” (OTSC) and snare
8. Low anterior resection (LAR) with total mesorectal excision (TME)
9. Abdominoperineal resection (APR) with TME

There are thus many different ways of removing a rectal NET. A common scenario is that the rectal NET is removed using a snare polypectomy with or without prior lifting. This is commonly performed if the lesion is not recognised as a rectal NET and assumed to be a more common type of polyp. This often results in an R1 resection of the rectal NET. For management of R1 resection, see question below.

Ideally, the lesion in the rectum would be recognised as a NET by its yellow/orange colour and sometimes by the typical appearance of a doughnut-shaped lesion. The doughnut appearance commonly occurs when the lesion reaches 1 cm. Below the size of 1 cm an experienced endoscopist will be able to determine whether it is likely that an R0 resection can be achieved, and then it is reasonable to use at least a lifting or a cap technique to remove the lesion.⁵²

A meta-analysis showed that ESD was successful for rectal NEN with a complete resection rate of 89%, 4% adverse events and <1% local recurrence. The complete resection rate was better for ESD than for conventional EMR (89 vs. 75%, $p < .001$). However, modified-EMR (with band ligation, double channel, cap assisted, circumferential pre-cutting) showed complete resection in 91% of patients.⁵³ Two meta-analyses showed modified EMR superior to c-EMR and ESD (95% vs. 84%, $p = .03$) with no differences in adverse events and recurrence rates.^{31,54} Recent small studies reported a 100% R0 rate after

endoscopic full thickness resection (eFTR) without major adverse events and short intervention times.^{55,56}

Patients with rectal NET >20 mm or evidence of lymph node metastases are treated, depending on the level of the rectal NET, with either a low anterior resection (LAR) or abdominoperineal resection (APR) combined with a total mesorectal excision (TME). The most important complication of a LAR with TME is anastomotic leakage. Some evidence suggests only a small number of patients have mesorectal metastases; only 3/8 patients undergoing LAR and synchronous TME for rectal NET had lymph node metastases in the mesorectum.⁵⁷ As mentioned above, for lesions >2 cm, the likelihood of LN and distant metastasis is higher and full imaging is always required. TAMIS can be performed if patients have comorbidities precluding more major resection.⁵⁸

For lesions 1–2 cm endoscopic resection can be undertaken, but it is important to achieve R0 resection. If there is contact with the muscularis propria, some of the rectal muscle needs to be dissected out. This has been done endoscopically (either full or partial muscle resection with intermuscular dissection between the circular and longitudinal muscle) or with transanal surgery with full or partial thickness muscle resection. If lymph nodes are seen to be involved, clearly an oncological surgical resection is required.

Recurrence rates for LAR combined with TME for larger rectal NET or rectal NET with more malignant behaviour are based on case reports. Most recurrences are described in the lateral pelvic compartment or as liver metastases.^{39,59}

2.4.2 | Recommendations (also see algorithm)

- For lesions 10 mm or less endoscopic (mEMR, ESD, eFTR) resection is recommended and recurrence rates are low.
- For lesions 20 mm or more, surgical resection using LAR or APR is recommended (after exclusion of unresectable distant metastases).
- For lesions 10–20 mm full imaging will lead to MDT discussion about either endoscopic or surgical therapy.

Level of evidence/grade of recommendation: Level 3 grade C.

Figure 1 illustrates the diagnostic/therapeutic algorithm for rectal NET.

2.5 | Is there need for a second resection in patients with R1-resected rectal NET?

2.5.1 | Background

As mentioned above, it is common to have an R1 resection of a rectal polyp, usually since it is not recognised this was a NET prior to polypectomy. This is a common reason for referral to a NET unit when the polyp has been resected elsewhere.

Pathology issues: R1/2 resection is defined when a biopsy/tissue sample shows that the NET reaches the limits of the sample itself (even a free margin <1 mm is defined as R0), that is, the endoscopist did not succeed in a complete removal of the “polyp” or the

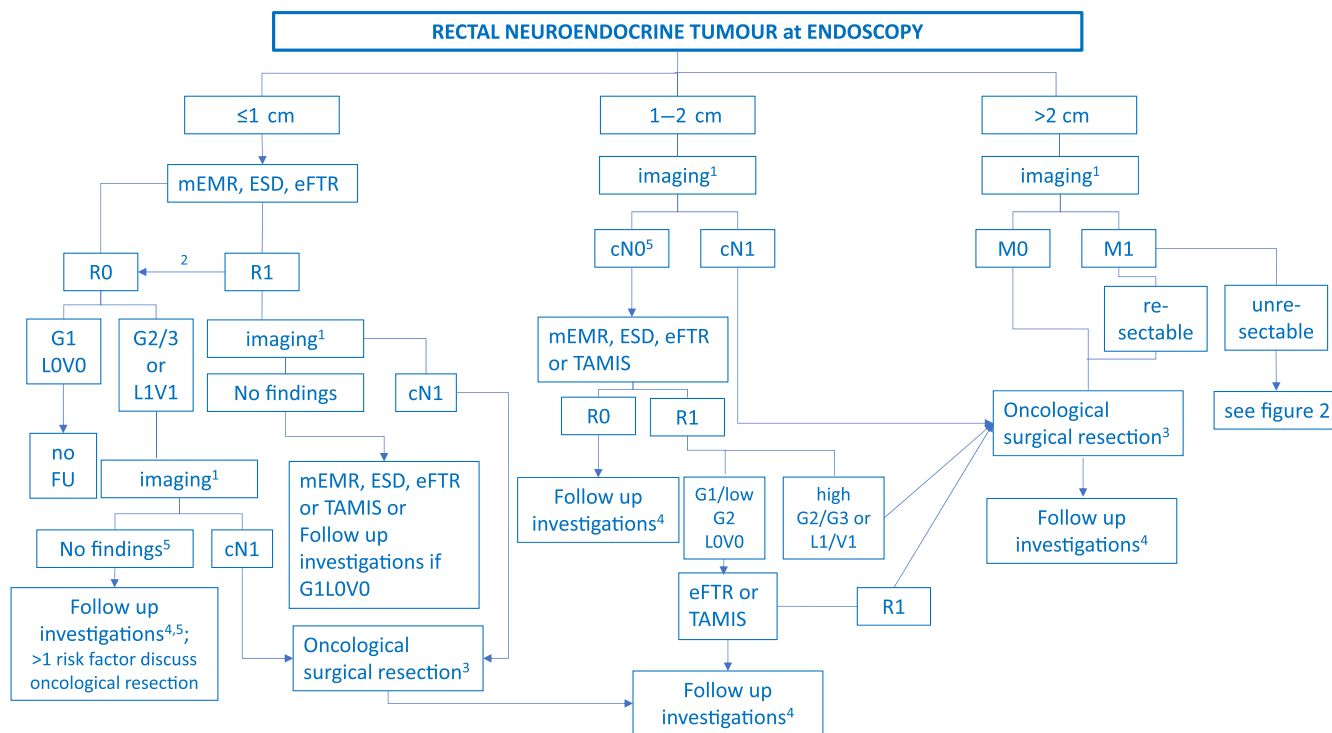


FIGURE 1 Diagnostic and therapeutic algorithm for patients with rectal neuroendocrine tumours (NET). ¹Imaging usually includes endoscopic ultrasound and pelvic magnetic resonance imaging (MRI) for local staging and distant metastases staging with chest and abdominal computed tomography (CT)/MRI and ⁶⁸Gallium SSA-PET-CT. ²In patients with R1 pathology after inappropriate endoscopic resection (e.g., force biopsy or snare resection) a second endoscopic resection with appropriate technique (mEMR, ESD, eFTR) can be undertaken without imaging and if the result is R0 and G1 LOVO no further investigations necessary. ³Oncological surgical resection means either a low anterior resection (LAR) or abdominoperineal resection (APR) combined with a total mesorectal excision (TME) depending on the localisation in the rectum. ⁴Follow-up investigations include conventional imaging, functioning imaging and endoscopic re-evaluation. For details please see text recommendation 2.8.1. ⁵In cases with more than one risk factor even with normal imaging a careful discussion with the patient is necessary to decide on follow-up or oncological resection; risk factors are: size >1 cm, G > 1; L1; V1. eFTR, endoscopic full thickness resection; ESD, endoscopic submucosal dissection; FU, follow-up; mEMR, modified endoscopic mucosal resection (for example cap EMR); TAMIS, transanal minimally invasive surgery.

endoscopist on purpose took a small sample of a large lesion in order to assess its nature. In the case of mucosectomy of a known NET lesion, especially when sessile, special care should be applied. It is common safety practice to align the fresh sample on cardboard to reduce fixation shrinking artefacts. In most cases this allows a proper handling of margins by pathologists and a correct R assessment. In some cases, however, this may still be difficult/impossible. The pathologist is recommended to report this issue clearly so that a discussion of the case may be decided before any further action.

In the presence of an R1 resection, if the original tumour was >2 cm, an oncological resection is indicated after appropriate imaging had excluded unresectable distant metastases (see above).

If the tumour was 1–2 cm and an R1 resection is documented there is a risk of recurrence at the site and in the pelvic LN. In addition to imaging (see above) careful examination of the resection site is needed which is usually visible quite easily due to the scarring that occurs after resection of a lesion this size. Biopsies should be taken from the site of resection and rectal EUS should determine if there is any abnormal tissue deep to the resection. Normally, a resection of this scarred area should be undertaken either by an expert endoscopist resecting the mucosa and submucosa down to the muscle layer, or by of full-thickness resection endoscopically or by transanal surgery. It is

important for a lesion of this size that it is resected en bloc (see above) so that the pathologist can definitively say that there is now an R0 resection at the end of this second procedure. In patients unfit for endoscopic or surgical resection, a watch-and-wait policy might be adopted after discussion with the patient, but it would have to be explained that the recurrence rate is unknown but probably not zero.

For lesions of less than 1 cm the usual situation is that the snare resects the tumour at or very close to the edge of the tumour and this is technically an R1 resection by oncological standards. This does not necessarily mean that there is tumour tissue remaining at the resection site. Normally, these patients would have a close inspection of the resection site together with biopsies and an endoscopic ultrasound of the area if possible. The safest approach is to perform further endoscopic or TAMIS resection to prevent any possible recurrence. It is unclear whether re-resection of R1 resected small rectal NET affects long term outcome.⁴⁹ Some units would recommend a watch-and-wait policy but there is a small risk of recurrence and the patient will need long term follow-up. There are large series from South Korea^{60,61} where this disease is very common, and it seems clear that up to 2 years the recurrence rate is close to 0. This does not necessarily mean that the recurrence rate is 0 for ever and if watch and wait is adopted we recommend flexible sigmoidoscopy at

intervals after an R1 resection of these small lesions. In practice, if these tumours recur, it is usually at the same site and they continue to be very slow growing so a full thickness resection can be considered on recurrence. As far as we are aware, the incidence of lymph node and distant metastases from these recurrences is extremely low.

2.5.2 | Recommendations (post R1 resection)

- >2 cm or adverse features (higher G2 / G3; L1; V1): oncological resection after exclusion of distant metastases
- 1–2 cm full imaging and endoscopic work up. Repeat endoscopic resection if appropriate (full thickness)
- <1 cm. Ideally: Second endoscopic resection or TAMIS to achieve R0, alternatively: if negative EUS, MRI and repeat biopsy: watch and wait after discussion with patient.

Level of evidence/grade of recommendation: Level 3 grade C.

2.6 | Is there a role for surgery in metastatic rectal NET?

2.6.1 | Background

It is common for larger rectal NET (>2 cm) to have distant metastases, particularly to the liver and bone.

Resection of the primary in the presence of distant metastases will depend on whether there are local symptoms (bleeding, obstruction) and whether any resection of metastases might be possible. Many factors will be involved in this discussion with the patient. In patients with asymptomatic primary and unresectable metastases tumour control by systemic treatment has priority.

2.6.2 | Recommendation

Primary resection in the presence of unresectable metastases will depend on the presence of local symptoms such as pain and bleeding.

Level of evidence/grade of recommendation: Level 5 grade D.

2.7 | Which systemic treatments should be selected in patients with metastatic colonic and rectal NET?

2.7.1 | Role of somatostatin analogues (SSA) for tumour control?

Background: Octreotide LAR and lanreotide autogel are well-established antiproliferative first-line treatments in patients with receptor positive GEP-NET and a proliferation rate Ki-67 not exceeding 10% based on the results of two placebo-controlled phase III trials.^{18,20} Whereas patients with NET

of the right-side of the colon (belonging to the midgut) were included in both trials without information on results of this subgroup, patients with hindgut NET were only included in the CLARINET trial. This subgroup comprised 14 patients (11 lanreotide arm, 3 placebo arm) and with a HR of 1.47 with broad confidence interval a benefit could not be demonstrated.²⁰

Recommendation: SSA are indicated as first-line treatment of metastatic receptor positive NETs of the right colon. Considering the limited treatment options for these patients and the favourable side effect profile of SSA, SSA may also be used in NET of colorectal origin belonging to the hindgut if the tumour lesions are SST positive and slowly growing.

Level of evidence/grade of recommendation for patients with caecal NET and NET of the right sided colon: Level 2a grade A.

Level of evidence/ grade of recommendation for left sided colon and rectum: Level 2b grade B.

2.7.2 | Is there a role for everolimus?

Background: Two large placebo-controlled studies for evaluation of the efficacy of everolimus with antiproliferative intention included patients with colorectal NET: The RADIANT-2 and the RADIANT-4 trial. A subgroup analysis of RADIANT-2 in patients with colorectal NET ($N = 39$, representing 9% of the study population) demonstrated a significant prolongation of mPFS by adding everolimus to octreotide LAR compared to placebo plus octreotide LAR (29.9 months vs. 6.6 months; HR 0.34, $p = .011$), despite objective responses not being documented.²¹ For the 28 patients with colonic NET treated within this study on patients with a history of CS, a mPFS of 29.9 months was documented in the treatment arm with everolimus and 13 months without (HR 0.39; $p = .056$). The RADIANT-4 trial of non-functioning NET included 40 patients with rectal NET, eight colonic NET and five caecal NET (18% of the study population). The subgroup publication of gastrointestinal NET⁶² reported clear efficacy for the rectal NET subcohort with a prolongation of PFS from 1.9 months with placebo to mPFS of 7.4 months with everolimus. The results of the patients with colonic NET were not reported separately. Taking the results for all gastrointestinal NETs together a prolongation of mPFS from 5.4 months (placebo) to 13.1 months (everolimus) was documented (HR 0.56). The majority of patients received prior treatments before inclusion in the RADIANT 2 or 4 trials.

Recommendation: Everolimus is indicated for tumour control in patients with metastatic colorectal NET progressing after prior treatment(s). In selected patients, for example with SST negative tumours, it may also be used as first-line systemic treatment.

Level of evidence/grade of recommendation for everolimus in colorectal NET: Level 1b (2 randomised controlled trials available with a cohort of colorectal NET representing 9% and 18% of the entire study cohort, respectively), grade B.

2.7.3 | Role for tyrosine kinase inhibitors (TKIs)?

Background: At the time of writing, the only TKI labelled in Europe for NET patients is sunitinib in pancreatic NET patients. Several phase II

trials with TKIs (sunitinib, pazopanib, cabozantinib, lenvatinib, surufatinib and axitinib)^{63–68} included some colorectal patients without reporting efficacy details for this subgroup. The phase II/III AXINET trial for patients with progressive extrapancreatic NET included four colonic and 16 rectal NET patients (8% of the study population) but specific data for this subgroup are not available. Using centralised reporting mPFS with axitinib + octreotide LAR was prolonged to 16.6 months compared with 9.9 months with placebo + octreotide-LAR. The Chinese SANETep trial is a randomised placebo-controlled phase III trial of surufatinib in patients with extrapancreatic NET. The trial included four colonic (2%) and 53 rectal (26.8%) NET patients. Efficacy for the entire study population was demonstrated with an ORR of 10% in surufatinib-treated patients (vs. 0% in the control arm), and a mPFS of 3.8 months in the placebo group versus 9.2 months in the surufatinib group (HR 0.33; $p < .0001$).⁶⁹ A phase III trial of cabozantinib is running in the USA (NCT03375320).

Recommendation: TKI may be used in patients with colorectal NET after failure of better-established treatment options (everolimus, PRRT, locoregional treatments), ideally within a clinical trial. More data are needed to define the role of TKIs in colorectal NET.

Level of evidence/grade of recommendation for TKIs in colorectal NET: Level 2b (low quality randomised trials available including a small subcohort of colorectal NET), grade B.

2.7.4 | Role of chemotherapy

Background: Chemotherapy plays a minor role in the treatment of well-differentiated NET of non-pancreatic origin but has not been specifically assessed in colorectal NET. Only the first randomised trial (EST 3272) ever conducted in metastatic “carcinoid” tumours specifically reported results for the small subgroup of colorectal NET (7 patients [6%]).⁷⁰ This trial randomised 118 patients to receive streptozotocin (STZ) with cyclophosphamide (CTX) versus STZ with 5-fluorouracil (5-FU). No significant differences were observed in response rate (RR) (33% vs. 26%) or survival (12.5 m vs. 11.2 m) among study arms. Global RR for colorectal NET was 29%, 20% for colon ($N = 5$) and 50% for rectal primaries ($N = 2$). Other randomised trials included $\leq 10\%$ of colorectal primaries⁷¹ or no colorectal primaries at all,⁷² and none reported subgroup analysis for colorectal NET. More recent non-controlled phase 2 trials have not included colorectal NET or have not specified the GI primary tumour site of patients included.⁷³ One of the few exceptions is the BETTER trial that explored capecitabine and bevacizumab in 49 patients with advanced GI NET (40 small bowel, 7 colorectal, 2 other primaries).⁷⁴ This trial reported an objective response rate per RECIST of 18% (12% per central review), a median PFS of 23.4 months, and a 2-year OS rate of 85%. Some retrospective series suggest FOLFOX may also be an active regimen in digestive NET (RR 17% in rectal NET).^{75,76} A systematic review and meta-analysis of 13 clinical trials and 7 retrospective series, that included 264 patients with non-pancreatic GI NET (median of 11 patients/study), reported an overall

RR of 11.5% (range: 5.8%–17.2%).⁷⁷ No solid data are available, however, on chemotherapy efficacy by tumour proliferative index, which is likely to have a relevant impact on response rates, particularly of cell cycle phase-specific cytotoxic agents.

In summary, the quality of evidence regarding assessment of chemotherapy efficacy in colorectal NET is poor. Site-specific clinical trials and exploratory descriptive analysis of trial outcomes per site and proliferative index are highly encouraged.

Recommendation: Chemotherapy efficacy data are very limited in colorectal NET and its use is, therefore, not recommended on a routine basis. Chemotherapy may be considered in selected individuals with rapidly progressive advanced colorectal NET upon failure of other better assessed therapeutic options. Fluoropyrimidine-based regimens, generally combined with temozolomide or oxaliplatin, are the preferred treatment options when chemotherapy is judged to be indicated in selected patients with colorectal NET.

Level of evidence/ grade of recommendation for chemotherapy in colorectal NETs: Level 2b (low quality randomised trials available for extrapancreatic NET including a small subcohort of colorectal NET), grade C.

2.7.5 | PRRT for colorectal NET

Background: Metastatic rectal NET are generally associated with a poorer prognosis and treatment options are not standardised. [¹⁷⁷Lu] Lu-DOTA-TATE PRRT is now approved for the treatment of unresectable or metastatic, progressive, well-differentiated (G1 and G2), SST-positive GEP NET in adults in Europe and the United States. Overall, published data support a significant improvement in progression-free survival and quality of life of PRRT-treated midgut NET patients (including 4 colonic NET patients). In addition, a non-significant trend to better overall survival compared to high dose SSA was documented.⁷⁸ PRRT may be considered in advanced metastatic rectal NET patients showing SSA PET-CT-positivity. Published evidence of the efficacy and feasibility of PRRT in rectal NEN is scarce, mostly consisting of case reports or small series included in larger cohorts including NET of other primary tumour sites.^{79–83}

In 2019, a retrospective study specifically addressing results of PRRT in patients with advanced rectal NET was published⁸⁴: 27 rectal NEN patients (G2 = 19, G3 = 3, G1 = 1; unknown grade in 4 cases) were treated with PRRT (26 for disease progression, 1 for uncontrolled symptom). PRRT was well tolerated, showing minimal toxicity (no grade 3 or 4 toxicity was reported) and promising results, both in terms of objective response (overall disease control rate was 96%: 70% had RECIST 1.1 partial response, 26% had stable disease) and symptom control (overall 59% reported partial improvement of symptoms: mostly reduction of pain, improvement in weight, prior bowel symptoms). Finally, the study showed that re-treatment with PRRT is also feasible provided that SST-expression is maintained. Overall, further data are needed to fully assess the benefits of PRRT in rectal NEN in the paradigm of other treatment options, although preliminary published results are encouraging.

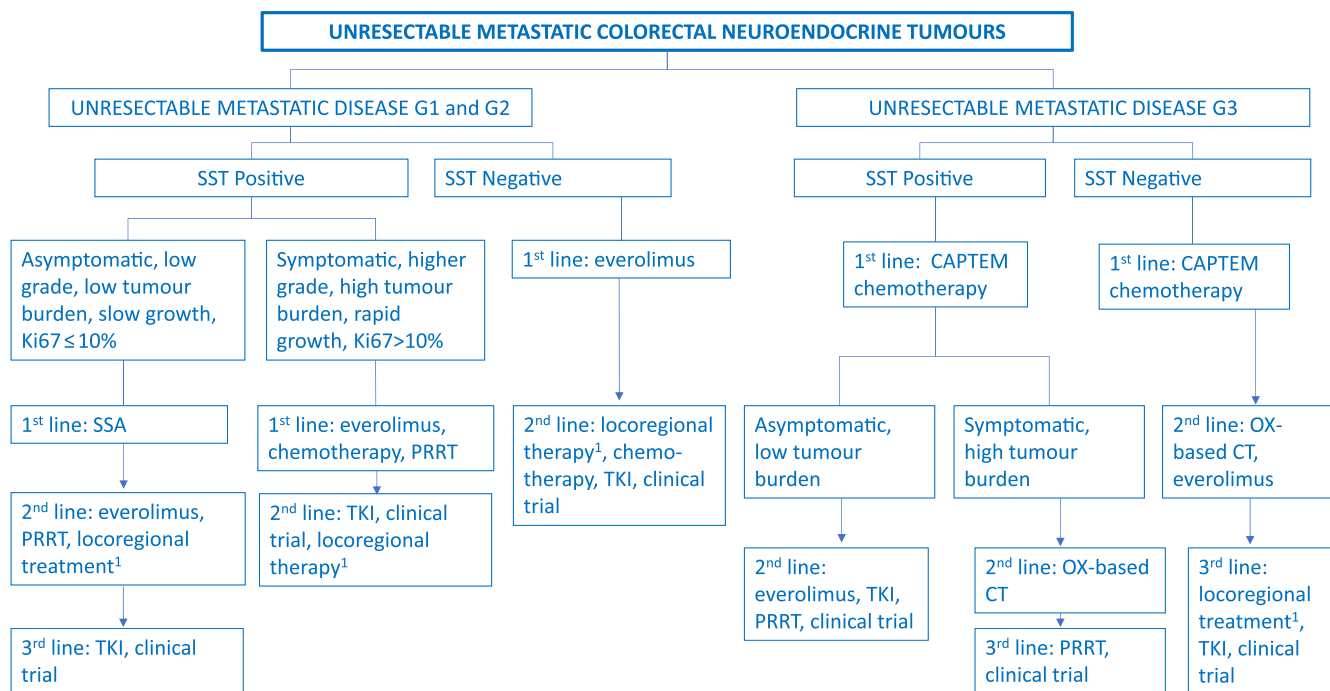


FIGURE 2 Treatment algorithm illustrating antiproliferative treatment strategies for patients with unresectable metastatic colorectal neuroendocrine tumours (NET). ¹Only in patients with liver predominant disease. CAPTEM, chemotherapy with capecitabine + temozolomide; OX-based CT, chemotherapy with oxaliplatin and 5-fluoro-uracil + folinic acid or capecitabine; locoregional treatment, treatment directed to liver metastases only in liver predominant disease (chemo-) embolisation, radioembolisation; PRRT, peptide receptor radionuclide therapy; SST, somatostatin receptor; SSA, somatostatin analogues; TKI, tyrosine kinase inhibitors. Arrows in the figure represent progressive disease. Asymptomatic or symptomatic in this algorithm does not refer to carcinoid syndrome or other hormonal symptoms but to general tumour-related symptoms such as pain, weight loss, and inappetence. Patients with carcinoid syndrome should always be treated with SSA. As evidence for several situations is limited discussion of the individual situation of a patient with metastatic colorectal NET in an experienced MDT is mandatory.

Recommendation: PRRT is recommended for SST positive metastatic colorectal NET progressing after prior treatment(s) although further data are needed.

Level of evidence/grade of recommendation: Level 4, grade B.

Figure 2 summarises the treatment options in patients with unresectable metastatic colorectal NET.

2.7.6 | Neoadjuvant treatment

Data on neoadjuvant treatment of NEN patients with colorectal NET, mainly with chemotherapy, PRRT and chemoradiotherapy in the case of rectal primary, are sparse.⁸⁵ These data derive from retrospective studies of limited numbers of patients or case reports. It is reasonable to consider neoadjuvant/downstaging therapies in selected patients with locally advanced or oligometastatic disease, no comorbidities and good performance status, but prospective studies are necessary to clarify their role in this clinical setting. In those rare cases with potential application of a neoadjuvant approach it is strongly advisable to be cautious and discuss it after careful evaluation of all the parameters in a multidisciplinary setting.

Recommendation: Neoadjuvant therapy could be considered in carefully selected patients although further data is needed.

Level of evidence/grade of recommendation: Level 4 grade D.

2.8 | What is the recommended follow-up in rectal or colonic NET?

2.8.1 | Rectal NET—Background

Following local endoscopic excision of rectal NET, clear distinction needs to be made following resection that is pathologically R0, indeterminate or R1. As per above, every attempt should be made to render indeterminate or R1 resected lesions R0 and this will thus allow for follow-up decisions based on R0 resection category.

The rate of recurrence following local/endoscopic excision of rectal NET varies and is dependent on factors such as size and tumour biology, as above.

Analysis of follow-up is difficult due to the retrospective nature of data and grouping of patients with and without additional therapies following initial endoscopic resections (e.g., salvage local excisions either endoscopic or surgical). A recent systematic review and meta-analysis of prognostic importance of lymphovascular invasion (LVI) in small (<20 mm) rectal NET including 15 studies with a total of 1213 patients, provided sufficient data to evaluate the prognostic impact of LVI on disease recurrence.³⁶ In total, 1022/1213 (84.2%) cases were followed up. The groups of patients were very heterogenous. Two cases of recurrence were found in follow up: 109 patients in three studies had no further resection, even though, LVI was identified at endoscopic resection. None of these 109 recurred during the follow-

up period (30–76 months). A total of 31 patients had additional radical surgery after endoscopic resection, of which positive lymph nodes were found in 21.7% (5/23).³⁶

Another meta-analysis comparing resection techniques (EMR with suction vs. ESD) for small rectal NET found overall recurrence rates to be low (<1%) with one local recurrence and one case with metastasis to the liver (duration of follow-up was short).⁵⁴ Another meta-analysis comparing ESD to EMR techniques for endoscopic resection did not find any difference with respect to risk of recurrence.⁸⁶

Specific information for method of imaging, best intervals, and duration of follow-up after R0 resection of rNET with risk factors (size >10 mm, G2/G3, microangiainvasion) are not available.

Recommendations:

- After R0 resection of a rectal NET G1 L0 V0 ≤ 10 mm a follow-up is not necessary.
- After R0 resection of a rectal NET G1 L1 or V1 or G2/G3 ≤ 10 mm 6 monthly abdominopelvic MRI and yearly sigmoidoscopy for at least 5 years is recommended. In addition, ⁶⁸Ga-SSR-PET/CT is recommended initially and after 12 months.
- After R1 resection of a rectal NET G1/ low G2 ≤ 10 mm (without second endoscopic resection to reach R0) endoscopy and EUS or MRI 12 monthly for at least 5 years is recommended.
- After R0 resection of a rectal NET G1/G2 > 10 mm 6 monthly MRI and yearly sigmoidoscopy for at least 5 years is recommended. In addition, ⁶⁸Ga-SSR-PET/CT is recommended initially and after 12 months.
- After R0 resection of a rectal NET G3 3 monthly MRI for 2 years followed by 6 monthly MRI for 5 years and 6 monthly sigmoidoscopy for 2 years, followed by yearly endoscopic investigations for 5 years is recommended. In addition, ⁶⁸Ga-SSR-PET/CT is recommended initially and after 12 months. ¹⁸F-FDG PET/CT may be considered.

Level of evidence/grade of recommendation: Level 5 grade C.

2.8.2 | Colonic NET-background

Due to the rarity of colonic NET no specific information for follow-up from published data are available. Tumour specific follow-up is mainly based on the estimated risk of recurrence and clinical symptoms. In the low risk group of pT1 pN0 R0 G1, follow-up may be limited to yearly abdominal MRI for 5 years and a follow-up colonoscopy after 12 to 24 months, but for the majority of patients life-long follow-up is recommended according to the ENETS standards of care (SOC).⁸⁷ Curative resected stage III and IV patients harbour a relevant risk of recurrence and imaging is indicated 6 monthly long term. If initially receptor positive, ⁶⁸Ga-SSR-PET/CT is recommended every 24 months according to the SOC publication.⁸⁷ In NET G3 cases a shorter follow-up interval of 3 months may be appropriate and additional ¹⁸F-FDG PET/CT can be considered.

Recommendations:

- After complete resection of a NET G1/G2 without lymph node involvement abdominal MRI or CT in yearly intervals for at least 5 years is recommended.

- In patients with complete resected colonic NET G1/G2 and initial stage III or IV imaging with thoracoabdominal CT or abdominal MRI and chest CT is recommended 6 monthly. In addition, ⁶⁸Ga-SSR-PET/CT every 24 months is recommended if initially positive.
- In patients after complete resection of a colonic NET G3, initial imaging intervals of 3 months are recommended.
- Colonoscopy is recommended in all complete resected patients after 12 months or if symptoms occur.

Level of evidence/grade of recommendation: Level 5 grade C.

3 | UNMET NEEDS AND FUTURE PERSPECTIVES

As illustrated by the low levels of evidence for the recommendations in our guidance paper, colorectal NET is an under-researched area.

The most frequent colorectal NET are the small rectal NET which in the vast majority harbour a low malignant potential. Risk factors for lymph node and distant metastases have been identified. The best technique to treat these patients as well as the need for follow-up is unclear. Long term follow-up data (at least 5 years) for R1 resected small tumours without risk factors are needed to establish whether late recurrence occurs. In patients with R0 resection and risk factors there are no standardised follow-up protocols available. For localised rectal NET we therefore suggest:

- Randomised clinical trial comparing the outcome of modified EMR techniques with endoscopic full thickness resection
- Prospective data collection of R1 resected rectal NET patients if a second endoscopic intervention is not performed to establish the risk of late recurrence
- Follow-up protocols need to be researched.

In patients diagnosed with metastatic disease the best therapeutic approach or sequence of treatments is largely unknown. Although tumour characterisation has improved and it has been identified that ileal NET, colonic NET and rectal NET are different entities, they are mixed together in study protocols as “extrapancreatic NET” often without outcome data being reported for the subgroups. Further clinical trials should include colon NET and rectal NET as individual cohorts.

There is still a lack of predictive markers that could be used for treatment decisions. First retrospective data report high response rates to PRRT in metastatic well-differentiated rectal NET (see above).⁸⁴ At the time of writing two international studies (NCT 03972488 and NCT 04919226) will analyse the efficacy of first line PRRT in NET G2 / G3. Hopefully, reports will include information on the subcohort of rectal NET patients.

With the WHO classification 2019, the subgroup of NET G3 has been introduced also for gastrointestinal NET.⁶ Most available data for NET G3 focus on pancreatic NET G3 and the best treatment approach for colorectal NET G3 is unclear.

For metastatic colorectal NET we suggest:

- An international effort to run a trial for metastatic rectal NET (e.g., to compare CAPTEM chemotherapy with PRRT in NET G2 with Ki-67 >10% as first-line treatment)
- Inclusion of metastatic colonic and metastatic rectal NET patients in trials evaluating new treatment options with separate reports for these subgroups
- More research to establish predictive markers.

AUTHOR CONTRIBUTIONS

Anja Rinke: Conceptualization; data curation; supervision; writing – original draft; writing – review and editing. **Valentina Ambrosini:** Data curation; writing – original draft; writing – review and editing. **Clarisse Dromain:** Data curation; writing – original draft; writing – review and editing. **Rocio Garcia-Carbonero:** Data curation; writing – original draft; writing – review and editing. **Amy Hajj:** Writing – review and editing. **Anna Koumariou:** Visualization; writing – original draft; writing – review and editing. **Els Nieveen van Dijkum:** Data curation; writing – original draft; writing – review and editing. **Dermot O'Toole:** Data curation; writing – original draft; writing – review and editing. **Guido Rindi:** Data curation; writing – original draft; writing – review and editing. **Jean Yves Scoazec:** Data curation; writing – original draft; writing – review and editing. **John Ramage:** Conceptualization; supervision; visualization; writing – original draft; writing – review and editing.

ACKNOWLEDGMENTS

We thank the members of the ENETS office for their support. The authors of this ENETS guidance paper are grateful to the ENETS Advisory Board members for their useful suggestions and comments in a common effort to improve the quality of the present manuscript. Following colleagues were participants of the ENETS guidance paper consensus meeting 13 October 2022: Bartsch, D. K. (Department of Visceral-, Thoracic- and Vascular Surgery Philipps-University Marburg, Marburg, Germany); Begum N. (Department for General-, Visceral-, Thoracic- and Endocrine Surgery, Johannes-Wesling-Klinikum Minden, University Hospital of the Ruhr-University Bochum, Germany); Capdevila, J. (Medical Oncology Department, Gastrointestinal and Endocrine Unit, Vall d'Hebron University Hospital, Barcelona, Spain); Caplin, M. (Neuroendocrine Tumour Unit, ENETS Center of Excellence, Royal Free Hospital and University College London, London, United Kingdom); Castaño, J. P. (Maimonides Biomedical Research Institute of Córdoba (IMIBIC), Reina Sofia University Hospital, University of Córdoba, Córdoba, Spain); Couvelard, A. (Pathology Department, Bichat Hospital, AP-HP and Université Paris Cité, Paris, France); Denecke T. (Universitätsklinikum Leipzig, Klinik für Diagnostische und Interventionelle Radiologie, Leipzig, Germany); Deroose, C. M. (University Hospitals Leuven, Nuclear Medicine and KU Leuven, Department of Imaging and Pathology, Nuclear Medicine & Molecular Imaging, Leuven, Belgium); Fazio, N. (Division of Gastrointestinal Medical Oncology and Neuroendocrine Tumours, European Institute of Oncology (IEO), IRCCS, Milan, Italy); Hofland, J. (Department of

Internal Medicine, Erasmus MC, Rotterdam, The Netherlands); Kaltsas, G. (1st Propaedeutic Department of Internal Medicine, National and Kapodistrian University of Athens, Athens, Greece); Kjaer, A. (Department of Clinical Physiology and Nuclear Medicine & Cluster for Molecular Imaging, Copenhagen University Hospital – Rigshospitalet & Department of Biomedical Sciences, University of Copenhagen, Copenhagen, Denmark); Knigge, U. (Departments of Surgery and Clinical Endocrinology, ENETS Center of Excellence, Copenhagen University Hospital, Rigshospitalet, Copenhagen, Denmark); Kos-Kudła, B. (Department of Endocrinology and Neuroendocrine Tumours, Medical University of Silesia, Katowice, Poland); Panzuto, F. (Department of Medical-Surgical Sciences and Translational Medicine, Sapienza University of Rome / Digestive Disease Unit, Sant'Andrea University Hospital, ENETS Center of Excellence, Rome, Italy); Pavel, M. (Department of Medicine 1, Universitätsklinikum Erlangen, Erlangen, Germany); Peeters M. (Antwerp University Hospital, Department of Oncology, Edegem, Belgium); Salazar R. (Institut Català d'Oncologia, Barcelona, Spain); Santos A. P. (Endocrinology Department, Endocrine Tumours Clinic, Precancerous Lesions and Early Cancer Management Group, RISE@CI-IPO (Health Research Network), Portuguese Oncology Institute of Porto (IPO Porto) / Porto Comprehensive Cancer Center (Porto.CCC), Porto, Portugal); Sorbye H. (Haukeland University Hospital, Dept. of Oncology, Bergen, Norway); Srirajaskanthan R. (Neuroendocrine Tumour Unit, Kings College Hospital / Department of Gastroenterology, Hambleton Wing, Kings College Hospital, London, United Kingdom); Sundin A. (Uppsala University, Surgical Sciences, Uppsala, Sweden); Tesselaar, M.E. T. (Department of Gastrointestinal Oncology, The Netherlands Cancer Institute, Amsterdam, The Netherlands); Tiensuu Janson, E. (Department of Medical Sciences, Endocrine Oncology, Medical Faculty, Uppsala Universitet, Uppsala, Sweden); Toumpanakis, C. (Neuroendocrine Tumour Unit, ENETS Center of Excellence, Royal Free Hospital and University College London, London, United Kingdom); van Velthuysen, M. F. (Department of Pathology, Erasmus MC, Rotterdam, The Netherlands); Walter, T. (Department of Medical Oncology, Hôpital Edouard Herriot, Lyon, France); Welin S. (Endocrine Oncology, University Hospital, Uppsala, Sweden). Open Access funding enabled and organized by Projekt DEAL.

CONFLICT OF INTEREST STATEMENT

Anja Rinke has received travel and educational support from Ipsen and Novartis, speaker honoraria from AAA, Advanz Pharma, Falk Foundation, Ipsen and Novartis and advisory honoraria from AAA, Advanz Pharma, Esteve, Ipsen and Novartis. Valentina Ambrosini received speaker honoraria from ESMIT/EANM/ESMO in the past 3 years. Clarisse Dromain received consultant fee from Ipsen. Rocio Garcia-Carbonero has provided scientific advice and/or received honoraria or funding for continuous medical education from AAA, Advanz Pharma, Amgen, Bayer, BMS, Esteve, Hutchmed, Ipsen, Merck, Midatech Pharma, MSD, Novartis, PharmaMar, Pierre Fabre, Roche, Servier and Sanofi, and has received research support from Pfizer, BMS and MSD. Amy Hajj: No conflict of interest. Anna Koumariou has received educational support from Faran SA, Ipsen and Novartis,

speaker Ipsen and Faran SA. Els Nieveen van Dijkum: No conflict of interest. Dermot O'Toole has received travel and educational support from Ipsen and Novartis, speaker Ipsen and Novartis and advisory honoraria Ipsen and Novartis. Previous educational grants Wyeth Lederle. Guido Rindi: AAA speaker bureau; Bracco Imaging consultant fees. Jean-Yves Scoazec: No conflict of interest. John Ramage has received travel and educational support from Novartis and Ipsen.

PEER REVIEW

The peer review history for this article is available at <https://www.webofscience.com/api/gateway/wos/peer-review/10.1111/jne.13309>.

DATA AVAILABILITY STATEMENT

"n/a".

ORCID

Anja Rinke  <https://orcid.org/0000-0002-8156-2915>

Clarisse Dromain  <https://orcid.org/0000-0002-2999-1958>

Anna Koumariou  <https://orcid.org/0000-0002-4159-2511>

Guido Rindi  <https://orcid.org/0000-0003-2996-4404>

John Ramage  <https://orcid.org/0000-0003-4824-6600>

REFERENCES

- Ramage JK, De Herder WW, Delle Fave G, et al. ENETS consensus guidelines update for colorectal neuroendocrine neoplasms. *Neuroendocrinology*. 2016;103(2):139-143.
- Rindi G, Komminoth Paul JSJ-YS. *Colorectal neuroendocrine neoplasms. WHO Classification of Tumour Editorial Board (ed) Digestive System Tumours*. International Agency for Research on Cancer; 2019: 188-191.
- Rindi G, Mete O, Uccella S, et al. Overview of the 2022 WHO classification of neuroendocrine neoplasms. *Endocr Pathol*. 2022;33(1): 115-154.
- AK L. Anal neuroendocrine neoplasms. *WHO Classification of Tumour Editorial Board (ed) Digestive System Tumours*. International Agency for Research on Cancer; 2019:212-213.
- Sorbye H, Grande E, Pavel M, et al. European neuroendocrine tumor society (ENETS) 2023 guidance paper for digestive neuroendocrine carcinoma. *J Neuroendocrinol*. 2023;35(3):e13249.
- Klimstra DS, Kloppel G, G. LRSaR. *Classification of neuroendocrine Neoplasm of the Digestive System. WHO Classification of Tumour Editorial Board (ed) Digestive System Tumours*. International Agency for Research on Cancer; 2019:16-19.
- Shi C, Woltering EA, Beyer DT, Klimstra DS, Bergsland EK, et al. *Neuroendocrine Tumors of Colon and Rectum. Amin MB ed AJCC Cancer Staging Manual*. 1st ed. Springer Verlag; 2017:395-406.
- van Velthuysen MF, Couvelard A, Rindi G, et al. ENETS standardized (synoptic) reporting for neuroendocrine tumour pathology. *J Neuroendocrinol*. 2022;34(3):e13100.
- Kim JY, Kim KS, Kim KJ, et al. Non-L-cell immunophenotype and large tumor size in rectal neuroendocrine tumors are associated with aggressive clinical behavior and worse prognosis. *Am J Surg Pathol*. 2015;39(5):632-643.
- Dasari A, Shen C, Halperin D, et al. Trends in the incidence, prevalence, and survival outcomes in patients with neuroendocrine tumors in the United States. *JAMA Oncol*. 2017;3(10):1335-1342.
- White BE, Bouvier C, Genus T, et al. Incidence and prevalence of neuroendocrine neoplasms reported in England from 2015 to 2017. *Endocrine Abstracts*2019.
- Kooyker AI, Verbeek WH, van den Berg JG, Tesselaar ME, van Leerdam ME. Change in incidence, characteristics and management of colorectal neuroendocrine tumours in The Netherlands in the last decade. *United European Gastroenterol J*. 2020;8(1):59-67.
- Korse CM, Taal BG, van Velthuysen ML, Visser O. Incidence and survival of neuroendocrine tumours in The Netherlands according to histological grade: experience of two decades of cancer registry. *Eur J Cancer*. 2013;49(8):1975-1983.
- Xu R, Zhou B, Hu P, et al. Development and validation of prognostic nomograms for patients with colon neuroendocrine neoplasms. *World J Surg Oncol*. 2021;19(1):233.
- Nuñez-Valdovinos B, Carmona-Bayonas A, Jimenez-Fonseca P, et al. Neuroendocrine tumor heterogeneity adds uncertainty to the World Health Organization 2010 classification: real-world data from the Spanish tumor registry (R-GETNE). *Oncologist*. 2018;23(4):422-432.
- McMullen T, Al-Jahdali A, de Gara C, Ghosh S, McEwan A, Schiller D. A population-based study of outcomes in patients with gastrointestinal neuroendocrine tumours. *Can J Surg*. 2017;60(3):192-197.
- Grozinsky-Glasberg S, Davar J, Hofland J, et al. European neuroendocrine tumor society (ENETS) 2022 guidance paper for carcinoid syndrome and carcinoid heart disease. *J Neuroendocrinol*. 2022;34:e13146.
- Rinke A, Müller HH, Schade-Brittinger C, et al. Placebo-controlled, double-blind, prospective, randomized study on the effect of octreotide LAR in the control of tumor growth in patients with metastatic neuroendocrine midgut tumors: a report from the PROMID study group. *J Clin Oncol*. 2009;27(28):4656-4663.
- Strosberg J, El-Haddad G, Wolin E, et al. Phase 3 trial of (177)Lu-Dotatate for midgut neuroendocrine tumors. *N Engl J Med*. 2017; 376(2):125-135.
- Caplin ME, Pavel M, Ćwikła JB, et al. Lanreotide in metastatic enteropancreatic neuroendocrine tumors. *N Engl J Med*. 2014;371(3): 224-233.
- Castellano D, Bajetta E, Panneerselvam A, et al. Everolimus plus octreotide long-acting repeatable in patients with colorectal neuroendocrine tumors: a subgroup analysis of the phase III RADIANT-2 study. *Oncologist*. 2013;18(1):46-53.
- Al Natour RH, Saund MS, Sanchez VM, et al. Tumor size and depth predict rate of lymph node metastasis in colon carcinoids and can be used to select patients for endoscopic resection. *J Gastrointest Surg*. 2012;16(3):595-602.
- Osagiede O, Habermann E, Day C, et al. Factors associated with worse outcomes for colorectal neuroendocrine tumors in radical versus local resections. *J Gastrointest Oncol*. 2020;11(5):836-846.
- Lee EJ, Lee JB, Lee SH, et al. Endoscopic submucosal dissection for colorectal tumors—1,000 colorectal ESD cases: one specialized institute's experiences. *Surg Endosc*. 2013;27(1):31-39.
- Yamasaki Y, Uedo N, Ishihara R, Tomita Y. Endoscopic mucosal resection of early stage colon neuroendocrine carcinoma. *BMJ Case Rep*. 2015;2015:bcr2014208148.
- Murray SE, Lloyd RV, Sippel RS, Chen H. Clinicopathologic characteristics of colonic carcinoid tumors. *J Surg Res*. 2013;184(1):183-188.
- Bisogni D, Talamucci L, Rossi M, et al. Endoscopic full-thickness resection with the full-thickness resection device (FTRD) for "difficult to resect" colonic lesions. A single-center experience. *Ann Ital Chir*. 2020;91:486-493.
- Al-Bawardy B, Rajan E, Wong Kee Song LM. Over-the-scope clip-assisted endoscopic full-thickness resection of epithelial and subepithelial GI lesions. *Gastrointest Endosc*. 2017;85(5):1087-1092.
- Park CH, Cheon JH, Kim JO, et al. Criteria for decision making after endoscopic resection of well-differentiated rectal carcinoids with regard to potential lymphatic spread. *Endoscopy*. 2011;43(9):790-795.
- Inada Y, Yoshida N, Fukumoto K, et al. Risk of lymph node metastasis after endoscopic treatment for rectal NETs 10 mm or less. *Int J Colorectal Dis*. 2021;36(3):559-567.

31. Fine C, Roquin G, Terrebbonne E, et al. Endoscopic management of 345 small rectal neuroendocrine tumours: a national study from the French group of endocrine tumours (GTE). *United European Gastroenterol J*. 2019;7(8):1102-1112.
32. Gamboa AC, Liu Y, Lee RM, et al. A novel preoperative risk score to predict lymph node positivity for rectal neuroendocrine tumors: an NCDB analysis to guide operative technique. *J Surg Oncol*. 2019;120(6):932-939.
33. Ngamruengphong S, Kamal A, Akshintala V, et al. Prevalence of metastasis and survival of 788 patients with T1 rectal carcinoid tumors. *Gastrointest Endosc*. 2019;89(3):602-606.
34. Zhao B, Hollandsworth HM, Lopez NE, et al. Outcomes for a large cohort of patients with rectal neuroendocrine tumors: an analysis of the National Cancer Database. *J Gastrointest Surg*. 2021;25(2):484-491.
35. Soga J. Carcinoids of the rectum: an evaluation of 1271 reported cases. *Surg Today*. 1997;27(2):112-119.
36. Kang HS, Kwon MJ, Kim TH, Han J, Ju YS. Lymphovascular invasion as a prognostic value in small rectal neuroendocrine tumor treated by local excision: a systematic review and meta-analysis. *Pathol Res Pract*. 2019;215(11):152642.
37. Ricci AD, Pusceddu S, Panzuto F, et al. Assessment of the risk of nodal involvement in rectal neuroendocrine neoplasms: the NOVARA score, a multicentre retrospective study. *J Clin Med*. 2022;11(3):713. doi:10.3390/jcm11030713
38. Chida K, Watanabe J, Hirasawa K, et al. A novel risk-scoring system for predicting lymph node metastasis of rectal neuroendocrine tumors. *Ann Gastroenterol Surg*. 2020;4(5):562-570.
39. Ushigome H, Fukunaga Y, Nagasaki T, et al. Difficulty of predicting lymph node metastasis on CT in patients with rectal neuroendocrine tumors. *PLoS One*. 2019;14(2):e0211675.
40. Beets-Tan RGH, Lambregts DMJ, Maas M, et al. Magnetic resonance imaging for clinical management of rectal cancer: updated recommendations from the 2016 European Society of Gastrointestinal and Abdominal Radiology (ESGAR) consensus meeting. *Eur Radiol*. 2018;28(4):1465-1475.
41. Concors SJ, Sinnamon AJ, Folkert IW, et al. Predictors of metastases in rectal neuroendocrine tumors: results of a National Cohort Study. *Dis Colon Rectum*. 2018;61(12):1372-1379.
42. Hayoz R, Vietti-Violi N, Duran R, Knebel JF, Ledoux JB, Dromain C. The combination of hepatobiliary phase with Gd-EOB-DTPA and DWI is highly accurate for the detection and characterization of liver metastases from neuroendocrine tumor. *Eur Radiol*. 2020;30(12):6593-6602.
43. Bozkurt MF, Virgolini I, Balogova S, et al. Guideline for PET/CT imaging of neuroendocrine neoplasms with. *Eur J Nucl Med Mol Imaging*. 2017;44(9):1588-1601.
44. de Mestier L, Lorenzo D, Fine C, et al. Endoscopic, transanal, laparoscopic, and transabdominal management of rectal neuroendocrine tumors. *Best Pract Res Clin Endocrinol Metab*. 2019;33(5):101293.
45. Zhou X, Xie H, Xie L, Li J, Fu W. Factors associated with lymph node metastasis in radically resected rectal carcinoids: a systematic review and meta-analysis. *J Gastrointest Surg*. 2013;17(9):1689-1697.
46. Li YW, He YP, Liu FQ, et al. Grade G2 rectal neuroendocrine tumor is much more invasive compared with G1 tumor. *Front Oncol*. 2021;11:646536.
47. Kuiper T, van Oijen MGH, van Velthuysen MF, et al. Endoscopically removed rectal NETs: a nationwide cohort study. *Int J Colorectal Dis*. 2021;36(3):535-541.
48. O'Neill S, Haji A, Ryan S, et al. Nodal metastases in small rectal neuroendocrine tumours. *Colorectal Dis*. 2021;23(12):3173-3179.
49. Kim J, Kim JH, Lee JY, Chun J, Im JP, Kim JS. Clinical outcomes of endoscopic mucosal resection for rectal neuroendocrine tumor. *BMC Gastroenterol*. 2018;18(1):77.
50. Yang DH, Park Y, Park SH, et al. Cap-assisted EMR for rectal neuroendocrine tumors: comparisons with conventional EMR and endoscopic submucosal dissection (with videos). *Gastrointest Endosc*. 2016;83(5):1015-1022.
51. Yamashina T, Tumura T, Maruo T, et al. Underwater endoscopic mucosal resection: a new endoscopic method for resection of rectal neuroendocrine tumor grade 1 (carcinoid) ≤ 10 mm in diameter. *Endosc Int Open*. 2018;6(1):E111-E114.
52. Shi WK, Hou R, Li YH, et al. Long-term outcomes of transanal endoscopic microsurgery for the treatment of rectal neuroendocrine tumors. *BMC Surg*. 2022;22(1):43.
53. Zhang HP, Wu W, Yang S, Lin J. Endoscopic treatments for rectal neuroendocrine tumors smaller than 16 mm: a meta-analysis. *Scand J Gastroenterol*. 2016;51(11):1345-1353.
54. Pan J, Zhang X, Shi Y, Pei Q. Endoscopic mucosal resection with suction vs. endoscopic submucosal dissection for small rectal neuroendocrine tumors: a meta-analysis. *Scand J Gastroenterol*. 2018;53(9):1139-1145.
55. Meier B, Albrecht H, Wiedbrauck T, Schmidt A, Caca K. Full-thickness resection of neuroendocrine tumors in the rectum. *Endoscopy*. 2020;52(1):68-72.
56. Brand M, Reimer S, Reibetanz J, Flemming S, Kornmann M, Meining A. Endoscopic full thickness resection vs. transanal endoscopic microsurgery for local treatment of rectal neuroendocrine tumors—a retrospective analysis. *Int J Colorectal Dis*. 2021;36(5):971-976.
57. Fujii Y, Kobayashi K, Kimura S, Uehara S, Miyai H, Takiguchi S. Indications for lateral lymph node dissection in patients with rectal neuroendocrine tumors: a case report and review of the literature. *Mol Clin Oncol*. 2021;14(4):80.
58. Hayashi S, Takayama T, Ikarashi M, Hagiwara K, Matsuno Y, Suzuki T. Transanal minimally invasive surgery for rectal neuroendocrine tumors. *Surg Endosc*. 2021;35(12):6746-6753.
59. Nakamoto T, Koyama F, Nakagawa T, et al. Four resections of meta-chronous liver metastases and lateral lymph node metastases of a rectal carcinoid tumor—a case report. *Gan to Kagaku Ryoho*. 2014;41(12):1829-1831.
60. Choi CW, Park SB, Kang DH, et al. The clinical outcomes and risk factors associated with incomplete endoscopic resection of rectal carcinoid tumor. *Surg Endosc*. 2017;31(12):5006-5011.
61. Cha B, Shin J, Ko WJ, Kwon KS, Kim H. Prognosis of incompletely resected small rectal neuroendocrine tumor using endoscope without additional treatment. *BMC Gastroenterol*. 2022;22(1):293.
62. Singh S, Carnaghi C, Buzzoni R, et al. Everolimus in neuroendocrine tumors of the gastrointestinal tract and unknown primary. *Neuroendocrinology*. 2018;106(3):211-220.
63. Kulke MH, Lenz HJ, Meropol NJ, et al. Activity of sunitinib in patients with advanced neuroendocrine tumors. *J Clin Oncol*. 2008;26(20):3403-3410.
64. Phan AT, Halperin DM, Chan JA, et al. Pazopanib and depot octreotide in advanced, well-differentiated neuroendocrine tumours: a multicentre, single-group, phase 2 study. *Lancet Oncol*. 2015;16(6):695-703.
65. Grande E, Capdevila J, Castellano D, et al. Pazopanib in pretreated advanced neuroendocrine tumors: a phase II, open-label trial of the Spanish task force Group for Neuroendocrine Tumors (GETNE). *Ann Oncol*. 2015;26(9):1987-1993.
66. Capdevila J, Fazio N, Lopez C, et al. Lenvatinib in patients with advanced grade 1/2 pancreatic and gastrointestinal neuroendocrine tumors: results of the phase II TALENT trial (GETNE1509). *J Clin Oncol*. 2021;39(20):2304-2312.
67. Xu J, Li J, Bai C, et al. Surufatinib in advanced well-differentiated neuroendocrine tumors: a multicenter, single-arm, open-label. *Phase Ib/II Trial Clin Cancer Res*. 2019;25(12):3486-3494.

68. Strosberg JR, Cives M, Hwang J, et al. A phase II study of axitinib in advanced neuroendocrine tumors. *Endocr Relat Cancer*. 2016;23(5):411-418.
69. Xu J, Shen L, Zhou Z, et al. Surufatinib in advanced extrapancreatic neuroendocrine tumours (SANET-ep): a randomised, double-blind, placebo-controlled, phase 3 study. *Lancet Oncol*. 2020;21(11):1500-1512.
70. Moertel CG, Hanley JA. Combination chemotherapy trials in metastatic carcinoid tumor and the malignant carcinoid syndrome. *Cancer Clin Trials*. 1979;2(4):327-334.
71. Sun W, Lipsitz S, Catalano P, Mailliard JA, Haller DG, Group ECO. Phase II/III study of doxorubicin with fluorouracil compared with streptozocin with fluorouracil or dacarbazine in the treatment of advanced carcinoid tumors: eastern cooperative oncology group study E1281. *J Clin Oncol*. 2005;23(22):4897-4904.
72. Meyer T, Qian W, Caplin ME, et al. Capecitabine and streptozocin ± cisplatin in advanced gastroenteropancreatic neuroendocrine tumours. *Eur J Cancer*. 2014;50(5):902-911.
73. Espinosa-Olarte P, La Salvia A, Riesco-Martinez MC, Anton-Pascual B, Garcia-Carbonero R. Chemotherapy in NEN: still has a role? *Rev Endocr Metab Disord*. 2021;22(3):595-614.
74. Mityr E, Walter T, Baudin E, et al. Bevacizumab plus capecitabine in patients with progressive advanced well-differentiated neuroendocrine tumors of the gastro-intestinal (GI-NETs) tract (BETTER trial) – a phase II non-randomised trial. *Eur J Cancer*. 2014;50(18):3107-3115.
75. Girot P, Baudin E, Senellart H, et al. Oxaliplatin and 5-fluorouracil in advanced well-differentiated digestive neuroendocrine tumors: a multicenter National Retrospective Study from the French Group of Endocrine Tumors. *Neuroendocrinology*. 2022;112(6):537-546.
76. Merola E, Dal Buono A, Denecke T, et al. Efficacy and toxicity of 5-fluorouracil-oxaliplatin in Gastroenteropancreatic neuroendocrine neoplasms. *Pancreas*. 2020;49(7):912-917.
77. Lamarca A, Elliott E, Barriuso J, et al. Chemotherapy for advanced non-pancreatic well-differentiated neuroendocrine tumours of the gastrointestinal tract, a systematic review and meta-analysis: a lost cause? *Cancer Treat Rev*. 2016;44:26-41.
78. Strosberg JR, Caplin ME, Kunz PL, et al. Lu-Dotatate plus long-acting octreotide versus high-dose long-acting octreotide in patients with midgut neuroendocrine tumours (NETTER-1): final overall survival and long-term safety results from an open-label, randomised, controlled, phase 3 trial. *Lancet Oncol*. 2021;22(12):1752-1763.
79. Zhang J, Kulkarni HR, Singh A, Niepsch K, Müller D, Baum RP. Peptide receptor radionuclide therapy in grade 3 neuroendocrine neoplasms: safety and survival analysis in 69 patients. *J Nucl Med*. 2019;60(3):377-385.
80. Rudisile S, Gosewisch A, Wenter V, et al. Salvage PRRT with. *BMC Cancer*. 2019;19(1):788.
81. Zhang J, Kulkarni HR, Singh A, Baum RP. Twelve-year survival of a patient with lymph node, pulmonary, bone, cardiac and intraspinal metastases of a rectal neuroendocrine neoplasm treated with peptide receptor radionuclide therapy-the value of salvage peptide receptor radionuclide therapy. *Clin Nucl Med*. 2020;45(4):e198-e200.
82. Ryan J, Akhurst T, Lynch AC, Michael M, Heriot AG. Neoadjuvant. *ANZ J Surg*. 2017;87(1-2):92-93.
83. Abdülrezzak Ü, Kula M, Tutuş A, Buyukkaya F, Karaca H. PET/CT and bremsstrahlung imaging after 90Y DOTANOC therapy for rectal net with liver metastases. *Clin Nucl Med*. 2015;40(10):799-801.
84. Kong G, Grozinsky-Glasberg S, Hofman MS, et al. Highly favourable outcomes with peptide receptor radionuclide therapy (PRRT) for metastatic rectal neuroendocrine neoplasia (NEN). *Eur J Nucl Med Mol Imaging*. 2019;46(3):718-727.
85. Lania A, Ferrau F, Rubino M, Modica R, Colao A, Faggiano A. Neoadjuvant therapy for neuroendocrine neoplasms: recent progresses and future approaches. *Front Endocrinol (Lausanne)*. 2021;12:651438.
86. Yong JN, Lim XC, Nistala KRY, et al. Endoscopic submucosal dissection versus endoscopic mucosal resection for rectal carcinoid tumor. A meta-analysis and meta-regression with single-arm analysis. *J Dig Dis*. 2021;22(10):562-571.
87. Knigge U, Capdevila J, Bartsch DK, et al. ENETS consensus recommendations for the standards of care in neuroendocrine neoplasms: follow-up and documentation. *Neuroendocrinology*. 2017;105(3):310-319.

How to cite this article: Rinke A, Ambrosini V, Dromain C, et al. European Neuroendocrine Tumor Society (ENETS) 2023 guidance paper for colorectal neuroendocrine tumours. *J Neuroendocrinol*. 2023;35(6):e13309. doi:10.1111/jne.13309