



Since January 2020 Elsevier has created a COVID-19 resource centre with free information in English and Mandarin on the novel coronavirus COVID-19. The COVID-19 resource centre is hosted on Elsevier Connect, the company's public news and information website.

Elsevier hereby grants permission to make all its COVID-19-related research that is available on the COVID-19 resource centre - including this research content - immediately available in PubMed Central and other publicly funded repositories, such as the WHO COVID database with rights for unrestricted research re-use and analyses in any form or by any means with acknowledgement of the original source. These permissions are granted for free by Elsevier for as long as the COVID-19 resource centre remains active.



From Your Nose to Your Toes: A Review of Severe Acute Respiratory Syndrome Coronavirus 2 Pandemic–Associated Pernio

Lisa M. Arkin¹, John J. Moon¹, Jennifer M. Tran¹, Samira Asgari², Cliona O'Farrelly³, Jean-Laurent Casanova^{4,5}, Edward W. Cowen⁶, Jacqueline W. Mays⁷, Anne Marie Singh⁸ and Beth A. Drolet¹, on behalf of the COVID Human Genetic Effort⁹

Despite thousands of reported patients with pandemic-associated pernio, low rates of seroconversion and PCR positivity have defied causative linkage to severe acute respiratory syndrome coronavirus 2 (SARS-CoV-2). Pernio in uninfected children is associated with monogenic disorders of excessive IFN-1 immunity, whereas severe COVID-19 pneumonia can result from insufficient IFN-1. Moreover, SARS-CoV-2 spike protein and robust IFN-1 response are seen in the skin of patients with pandemic-associated pernio, suggesting an excessive innate immune skin response to SARS-CoV-2. Understanding the pathophysiology of this phenomenon may elucidate the host mechanisms that drive a resilient immune response to SARS-CoV-2 and could produce relevant therapeutic targets.

Journal of Investigative Dermatology (2021) **141**, 2791–2796; doi:10.1016/j.jid.2021.05.024

INTRODUCTION

In March 2020, just weeks after the onset of community spread of COVID-19 in Italy, reports of pandemic-associated pernio emerged. Shortly thereafter, dermatologists in the

United States were inundated with pernio referrals as the first surge of COVID-19 arrived in the United States (Bouaziz et al., 2020; Cordoro et al., 2020; Duong et al., 2020; Galván Casas et al., 2020; Landa et al., 2020; López-Robles et al., 2020; Piccolo et al., 2020). The phenotype of cool extremities with pain/swelling followed by red–violaceous discoloration and finally vesiculation of the toes and fingers were strikingly consistent (Figure 1a). Whereas older age was an important risk factor for severe infection, most patients with pernio were young, with a median age of 25 years in an international dermatology registry (Castelo-Soccio et al., 2021; Freeman et al., 2020). Many had close contact with severe acute respiratory syndrome coronavirus 2 (SARS-CoV-2) infected individuals; yet, nearly all were otherwise healthy and denied typical respiratory manifestations of COVID-19 (Castelo-Soccio et al., 2021; Freeman et al., 2020). The spatial and temporal association between pernio and the COVID-19 pandemic has now been independently observed across multiple countries, including Italy, Spain, Germany, the United Kingdom, France, and the United States.

The strength of this spatial and temporal association along with its consistency across multiple countries supports a SARS-CoV-2–triggered phenomenon. Yet, low rates of positive PCR testing of nasopharyngeal samples (0–20%) and antibody positivity (0–55%) across 175 publications and thousands of reported patients have led some authors to suggest that this is an epiphenomenon (Baeck and Herman, 2021; Galván Casas et al., 2020). This review will summarize and integrate the growing evidence for a causal relationship with SARS-CoV-2 and construct a mechanistic hypothesis. Pandemic-associated pernio augments the knowledge regarding the spectrum of SARS-CoV-2 infection and reinforces the critical importance of IFN-1 signaling in disease outcomes. A robust IFN-1 response in patients who remain asymptomatic and antibody negative could suggest a population with intrinsic resistance to severe COVID-19. Because the host immune response to SARS-CoV-2 infection is a critical determinant for COVID-19 outcomes, understanding those with natural resiliency to SARS-CoV-2 exposure could produce clinically relevant therapeutic targets.

INBORN ERRORS OF IFN-1 AND LIFE-THREATENING INFECTION

IFN-1 responses are tightly regulated to ensure protective immunity while avoiding toxicity from excessive and prolonged IFN signaling. They are largely produced in the blood by plasmacytoid dendritic cells (pDCs) in response to viral

¹Department of Dermatology, School of Medicine and Public Health, University of Wisconsin-Madison, Madison, Wisconsin, USA; ²Division of Genetics, Department of Medicine, Brigham and Women's Hospital, Boston, Massachusetts, USA; ³Comparative Immunology, School of Biochemistry and Immunology, Trinity College Dublin, Dublin, Ireland; ⁴St. Giles Laboratory of Human Genetics of Infectious Diseases, The Rockefeller University, New York, New York, USA; ⁵Howard Hughes Medical Institute, The Rockefeller University, New York, New York, USA; ⁶Dermatology branch, National Institute of Arthritis and Musculoskeletal and Skin Diseases, National Institute of Health, Bethesda, Maryland, USA; ⁷Oral Immunobiology Unit, National Institute of Dental and Craniofacial Research, National Institutes of Health, Bethesda, Maryland, USA; and ⁸Department of Pediatrics, School of Medicine and Public Health, University of Wisconsin-Madison, Madison, Wisconsin, USA

⁹See Acknowledgments for complete list of COVID Human Genetic Effort contributors.

Correspondence: Beth A. Drolet, Department of Dermatology, School of Medicine and Public Health, University of Wisconsin-Madison, 1 South Park Clinic, Madison, Wisconsin 53715, USA. E-mail: bdrolet@dermatology.wisc.edu

Abbreviations: ACE2, angiotensin-converting enzyme 2; HCV, hepatitis C virus; pDC, plasmacytoid dendritic cell; RAS, renin-angiotensin system; SARS-CoV-2, severe acute respiratory syndrome coronavirus 2

Received 15 April 2021; revised 17 May 2021; accepted 18 May 2021; accepted manuscript published online 15 July 2021; corrected proof published online 22 September 2021

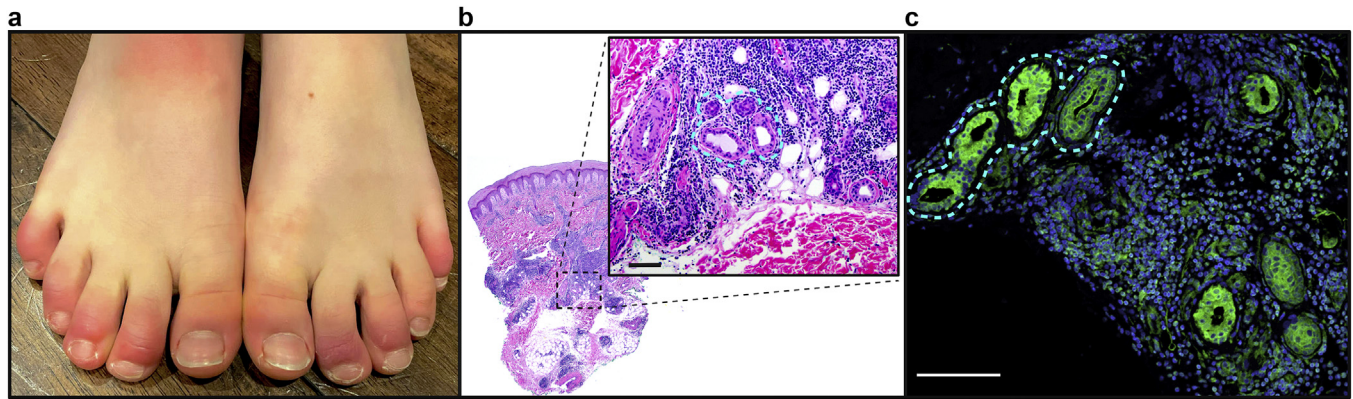


Figure 1. Pandemic-associated pernio presentation and histopathology. (a) Representative clinical photographs of COVID toes, with red–violet discoloration and swelling on multiple distal digits bilaterally. (b, c) Representative histopathologic section of a patient’s punch biopsy specimen (H&E); (b) demonstrating dense perivascular and periadnexal inflammatory infiltrate; (inset) magnification demonstrating tight inflammation around eccrine structures (outlined). Bar = 100 μ m. (c) Staining of eccrine structures (outlined) for ACE2 (green) and nuclei (blue). Bar = 100 μ m. ACE2, angiotensin-converting enzyme 2.

infection through the activation of toll-like receptors 3, 7, and 9; RIG-I; and MDA5. IFN-1 is produced in lower amounts by >400 discernable cell types (intrinsic immunity). On binding to IFN-1 receptor, the IFN-1 (13 IFN- α , IFN- β , IFN- ϵ , IFN- κ , IFN- ω) activates robust antiviral defense programs of INF-stimulated genes, which obstruct various steps of viral replication. Monogenic variants that impair key IFN-1–related genes are associated with life-threatening infections due to influenza pneumonia, respiratory syncytial virus, rhinovirus, and herpes encephalitis (Asgari et al., 2017; Ciancanelli et al., 2015; Lamborn et al., 2017; Zhang et al., 2007).

IFN-1 SIGNALING IS CRITICAL IN COVID-19 OUTCOMES

Recent investigations of host-specific responses to SARS-CoV-2 have confirmed the central role of IFN-1 signaling in COVID-19 outcomes. An attenuated IFN-1 response was found in critically ill patients with SARS-CoV-1 (Channappanavar et al., 2016). In an international cohort, our team found that 3% of patients with life-threatening COVID-19 harbor loss-of-function variants involved in IFN-1 signaling, with pDCs that did not produce IFN-1 in response to SARS-CoV-2 (Zhang et al., 2020). An accompanying study found that 10% of patients with critical COVID-19 infection had circulating neutralizing autoantibodies against IFN-1. These autoantibodies were pre-existing and were a cause of severe disease rather than a consequence of infection. Remarkably, 94% of these patients were men, half of whom were aged >65 years, and more than a third died from COVID-19 (Bastard et al., 2020).

EXCEPTIONAL INNATE IMMUNITY MAY PROVIDE RESISTANCE TO VIRAL INFECTION WITHOUT ENGAGING THE ADAPTIVE IMMUNE SYSTEM

In theory, robust innate and intrinsic immune responses may be sufficient to clear a viral exposure without triggering antibody production. This is a difficult phenomenon to study because most patients with viral clearance are identified by their postinfectious seroconversion. However, potential resistance to hepatitis C virus (HCV) infection has been described in high-risk injection drug users who lack HCV-specific T-cell responses and seroconversion despite a long

history of HCV exposure, suggesting that individuals may be resistant to viral infection or protected from viral replication by an exceptional innate antiviral response without seroconversion (Shawa et al., 2017). The pandemic provides an opportunity to investigate antiviral resistance through the study of close contacts of patients with critical COVID-19 who remain asymptomatic and seronegative. Patients with pandemic-associated pernio may also serve as a model for a mild or resistant SARS-CoV-2 phenotype and are readily identifiable by their skin findings.

ASSOCIATION OF PERNIO/CHILBLAINS WITH MONOGENIC DISORDERS OF CONSTITUTIVELY ACTIVE IFN-1 PRODUCTION

Both clinically and histologically, pandemic-associated pernio mimics the skin lesions of familial chilblain lupus and Aicardi–Goutières syndrome, which are characterized by IFN-1 excess. These monogenic disorders, referred to as type 1 interferonopathies, are caused by mutations associated with impaired nucleic acid sensing that lead to sustained and upregulated IFN-1 signaling (Rice et al., 2007; Ugenti et al., 2019; Zimmermann et al., 2019). In affected patients, pernio develops in early infancy, followed by systemic vasculopathy due to autoinflammation. IFN-1 is profoundly increased in affected skin and blood. Similar to pandemic-associated pernio, cold is a critical precipitant. In familial chilblain lupus, 5-day cold exposure of primary fibroblasts followed by rewarming enhanced ROS, a known trigger of DNA damage, and increased IFN-1 activation, switching cells from a quiescent to a proinflammatory state (Günther et al., 2015).

INVESTIGATION OF COVID TOES IDENTIFIES SPIKE PROTEIN

COVID-19 autopsy studies have shown a SARS-CoV-2 tropism for the skin. Angiotensin-converting enzyme 2 (ACE2), the SARS-CoV-2 receptor, is expressed on dermal blood vessels, the basal layer of the epidermis, and unexpectedly on eccrine glands (Hamming et al., 2004) (Figure 1b). We hypothesize that this expression may explain the localization of inflammation to hands and feet because these sites harbor the highest concentration of eccrine glands.

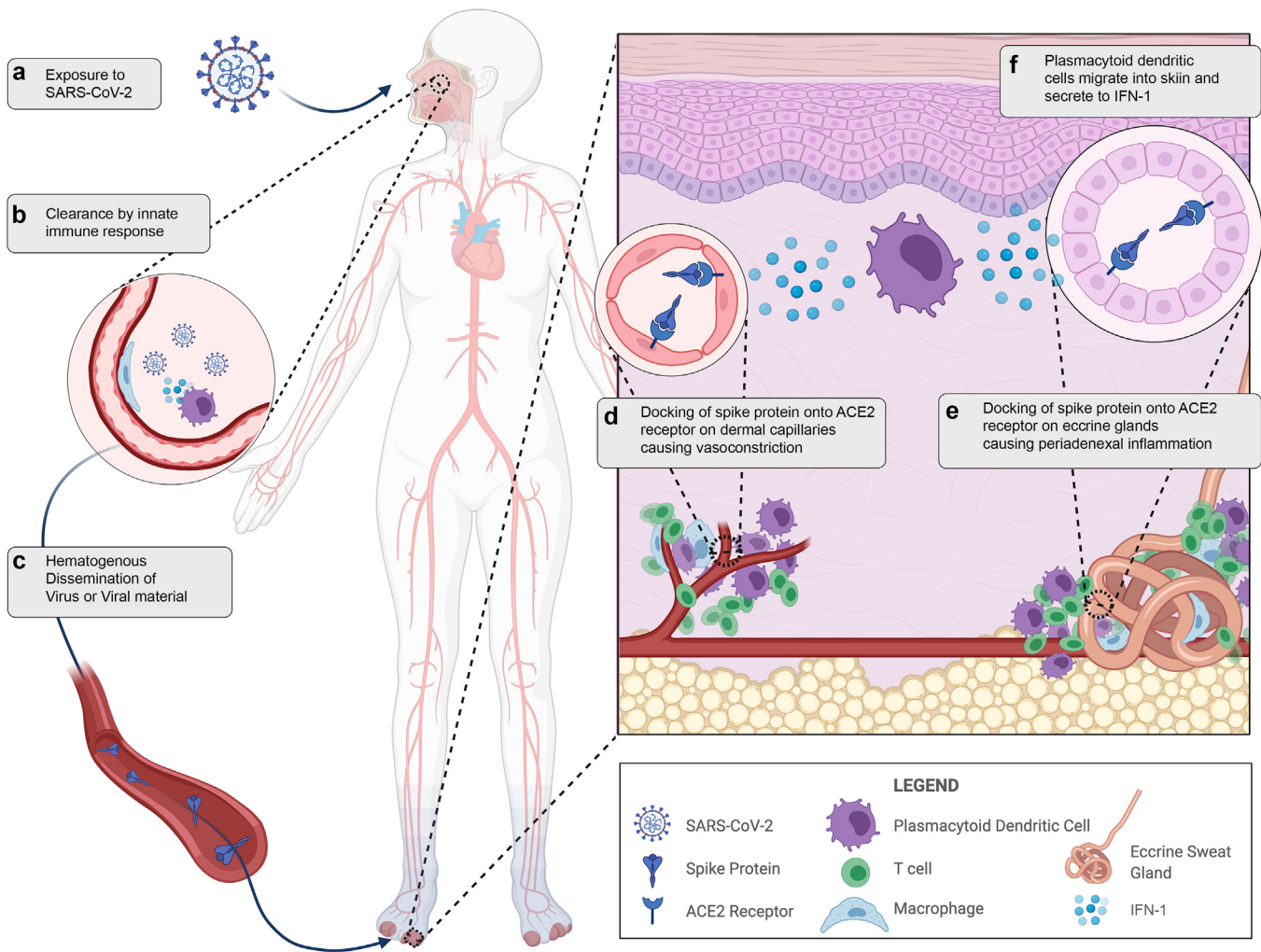


Figure 2. Illustrated hypothesis of pandemic-associated pernio pathophysiology. (a) Viral exposure to SARS-CoV-2 in the environment. (b) SARS-CoV-2 is cleared by a robust innate immune response in the nasopharynx. (c) There is hematogenous showering and dissemination of viral material or virus. (d) Docking of spike protein to the ACE2 receptor on dermal capillaries results in vasoconstriction and perivascular inflammation. (e) Docking of spike protein to ACE2 receptors on eccrine glands results in periadnexal inflammation. (f) Plasmacytoid dendritic cells, the major contributor to IFN-1 response, migrate to the skin in response to viral material. ACE2, angiotensin-converting enzyme 2; SARS-CoV-2, severe acute respiratory syndrome coronavirus 2.

This is further supported by the recent demonstration of SARS-CoV-2–associated spike protein in cutaneous vascular endothelium and eccrine glands in biopsies from patients with COVID toes (Colmenero et al., 2020; Ko et al., 2021; Magro et al., 2021; Moon et al., 2021; Santonja et al., 2020). It should be noted that not all biopsy specimens detected spike protein, which could reflect the timing and depth of skin biopsy. Importantly, nucleocapsid antibody staining has been negative.

The immunohistochemistry patterns in published studies, coupled with lack of detection of viral RNA by in situ hybridization or PCR from tissue, suggests that pandemic-associated pernio may result from hematogenous spread of viral material and may not require viral replication in the skin (Herman et al., 2020; Ko et al., 2021). Emerging reports of pernio after mRNA vaccination also raise speculation that this could be an immune response to viral proteins or RNA without viral replication (Davido et al., 2021; McMahon et al., 2021). In unaffected skin of patients with critical COVID-19 infection, Magro et al. (2020) found

microvascular complement deposition (an end-terminal event driving thrombosis) strongly colocalized with spike protein and the ACE2 receptor but without in situ evidence of viral RNA. The colocalization of the ACE2 receptor and viral capsid proteins suggests that circulating viral debris may dock onto the endothelium/eccrine ducts. This would be consistent with the hypothesis that patients with pandemic-associated pernio clear the SARS-CoV-2 through a robust IFN-1 response but shower viral debris that binds ACE2 receptors in the skin. Finally, the renin-angiotensin system (RAS) is expressed locally in the skin and may be indirectly activated by ACE2 binding from SARS-CoV-2 (Moon et al., 2021; Silva et al., 2020; Steckelings et al., 2004). We hypothesize that persistent vasoconstriction, poor capillary refill, and the chronicity of the response in some patients could also be linked to local cutaneous RAS activation (Figure 2).

EVIDENCE OF ROBUST IFN-1 RESPONSE IN COVID TOES

Pandemic-associated pernio exhibits a lymphocytic infiltrate in a perivascular and perieccrine distribution (Figure 1b),

which is composed predominantly of lymphocytes and pDCs. pDCs are responsible for the initiation of IFN-1 signaling in response to recognition of viral RNA. Immunohistochemistry studies have revealed robust MxA staining (a downstream product of IFN-1 activation) in affected specimens in a perivascular and perieccrine distribution (Aschoff et al., 2020). A recent paper suggested a viral-induced interferonopathy in affected patients, demonstrating a significant increase of in vitro IFN- α production after stimulation compared with that in patients with mild or severe acute COVID-19 infection (Hubiche et al., 2021).

COLD FEET: AMBIENT TEMPERATURE AFFECTS VIRUS-HOST RESPONSES

A cold environment is crucial to the induction of COVID toes. Humans maintain a narrow range of core body temperatures through neural, vascular, and biochemical mechanisms. Increases in body temperature through fever enhance immune function and pathogen killing. Colder ambient temperatures are known to diminish the efficiency of the innate immune response, facilitating viral replication in other infections (Foxman et al., 2015). Indeed, in vitro SARS-CoV-2 replication significantly increases with colder temperatures, demonstrating 10-fold higher infectious titers when incubated at 33 °C versus incubating at 37 °C (V'kovski et al., 2021). Importantly, attenuated IFN-1 expression is responsible for the increased viral replication efficiency at 33 °C. In pandemic-associated pernio, one could hypothesize that after clearance from the warmer respiratory tract, dispersed viral material settles at these colder acral sites owing to skin tropism through ACE2 expression, evading immune clearance. With rewarming of the toes, a local IFN-1 response could be initiated by pDCs after migration into the skin.

CONCLUSIONS

The striking spatial and temporal association with the pandemic, the accumulating evidence of both viral material and MxA in the affected skin, and the biologic plausibility of pernio linked to the critical role of IFN-1 signaling in COVID-19 all suggest a causal linkage with SARS-CoV-2. This evidence implicates a robust IFN-1 response in affected patients. The absence of antibody production supports rather than undermines this hypothesis because an exceptional innate and intrinsic immune activity may be enough to clear the viral infection without seroconversion. These findings further intimate IFN-1 signaling in host outcomes to COVID-19.

In cooperation with the National Institutes of Health-funded Human Genome Effort and the International COVID Human Genomic Effort, the COVID toes biobank at the University of Wisconsin-Madison seeks to identify the genetic and immunologic basis to provide clinically relevant insights into SARS-CoV-2-associated pernio and could provide a framework for considering preventative approaches to SARS-CoV-2 infection utilizing early administration of IFNs.

ORCIDs

Lisa M. Arkin: <http://orcid.org/0000-0002-0468-9568>

John J. Moon: <http://orcid.org/0000-0003-2422-8424>

Jennifer M. Tran: <http://orcid.org/0000-0003-1505-8099>

Samira Asgari: <http://orcid.org/0000-0002-2347-8985>

Cliona O'Farrelly: <http://orcid.org/0000-0002-0616-2874>

Jean-Laurent Casanova: <http://orcid.org/0000-0002-7782-4169>

Edward W. Cowen: <http://orcid.org/0000-0003-1918-4324>

Jacqueline W. Mays: <http://orcid.org/0000-0002-4472-9974>

Beth A. Drolet: <http://orcid.org/0000-0002-0844-7195>

CONFLICT OF INTEREST

The Authors have no conflict of interest.

ACKNOWLEDGMENTS

This research was supported in part by the Intramural Research Program of the National Institute of Dental and Craniofacial Research (NIDCR) and the National Institute of Arthritis and Musculoskeletal and Skin Diseases of the National Institutes of Health (NIH). In addition, research at the University of Wisconsin-Madison is supported through a Wisconsin Partnership Program COVID-19 Response Grant. Figure 1c was contributed by Ana Costa da Silva and Clara H. Kim from the JW Mays Lab, NIDCR, NIH with support from the NIDCR Imaging Core: ZIC DE000750. Figure 2 was created with BioRender.com. This review was conducted in Madison, WI. The other authors (COVID Human Genetic Effort) contributed to conceptualization of the review and to the writing (review and editing). The full list of authors (COVID Human Genetic Effort) and their affiliations are given as follows:

Alessandro Aiuti^{1,2}, Alexandre Belot³, Alexandre Bolze⁴, Anastasiia Bondarenko⁵, Anna Sediva⁶, Anna Shcherbina⁷, Anna M. Planas⁸, Antonio Condino-Neto⁹, Aurora Pujol^{10,11,12}, Beth A. Drolet¹³, Biggs Catherine¹⁴, Carlos Flores^{15,16,17,18}, Carlos Rodríguez-Gallego^{19,20}, Carolina Prando²¹, Clifton L. Dalgard²², Cliona O'Farrelly²³, Colobran Roger²⁴, Davoud Mansouri²⁵, Diederik van de Beek²⁶, Donald C. Vinh^{27,28}, Elena Hsieh^{29,30}, Evangelos Andreaskos³¹, Filomeen Haerynck³², Furkan Uddin^{33,34,35}, Giorgio Casari³⁶, Giuseppe Novelli³⁷, Graziano Pesole^{38,39}, Isabelle Meyts^{40,41}, Ivan Tancevski⁴², Jacques Fellay^{43,44}, Jean-Laurent Casanova⁴⁵, Jordi Tur⁴⁶, Kai Kisand⁴⁷, Keisuke Okamoto^{48,49}, Kristina Mironska⁵⁰, Laurent Abel⁵¹, Laurent Renia⁵², Lisa F.P. Ng^{53,54}, Mohammed Shahrooei^{54,55}, Pere Soler-Palacín⁵⁶, Petter Brodin⁵⁷, Qiang Pan-Hammarström⁵⁸, Rabih Halwani⁵⁹, Rebeca Perez de Diego⁶⁰, Saleh Al-Muhsen⁶¹, Sara Espinosa-Padilla⁶², Satoshi Okada⁶³, Tayfun Ozcelik⁶⁴, Tayoun Ahmad Abou⁶⁵, Timokrats Karamitros⁶⁶, Trine H. Mogensen^{67,68} and Yu-Lung Lau⁶⁹

¹San Raffaele Telethon Institute for Gene Therapy, IRCCS Ospedale San Raffaele, Milan, Italy; ²Vita Salute San Raffaele University, Milan, Italy; ³Pediatric Nephrology, Rheumatology, Dermatology, HFME, Hospices Civils de Lyon, National Referee Centre RAISE, & INSERM U1111, Université de Lyon, Lyon, France; ⁴Helix, San Mateo, California, USA; ⁵Department of Pediatric Infectious Diseases and Pediatric Immunology, Shupyk National Medical Academy for Postgraduate Education, Kiev, Ukraine; ⁶Department of Immunology, Second Faculty of Medicine, Charles University, University Hospital in Motol, Prague, Czech Republic; ⁷Department of Immunology, Dmitry Rogachev National Medical Research Center of Pediatric Hematology, Oncology and Immunology, Moscow, Russia; ⁸Department of Brain Ischemia and Neurodegeneration, IIBB-CSIC, IDIBAPS, Barcelona, Spain; ⁹Department of Immunology, Institute of Biomedical Sciences, University of São Paulo, São Paulo, Brazil; ¹⁰Neurometabolic Diseases Laboratory, Bellvitge Biomedical Research Institute (IDIBELL), L'Hospitalet de Llobregat, Barcelona, Spain; ¹¹Catalan Institution for Research and Advanced Studies (ICREA), Barcelona, Spain; ¹²Center for Biomedical Research on Rare Diseases (CIBERER), ISCIII, Madrid, Spain; ¹³School of Medicine and Public Health, University of Wisconsin, Madison, Wisconsin, USA; ¹⁴Division of Allergy and Immunology, Faculty of Medicine, The University of British Columbia, Vancouver, British Columbia, Canada; ¹⁵Genomics Division, Instituto Tecnológico y de Energías Renovables (ITER), Santa Cruz de Tenerife, Spain; ¹⁶Research Unit, Hospital Universitario Ntra. Sra. de Candelaria, Santa Cruz de Tenerife, Spain; ¹⁷Instituto de Tecnologías Biomédicas (ITB), Universidad de La Laguna, Santa Cruz de Tenerife, Spain; ¹⁸CIBER de Enfermedades Respiratorias, Instituto de Salud Carlos III, Madrid, Spain; ¹⁹Department of Immunology, Hospital Universitario de Gran Canaria Dr Negrín, Canarian Health System, Las Palmas de Gran Canaria, Spain; ²⁰Department of Clinical Sciences, University Fernando Pessoa Canarias, Las Palmas de Gran Canaria, Spain; ²¹Faculdades Pequeno Príncipe, Instituto de Pesquisa Pelé Pequeno Príncipe, Curitiba, Brazil; ²²Department of Anatomy, Physiology & Genetics, F. Edward Hebert School of Medicine, Uniformed Services University of the Health Sciences, Bethesda, Maryland, USA; ²³Comparative Immunology Group, School of Biochemistry and Immunology, Trinity Biomedical Sciences Institute, Trinity College Dublin, The University of Dublin, Dublin, Ireland ²⁴Immunology Division, Genetics Department, Hospital Universitari Vall d'Hebron, Vall d'Hebron Research

- Institute, Vall d'Hebron Barcelona Hospital Campus, Universitat Autònoma de Barcelona (UAB), Barcelona, Spain;²⁵Department of Clinical Immunology and Infectious Diseases, The Clinical Tuberculosis and Epidemiology Research Center, National Research Institute of Tuberculosis and Lung Diseases (NRITLD), Masih Daneshvari Hospital, Shahid Beheshti University of Medical Sciences, Tehran, Iran;²⁶Department of Neurology, Amsterdam Neuroscience, Amsterdam UMC, University of Amsterdam, Amsterdam, Netherlands;²⁷Division of Infectious Diseases, Department of Medicine, Faculty of Medicine and Health Sciences, McGill University Health Centre, Montréal, Québec, Canada;²⁸Infectious Disease Susceptibility Program, Research Institute, McGill University Health Centre, Montréal, Québec, Canada;²⁹Department of Immunology and Microbiology, School of Medicine, University of Colorado Anschutz Medical Campus, Aurora, Colorado, USA;³⁰Division of Allergy and Immunology, Department of Pediatrics, School of Medicine, Children's Hospital Colorado, University of Colorado Anschutz Medical Campus, Aurora, Colorado, USA;³¹Laboratory of Immunobiology, Center for Clinical, Experimental Surgery & Translational Research, Biomedical Research Foundation of the Academy of Athens, Athens, Greece;³²Department of Paediatric Immunology and Pulmonology, Centre for Primary Immunodeficiency Ghent (CPiG), PID Research Laboratory, Jeffrey Modell Diagnosis and Research Centre, Ghent University Hospital, Edegem, Belgium;³³Holy Family Red Crescent Medical College, Dhaka, Bangladesh;³⁴Centre for Precision Therapeutics, NeuroGen Children's Healthcare, Dhaka, Bangladesh;³⁵Genetics and Genomic Medicine Centre, NeuroGen Children's Healthcare, Dhaka, Bangladesh;³⁶Medical Genetics, IRCCS Ospedale San Raffaele, Milan, Italy;³⁷Department of Biomedicine and Prevention, School of Medicine and Surgery, Tor Vergata University of Rome, Rome, Italy;³⁸Institute of Biomembranes, Bioenergetics and Molecular Biotechnologies, Consiglio Nazionale delle Ricerche, Bari, Italy;³⁹Department of Biosciences, Biotechnology and Biopharmaceutics, University of Bari Aldo Moro, Bari, Italy;⁴⁰Department of Pediatrics, University Hospitals Leuven, Leuven, Belgium;⁴¹Laboratory for Inborn Errors of Immunity, Department of Microbiology, Immunology and Transplantation, KU Leuven, Leuven, Belgium;⁴²Department of Internal Medicine II, Medical University of Innsbruck, Innsbruck, Austria;⁴³School of Life Sciences, Ecole Polytechnique Fédérale de Lausanne, Lausanne, Switzerland;⁴⁴Precision Medicine Unit, Lausanne University Hospital, University of Lausanne, Lausanne, Switzerland;⁴⁵The Rockefeller University, Howard Hughes Medical Institute, Necker Hospital, New York, New York, USA;⁴⁶Institut de Biomedicina de Valencia CSIC, Valencia, Spain;⁴⁷Molecular Pathology, Department of Biomedicine, Institute of Biomedicine and Translational Medicine, University of Tartu, Tartu, Estonia;⁴⁸Laboratory of Clinical Pharmacology & Therapeutics, Division of Pharmasciences, Faculty of Pharmaceutical Sciences, Hokkaido University, Sapporo, Japan;⁴⁹Department of Pediatrics and Developmental Biology, Graduate School of Medical and Dental Sciences, Tokyo Medical and Dental University, Tokyo, Japan;⁵⁰Department of Pediatric Immunology, Medical Faculty, University Clinic for Children's Diseases, University "St. Cyril and Methodij" Skopje, Skopje, North Macedonia;⁵¹INSERM U1163, Imagine Institute, University of Paris, Paris, France;⁵²A*STAR Infectious Diseases Labs (ID labs), Agency for Science, Technology and Research (A*STAR), Singapore, Singapore;⁵³Singapore Immunology Network (SigN), Agency for Science, Technology and Research (A*STAR), Singapore, Singapore;⁵⁴Saeed Pathobiology and Genetics Lab, Tehran, Iran;⁵⁵Clinical and Diagnostic Immunology, Immunogenetics Research Group, Department of Microbiology and Immunology, KU Leuven, Leuven, Belgium;⁵⁶Pediatric Infectious Diseases and Immunodeficiencies Unit, Vall d'Hebron Barcelona Hospital Campus, Barcelona, Spain;⁵⁷Science for Life Laboratory (SciLifeLab), Department of Women's and Children's Health, Karolinska Institutet, Stockholm, Sweden;⁵⁸Department of Biosciences and Nutrition, Karolinska Institutet, Stockholm, Sweden;⁵⁹Sharjah Institute of Medical Research, College of Medicine, University of Sharjah, Sharjah, United Arab Emirates;⁶⁰Innate Immunity Group, Laboratory of Immunogenetics of Human Diseases, IdiPAZ Institute for Health Research, La Paz Hospital, Madrid, Spain;⁶¹Immunology Research Laboratory, Department of Pediatrics, College of Medicine, King Saud University Medical City, King Saud University, Riyadh, Saudi Arabia;⁶²Instituto Nacional de Pediatría (National Institute of Pediatrics), Mexico City, Mexico;⁶³Department of Pediatrics, Graduate School of Biomedical and Health Sciences, Hiroshima University, Hiroshima, Japan;⁶⁴Department of Molecular Biology and Genetics, Bilkent University, Ankara, Turkey;⁶⁵Al Jalila Children's Genomics Centre, Al Jalila Children's Specialty Hospital, Dubai, United Arab Emirates;⁶⁶Bioinformatics and Applied Genomics Unit, Department of Microbiology, Hellenic Pasteur Institute, Athens, Greece;⁶⁷Department of Biomedicine, Aarhus University, Aarhus, Denmark;⁶⁸Department of Infectious Diseases, Aarhus University Hospital, Aarhus, Denmark;⁶⁹Department of Paediatrics & Adolescent Medicine, Li Ka Shing Faculty of Medicine, The University of Hong Kong, Hong Kong, China
- ## AUTHOR CONTRIBUTIONS
- Conceptualization: BAD, COF, JLC, JJM, JWM, LMA; Project Administration: JJM; Supervision: BAD; Visualization: JJM, JWM; Writing - Original Draft Preparation: BAD, COF, JLC, JJM, LMA; Writing - Review and Editing: AMS, EWC, JWM, JMT, SA
- ## REFERENCES
- Aschoff R, Zimmermann N, Beissert S, Günther C. Type I interferon signature in chilblain-like lesions associated with the COVID-19 pandemic. *Dermatopathology* (Basel) 2020;7:57–63.
- Asgari S, Schlapbach LJ, Anchisi S, Hammer C, Bartha I, Junier T, et al. Severe viral respiratory infections in children with *IFIH1* loss-of-function mutations. *Proc Natl Acad Sci USA* 2017;114:8342–7.
- Baeck M, Herman A. COVID toes: where do we stand with the current evidence? *Int J Infect Dis* 2021;102:53–5.
- Bastard P, Rosen LB, Zhang Q, Michailidis E, Hoffmann HH, Zhang Y, et al. Autoantibodies against type I IFNs in patients with life-threatening COVID-19. *Science* 2020;370:eabd4585.
- Bouaziz JD, Duong TA, Jachiet M, Velter C, Lestang P, Cassius C, et al. Vascular skin symptoms in COVID-19: a French observational study. *J Eur Acad Dermatol Venereol* 2020;34:e451–2.
- Castelo-Socorro L, Lara-Corrales I, Paller AS, Bean E, Rangu S, Oboite M, et al. Acral changes in pediatric patients during COVID 19 pandemic: registry report from the COVID 19 response task force of the society of pediatric dermatology (SPD) and pediatric dermatology research alliance (PeDRA). *Pediatr Dermatol* 2021;38:364–70.
- Channappanavar R, Fehr AR, Vijay R, Mack M, Zhao J, Meyerholz DK, et al. Dysregulated type I interferon and inflammatory monocyte-macrophage responses cause lethal pneumonia in SARS-CoV-infected mice. *Cell Host Microbe* 2016;19:181–93.
- Ciancanelli MJ, Huang SX, Luthra P, Garner H, Itan Y, Volpi S, et al. Infectious disease. Life-threatening influenza and impaired interferon amplification in human IRF7 deficiency. *Science* 2015;348:448–53.
- Colmenero I, Santonja C, Alonso-Riaño M, Noguera-Morel L, Hernández-Martín A, Andina D, et al. SARS-CoV-2 endothelial infection causes COVID-19 chilblains: histopathological, immunohistochemical and ultrastructural study of seven paediatric cases. *Br J Dermatol* 2020;183:729–37.
- Cordoro KM, Reynolds SD, Wattier R, McCalmont TH. Clustered cases of acral pernio: clinical features, histopathology, and relationship to COVID-19. *Pediatr Dermatol* 2020;37:419–23.
- David B, Mascitti H, Fortier-Beaulieu M, Jaffal K, de Truchis P. 'Blue toes' following vaccination with the BNT162b2 mRNA COVID-19 vaccine. *J Travel Med* 2021;28:taab024.
- Duong TA, Velter C, Rybojad M, Comte C, Bagot M, Sulimovic L, et al. Did Whatsapp® reveal a new cutaneous COVID-19 manifestation? *J Eur Acad Dermatol Venereol* 2020;34:e348–50.
- Foxman EF, Storer JA, Fitzgerald ME, Wasik BR, Hou L, Zhao H, et al. Temperature-dependent innate defense against the common cold virus limits viral replication at warm temperature in mouse airway cells. *Proc Natl Acad Sci USA* 2015;112:827–32.
- Freeman EE, McMahon DE, Lipoff JB, Rosenbach M, Kovarik C, Takeshita J, et al. Pernio-like skin lesions associated with COVID-19: a case series of 318 patients from 8 countries. *J Am Acad Dermatol* 2020;83:486–92.
- Galván Casas C, Català A, Carretero Hernández G, Rodríguez-Jiménez P, Fernández-Nieto D, Rodríguez-Villa Lario A, et al. Classification of the cutaneous manifestations of COVID-19: a rapid prospective nationwide consensus study in Spain with 375 cases. *Br J Dermatol* 2020;183:71–7.
- Günther C, Berndt N, Wolf C, Lee-Kirsch MA. Familial chilblain lupus due to a novel mutation in the exonuclease III domain of 3' repair exonuclease 1 (TREX1). *JAMA Dermatol* 2015;151:426–31.
- Hamming I, Timens W, Bulthuis ML, Lely AT, Navis GJ, van Goor H. Tissue distribution of ACE2 protein, the functional receptor for SARS coronavirus. A first step in understanding SARS pathogenesis. *J Pathol* 2004;203:631–7.

- Herman A, Peeters C, Verroken A, Tromme I, Tennstedt D, Marot L, et al. Evaluation of chilblains as a manifestation of the COVID-19 pandemic. *JAMA Dermatol* 2020;156:998–1003.
- Hubiche T, Cardot-Leccia N, Le Duff F, Seitz-Polski B, Giordana P, Chiaverini C, et al. Clinical, laboratory, and interferon-alpha response characteristics of patients with chilblain-like lesions during the COVID-19 pandemic. *JAMA Dermatol* 2021;157:202–6.
- Ko CJ, Harigopal M, Gehlhausen JR, Bosenberg M, McNiff JM, Damsky W. Discordant anti-SARS-CoV-2 spike protein and RNA staining in cutaneous pernioic lesions suggests endothelial deposition of cleaved spike protein. *J Cutan Pathol* 2021;48:47–52.
- Lamborn IT, Jing H, Zhang Y, Drutman SB, Abbott JK, Munir S, et al. Recurrent rhinovirus infections in a child with inherited MDA5 deficiency. *J Exp Med* 2017;214:1949–72.
- Landa N, Mendieta-Eckert M, Fonda-Pascual P, Aguirre T. Chilblain-like lesions on feet and hands during the COVID-19 pandemic. *Int J Dermatol* 2020;59:739–43.
- López-Robles J, de la Hera I, Pardo-Sánchez J, Ruiz-Martínez J, Cutillas-Marco E. Chilblain-like lesions: a case series of 41 patients during the COVID-19 pandemic. *Clin Exp Dermatol* 2020;45:891–2.
- Magro CM, Mulvey JJ, Laurence J, Sanders S, Crowson AN, Grossman M, et al. The differing pathophysiologies that underlie COVID-19-associated perniois and thrombotic retiform purpura: a case series. *Br J Dermatol* 2021;184:141–50.
- Magro CM, Mulvey JJ, Laurence J, Seshan S, Crowson AN, Dannenberg AJ, et al. Docked severe acute respiratory syndrome coronavirus 2 proteins within the cutaneous and subcutaneous microvasculature and their role in the pathogenesis of severe coronavirus disease 2019. *Hum Pathol* 2020;106:106–16.
- McMahon DE, Amerson E, Rosenbach M, Lipoff JB, Moustafa D, Tyagi A, et al. Cutaneous reactions reported after Moderna and Pfizer COVID-19 vaccination: a registry-based study of 414 cases. *J Am Acad Dermatol* 2021;85:46–55.
- Moon JJ, Costa da Silva A, Tran JM, Kim C, Sharma R, Hinshaw M, et al. SARS-CoV-2-associated ‘covid toes.’ multiplex immunofluorescent characterization of its pathophysiology. Society for Investigative Dermatology. <https://www.sidannualmeeting.org/wp-content/uploads/2021/05/SID-2021-Virtual-Meeting-LB-Abstract-Booklet-FINAL.pdf>; 2021 (accessed 24 May 2021).
- Piccolo V, Neri I, Filippeschi C, Oranges T, Argenziano G, Battarra VC, et al. Chilblain-like lesions during COVID-19 epidemic: a preliminary study on 63 patients. *J Eur Acad Dermatol Venereol* 2020;34:e291–3.
- Rice G, Newman WG, Dean J, Patrick T, Parmar R, Flintoff K, et al. Heterozygous mutations in TREG1 cause familial chilblain lupus and dominant Aicardi-Goutieres syndrome. *Am J Hum Genet* 2007;80:811–5.
- Santonja C, Heras F, Núñez L, Requena L. COVID-19 chilblain-like lesion: immunohistochemical demonstration of SARS-CoV-2 spike protein in blood vessel endothelium and sweat gland epithelium in a polymerase chain reaction-negative patient. *Br J Dermatol* 2020;183:778–80.
- Shawa IT, Felmler DJ, Hegazy D, Sheridan DA, Cramp ME. Exploration of potential mechanisms of hepatitis C virus resistance in exposed uninfected intravenous drug users. *J Viral Hepat* 2017;24:1082–8.
- Silva IMS, Assersen KB, Willadsen NN, Jepsen J, Artuc M, Steckelings UM. The role of the renin-angiotensin system in skin physiology and pathophysiology. *Exp Dermatol* 2020;29:891–901.
- Steckelings UM, Wollschläger T, Peters J, Henz BM, Hermes B, Artuc M. Human skin: source of and target organ for angiotensin II. *Exp Dermatol* 2004;13:148–54.
- Uggetti C, Lepelley A, Crow YJ. Self-awareness: nucleic acid-driven inflammation and the type I interferonopathies. *Annu Rev Immunol* 2019;37:247–67.
- V'kovski P, Gultom M, Kelly JN, Steiner S, Russeil J, Mängeat B, et al. Disparate temperature-dependent virus-host dynamics for SARS-CoV-2 and SARS-CoV in the human respiratory epithelium. *PLoS Biol* 2021;19:e3001158.
- Zhang Q, Bastard P, Liu Z, Le Pen J, Moncada-Velez M, Chen J, et al. Inborn errors of type I IFN immunity in patients with life-threatening COVID-19. *Science* 2020;370:eabd4570.
- Zhang SY, Jouanguy E, Sancho-Shimizu V, von Bernuth H, Yang K, Abel L, et al. Human toll-like receptor-dependent induction of interferons in protective immunity to viruses. *Immunol Rev* 2007;220:225–36.
- Zimmermann N, Wolf C, Schwenke R, Lüth A, Schmidt F, Engel K, et al. Assessment of clinical response to Janus kinase inhibition in patients with familial chilblain lupus and TREG1 mutation. *JAMA Dermatol* 2019;155:342–6.