

Serveur Académique Lausannois SERVAL serval.unil.ch

Publisher's version PDF

Faculty of Biology and Medicine Publication

Originally published at:

Title: Interleukin 23-Helper T Cell 17 Axis as a Treatment Target for Pityriasis Rubra Pilaris.

Authors: Feldmeyer L, Mylonas A, Demaria O, Mennella A, Yawalkar N, Laffitte E, Hohl D, Gilliet M, Conrad C

Journal: JAMA dermatology

Year: 2017 Apr 1

Volume: 153

Issue: 4

Pages: 304-308

DOI: 10.1001/jamadermatol.2016.5384

Copyright (year) American Medical Association. All rights reserved.

Interleukin 23–Helper T Cell 17 Axis as a Treatment Target for Pityriasis Rubra Pilaris

Laurence Feldmeyer, MD, PhD; Alessio Mylonas, MSc; Olivier Demaria, PhD; Anna Mennella, MSc; Nikhil Yawalkar, MD; Emmanuel Laffitte, MD; Daniel Hohl, MD; Michel Gilliet, MD; Curdin Conrad, MD

IMPORTANCE Treatment of pityriasis rubra pilaris (PRP) is solely based on its resemblance to psoriasis rather than any knowledge of its pathomechanism. Insight into pathogenic mediators of inflammation is essential for targeted and valid treatment options that could replace previous serendipitous therapeutic approaches in refractory PRP.

OBJECTIVE To determine whether blockade of the interleukin 23–helper T cell 17 (IL-23–T_H17) pathway with ustekinumab represents an efficacious and, based on its proinflammatory cytokine profile, targeted treatment option in PRP.

DESIGN, SETTING, AND PARTICIPANTS In this case report, a patient with PRP received outpatient treatment at a university hospital department of dermatology with ustekinumab according to the dosing regimen approved for psoriasis. Lesional skin biopsy samples were taken from this patient and 2 others with refractory PRP. Messenger RNA (mRNA) expression of proinflammatory innate and T-cell–derived cytokines were measured and compared with skin samples from patients with psoriasis and healthy donors. From 1 patient, lesional skin samples were taken before ustekinumab treatment and 4 and 28 weeks after treatment initiation. Follow-up was completed after 6 months.

INTERVENTION Subcutaneous ustekinumab, 45 mg, at weeks 0 and 4 and quarterly thereafter.

MAIN OUTCOMES AND MEASURES The primary outcome was to determine the changes in expression of proinflammatory innate and T-cell–derived cytokines during ustekinumab therapy. The secondary objective was to evaluate the clinical and histopathologic phenotype in relation to the mRNA expression profile of proinflammatory cytokines.

RESULTS In lesional PRP skin samples from a single patient, upregulated expression levels were found for most proinflammatory innate cytokines, including tumor necrosis factor (TNF), IL-6, IL-12, IL-23, and IL-1 β . Among adaptive T-cell cytokines, an increase of T_H1 cytokines and, in particular, T_H17 cytokines IL-17A, IL-17F, and IL-22 was seen in PRP. The patient with PRP who received ustekinumab showed regression of skin lesions after 2 weeks and almost complete resolution after 1 month. Clinical and histopathologic improvement paralleled the expression levels of T_H17 cytokines but not of interferon- γ and TNF, which lagged behind the amelioration.

CONCLUSIONS AND RELEVANCE In this case report, a role of the IL-23–T_H17-axis in PRP was identified, suggesting a shared pathogenic inflammatory pathway with psoriasis, despite evident clinical and histopathologic differences. In addition, this report provides a rationale for targeting the IL-23–T_H17-pathway as a treatment option for refractory PRP.

JAMA Dermatol. 2017;153(4):304–308. doi:10.1001/jamadermatol.2016.5384
Published online January 25, 2017.

Author Affiliations: Department of Dermatology and Venereology, University Hospital of Lausanne, Centre Hospitalier Universitaire Vaudois, Lausanne, Switzerland (Feldmeyer, Mylonas, Demaria, Mennella, Hohl, Gilliet, Conrad); Department of Dermatology and Venereology, Inselspital Bern University Hospital, University of Bern, Bern, Switzerland (Feldmeyer, Yawalkar); Department of Dermatology and Venereology, Geneva University Hospitals, Geneva, Switzerland (Laffitte).

Corresponding Author: Curdin Conrad, MD, Department of Dermatology and Venereology, University Hospital of Lausanne, Centre Hospitalier Universitaire Vaudois, Av de Beaumont 29, CH-1011 Lausanne, Switzerland (curdin.conrad@chuv.ch).

Pityriasis rubra pilaris (PRP) is a chronic inflammatory skin disease that typically appears sporadically and is acquired in most cases.¹ Pityriasis rubra pilaris is clinically characterized by follicular hyperkeratosis on an erythematous base. These papules show a tendency to coalesce, thereby forming large orange-red plaques with classic demarcated islands of sparing. Pityriasis rubra pilaris frequently involves the palms and soles, leading to palmoplantar orange-red waxy keratoderma. The major clinical differential diagnosis is psoriasis. However, in its most common form, type 1 PRP is typically self-limited and resolves within 3 years in 80% of cases. Based on reported associations with various autoimmune diseases, such as myasthenia gravis, arthritis, and myositis, a pathogenesis driven by an aberrant immune response has been suggested. However, the pathogenesis of PRP remains elusive. Thus, treatment of PRP is mainly empirical and, owing to its resemblance to psoriasis, classic treatments for psoria-

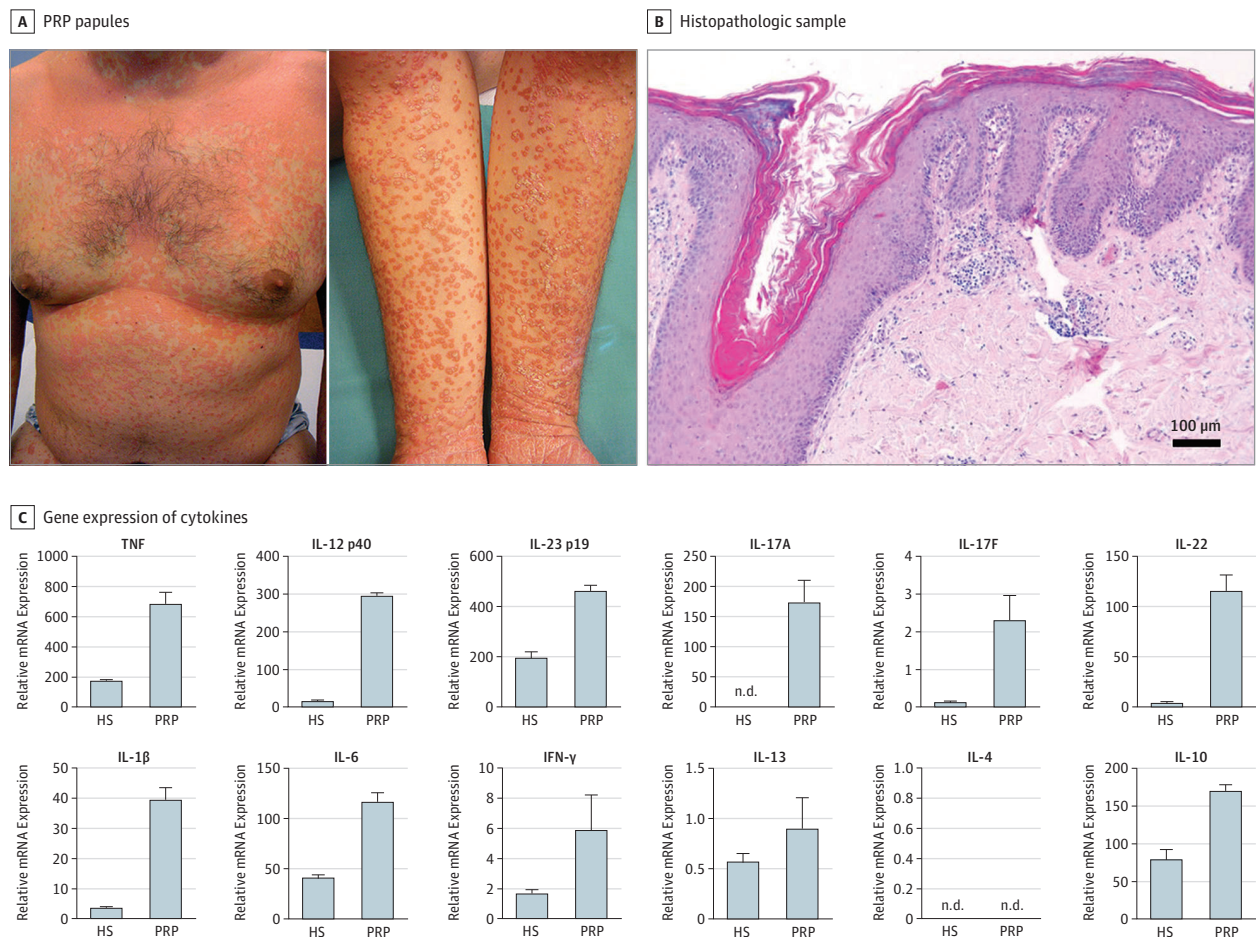
Key Points

Question Does targeting the interleukin 23–helper T cell 17 pathway represent a targeted treatment option for pityriasis rubra pilaris?

Findings In this case report, gene expression analyses of lesional skin samples taken from 3 patients with pityriasis rubra pilaris revealed a preferential helper T cell 17 expression profile. Analyses of samples from 1 patient performed before and during anti-interleukins 12 and 23 treatment with ustekinumab showed that expression levels of helper T cell 17 cytokines, but not of tumor necrosis factor or interferon- γ , paralleled clinical and histologic improvements.

Meaning This report identifies a role of the interleukin 23–helper T cell 17 axis in pityriasis rubra pilaris and provides a rationale for targeting this pathway as a treatment option for refractory pityriasis rubra pilaris.

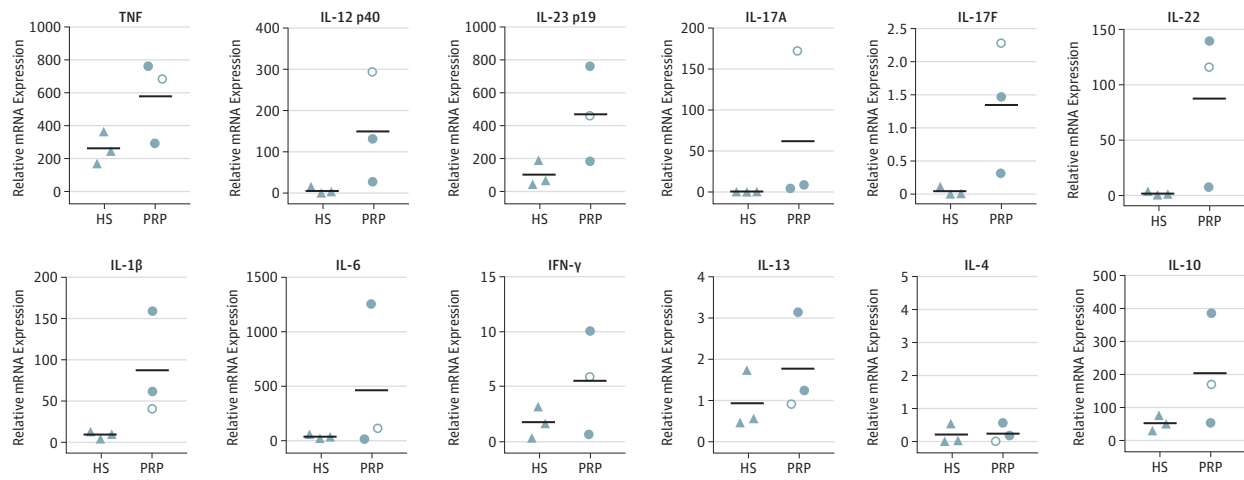
Figure 1. Expression of Helper T Cell 17 (T_H17) and T_H22 Cytokines in Skin Lesions of Pityriasis Rubra Pilaris (PRP)



A, Clinical image of a patient in his 40s with PRP shows typical orange-red follicular papules with scaly centers progressing to a widespread suberythroderma with islands of normal skin. B, Histopathologic evaluation of lesional skin with PRP shows a psoriasiform acanthosis (thickening of the epidermis), irregular hyperkeratosis (thickening of the corneal layer) with alternating vertical and horizontal orthokeratosis and parakeratosis (characteristic checkerboard pattern), and keratin plugs in the follicles

(hematoxylin-eosin, bar indicates 100 μ m). C, Relative messenger RNA (mRNA) expression of innate cytokines and adaptive T-cell-derived cytokines in lesional PRP skin compared with healthy skin shows particularly an upregulation of T_H17 cytokines in PRP. Error bars represent range of duplicates. HS indicates healthy skin; IFN- γ , interferon- γ ; IL, interleukin; mRNA, messenger RNA; and TNF, tumor necrosis factor.

Figure 2. Preferential Expression of Helper T Cell 17 and 22 (T_H17 and T_H22) Cytokines in Skin Lesions of Pityriasis Rubra Pilaris (PRP)



Messenger RNA (mRNA) expression of innate cytokines and adaptive T-cell-derived cytokines in the lesional skin samples of 3 patients (the patient in Figure 1 and 2 additional patients) with PRP compared with healthy skin (HS) confirms upregulation of proinflammatory innate cytokines and T_H17 cytokines

in PRP. Triangles represent individual donor with HS; dots, individual patients with PRP (open symbol corresponds to the patient in Figure 1). Horizontal bar denotes the mean value. IFN- γ indicates interferon- γ ; IL, interleukin; and TNF, tumor necrosis factor.

sis are used. Topical corticosteroids, vitamin D analogues, phototherapy, systemic retinoids, methotrexate disodium, cyclosporine, and more recently anti-tumor necrosis factor (TNF) agents have been described.¹ In addition, isolated cases of effective treatment with combined anti-interleukins 12 and 23 (IL-12, IL-23) (ustekinumab) have been published.^{2,3} None of these treatments was based on a pathophysiological rationale, but solely on the resemblance of PRP to psoriasis.

Herein we report that the cytokine expression in PRP shows a helper T cell 17 (T_H17) and T_H1 profile and that clinical improvement parallels the decrease in lesional T_H17 cytokines during effective anti-IL-12/IL-23 therapy. These findings suggest a role for T_H17 cytokines in PRP and provide basis for a targeted treatment in blocking the IL-23-T_H17 axis.

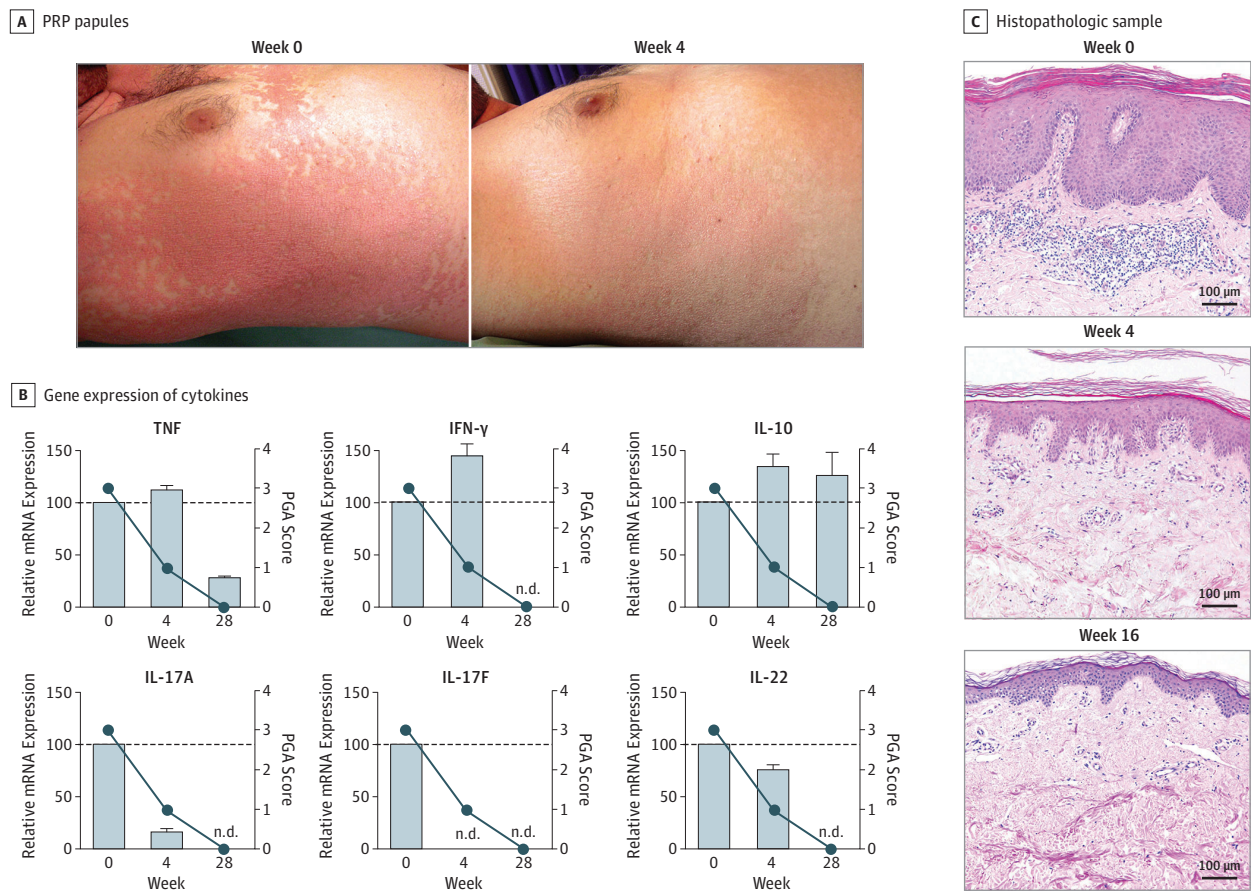
Methods

Skin biopsy samples were obtained from 3 patients with PRP at specified time points. Skin samples were fixed using 4% paraformaldehyde for histopathologic analysis or snap frozen and stored at -80°C for reverse transcription-polymerase chain reaction analysis (RT-PCR). Paraffin-embedded skin sections were deparaffinized and stained using a standard hematoxylin-eosin staining protocol. For quantitative RT-PCR, complementary DNA was synthesized using reverse transcriptase (SuperScript II; Invitrogen), and relative gene expression was quantified using specific probes (*TaqMan*; Life Technologies) and calculated using the comparative C_T method, where 2^{-ΔΔC_T} describes the difference in C_T values between the target gene and normalizer gene [(C_T gene of interest - C_T internal control) sample A - (C_T gene of interest - C_T internal control) sample B)] using glyceraldehyde-3-phosphate dehydrogenase (GAPDH) as an endogenous control. Analyses were performed in duplicates, and mean values

or mean values plus the range of duplicates are depicted. This study was performed in accordance with the guidelines of the Declaration of Helsinki⁴ and was approved by the cantonal ethics committee of Vaud, Switzerland. All patients provided written informed consent.

Report of a Case

A man in his 40s with PRP presented with painful palmoplantar hyperkeratosis, erythema of the face and scalp, and characteristic confluent red to orange follicular papules progressing to suberythroderma (Figure 1A). Diagnosis was confirmed by results of histopathologic analysis showing a psoriasiform dermatitis with irregular hyperkeratosis and the typical alternating vertical and horizontal orthokeratosis and parakeratosis (checkerboard pattern), keratin plugs in the follicles, and a sparse lymphohistiocytic, perivascular dermal infiltrate (Figure 1B). Because PRP shares common features with psoriasis, we analyzed messenger RNA (mRNA) expression of innate and adaptive cytokines involved in psoriasis pathogenesis. We found upregulated mRNA expression levels for most proinflammatory innate cytokines, including TNF, IL-6, IL-12, IL-23, and IL-1 β in the lesional skin sample of the patient with PRP compared with normal skin (Figure 1C). Among adaptive T-cell cytokines, we found a particular increase of T_H17 cytokines IL-17A, IL-17F, and IL-22 in PRP compared with basal expression in normal skin, suggesting that these cytokines might play a pathogenic role in PRP similar to that in psoriasis. Preferential overexpression of T_H17 cytokines was confirmed in 2 additional patients with PRP, showing a similar profile (Figure 2). Furthermore, cytokines of the IL-23-T_H17 axis showed comparable mRNA expression levels in all 3 patients with PRP and in psoriasis.

Figure 3. Change in Helper T Cell 17 (T_H17) Cytokines in Pityriasis Rubra Pilaris (PRP) During Treatment With Ustekinumab

A, Clinical image of the patient with PRP before (week 0) and week 4 after initiation of anti-interleukins 12 and 23 (IL-12/IL-23) treatment (ustekinumab [Stelara]) shows rapid improvement. B, Relative messenger RNA (mRNA) expression of tumor necrosis factor (TNF), interferon- γ (IFN- γ), IL-10, IL-17A, IL-17F, and IL-22 within the skin at weeks 0, 4, and 28. The different cytokines are shown overlapped to the Physician Global Assessment (PGA) score to

analyze potential correlation of gene expressions with clinical improvement. PGA scores range from 0 to 4, with higher scores indicating greater severity. Error bars represent range of duplicates. C, Histopathologic images of lesional skin samples with PRP at weeks 0, 4, and 28 show reduction of acanthosis, normalization of hyperkeratosis and parakeratosis toward orthokeratosis, and disappearance of the dermal inflammatory infiltrate (hematoxylin-eosin).

In our patient, topical therapies remained insufficient; his PRP was further aggravated despite 4 months of treatment. Worsening of the dermatosis on sun exposure prevented us from using phototherapy. Acitretin and methotrexate were contraindicated owing to a history of a drug-induced hepatitis with ongoing elevation of liver enzyme levels. Because IL-23 is critical for the differentiation and expansion of T_H17 cells,^{5,6} and because we found a preferential overexpression of T_H17 cytokines, we opted for ustekinumab (Stelara), a human anti-IL-12/IL-23 antibody approved for severe psoriasis.⁷

Subcutaneous ustekinumab, 45 mg, was given at weeks 0 and 4 and quarterly thereafter, according to the psoriasis dose regimen. The lesions showed regression after 2 weeks and almost complete resolution after 1 month (Figure 3A). After 6 months, the treatment was interrupted and the patient remained in remission. The clinical improvement as reflected by the 4-point Physician Global Assessment (a measure of the mean redness, thickness, and scaling of the lesions, each graded on a scale of 0-4, with higher scores indicating increased severity) nicely

paralleled the mRNA expression of IL-17A and IL-17F and, to some degree, expression of IL-22 (Figure 3B). On the other hand, although the expression of TNF and IFN- γ declined eventually, their decrease markedly lagged behind the clinical improvement, whereas IL-1 β and IL-10 mRNA expression remained unchanged after 6 months of treatment. Furthermore, the expression of T_H17 cytokines also paralleled the improvement of histopathologic findings, such as normalization of the epidermal thickening and the corneal layer and attenuation of the cellular infiltrate (Figure 3C). This finding suggests a role for T_H17 cytokines in the pathogenesis of PRP and in driving its skin phenotype.

Discussion

Studies of PRP treatment are hampered by the unclear pathogenesis and the low incidence of the disease; therefore PRP therapy is based on the results of small case series and case reports.^{8,9} Consequently, the therapy for PRP remains largely

empirical and, owing to its clinical and histopathologic similarities to psoriasis, classic psoriasis treatments are being used.

In psoriasis, epidermal hyperplasia is driven by IL-23 and mediated by IL-17 and IL-22, with IL-22 directly inducing keratinocyte hyperproliferation.^{10,11} Furthermore, the blockade of IL-12/IL-23, IL-23 specifically, and IL-17 have all been proven effective in psoriasis.^{7,12,13} Epidermal thickening, hyperproliferation and altered differentiation of keratinocytes are also hallmarks of PRP, rendering T_H17 cells an interesting therapeutic target in PRP. Indeed, we found an increased T_H17 expression profile in skin lesions of 3 patients with PRP and showed that the expression levels of T_H17 cytokines, but not of TNF or the T_H1 cytokine IFN- γ , paralleled clinical improvement during anti-IL-12/IL-23 treatment. Pityriasis rubra pilaris is often self-limiting, but the progressive disease course before treatment and the rapid response after a single injection strongly suggest that disease resolution was not spontaneous. Furthermore, previous reports in PRP described equally rapid efficacy on initiation of ustekinumab treatment.³ Successful anti-IL-17 treatment of a patient with refractory PRP was also recently reported, which further supports an efficacy of the IL-23-T_H17 blockade in PRP.¹⁴

This study indicates a shared inflammatory pathway in psoriasis and PRP. Interestingly, mutations in the caspase recruitment domain family member 14 gene (*CARD14* [HGNC 16446]) have been identified in both diseases, raising the possibility that *CARD14* is upstream of the IL-23-T_H17 pathway. However, our patient did not display any *CARD14* mutation

known in familial¹⁵ or sporadic¹⁶ PRP. Whether the efficacy of blocking the IL-23-T_H17 pathway is linked to a specific genotype and/or clinical subtype remains to be shown.

Despite pathogenic commonalities between psoriasis and PRP, obvious distinctions remain, such as orange-red waxy keratoderma, follicular hyperkeratosis, and absence of neutrophils in PRP. Future studies should identify pathologic mechanisms underlying these differences. Another feature of PRP is its spontaneous resolution. Interestingly, we found higher levels of IL-10 in PRP compared with psoriasis, which persisted on treatment, suggesting a potential anti-inflammatory pathway in PRP.

Limitations

This study has some limitations owing to the restricted number of patients included. Additional studies will need to further corroborate our findings by treating larger cohorts of patients with PRP using ustekinumab, and anti-IL-17- and anti-IL-23-specific antibodies.

Conclusions

This study identifies a role of the IL-23-T_H17-axis in PRP, suggesting a shared pathogenic inflammatory pathway with psoriasis. The findings provide a rationale for targeting the IL-23-T_H17 axis as a treatment option for refractory PRP that could replace previous serendipitous therapeutic approaches.

ARTICLE INFORMATION

Accepted for Publication: November 12, 2016.

Published Online: January 25, 2017.

doi:10.1001/jamadermatol.2016.5384

Author Contributions: Dr Feldmeyer and Mr Mylonas contributed equally to this study. Dr Conrad had full access to all the data in the study and takes responsibility for the integrity of the data and the accuracy of the data analysis.

Study concept and design: Mylonas, Gilliet, Conrad.
Acquisition, analysis, or interpretation of data: Feldmeyer, Mylonas, Demaria, Mennella, Yawalkar, Laffitte, Hohl, Conrad.

Drafting of the manuscript: Feldmeyer, Mylonas, Conrad.

Critical revision of the manuscript for important intellectual content: Feldmeyer, Mylonas, Demaria, Mennella, Yawalkar, Laffitte, Hohl, Gilliet.

Statistical analysis: Mylonas, Mennella, Conrad.

Administrative, technical, or material support: Mylonas, Demaria, Yawalkar, Laffitte, Hohl.

Study supervision: Feldmeyer, Mylonas, Gilliet, Conrad.

Conflict of Interest Disclosures: None reported.

Additional Contributions: Stephanie Bibert, PhD, and Pierre-Yves Bochud, MD, Department of Internal Medicine, Infectious Diseases Service, University Hospital of Lausanne, Centre Hospitalier Universitaire Vaudois, performed the *CARD14* sequencing. They received no extra compensation for this work. We thank the patient for granting permission to publish this information.

REFERENCES

- Ross NA, Chung HJ, Li Q, Andrews JP, Keller MS, Uitto J. Epidemiologic, clinicopathologic, diagnostic, and management challenges of pityriasis rubra pilaris: a case series of 100 patients. *JAMA Dermatol.* 2016;152(6):670-675.
- Wohlrab J, Krefl B. Treatment of pityriasis rubra pilaris with ustekinumab. *Br J Dermatol.* 2010;163(3):655-656.
- Di Stefani A, Galluzzo M, Talamonti M, Chiricozzi A, Costanzo A, Chimenti S. Long-term ustekinumab treatment for refractory type I pityriasis rubra pilaris. *J Dermatol Case Rep.* 2013;7(1):5-9.
- World Medical Association. World Medical Association Declaration of Helsinki: ethical principles for medical research involving human subjects. *JAMA.* 2013;310(20):2191-2194. doi:10.1001/jama.2013.281053
- McGeachy MJ, Chen Y, Tato CM, et al. The interleukin 23 receptor is essential for the terminal differentiation of interleukin 17-producing effector T helper cells in vivo. *Nat Immunol.* 2009;10(3):314-324.
- Miossec P, Korn T, Kuchroo VK. Interleukin-17 and type 17 helper T cells. *N Engl J Med.* 2009;361(9):888-898.
- Leonardi CL, Kimball AB, Papp KA, et al; PHOENIX 1 study investigators. Efficacy and safety of ustekinumab, a human interleukin-12/23 monoclonal antibody, in patients with psoriasis: 76-week results from a randomised, double-blind, placebo-controlled trial (PHOENIX 1). *Lancet.* 2008;371(9625):1665-1674.
- Ross NA, Chung HJ, Li Q, Andrews JP, Keller MS, Uitto J. Epidemiologic, clinicopathologic, diagnostic, and management challenges of pityriasis rubra pilaris: a case series of 100 patients. *JAMA Dermatol.* 2016;152(6):670-675.
- Klein A, Landthaler M, Karrer S. Pityriasis rubra pilaris: a review of diagnosis and treatment. *Am J Clin Dermatol.* 2010;11(3):157-170.
- Rizzo HL, Kagami S, Phillips KG, Kurtz SE, Jacques SL, Blauvelt A. IL-23-mediated psoriasis-like epidermal hyperplasia is dependent on IL-17A. *J Immunol.* 2011;186(3):1495-1502.
- Conrad C, Gilliet M. Type I IFNs at the interface between cutaneous immunity and epidermal remodeling. *J Invest Dermatol.* 2012;132(7):1759-1762.
- Gordon KB, Duffin KC, Bissonnette R, et al. A phase 2 trial of guselkumab versus adalimumab for plaque psoriasis. *N Engl J Med.* 2015;373(2):136-144.
- Langley RG, Elewski BE, Lebwohl M, et al; ERASURE Study Group; FIXTURE Study Group. Secukinumab in plaque psoriasis: results of two phase 3 trials. *N Engl J Med.* 2014;371(4):326-338.
- Schuster D, Pfister-Wartha A, Bruckner-Tuderman L, Schempp CM. Successful treatment of refractory pityriasis rubra pilaris with secukinumab. *JAMA Dermatol.* 2016;152(11):1278-1280.
- Fuchs-Telem D, Sarig O, van Steensel MA, et al. Familial pityriasis rubra pilaris is caused by mutations in *CARD14*. *Am J Hum Genet.* 2012;91(1):163-170.
- Li Q, Jin Chung H, Ross N, et al. Analysis of *CARD14* polymorphisms in pityriasis rubra pilaris: activation of NF- κ B. *J Invest Dermatol.* 2015;135(7):1905-1908.