



## Difficult management of an extremely rare case of giant pigmented epithelioid melanocytoma



Mengu Ma Tooh<sup>a</sup>, Oumama El Ezzi<sup>a</sup>, Samuel Rotman<sup>b</sup>, Mirko Dolci<sup>c</sup>, Raymond Bossou<sup>d</sup>, Anthony de Buys Roessingh, MD, PhD<sup>a,\*</sup>

<sup>a</sup> Department of Pediatric Surgery, University Hospital of Lausanne (CHUV), 1011 Lausanne, Switzerland

<sup>b</sup> Department of Pathology, CHUV, 1011 Lausanne, Switzerland

<sup>c</sup> Department of Anesthesiology, CHUV, 1011 Lausanne, Switzerland

<sup>d</sup> Department of Pediatrics, Department of Zou and Colline, Abomey, Benin

### ARTICLE INFO

#### Article history:

Received 7 February 2017

Received in revised form

6 April 2017

Accepted 8 April 2017

Available online 10 April 2017

#### Keywords:

Pigmented epithelioid melanocytoma

Lymphatic leakage

### ABSTRACT

Pigmented epithelioid melanocytoma (PEM), a heavily pigmented and highly uncommon melanocytic lesion, is extremely rare. It comes under several forms and names. We report the case of a three-year-old boy born with an isolated right lumbopelvic and femoral giant PEM. The boy was unable to walk due to the size and the shape of the lesion. He underwent two stages of intralesional resections, one in Benin and the second in Switzerland. The first surgery was followed by hypotensive hypovolemic and anaphylactic shocks, and the second surgery by a continuous lymphatic leakage from the wounds for months. The strategic management approach, the surgery and follow-up of this case of giant PEM presented a real challenge.

© 2017 The Authors. Published by Elsevier Inc. This is an open access article under the CC BY-NC-ND license (<http://creativecommons.org/licenses/by-nc-nd/4.0/>).

## 1. Introduction

The first description of a PEM proliferation lesion was made in 1832 by Dick [1], who also noted that it mostly occurred in horses. He therefore at first named the lesion “animal type melanoma”. It is only recently that several of its different manifestations, such as the pigmented synthesizing melanoma or the epithelioid blue nevus associated with the “Carney complex” [2], were regrouped under the general term of PEM because of their histological similarities [3]. Other authors have suggested that PEM may be used to indicate a low grade melanocytic tumor with metastatic potential undistinguishable from animal type melanoma<sup>3</sup>. Nevertheless, these melanocytic-type lesions remain extremely uncommon. Surgical excision may be challenging, even if different options are present. In our case, the quality of the skin, as well as its capacity to heal, were uncommonly poor, leading to several difficulties such as, first, hypovolemic shock after surgery, and then continuous leakage of the wounds during months.

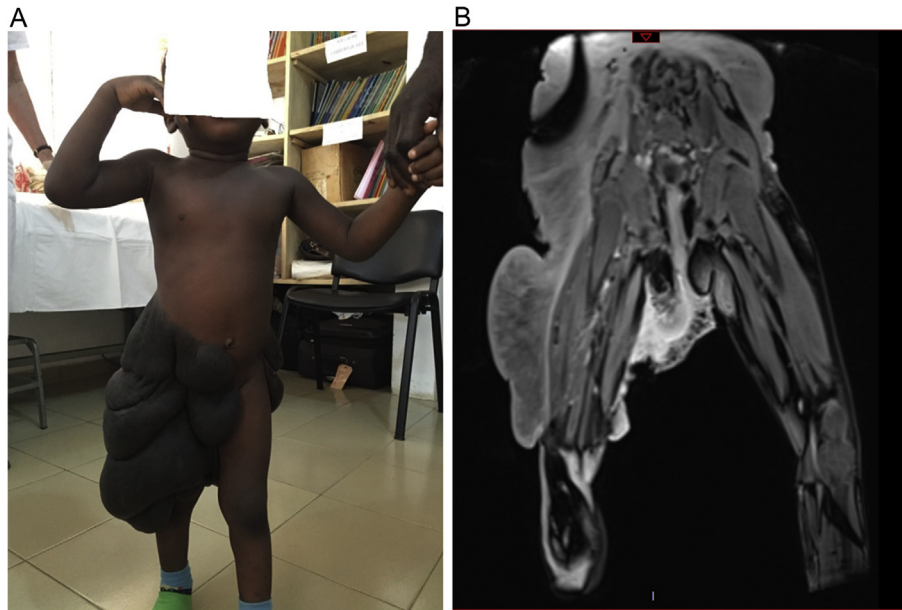
## 2. Case report

A three-year-old boy was born with a right giant lumbopelvic and femoral pigmented lesion. The lesion increased in size as the child grew up and became increasingly incapacitating. The boy was first seen during one of our surgical cooperation missions in his country, Benin. Examination revealed that the deep, soft and redundant lesion covered the entire right abdominopelvic and inguinal areas along the right flank, with an extension to the buttocks on both sides (Fig. 1A). There were numerous satellite lesions on the legs and on the thorax. The weight of the lesion was so great that the child could not walk.

An initial partial resection was performed in Benin by our surgical team in order to remove part of the lesion and to obtain a tissue sample for histological analysis. We presumed that reducing the weight of the mass would allow the boy to stand and walk. We found that the lesion, lying on the muscle fascia, was deep and highly vascularised. Post-operative follow-up was extremely difficult as the boy suffered a hypovolemic shock after 2 h of surgery, followed by an anaphylactic shock after a blood transfusion. After resuscitation, he went into a coma, breathing spontaneously but without any capacity to communicate. The 6th day after surgery, he recovered completely. During this period, dressings had to be replaced several times a day because of a general leakage of the

\* Corresponding author. Service de chirurgie pédiatrique, Centre Hospitalier Universitaire Vaudois (CHUV), CH -1011 Lausanne, Switzerland.

E-mail address: [anthony.debuys-roessingh@Chuv.ch](mailto:anthony.debuys-roessingh@Chuv.ch) (A. de Buys Roessingh).



**Fig. 1.** **A.** The three-year-old boy was born with a right giant lumbopelvic and femoral pigmented lesion. The lesion covered the entire right abdominopelvic and inguinal areas along the right flank, with an extension to the buttocks on both sides. **B.** Magnetic Resonance Imaging (MRI) showed a deeply located mass, lying on the aponevrotic layer, hypervascularised, receiving its blood from the external iliac, superficial femoral and popliteal arteries.

probably lymphatic component of the residual skin after surgery. The skin finally healed and closed completely after about three months. Histological analysis confirmed the diagnosis of PEM, with a low risk of malignancy.

The boy was transferred to Switzerland a few months later in order to investigate the depth of the lesion and to remove its residual portion. Magnetic resonance imaging (MRI) showed a deeply located mass, lying on the aponevrotic layer, hypervascularised, receiving its blood flow from the external iliac, superficial femoral and popliteal arteries (Fig. 1B). The right gluteus looked atrophic. There was no element indicative of a “Carney complex”, which also includes skin and heart myxomas, endocrine tumors or over-activity.

He underwent a second stage of intralesional resection with iterative care. Due to the large surface of the lesion and the absence of fat tissue between the lesion and the muscles, we chose not to do a superficial skin graft. The patient was then transferred to the intensive care unit for blood transfusion and albumin supply. He recovered after two days. Surgery in Switzerland was followed by intense leakage from the remaining skin along the scar, and also from the superficial layer of the skin, which was very fragile. Postoperative care included multiple changes of dressing during the week, not only because of the leakage, but also to prevent the child from scratching himself and bleeding. As the skin was very fragile, we tried several types of skin protection and film dressings such as hydrofiber or knitted viscose, or paraffin tulle, or low adherence dressings. Showers were also given every two days to clean the skin and remove all kind of bacteria contamination. The skin remained very fragile and the leakage persisted for months (Fig. 2A). After months, the skin became dryer and the child was finally transferred to his country. He is now followed by local pediatricians and we will follow him every six months during our missions of cooperation.

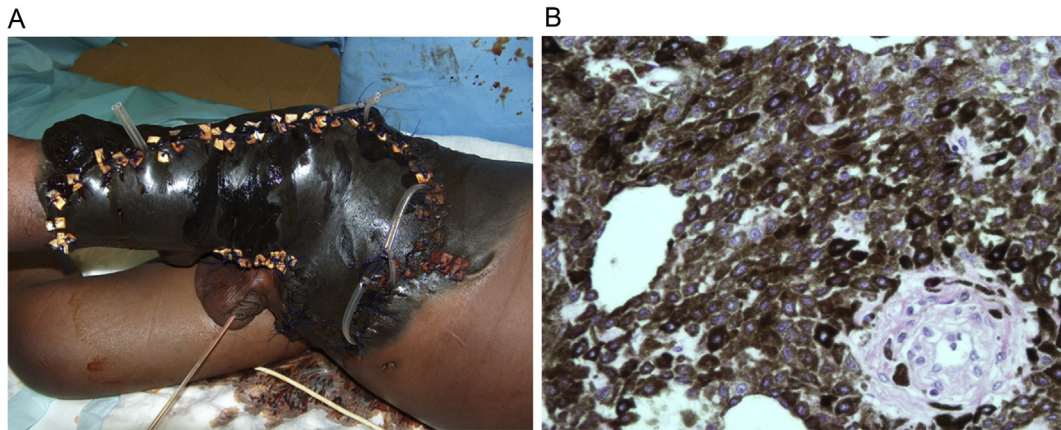
The second fresh histopathological analysis confirmed a highly pigmented tumor, extending deeply into the derm and hypoderm. There was a Paget-like infiltration of the epiderm. There was no dermal border zone free of the tumor. Microscopically, the tumor

was composed of a proliferation of epitheloid cells. The cytoplasm was abundant and heavily charged in melanic pigments. In some area, pigments density was so high that pigments formed broad intracytoplasmic granules avoiding a precise nuclear morphology's analysis. No mitoses and no atypia were observed. The stroma showed some large arteries. By immunochemistry, tumoral cells presented melanocytic differentiation and were positive for Melan A, S100 and HMB45 (Fig. 2B). Melanophage population was characterized using CD163 and CD68.

### 3. Discussion

When we discovered the child in Africa, he was suffering from a debilitating large, deep, redundant dark tumor of unknown etiology estimated at 30% of his total body surface (TBS). Performing a resection of the mass in Benin was too great a challenge, mainly because of its size and the unknown nature of the lesion. It would have been possible to cover the surface of the resulting wound with a superficial meshed skin graft, but there was a high risk of skin necrosis in case of bacterial contamination. The brevity of our stay in Benin (10 days) and the lack of appropriate follow-up did not allow us to opt for this particular strategy. This surgery would simply have been too risky. We therefore decided on a partial resection to try to reduce the size of the mass and also procure tissue samples for histological diagnosis in our country, Switzerland. Surgery was difficult because of the quality of the skin, which was soft and without consistency. Suturing the skin proved difficult, and we had to use large needles to join the edges of the wound. While still in Benin, we observed a persistent dark leakage of the skin, and later learned that the dressings had to be changed frequently during the several weeks the child remained in Africa after the surgery. After three months, we received a picture of the child, showing an apparently closed skin.

The child was then transferred to Switzerland for the second stage of surgery. We had a discussion similar to the one we had had in Africa concerning the choice of surgical strategy, because the skin was highly contaminated by several bacteria. Superficial



**Fig. 2.** **A.** Postoperative care included multiple changes of dressing during the week, not only because of the leakage, but also to prevent the child from scratching himself and bleeding. **B.** Microscopically, the tumor was composed of a proliferation of epithelioid cells. The cytoplasm was abundant and heavily charged in melanic pigments. No mitoses and no atypia were observed.

meshed skin graft could have been envisaged after a resection, but there was no healthy tissue layer above the aponeurosis and muscles. In addition, covering all the surface of the skin with an artificial derma would entail a high risk of contamination and infection. We therefore chose to perform an intralesionnal resection with direct skin closure of the edges. Skin leakage was again present, and persisted for a surprisingly long period. Dressings were mandatory to prevent the child from scratching himself and bleeding.

This case of giant PEM shows how difficult it is to plan a surgical strategy when the diagnosis is uncertain and the surgery is performed abroad, especially in developing countries, where surgical strategy and planning should be adapted to the local surgical and medical environment. Moreover, local pediatric surgeons have to organize the long-term treatment, and follow-up is not always easy for the local team. Our collaboration in Africa gives us the opportunity to share our professional experience with local medical teams. The creation of an independent surgical center with local professionals who can perform operations and plan the follow-up on their own is now a reality [4].

In our case however, even though partial intralesionnal resection did considerably reduce the weight of the mass, thus making it possible for the child to walk, follow-up proved very difficult in both countries. The child will be returned to his country as soon as possible, when the skin has closed. He will then be followed by the local team, and by our team on our yearly visit, to check the scar and the growth of the satellite lesions.

#### 4. Conclusion

PEM has a distinct histopathologic/diagnostic identity among melanocytic tumors, and possibly a favorable prognosis [5]. However, its biologic behavior and its relationship to naevi and melanoma remain to be clearly established. Several authors suggest that further cases of PEM, their treatment and long-term follow-up, should be published in order to better assess the biologic/prognostic characteristics of PEM. A close mid- and long-term follow up is essential for this rare condition in order to better understand its prognosis and development.

#### References

- [1] Dick W. Melanosis in men and horses. *Lancet* 1832;19:192.
- [2] Zembowicz A, Carney JA, Mihm MC. Pigmented epithelioid melanocytoma: a low-grade melanocytic tumor with metastatic potential indistinguishable from animal-type melanoma and epithelioid blue nevus. *Am J Surg Pathol* 2004;28:31–40.
- [3] Aung PP, Mutyambizi KK, Danialan R, et al. Differential diagnosis of heavily pigmented melanocytic lesions: challenges and diagnostic approach. *J Clin Pathol* 2015;68:963–70.
- [4] de Buys Roessingh AS, Dolci M, Zbinden-Trichet C, Bossou R, et al. Success and failure for children born with facial cleft in Africa: a 15-year follow-up. *World J Surg* 2012;36:1963–9.
- [5] Pepe CA, Lombardi M, Cortelazzi C, Aimi F, et al. Pigmented epithelioid melanocytoma: report of a case with favorable outcome after a 4-year follow-up period. *Acta Biomed* 2014;9(85):60–3.