
**UNIVERSITE DE LAUSANNE – FACULTE DE BIOLOGIE ET DE MEDECINE
DEPARTEMENT DES SERVICES DE CHIRURGIE ET D' ANESTHESIOLOGIE**

Service de Chirurgie Thoracique et vasculaire

Chef de Service : Professeur Hans-Beat Ris

**VIDEO-ASSISTED RIGHT SUPRADIAPHRAGMATIC THORACIC DUCT
LIGATION FOR NON TRAUMATIC RECURRENT CHYLOTHORAX**

THESE

Présentée à la Faculté de Biologie et de Médecine de

L'Université de Lausanne pour l'obtention

du grade de

DOCTEUR EN MEDECINE

Par

WF
980
chr

Michel Christodoulou

BHTE 3427

Médecin diplômé de la Confédération Suisse

Originaire de Egnach (Thurgovie)

Lausanne

2006

Ligature supra-diaphragmatique du canal thoracique, video-assistée, pour chylothorax récurrent non traumatique.

Introduction

Un chylothorax est une pathologie comprenant des manifestations respiratoires, nutritionnelles et immunologiques. La récurrence du chylothorax ou l'échec du traitement conservateur imposent un traitement chirurgical. Ce travail rapporte notre expérience de ligature supra-diaphragmatique, vidéo-assistée du canal thoracique, pour chylothorax récurrent non traumatique.

Patients et méthodes

Entre 1999 et 2004, nous avons recensé six observations (quatre du côté droit, un du côté gauche et un bilatéral) Le chylothorax s'est développé chez trois patients traités par radio et chimiothérapie pour tumeur (deux lymphomes et une tumeur du sein) un dans le contexte d'une lymphangioléiomyomatose et un après greffe cardiaque.

Résultats

Les patients ont bénéficié sous anesthésie générale, d'une ligature du canal thoracique supra-diaphragmatique, vidéo-assistée. Le temps opératoire moyen a été de 102 minutes. Le chylothorax a régressé chez cinq des six patients en sept jours. Un patient a été repris par thoracotomie droite au huitième jour pour chylothorax persistant. Dans la phase post-opératoire, un patient a développé une détresse respiratoire nécessitant une ventilation mécanique. Un autre patient a présenté un chylopéritoine important traité par un stent de Le Veen®. Le séjour moyen a été de quatorze jours sans mortalité péri-opératoire.

Conclusion

Le traitement du chylothorax non traumatique récurrent est, en première intention, un traitement médical. En cas de récurrence ou d'échec du traitement conservateur, le traitement chirurgical par ligature du canal thoracique supra-diaphragmatique, vidéo-assistée, permet de traiter avec succès le chylothorax récurrent non traumatique.

Video-assisted right supradiaphragmatic thoracic duct ligation for non-traumatic recurrent chylothorax

Michel Christodoulou, Hans-Beat Ris^{*}, Edgardo Pezzetta

Division of Thoracic Surgery, Centre Hospitalier Universitaire Vaudois, 1010 Lausanne, Switzerland

Received 14 November 2005; received in revised form 28 January 2006; accepted 31 January 2006

Abstract

Background: Chylothorax is an uncommon disorder with respiratory, nutritional and immunological manifestations. Surgical management is indicated in case of recurrence or failure after conservative treatment. We report our experience with video-assisted right-sided supradiaphragmatic thoracic duct ligation for non-traumatic, non-postoperative persistent or recurrent chylothorax. **Patients and methods:** The medical records of six patients operated at our institution between 1999 and 2004 were retrospectively reviewed. A right-sided chylothorax was found in four patients, a left-sided in one, and a bilateral in one. Three patients developed chylothorax after chemotherapy and chest irradiation for malignant diseases (lymphoma in two patients and breast cancer in one), one in the context of lymphangioleiomyomatosis, one due to a non-diagnosed lymphoma, and one after heart transplantation. **Results:** The mean operative time was 102 min, with an average length of hospital stay of 14 days. Persistent cessation of chylous effusion within 7 days after surgery was observed in 5/6 patients without recurrence during a mean follow-up time of 41 months. One patient with undiagnosed mediastinal lymphoma required re-operation and thoracic duct ligation on day 8 by right-sided thoracotomy due to persistent chylothorax. No 30-day mortality was recorded. Two patients presented postoperative complications including respiratory insufficiency requiring mechanical ventilation in one, and chylous ascites development requiring peritoneo-venous LeVein shunting in one patient. **Conclusions:** Recurrent or persistent non-traumatic chylothorax may be successfully treated by video-assisted right supradiaphragmatic thoracic duct ligation.

© 2006 Elsevier B.V. All rights reserved.

Keywords: Chylothorax; Supradiaphragmatic duct ligation; Video-assisted thoracic surgery

1. Introduction

Chylothorax is an uncommon but vexing clinical disorder [1–4] and may be a life-threatening condition if left untreated [2]. It may be related to various underlying causes such as penetrating or blunt trauma to the neck, chest or upper abdomen, surgery involving the oesophagus, lung, pleura, mediastinum and heart, and diseases such as lymphangioleiomyomatosis or lymphoma [1–6].

The clinical presentation of chylothorax is mainly related to the presence of pleural effusion and nutritional deterioration resulting from loss of large amounts of electrolytes, proteins, lipids and vitamins [1–4]. Immune deficiency and lymphopenia are other significant characteristics of the disease [1,2,4].

The optimal treatment of chylothorax is still controversial and depends on the setting in which it evolves. Conservative management is usually recommended in first

line and consists of total parenteral nutrition or low fat, medium-chain triglyceride supplemented regimens for several weeks [1–4]. However, repeated thoracocentesis or chest tube drainage is often required during conservative treatment in order to relieve dyspnea, which bears an increased risk of pleural infection [1,2,4]. Refractory chylothorax after failure of medical therapy is usually addressed for surgery. Several surgical procedures have been described in this context including pleurodesis, pleurectomy, right supradiaphragmatic thoracic duct ligation and pleuro-peritoneal shunting [1–4,7]. Thoracic duct ligation has been introduced by Lampson [8] in 1948 which decreased the mortality rate from 50% to 15%. It has been recognised that surgical intervention to ligate the thoracic duct should be performed before the debilitating complications of chylothorax have manifested. Although thoracic duct ligation has been accomplished by thoracoscopy, most surgeons rely on open procedure through a right thoracotomy. Thoracic duct ligation performed by a VATS approach has not gained wide acceptance since most reports deal with anecdotal observations and are based mainly on case reports [5,9–21]. We report our experience with thoracoscopic right supra-diaphragmatic thoracic duct ligation in a small series

^{*} Corresponding author. Tel.: +41 21 3142408; fax: +41 21 3142358.
E-mail address: Hans-Beat.Ris@chuv.ch (H.-B. Ris).

of six patients presenting with recurrent or persisting non-traumatic chylothorax.

2. Patients and methods

All patients presenting with symptomatic, recurrent or persisting non-traumatic chylothorax who underwent video-assisted right supradiaphragmatic thoracic duct ligation between 1999 and 2004 at our institution were the subject of this report. Inclusion criteria for video-assisted supradiaphragmatic duct ligation consisted of the presence of persisting or recurrent chylothorax with elevated triglyceride levels > 1.3 mmol/l in the pleural effusion following unsuccessful conservative management and chest tube drainage. CT scan of the chest was performed after drainage in order to confirm full expansion of the lungs. The presence of an entrapped lung by loculated effusions or a pleural peel was an exclusion criteria for video-assisted supradiaphragmatic thoracic duct ligation.

2.1.1. Surgical technique

General anaesthesia with selective double lumen intubation was performed and the patient was placed in a left lateral position. After exclusion of the right lung, two 7 mm thoracoports were inserted in the mid-axillary line at the levels of 8th and 10th intercostal spaces, respectively (Fig. 1a). The optic and a suction device were introduced which allowed the emptying and inspection of the pleural cavity. A 4 cm incision was then performed at the posterolateral level of the 9th intercostal space in order to introduce conventional surgical instruments without thoracoport (Fig. 1a). The inferior border of the lung was grasped by an endoscopic duval forceps and the pulmonary ligament was divided (Fig. 1b). The azygous vein was identified and the parietal pleura was incised between the azygous vein and the vertebral bodies, from the diaphragmatic hiatus to the inferior pulmonary vein. The oesophagus was dissected from the hiatus to the inferior pulmonary vein and retracted medially (Fig. 1c). The descending aorta was dissected behind the esophagus on its medial aspect

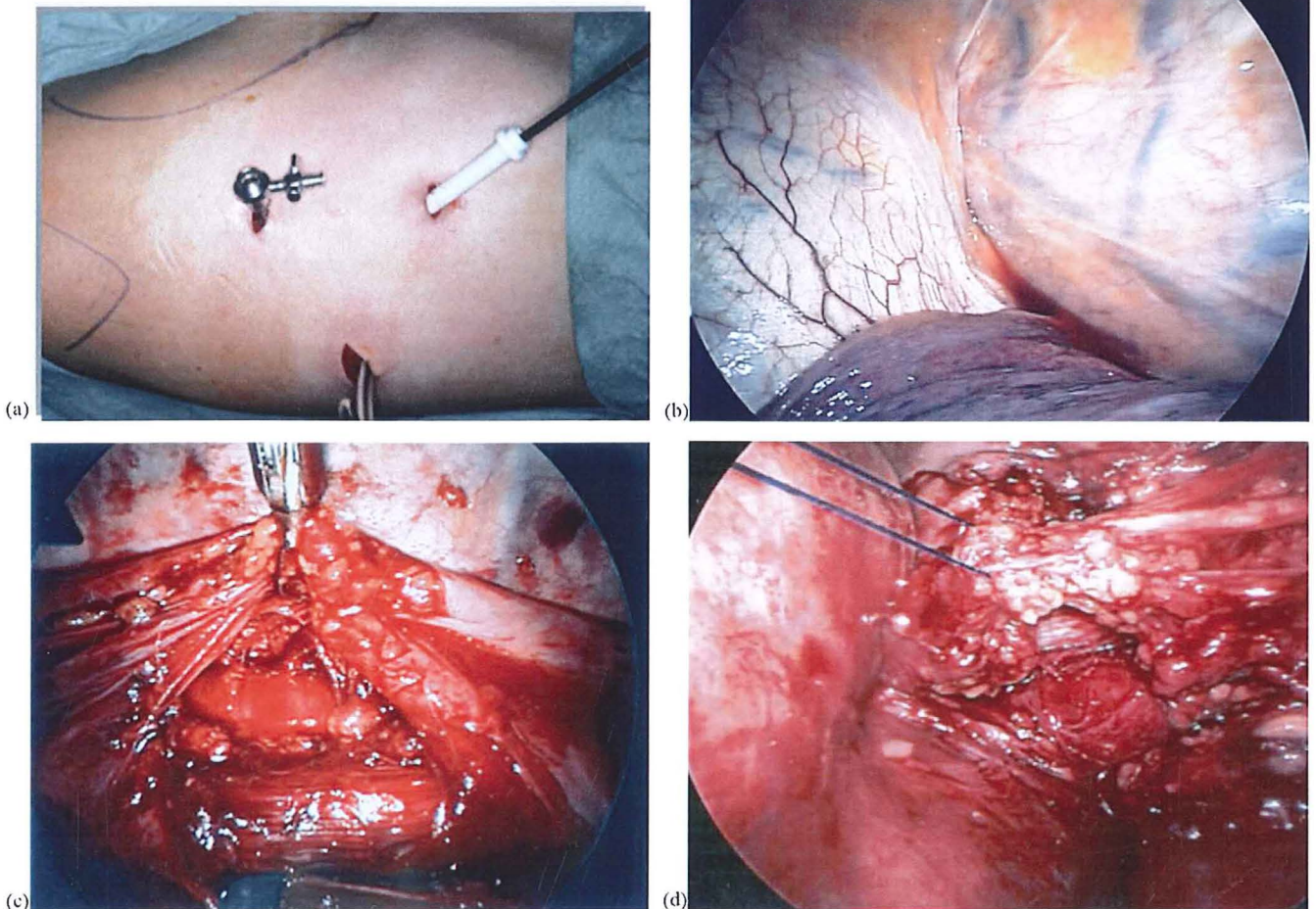


Fig. 1. Video-assisted right-sided supradiaphragmatic thoracic duct ligation for non-traumatic persistent or recurrent chylothorax; (a) positioning of two 7 mm trocars in the mid-axillary line at the levels of the 8th and 10th intercostal space, and a 4 cm incision at the posterior level of the 9th intercostal space; (b) visualisation and division of the pulmonary ligament; (c) division of the parietal pleura along azygous vein and the esophagus from the hiatus to the inferior pulmonary vein, dissection and medial retraction of the esophagus and dissection of the ventral part of the descending aorta; and (d) mass ligation of all fibro-fatty tissue between the azygous vein, the vertebral bodies, the esophagus and the aorta by three ligatures of 3-0 prolene®.

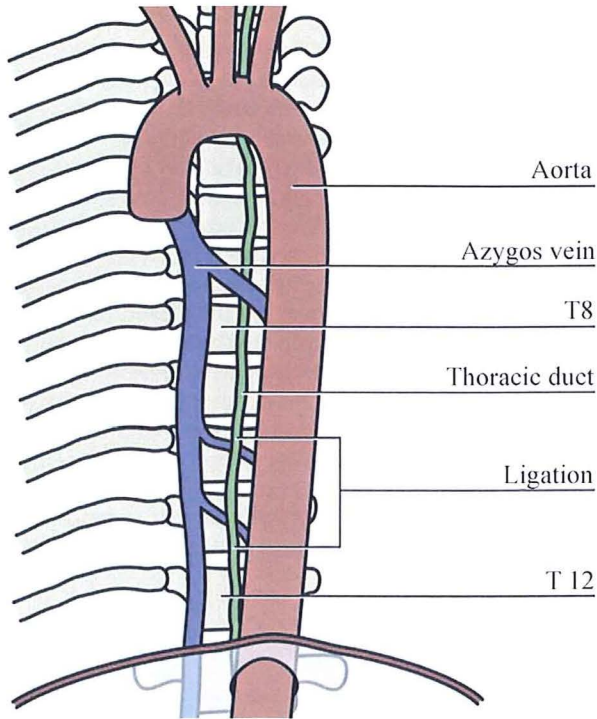


Fig. 2. Schematic drawing of video-assisted right supradiaphragmatic thoracic duct ligation. Mass ligation of all the fibro-fatty tissue between the oesophagus, the dorsal aspect of the aorta, the azygos vein and the vertebral bodies was performed by using three ligatures of non-resorbable 3-0 polypropylene (prolene®) at a distance of 2 cm each, beginning at the level of the diaphragm.

(Fig. 1d). Mass ligation of all the fibro-fatty tissue between the oesophagus, the dorsal aspect of the aorta, the azygos vein and the vertebral bodies was performed by using three ligatures of non-resorbable 3-0 polypropylene (prolene®) at a distance of 2 cm each, beginning at the level of the diaphragm (Fig. 2). An endoscopic device was used for this purpose. Chest tube drainage (28F) was performed after removal of the thoracoports. Oral feeding without dietary restriction was started at postoperative day 1.

3. Results

The patient's demographics and characteristics are summarised in Table 1. A right-sided chylothorax was seen in four patients, a left-sided in one, and a bilateral in one.

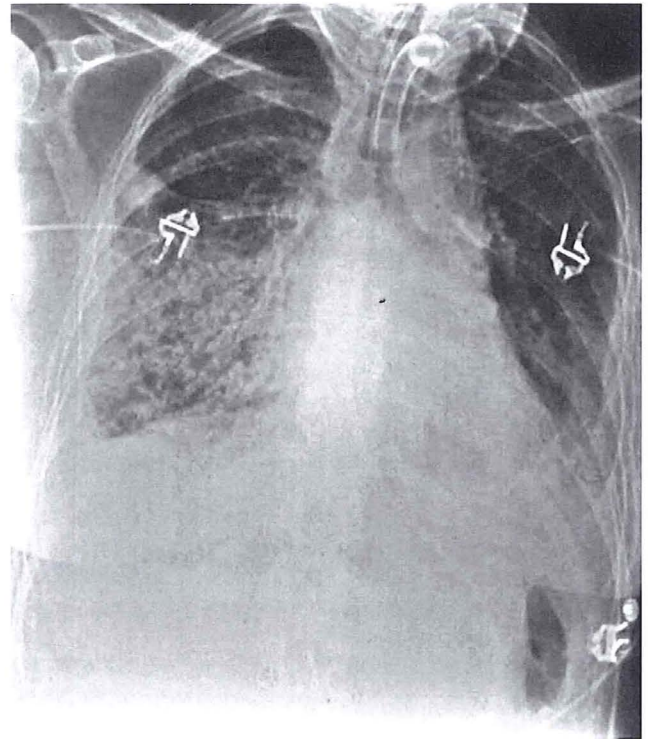


Fig. 3. Postoperative chest X-ray of patient 1 who developed respiratory insufficiency due to infiltration of the right lower lobe and chylous bronchorrhoe after successful video-assisted thoracic duct ligation.

Three patients developed a chylothorax after chemotherapy and chest irradiation for malignant diseases (lymphoma in two patients and breast cancer in one), one in the context of lymphangioleiomyomatosis, one due to a non-diagnosed lymphoma, and one after heart transplantation. The duration of chylothorax before thoracic duct ligation ranged from 7 to 14 days.

The mean operative time was 102 min (range 50–140 min) and the average hospitalisation time was 14 days (range 8–28 days). No perioperative complications were observed in patients with a left-sided chylothorax treated by video-assisted right supradiaphragmatic thoracic duct ligation. The mean time of chest tube drainage was 7 days ranging from 6 to 10 days. Immediate cessation of chylous fluid secretion was observed in 5/6 patients despite the fact that the patients had eaten normally starting at postoperative day 1, without any

Table 1
Patient's characteristics and postoperative results after video-assisted right-sided supradiaphragmatic thoracic duct ligation

| Patient number | Age (years) | Sex | Cause | Side | Operative time (min) | Drainage (days) | Recurrence | Complications |
|----------------|-------------|-----|---------------------|-------|----------------------|-----------------|---------------------|---------------------------|
| 1 | 51 | F | RT-CHT ^a | l + r | 140 | 10 | – | Respiratory insufficiency |
| 2 | 51 | F | RT-CHT ^b | l | 130 | 6 | – | – |
| 3 | 42 | M | RT-CHT ^c | r | 50 | 6 | – | – |
| 4 | 57 | M | Heart TX | r | 88 | 10 | – | – |
| 5 | 49 | M | LAM ^d | r | 100 | 7 | – | – |
| 6 | 57 | F | Lymphoma | l | 70 | 8 | Day 8, re-operation | – |

^a Mediastinal irradiation and chemotherapy for lymphoma 20 years ago.

^b Chest wall irradiation and chemotherapy for breast cancer 15 years ago.

^c Chest wall irradiation and chemotherapy for breast cancer 15 years ago.

^d Pulmonary lymphangioleiomyomatosis.

diet or restriction. One patient was re-operated by right-sided thoracotomy on day 8 postoperatively due to persistent chylothorax. The revisited chest revealed enlarged lymph nodes along the posterior lower mediastinum consistent with malignant lymphoma on frozen section examination. Mass ligations were performed using 2-0 mersilene® sutures at three different levels through thoracotomy, which was followed by cessation of chylous drainage within 2 days. There was no 90-day postoperative morbidity in 4/6 patients. One patient (status post radiochemotherapy for mediastinal lymphoma) developed postoperative infiltration of the right lower lobe associated with chylous bronchorrhoe and respiratory insufficiency requiring tracheotomy and mechanical ventilation without recurrent chylothorax (Fig. 3). Another patient (status post heart transplantation) developed a chylous ascites on postoperative day 10 without recurrent chylothorax and treated by a Le Vein peritoneo-venous shunt. No recurrent pleural effusion was observed in any patient during a mean follow-up time of 41 months.

4. Discussion

Non-traumatic, non-postoperative chylothorax may be addressed for surgery in case of recurrence or persistence despite adequate conservative management [1,2,5]. Medical treatment of a chylothorax related to malignancies is associated with a significant failure rate due to direct infiltration, external compression or rupture of the thoracic duct by the underlying disease [1,6]. The indications for a surgical approach consist of an average daily chylous loss exceeding 1500 ml in adults or 100 ml per year of age in children for a 5-day period, and a continuous drainage of chyle over a period of 14 days of conservative management [1,2,7,22]. Timing of surgery is still a matter of debate and various surgical procedures have been described. Supradiaphragmatic mass ligation of the thoracic duct through right-sided thoracotomy is generally considered as the modality of choice in the absence of signs of restriction and entrapped lung by a thickened pleural peel on chest CT [2,4,20,23]. The disadvantage consists of the morbidity related to thoracotomy performed in frail and malnourished patients.

It has been demonstrated that thoracic duct ligation may be successfully performed by using video-assisted thoracoscopy in order to avoid a thoracotomy, with apparently lesser postoperative pain, shorter recovery time and hospital stay [9–21]. However, this technique has not gained wide acceptance at date due to the rarity of this intervention. Only few reports relying mainly on anecdotal observations have been published [9–21]. Various procedures have been described for this purpose including ligation, stapling or clipping of the thoracic duct, or fibrin glue application in order to achieve pleurodesis [12–17]. The main advantage of this technique is the avoidance of thoracotomy, which may result in lesser reluctance of physicians towards a surgical approach, quicker referral for surgery and as a consequence, a decreased morbidity related to chylous loss.

Our results emerging from a small series of patients with recurrent or persisting non-traumatic chylothorax undergoing video-assisted thoracic duct ligation endorse the results of previous reports. The procedure is safe and efficient provided

there are no restriction or entrapment of the lung by a chronic pleural peel underlining the importance of preoperative assessment by chest CT scan. All patients in our series underwent right-sided supradiaphragmatic mass ligation of the fibro-fatty tissue between azygous vein, esophagus, descending aorta and vertebral bodies irrespective of the side of chylothorax [22–25]. Individual dissection and ligation of the thoracic duct bears the risk of missing anatomic variations and duplications of the thoracic duct during surgery which may occur in as much as 40% of the patients [25].

The majority of our patients revealed a low operation time, duration of chest tube drainage and hospitalisation, and no postoperative morbidity. Patients with a left-sided chylothorax treated by a video-assisted right supradiaphragmatic thoracic duct ligation did equally as well as those with a right-sided chylothorax. No recurrence was observed in 5/6 patients after a mean follow-up time of 41 months. However, one patient with lymphoma situated in the posterior aspect of the mediastinum revealed a persistent chylothorax after video-assisted thoracic duct ligation with cessation after a redo-operation through thoracotomy. One patient developed postoperative respiratory insufficiency due to right lower lobe infiltration and chylous bronchorrhoe, which required prolonged mechanical ventilation and tracheostomy although there was no residual pleural effusion after duct ligation. This patient developed right-sided chylothorax several years after radiochemotherapy for mediastinal lymphoma. Another patient developed chylous ascites after successful thoracic duct ligation for chylothorax occurring after heart transplantation. These observations underline the somewhat unpredictable and poorly interpretable course after surgical interventions for non-traumatic or non-postoperative lymphatic disorders.

Our results demonstrate that video-assisted right-sided supradiaphragmatic thoracic duct ligation offers rewarding long-term results for the treatment of recurrent or persistent non-traumatic and non-operative chylothorax, irrespective of the side of its manifestation and its underlying cause. The main advantage of the VATS approach is its low morbidity in already debilitated patients, which may result in better acceptance of surgery for this disorder and earlier referral for surgical intervention.

References

- [1] Valentine VG, Raffin TA. The management of chylothorax. *Chest* 1992;102:586–91.
- [2] Marts BC, Naunheim KS, Fiore AC, Pennington G. Conservative versus surgical management of chylothorax. *Am J Surg* 1992;164:532–4.
- [3] Browse NL, Allen DR, Wilson NM. Management of chylothorax. *Br J Surg* 1997;84:1711–6.
- [4] Romero S. Nontraumatic chylothorax. *Curr Opin Pulm Med* 2000;6:287–91.
- [5] Fahimi H, Casselmann FP, Mariani MA, van Boven WJ, Knaepen PJ, van Swieten HA. Current management of postoperative chylothorax. *Ann Thorac Surg* 2001;71:448–51.
- [6] O'Callaghan AM, Mead GM. Chylothorax in lymphoma: mechanisms and management. *Ann Oncol* 1995;6:603–7.
- [7] Murphy MC, Newman BM, Rodgers BM. Pleuroperitoneal shunts in the management of persistent chylothorax. *Ann Thorac Surg* 1989;48:195–200.
- [8] Lampson RS. Traumatic chylothorax: a review of the literature and report of a case treated by mediastinal ligation of the thoracic duct. *J Thorac Surg* 1948;17:778–91.

- [9] Daniel TM, Kern JA, Tribble CG, Kron IL, Spotniz WB, Rodgers BM. Thoracoscopic surgery for diseases of the lung and pleura. Effectiveness, changing indications and limitations. *Ann Surg* 1993;217:566–75.
- [10] Ferguson MK. Thoracoscopy for empyema, bronchopleural fistula, and chylothorax. *Ann Thorac Surg* 1993;56:644–5.
- [11] Graham DD, Mc Gahren ED, Tribble CG, Daniel TM, Rodgers BM. Use of video-assisted thoracic surgery in the treatment of chylothorax. *Ann Thorac Surg* 1994;57:1507–12.
- [12] Shirai T, Amano J, Takabe K. Thoracoscopic diagnosis and treatment of chylothorax after pneumonectomy. *Ann Thorac Surg* 1991;52:306–7.
- [13] Inderbitzi RG, Krebs T, Stirnemann P, Althaus U. Treatment of post-operative chylothorax by fibrin glue application under thoracoscopic view with the use of local anesthesia. *J Thorac Cardiovasc Surg* 1992;104:209–10.
- [14] Kent RB, Pinson TW. Thoracoscopic ligation of the thoracic duct. *Surg Endosc* 1993;7:52–3.
- [15] Zoetmulder F, Rutgers E, Baas P. Thoracoscopic ligation of a thoracic duct leakage. *Chest* 1994;106:1233–4.
- [16] Janssen JP, Joosten HJM, Postmus PE. Thoracoscopic treatment of post-operative chylothorax after coronary bypass surgery. *Thorax* 1994;49:1273.
- [17] Crosthwaite GL, Joypaul BV, Cuschieri A. Thoracoscopic management of thoracic duct injury. *J R Coll Surg Edinb* 1995;40:303–4.
- [18] Furrer M, Hopf M, Ris HB. Isolated primary chylopericardium: treatment by thoracoscopic thoracic duct ligation and pericardial fenestration. *J Thorac Cardiovasc Surg* 1996;112:1120–1.
- [19] Peillon C, D'Hont C, Melki J, Fattouh F, Perrier G, Dujon A, Testart J. Usefulness of video thoracoscopy in the management of spontaneous and postoperation chylothorax. *Surg Endosc* 1999;13:1106–9.
- [20] Stringel G, Teixeira JA. Thoracoscopic ligation of the thoracic duct. *JSLs* 2000;4:239–42.
- [21] Buchan KG, Hosseinpur AR, Ritchie AJ. Thoracoscopic thoracic duct ligation for traumatic chylothorax. *Ann Thorac Surg* 2001;72:1366–7.
- [22] Selle JG, Snyder III WH, Schreiber JT. Chylothorax: indications for surgery. *Ann Surg* 1973;177:245–9.
- [23] Patterson GA, Todd TRJ, Delarue NC, Ilies R, Pearson FG, Cooper JD. Supradiaphragmatic ligation of the thoracic duct in intractable chylous fistula. *Ann Thorac Surg* 1981;32:44.
- [24] Milsom JW, Kron IL, Rheuban KS, Rodgers BM. Chylothorax: an assessment of current surgical management. *J Thorac Cardiovasc Surg* 1985;89:221.
- [25] Malthaner RA, Inculet RI. Minithoracoscopy for pleural effusions. *Can Respir J* 1998;5(4):253–4.