

LARYNGOLOGY

# Outcomes of balloon dilation for paediatric laryngeal stenosis

## *Il balloon nel trattamento delle stenosi laringee in età pediatrica*

Giovanna Cantarella<sup>1,2</sup>, Michele Gaffuri<sup>2</sup>, Sara Torretta<sup>1,2</sup>, Simona Neri<sup>3</sup>, Maria Teresa Ambrosini<sup>3</sup>, Alessandra D'Onghia<sup>1,2</sup>, Lorenzo Pignataro<sup>1,2</sup>, Kishore Sandu<sup>4</sup>

<sup>1</sup>Fondazione IRCCS Ca' Granda Ospedale Maggiore Policlinico, Department of Otolaryngology and Head and Neck Surgery, Milan, Italy; <sup>2</sup>Department of Clinical Sciences and Community Health, University of Milan, Milan, Italy; <sup>3</sup>Unit of Pediatric Anesthesiology and Intensive Care, Fondazione IRCCS Ca' Granda Ospedale Maggiore Policlinico, Milan, Italy; <sup>4</sup>Airway Sector; Department of Otolaryngology, Lausanne University Hospital CHUV, Switzerland

### SUMMARY

**Objective.** Balloon dilation (BD) is a minimally invasive endoscopic treatment for paediatric laryngeal stenosis (LS) with reduced morbidity compared to open surgery. We retrospectively describe our experience in a cohort of children with chronic LS.

**Methods.** Fourteen children (median age: 28.5; range: 2-81 months) with chronic LS (multilevel in 8) were treated with tubeless total intravenous anaesthesia under spontaneous ventilation.

**Results.** Grade III LS was preoperatively detected in 12 children; the remaining 2 had grade IV stenosis. Six had prior tracheotomy, and one received it during the first intervention. Dilation laryngoplasty was the primary treatment in 11 children and was used as an adjuvant treatment in 3 after open reconstructive surgery. The median number of dilations was 2 (range: 1-6). There were no postoperative complications. At the end of the follow-up (median: 20.5; range: 2-46 months), detectable laryngeal lumen widening and/or respiratory improvement occurred in 12 children. Two of 7 patients with tracheostomy were decannulated.

**Conclusions.** Balloon laryngoplasty is a valuable therapeutic option to improve laryngeal patency in children with chronic multilevel LS, both as a primary and secondary adjuvant treatment after reconstructive surgery.

**KEY WORDS:** balloon dilation, paediatric, laryngeal stenosis, dyspnea, children

### RIASSUNTO

**Obiettivi.** Descrivere retrospettivamente la nostra esperienza con dilatazione laringea con balloon (DB) per il trattamento della stenosi laringea (SL) cronica in età pediatrica.

**Metodi.** Quattordici bambini (età mediana: 28,5; range: 2-81 mesi) con SL cronica (multilivello in 8 casi) sono stati sottoposti a DB in ventilazione spontanea in assenza di intubazione orotracheale con anestesia endovenosa esclusiva.

**Risultati.** Dodici bambini presentavano pre-operatoriamente una SL di grado III, i rimanenti una SL di grado IV. Sei pazienti erano portatori di tracheotomia mentre un paziente è stato sottoposto a tracheotomia durante la prima DB. La DB è stata eseguita come trattamento primario in 11 bambini e come adiuvante a chirurgia ricostruttiva in 3 casi. Il numero mediano di BD eseguite è 2 (range: 1-6). Non si sono verificate complicanze post-operatorie e, al termine del follow-up (mediana: 20,5; range: 2-46 mesi), in 12 bambini è stato obiettivato un ampliamento del lume laringeo e/o un miglioramento respiratorio. Due dei 7 pazienti con tracheotomia sono stati decannulati con successo.

**Conclusioni.** La DB risulta efficace e sicura per migliorare in bambini con SL cronica multi-livello sia come trattamento primario che come trattamento adiuvante.

**PAROLE CHIAVE:** dilatazione con balloon, pediatria, stenosi laringea, dispnea, bambini

Received: May 5, 2020

Accepted: July 28, 2020

### Correspondence

Sara Torretta

Department of Clinical Sciences and Community Health, Università degli Studi di Milano, Fondazione IRCCS Cà Granda Ospedale Maggiore Policlinico, Via F. Sforza 35, 20122 Milano, Italy  
Tel. +39 02 50320245. Fax +39 02 50320248  
E-mail: sara.torretta@unimi.it

### Funding

None.

### Conflict of interest

The Authors declare no conflict of interest.

**How to cite this article:** Cantarella G, Gaffuri M, Torretta S, et al. Outcomes of balloon dilation for paediatric laryngeal stenosis. *Acta Otorhinolaryngol Ital* 2020;40:360-367. <https://doi.org/10.14639/0392-100X-N0830>

© Società Italiana di Otorinolaringoiatria e Chirurgia Cervico-Facciale



OPEN ACCESS

This is an open access article distributed in accordance with the CC-BY-NC-ND (Creative Commons Attribution-Non-Commercial-NoDerivatives 4.0 International) license. The article can be used by giving appropriate credit and mentioning the license, but only for non-commercial purposes and only in the original version. For further information: <https://creativecommons.org/licenses/by-nc-nd/4.0/deed.en>

## Introduction

Laryngeal stenosis (LS) in neonatal and paediatric age groups is a potentially life-threatening condition and has a severe impact on the quality of life of children and families. It can be congenital or acquired, but the latter is most frequent, mainly due to prolonged endotracheal intubation in neonatal intensive care for severe prematurity<sup>1,2</sup>. The most commonly involved sites in LS are the subglottis and the posterior glottis, as the cricoid, the medial aspects of the arytenoid cartilage and the posterior commissure are the areas in the airway with a major risk of developing intubation injuries<sup>1</sup>.

Three main types of procedures have been proposed to treat established cicatricial LS: expansion of the airway with costal cartilage, resection of the stenotic part of the airway and dilation by means of rigid dilators or by inflatable balloons. Balloon dilation (BD) has been proposed since 1984 to treat tracheal and bronchial stenoses and is appropriate only if the cartilaginous skeleton of the airway is preserved. A balloon is used under direct endoscopic vision and allows the application of radial pressure on the airway stricture, thus theoretically reducing the risk of shearing the mucosa with consequent possible restenosis.

Recently, there has been an increase in the number of reports highlighting the important role of balloon laryngoplasty in avoiding tracheotomy in acute and subacute airway obstruction and in improving airway patency in immature or mature scarring with limited extension and thickness<sup>4,5</sup>. The procedure is minimally invasive and can avoid the intra- and postoperative risks of major reconstructive surgery.

This paper aims to retrospectively describe our experience with BD in a cohort of children affected by LS. The peculiarity of the described series is related to the extension of stenosis - multilevel in most cases - and to the chronic nature of the lesion, as the majority of patients were symptomatic for several months or years.

## Materials and methods

### *Study design and setting*

This study is a retrospective chart review of prospectively recruited children with LS, and it was carried out at the Otolaryngology Division of Milan University's Department of Clinical Sciences and Community Health in December 2019.

The protocol was approved by our local Ethics Committee of Fondazione IRCCS Ca' Granda Ospedale Maggiore Policlinico and was conducted in accordance with the principles of good clinical practice.

### *Study subjects*

The study involved the charts of children who had been treated with BD for chronic LS between February 2016 and October 2019. All patients underwent endoscopic treatment and subsequent postoperative follow-up in our tertiary outpatient clinic. The authors GC, MG and LP performed all the procedures with collaborative guidance of KS. All patients underwent transnasal flexible high-definition video laryngoscopies on their initial presentation and during follow-up visits.

The diagnosis of LS was confirmed by direct laryngotracheoscopy under general anaesthesia, and patients breathed spontaneously. The degree of LS before and after BD was scored according to the Myer-Cotton grading scale<sup>6</sup>.

LS was defined as chronic if symptoms were present for more than 3 months.

### *Interventions*

The retrospective chart review included demographic data and clinical histories. The clinical histories included all possible conditions predisposing to the development of LS, including prolonged intubation, intensive-care unit stay, prematurity, syndromic disease or defined genetic abnormalities, previous cardiac surgery and previous airway surgery. History of respiratory distress, stridor, voice impairment, failure to thrive, or swallowing impairment were recorded.

In the children without tracheotomy, BD was performed under tubeless total intravenous anaesthesia (TIVA) with spontaneous ventilation and supplemental oxygen administration dispensed by an uncuffed silicone endotracheal tube placed through the nasal fossa and left in the hypopharynx with its bevel facing the airway. A second similar uncuffed tube was prepared on a 2.7 mm Storz (Germany) rigid 0° endoscope ready to be used in case of the need for emergency intubation to allow rapid introduction under direct endoscopic vision. The anaesthetic technique was standardised as reported in Table I. Heart rate, blood pressure, pulse oximetry, Bispectral Index (BIS) level, transcutaneous CO<sub>2</sub> (TcCO<sub>2</sub>), respiratory rate and temperature were recorded intraoperatively.

Lidocaine was sprayed into the larynx under direct laryngoscopic vision at a dose of 2-4 mg/kg. Then, an appropriately sized Lindholm or Parson laryngoscope was placed to expose the larynx under suspension. First, a 0° rigid 2.7- or 4-mm telescope was introduced to examine the vocal cords, anterior and posterior commissures, subglottis, trachea, carina and mainstem bronchi. Once the stenosis was assessed, triamcinolone acetate (Kenacort<sup>®</sup> 40 mg/ml, Bristol-Myers Squibb s.r.l.) was injected into the stenotic and scarred areas. If concentric stenosis was found, 3-4 ra-

**Table I.** Description of the anaesthetic protocol for balloon dilation.

Anaesthetic procedures
Premedication: intranasal dexmedetomidine (3 mcg/kg), 30 minutes before the procedure
Mask induction with sevoflurane to for intravenous access placement
Anaesthetic maintenance with propofol (target-controlled infusion model; 3-4 mcg/ml) and remifentanyl (0.07-0.15 mcg/kg/min)
Propofol infusion titrated to a clinically adequate level of anaesthesia, guided by the BIS (target 40-60) and remifentanyl infusion titrated to respiratory rate (target >10 breaths per min) to avoid apnoea and desaturation
Careful laryngoscopy and 2% lidocaine spray to the vocal cords (2-4 mg/kg)
Supplemental oxygen administered through a Portex Blue Line tube positioned through a nostril into the hypopharynx
Propofol bolus to induce apnoea during balloon inflation, followed by hand-mask ventilation or endotracheal intubation until spontaneous breathing was resumed

dial incisions were performed using a microlaryngoscopy disposable sickle knife (Medtronic) mounted on a handle (Microfrance). In the case of posterior glottic stenosis, a single median sagittal incision was performed either by a sickle knife or by the digital AcuBlade CO<sub>2</sub> laser (Lumenis,

Superpulse). Next, an appropriately selected balloon was placed in the stenotic tract of the airway under direct telescopic or microscopic vision. An angioplasty balloon (Boston Scientific PTCA Dilatation Catheter) was utilised for the first 26 dilations, while the TRACOE Aeris® Balloon Dilation Catheter was available for the 4 dilations performed in cases 13 and 14. The balloon size was selected by adding 1 mm for the larynx and 2 mm for tracheal stenosis to the outer diameter of the age-appropriate endotracheal tube size for the patient<sup>7,8</sup>.

Balloon inflation was performed and maintained for 2 min or until oxygen saturation decreased to less than 90%. It was repeated 2-3 times for one min in patients who desaturated early. In cases of severe stenosis or fragile mucosa, the duration of each dilation was 20-30 sec to avoid mucosal shearing and/or development of an ischaemic lesion. In syndromic children, we used a balloon smaller than the age-appropriate balloon and reduced the dilation time to 20-30 sec for each inflation to minimise the risk of collateral mucosal damage under the assumption that a congenitally small cricoid might not safely tolerate an excessive or prolonged pressure that might cause cartilage damage.

**Table II.** Demographic and clinical characteristics of patients (Part I).

Case No.	Age (months)	Gender	Comorbidities	Previous surgery	Site of stenosis	Cause of stenosis
1	48	Male	Severe prematurity	No	Posterior glottis and subglottis	Acquired
2	76	Male	Severe prematurity	No	Subglottis and posterior glottis	Acquired
3	20	Male	Head, neck, chest burns	No	Subglottis	Acquired
4	30	Male	Down's syndrome	PCTR and LTR	Subglottis, glottis.	Mixed
5	27	Male	Severe prematurity	LTR	Glottis, subglottis	Acquired
6	81	Male	Prematurity	No	Subglottis	Acquired
7	14	Male	Prematurity	Endoscopic surgery	Glottis, subglottis	Mixed
8	7	Female	Genetic disease with multiple malformations	No	Subglottis	Acquired
9	51	Male	Severe prematurity -	LTR	Glottis, subglottis, and trachea	Acquired
10	6	Male	Down's syndrome and previous cardiac surgery	No	Subglottis	Mixed
11	20	Male	Severe prematurity	No	Glottis and subglottis	Mixed
12	64	Female	Down's syndrome. and previous cardiac surgery	No	Subglottis	Mixed
13	2	Male	DiGeorge syndrome	No	Glottis	Mixed
14	43	Male	Severe prematurity	No	Glottis and subglottis	Acquired

PCTR: partial cricotracheal resection; LTR: laryngotracheal reconstruction; EPCTR: extended partial cricotracheal resection. \* according to the Myer-Cotton classification<sup>6</sup>; \*\* no longer dependent on noninvasive ventilation.

Noninvasive ventilation (CPAP) was given in the immediate postoperative period along with temporary adrenaline and budesonide aerosols. Dexamethasone (1 mg/kg), cefazoline (25 mg/kg) and proton pump inhibitors were administered in the operating room and were continued during the postoperative period. Children were admitted to the paediatric intensive care unit for at least one night after the surgery. If additional dilations were needed, repeated procedures were performed at 2-6-week intervals.

The effectiveness of the procedure was defined by three main outcome measures:

- Stable improvement of airway patency with a reduction in the grade of stenosis according to the Myer-Cotton grading scale
- Clinical improvement and use of a phonatory valve that was not possible prior to dilation
- Decannulation or tolerating a fully capped tracheostomy cannula

#### Statistical analysis

Descriptive statistics were used to summarise the demographic and clinical characteristics of patients. The results

are given as absolute numbers and percentages or median values with ranges.

## Results

This case series comprised 14 children – median age: 28.5 months, range: 2-81 months; 12 boys and 2 girls; and 8 (57.1%) patients with severe prematurity and 5 (35.7%) with syndromic or genetically-defined disease. Patients had a history of prolonged intubation for severe prematurity (8/14, 57.1%), respiratory distress at birth (3/14, 21.4%), previous cardiac surgery (2/14, 14.3%) and severe burns extending to the lower face, neck and chest (1/14, 7.1%). The detailed demographic and clinical characteristics are reported in Table II. Dilation laryngoplasty was the primary treatment in 11 children; among them, acquired LS was documented in 8, while mixed-type stenosis was found in 3 syndromic children (cases 10, 12, 13). A congenital membranous glottic web (Cohen type 2)<sup>9</sup> affected case 13, but his stenosis became symptomatic after intubation for cardiac surgery (ventricular septal defect correction), adding mild acquired stenosis to the existing congenital stenosis. He was treated with sickle knife lysis of the web, followed by dilation. In 3

**Table II.** Demographic and clinical characteristics of patients (Part II).

Type of treatment	Pre-op. grade of stenosis*	No. of endoscopic treatments	Post-op. grade of stenosis*	Tracheotomy		Clinical condition after treatment	Follow-up (months)
				Predilation	Post dilation		
Primary	III	2	I	Yes	No	Asymptomatic	25
Primary	III	2	I	No	No	Mild fatigue at maximal effort	25
Primary	III	1	I	No	No	Asymptomatic	16
Adjuvant	III	2	III	Yes	Yes	Phonatory valve	19
Adjuvant	III	3	II	Yes	No	Asymptomatic	46
Primary	III	1	I	No	No	Asymptomatic	45
Primary	III	1	III	Yes	Yes	Requires EPCTR	42
Primary	III	1	I	No	No	Asymptomatic	25
Adjuvant	IV	6	III	Yes	Yes	Phonatory valve 24 h	22
Primary	IV	3	III	Yes	Yes	Phonatory valve (daytime)	12
Primary	III	2	III	No	Yes	Phonatory valve (daytime)	13
Primary	III	2	I	No	No	Asymptomatic	6
Primary	III	3	I	No	No	Improved <sup>++</sup>	6
Primary	III	1	II	No	No	Improved <sup>++</sup>	2

PCTR: partial cricotracheal resection; LTR: laryngotracheal reconstruction; EPCTR: extended partial cricotracheal resection. \* according to the Myer-Cotton classification<sup>6</sup>; <sup>++</sup> no longer dependent on noninvasive ventilation.

children, balloon laryngoplasty was an adjuvant treatment following reconstructive surgery (Tab. II).

Grade III LS was preoperatively detected in 12 of 14 (85.7%) children; the remaining 2 patients presented with grade IV stenosis. In one case of grade IV stenosis, a Down's syndrome patient had a cranio-caudal length of 3 mm and was affected by mixed-type stenosis; in the other patient, recurrence of grade IV stenosis was observed with a size of approximately 5 mm after a second attempt at airway expansion by cartilage grafts. Two patients with grade III stenosis and 1 patient with grade IV stenosis had previously undergone major surgical treatment (laryngotracheal reconstruction in 2 cases and partial cricotracheal resection followed by laryngotracheal reconstruction in 1 case). In most treated patients (8/14, 57.1%), multiple sites of obstruction were detected.

A total of 30 dilation procedures were performed; the median number of dilation procedures was 2 (range: 1-6). Only in one child (No. 11), affected by severe grade III glotto-subglottic stenosis, was a tracheotomy performed on the day of his first dilation to establish a secure distal airway. All the other dilation procedures were well tolerated without any immediate or late complications. We continued to use BD only if we found that there was clinical and endoscopic improvement compared to prior the endoscopy.

Postoperatively, the patients had a median follow-up of 20.5 months, ranging from 2-46 months. Residual grade I LS was documented in 8 of 14 (57.1%) patients; grade II and grade III LS were found in 1 (7.1%) and 5 (45.4%) patients, respectively. Follow-up laryngoscopy showed a low-

er grade of LS in 11 patients (78.6%). In 2 of the remaining 3 children, subjective improvement occurred, and these children currently tolerate the use of a phonatory valve over a down-sized cannula.

Six children had an initial tracheotomy, and one was tracheotomised at the time of the first dilation (Tab. III). Two were decannulated (cases No. 1 and 5) after BD, and 5 remained tracheotomised. The benefit achieved by BD procedures in cases No. 4, 9, 10 and 11 did not allow decannulation but the use of a phonatory valve was tolerated all day long. Case 7 had no benefit at all: he was an extremely premature child with severe multilevel fibrotic stenosis resulting from several endoscopic laser procedures performed elsewhere. After failing BD, he underwent a successful reconstructive procedure with subsequent decannulation. A detailed description of the clinical characteristics and outcomes in the subset of tracheotomised patients is reported in Table III.

BD laryngoplasty established a clearly detectable widening of the laryngeal lumen and respiratory improvement in 12 (85.7%) of the 14 children.

Figures 1-3 show the results achieved in 3 patients.

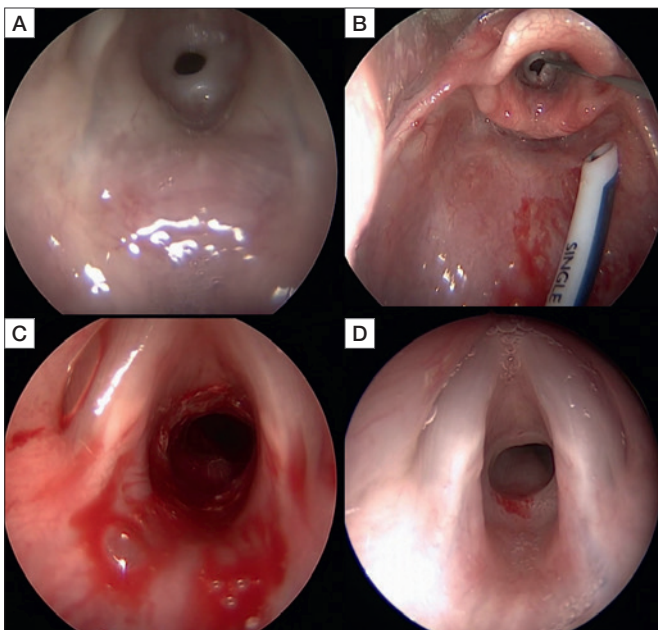
## Discussion

The use of BD is becoming progressively widespread in several surgical fields and is considered a valid and minimally invasive alternative to major open surgical procedures. The morbidity associated with airway dilation is low

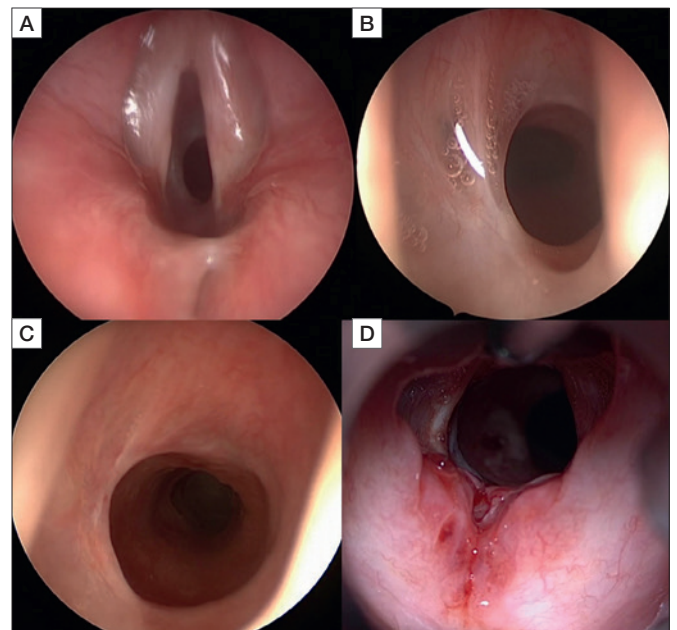
**Table III.** Detailed description of clinical characteristics and outcomes in the subset of tracheotomised patients.

Case No.	Comorbidities	Previous procedures (elsewhere)	Clinical staging* (before balloon dilation)	Outcome
1	Severe prematurity	Multiple unsuccessful decannulation attempts (elsewhere)	Multisite grade III LS	Decannulated
4	Down's syndrome	PCTR; LTR	Multisite grade III LS	Non-decannulated but using phonatory valve
5	Severe prematurity	Approximately 18 endoscopic laser procedures (elsewhere); LTS	Multisite grade III LS	Decannulated
7	Severe prematurity	Multiple endoscopic laser procedures (elsewhere)	Multisite grade III LS	Decannulated after reconstructive procedure
9	Severe prematurity	2 LTRs (1 elsewhere)	Multisite grade IV LS	Non-decannulated but using phonatory valve
10	Down's syndrome and cardiac surgery	Multiple unsuccessful extubation attempts (elsewhere)	Subglottic grade IV LS	Non-decannulated but using phonatory valve
11	Severe prematurity and prolonged endotracheal intubation	Multiple unsuccessful extubation attempts (elsewhere)	Multisite grade III LS	Tracheotomy at the first dilation; non-decannulated but using phonatory valve. Waiting for reconstructive surgery

LS: laryngeal stenosis; PCTR: partial cricotracheal resection; LTR: laryngotracheal reconstruction; \* according to the Myer-Cotton classification<sup>6</sup>.



**Figure 1.** A: Grade III subglottic stenosis in a 20-month-old male intubated with several failed attempts of extubation elsewhere, due to diffuse burns to head, neck and chest. B: Radial incisions of the concentric stenosis. Note the naso-oropharyngeal tube. C: Laryngoscopic view soon after dilation. D: Laryngoscopy performed 4 months later shows a stable scar and a sub-optimal airway.

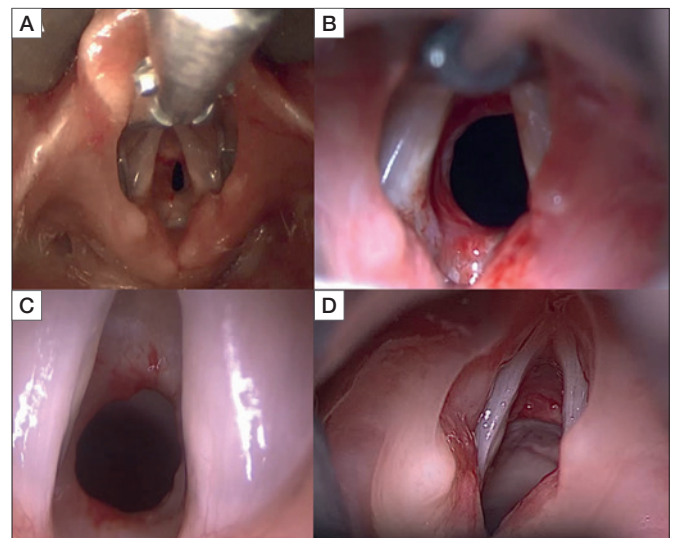


**Figure 2.** Multilevel obstruction in a 76-month-old male, severe prematurity, with a history of prolonged invasive ventilation. A: Posterior glottic stenosis due to inter-arytenoid scarring and associated subglottic stenosis. B: View of the subglottic stenosis. C: Subglottic result achieved after a single dilation, a second dilation is performed together with median incision of the posterior glottic scar, and intralesional injection of triamcinolone; D: final result.

if the procedure is cautiously performed and if the indications and contraindications are correctly respected<sup>4,5,9-11</sup>.

In our opinion, BD is mainly indicated for grade I-III stenosis (Cotton-Myer classification) and in rare cases of thin diaphragm-like grade IV stenosis. Conversely, long and thick stenoses, narrow congenital cricoid malformations, associated airway malacia, inflammation and multi-site dense stenoses require open operations such as airway expansion (laryngotracheal reconstruction with cartilage grafts) or airway resection and anastomosis (cricotracheal resection-CTR or an extended CTR); BD can be used as a complementary procedure to enhance open surgical results. Reconstructed multi-planar 3-D CT scans can be useful in multi-site airway stenosis. However, precise interpretation of laryngotracheal stenosis on CT scan in small children can be challenging.

A dedicated dynamic and rigid endoscopy is more valuable in detecting the exact site(s), length of the stenosis and extent of remaining normal trachea<sup>17</sup>. The quality of airway mucosa is critical and a CT scan cannot detect this information. Additionally, stagnated secretions at the stenotic sites will exaggerate the stenosis. We prefer doing CT/MRI scan in cervico-mediastinal vascular anomalies, though virtual bronchoscopy could be useful in complete airway stenosis that will not allow passing of endoscopes.



**Figure 3.** Multilevel obstruction in a 64-month-old female, affected by Down syndrome, with prior history of cardiac surgery. A: Subglottic mixed type concentric stenosis and posterior glottic stenosis. B: Immediate result after radial incisions of the stenosis and dilation by 6 mm balloon. C: Laryngoscopic view 4 weeks later showing that the improvement in patency is maintained; a second incision and dilation treatment with 8 mm balloon is performed; D: final result.

Most patients with correct selection criteria can undergo laryngeal BD without needing tracheotomy. In our series,

only one of the 8 non-tracheotomised patients (a child with a history of severe prematurity, affected by severe stridor and chest retractions at rest) needed a tracheotomy on the day of his first dilation. All the remaining 7 patients underwent dilation procedures without tracheotomy, obtaining immediate and persistent improvements in airway patency; these patients are currently asymptomatic despite their comorbidities.

The type of anaesthesia adopted is of crucial importance for both diagnostic assessment and the endoscopic procedure, as spontaneous breathing under intravenous anaesthesia provides an unobstructed surgical field and excellent evaluation of the dynamic airway function and the grades of obstruction. We strongly advocate the use of noninvasive ventilation in the immediate postoperative period. The continuous airway pressure acts like a pneumatic stent and promotes satisfactory airway epithelisation.

Eight of our patients had a history of severe prematurity. Recent advances in neonatal care have greatly improved the survival rates of premature infants who often require intubation and mechanical ventilation. Currently, only a small percentage of intubated babies develop LS, although the majority of paediatric LS cases are acquired because of prolonged intubation (Figs. 1,2).

LS can be associated with some syndromes, and its treatment may be challenging if comorbidities are severe. One of the 8 patients without tracheotomy in our series was affected by 22q11 microdeletion syndrome. He needed noninvasive ventilation without oxygen supplementation for several months after dilation, as two previous thoracotomies for cardiac surgery subsequently weakened his chest wall.

Most of the current literature regarding airway BD claims the efficacy of BD mainly in cases of acute/subacute stenosis<sup>12-15</sup> or membranous chronic stenosis with limited vertical extension. In both cases, a prerequisite for a successful procedure is the integrity of the cartilaginous laryngotracheal skeleton. Our small series suggests that the dilation procedure can be safely attempted in carefully selected cases of acquired or congenital LS and that a minor congenital subglottic malformation might not be an absolute contraindication. It is known that Down's syndrome might be associated with underdevelopment and/or malformation of the cricoid cartilage<sup>16</sup> with consequent airway narrowing. The frequent association of heart defects in these patients will prompt early cardiac surgery, and the subsequent prolonged intubation will add oedema and/or scar tissue, thus worsening congenital stenosis. This was the case in 2 of our patients affected by Down's syndrome. Despite congenital stenosis, cautious dilation might solve the acquired component, significantly im-

proving airway patency. A small hypoplastic cricoid and severe hypertrophy of subglottic submucosal glands with an added intubation insult respond best to cricotracheal resection and anastomosis<sup>17</sup>. Similarly, an elliptic cricoid malformation with minor intubation sequelae is best treated with cartilage graft(s) expansion cricoplasty<sup>17</sup>. In syndromic children, we used a balloon smaller in size than the age-appropriate balloon and reduced the dilation time to 20-30 seconds for each inflation to minimise the risk of mucosal ulceration and ischaemia, as a congenitally smaller cricoid might not safely tolerate excessive or prolonged pressure.

Our results, attesting to the effectiveness of BD in approximately 86% of children with chronic LS as both primary and adjuvant treatment, corroborate the results of previous studies. In particular, Wentzel et al.<sup>18</sup> in 2014 reported a success rate of 77% after BD in a cohort of 60 children, including 44 with subglottic stenosis; most of the cases were acquired after prolonged intubation. This result was further confirmed by a systematic literature review performed by the same authors<sup>18</sup>. The overall success rate, defined as symptomatic improvement, a decrease in the Myer-Cotton LS grade, decannulation, or the avoidance of reconstructive surgery, was slightly lower in their study (64%) than in ours.

More recently, Wenzel and coworkers<sup>4</sup> evaluated the impact of balloon laryngoplasty on the management of acute subglottic stenosis in 23 children and reported a success rate of approximately 83%. Tracheotomy was required in 3 patients, and open laryngotracheal reconstruction was required in one case.

The effectiveness of BD in mature severe laryngo (tracheal) stenosis has been previously documented in a small case series of 8 children and adolescents by Guarisco and Yang<sup>5</sup>, as an open surgical procedure was required in only one patient. They simultaneously applied laryngeal stenting in the 4 tracheotomised patients, who were all subsequently decannulated. None of the remaining patients required tracheotomy. In our opinion, an important factor that determines success after BD is the cranio-caudal length of LS, which has not been well elucidated in many publications. The vertical extent of the stenosis is calculated using a rigid, long and thin telescope that can go beyond the stenotic segment. The distal and proximal points of the stenosis are ink-marked on the telescope at the level of the incisor. The cranio-caudal length is then measured on a caliper ruler. In our opinion, any grade of thin diaphragm-like stenosis that is less than 5 mm in a non-collapsing airway could respond to BD, although this needs to be confirmed with prospective and larger multicentric studies. Open surgery must be considered when

there is no change or when there is progression of stenosis after 1-3 trials of BD, as well as in cases of severe cartilage malformations. It is difficult to decide the appropriate period when adjuvant BD can be performed safely after an open neck surgery. At the senior authors' institution, BD is done only after 6 weeks following laryngotracheal reconstruction or cricotracheal resection and anastomosis. We did not find any difference between the angioplasty balloons and the Tracoe balloon. However, our experience with the Tracoe Aeris balloon is not sufficient to make any definite conclusions.

The importance of choosing patients wisely, of adequate training in endoscopy and all types of open airway surgeries, of anesthesia strategies and of postoperative management cannot be overemphasised. The first choice of treatment, whether endoscopic or open, is the best chance to cure patients with LS. Additional collateral damage due to a wrongly chosen intervention might worsen the original stenosis and should be avoided. Surgical treatment of LS must be tailored depending on the patient's clinical condition, including the grade and type of stenosis and the presence of concomitant disease. Complex, multi-site stenosis with additional cricoarytenoid ankyloses is best treated by open approaches<sup>17</sup>.

An important limitation of our study is the relatively small number of patients. Nevertheless, to the best of our knowledge, this is the first Italian report on the systematic use of BD laryngoplasty for treating paediatric LS. The present results encourage the use of BD as a primary or adjuvant treatment to obtain adequate patency of the airway with the aim of avoiding tracheotomy when feasible and reducing the necessity of major reconstructive surgery.

## Conclusions

Our results confirm the efficacy of BD as a minimally invasive technique and as the first therapeutic option in selected cases of chronic and multilevel LS with an intact laryngotracheal cartilaginous framework. Failure of this first-line upfront endoscopic procedure does not compromise the chances of success of subsequent major reconstructive surgery.

This limited series also confirms the validity of dilation laryngoplasty as an adjuvant treatment to improve and stabilise the results of previous reconstructive surgeries.

## References

- Smith MM, Cotton RT. Diagnosis and management of laryngotracheal stenosis. *Exp Rev Res Med* 2018;12:709-17. <https://doi.org/10.1080/17476348.2018.1495564>
- Choi SS, Zalzal GH. Changing trends in neonatal subglottic stenosis. *Otolaryngol Head Neck Surg* 2000;122:61-3. [https://doi.org/10.1016/S0194-5998\(00\)70145-8](https://doi.org/10.1016/S0194-5998(00)70145-8)
- Cohen MD, Weber TR, Rao CC. Balloon dilatation of tracheal and bronchial stenosis. *Am J Roentgenol* 1984;142:477-8. <https://doi.org/10.2214/ajr.142.3.477>
- Wenzel AM, Schweiger C, Manica D, et al. Impact of balloon laryngoplasty on management of acute subglottic stenosis. *Eur Arch Otorhinolaryngol* 2018;275:2325-31. <https://doi.org/10.1007/s00405-018-5064-7>
- Guarisco JL, Yang CJ. Balloon dilation in the management of severe airway stenosis in children and adolescents. *J Pediatr Surg* 2013;48:1676-81. <https://doi.org/10.1016/j.jpedsurg.2012.12.035>
- Myer CM 3rd, O'Connor DM, Cotton RT. Proposed grading system for subglottic stenosis based on endotracheal tube sizes. *Ann Otol Rhinol Laryngol* 1994;103:319-23. <https://doi.org/10.1177/000348949410300410>
- Avelino M, Maunsell R, Jube Wastowski I. Predicting outcomes of balloon laryngoplasty in children with subglottic stenosis. *Int J Pediatr Otorhinolaryngol* 2015;79:532-6. <https://doi.org/10.1016/j.ijporl.2015.01.022>
- Sharma SD, Gupta SL, Wyatt M, et al. Safe balloon sizing for endoscopic dilatation of subglottic stenosis in children. *J Laryngol Otol* 2017;131:268-72. <https://doi.org/10.1017/S0022215117000081>
- Cohen SR. Congenital glottic webs in children. A retrospective review of 51 patients. *Ann Otol Rhinol Laryngol Suppl* 1985;121:2-16.
- Hulstein S, Hoffman H. Technique for improved safety in the endoscopic management of subglottic stenosis. *Am J Otolaryngol* 2016;37:490-2. <https://doi.org/10.1016/j.amjoto.2015.10.009>
- Maresh A, Preciado DA, O'Connell AP, et al. A comparative analysis of open surgery vs endoscopic balloon dilation for pediatric subglottic stenosis. *JAMA Otolaryngol Head Neck Surg* 2014;140:901-5. <https://doi.org/10.1001/jamaoto.2014.1742>
- Axon PR, Hartley C, Rothera MP. Endoscopic balloon dilatation of subglottic stenosis. *J Laryngol Otol* 1995;109:876-9. <https://doi.org/10.1017/s0022215100131561>
- Durden F, Sobol SE. Balloon laryngoplasty as a primary treatment for subglottic stenosis. *Arch Otolaryngol Head Neck Surg* 2007;133:772-5. <https://doi.org/10.1001/archotol.133.8.772>
- Bakthavachalam S, McClay JE. Endoscopic management of subglottic stenosis. *Otolaryngol Head Neck Surg* 2008;139:551-9. <https://doi.org/10.1016/j.otohns.2008.07.024>
- Hebra A, Powell DD, Smith CD, et al. Balloon tracheoplasty in children: results of a 15-year experience. *J Pediatr Surg* 1991;26:957-61. [https://doi.org/10.1016/0022-3468\(91\)90843-i](https://doi.org/10.1016/0022-3468(91)90843-i)
- Hamilton J, Yaneza MM, Clement WA, et al. The prevalence of airway problems in children with Down's syndrome. *Int J Pediatr Otorhinolaryngol* 2016;81:1-4. <https://doi.org/10.1016/j.ijporl.2015.11.027>
- Monnier P. *Pediatric airway surgery*. Berlin, Germany: Springer; 2011.
- Wentzel JL, Ahmad SM, Discolo CM, et al. Balloon laryngoplasty for pediatric laryngeal stenosis: case series and systematic review. *Laryngoscope* 2014;124:1707-12. <https://doi.org/10.1002/lary.24524>