

Case Report: Severe Cutaneous Leishmaniasis in a Human Immunodeficiency Virus Patient Coinfected with *Leishmania braziliensis* and Its Endosymbiotic Virus

Laurent Parmentier,† Alexia Cusini,† Norbert Müller, Haroun Zangger, Mary-Anne Hartley, Chantal Desponds, Patrik Castiglioni, Patrick Dubach, Catherine Ronet, Stephen M. Beverley, and Nicolas Fasel*

Department of Dermatology, University Hospital of Bern, Bern, Switzerland; Department of Infectious Diseases, University Hospital of Bern, Bern, Switzerland; Institute of Parasitology, Vetsuisse Faculty Berne, University of Bern, Bern, Switzerland; Department of Biochemistry, University of Lausanne, Lausanne, Switzerland; Department of Ear, Neck and Throat, Head and Neck Surgery, University Hospital of Bern, Bern, Switzerland; Department of Molecular Microbiology, Washington University School of Medicine, St. Louis, Missouri

Abstract. *Leishmania* parasites cause a broad range of disease, with cutaneous afflictions being, by far, the most prevalent. Variations in disease severity and symptomatic spectrum are mostly associated to parasite species. One risk factor for the severity and emergence of leishmaniasis is immunosuppression, usually arising by coinfection of the patient with human immunodeficiency virus (HIV). Interestingly, several species of *Leishmania* have been shown to bear an endogenous cytoplasmic dsRNA virus (LRV) of the *Totiviridae* family, and recently we correlated the presence of LRV1 within *Leishmania* parasites to an exacerbation murine leishmaniasis and with an elevated frequency of drug treatment failures in humans. This raises the possibility of further exacerbation of leishmaniasis in the presence of both viruses, and here we report a case of cutaneous leishmaniasis caused by *Leishmania braziliensis* bearing LRV1 with aggressive pathogenesis in an HIV patient. LRV1 was isolated and partially sequenced from skin and nasal lesions. Genetic identity of both sequences reinforced the assumption that nasal parasites originate from primary skin lesions. Surprisingly, combined antiretroviral therapy did not impact the devolution of *Leishmania* infection. The *Leishmania* infection was successfully treated through administration of liposomal amphotericin B.

INTRODUCTION

Leishmania parasites infect over 2 million people annually and cause a broad range of disease, with cutaneous afflictions being, by far, the most prevalent.¹ Variations in disease severity and symptomatic spectrum are mostly associated with parasite species. This is reflected by the geographical distribution of severely disseminated (DL) and mucosal leishmaniasis (ML), which occur predominantly in Central and South America and Ethiopia. *Leishmania braziliensis*, *Leishmania panamensis*, *Leishmania guyanensis*, and *Leishmania aethiopia* are the main causative species of these aggressive forms of leishmaniasis, which progress from a primary cutaneous lesion in 5–10% of infected patients.^{2,3}

Leishmania braziliensis, *L. guyanensis*, and *L. aethiopia* species are known to be variously infected by *Leishmania* RNA virus (LRV), a cytoplasmic double-stranded RNA (dsRNA) virus of the *Totiviridae* family.^{2,4,5} LRV presence is predominant in the Amazonian basin.⁶ Previously, we showed that this virus (LRV1) within the *L. guyanensis* parasites exacerbates disease outcome in a murine model by inducing a hyperinflammatory response with increased interferon β ,⁷ and inflammatory markers commonly found in the lesions of ML patients.^{8,9} Recently, we and collaborators showed that the presence of LRV1 in *L. guyanensis* and *L. braziliensis* is a risk factor for relapse in drug-treated patients.^{10,11}

Leishmaniasis is a rising opportunistic complication in human immunodeficiency virus (HIV)-positive individuals.¹² Although it is well known that the parasite can take advantage of the concomitant acquired immunodeficiency syndrome (AIDS)-related immunosuppression, potentially this could be further exacerbated by the presence of LRV1 within the infecting

parasite. In this case report, we recount the clinical presentation, diagnosis, and successful treatment of this severe cutaneous leishmaniasis in an HIV-positive patient caused by *L. braziliensis* and its cytoplasmic virus.

CASE REPORT

The patient, a 60-year-old female, presented at the clinic with several skin ulcerations on the limbs and trunk. The patient had been living in Paraguay for the three previous years and her lesions first developed 9 months earlier during a 1-month stay in Bolivia, where she was treated empirically for bacterial ecthyma. A concomitant HIV test was found positive after which she decided to travel back to Switzerland for further medical management. The initial physical examination revealed several large, ovoid skin ulcerations, ranging from 5 to 15 cm in diameter, with raised erythematous borders and a clear exudate (Figure 1A and B). The patient was afebrile and had no additional complaints.

Combined antiretroviral therapy (cART) with tenofovir, emtricitabine, and efavirenz was initiated based on a high viremia of 1,764 copies/mL (CD4-cell count of 803 cells/ μ L) and on the presence of a coinfecting *Leishmania* parasite. Treatment decreased viremia to 482 copies/mL after 2 months. The patient's skin lesions, however, continued to slowly progress, at which point she was referred to the dermatology department for further evaluation.

In addition to the skin lesions, the patient complained of a recently acquired unilateral rhinitis and nasal congestion. A nasal endoscopy revealed unilateral focal granulomatous hyperplasia of the head of the middle turbinate (Figure 1C). Magnetic resonance imaging showed no cartilaginous destruction or paranasal involvement. ML was suspected. Touch preparations from skin exudates disclosed no *Leishmania* amastigotes, and biopsies from lesion borders and nasal granulomatous tissue revealed chronic nonspecific inflammation, with no *Leishmania*, fungal, or mycobacterial

*Address correspondence to Nicolas Fasel, Department of Biochemistry, University of Lausanne, Ch. des Boveresses 155, Epalinges, Lausanne, Switzerland 1066. E-mail: nicolas.fasel@unil.ch

†These authors contributed equally to this work.

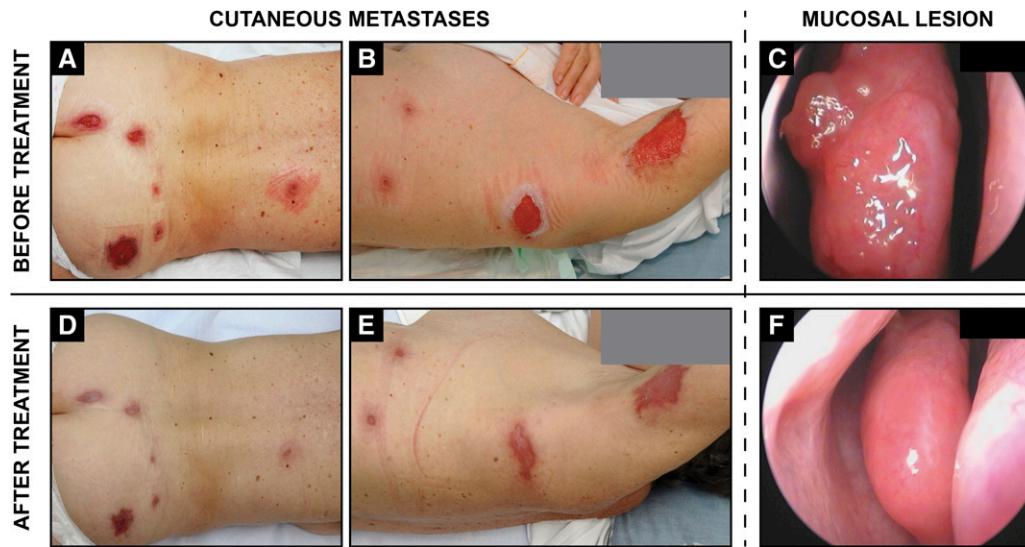


FIGURE 1. Cutaneous and mucosal metastatic leishmaniasis caused by *Leishmania* RNA virus-laden *Leishmania braziliensis* in a human immunodeficiency virus-coinfected patient. Pre-therapeutic examination (A–C) finds large well-demarcated skin ulcerations of the axillary regions and posterior trunk (A and B) while a nasal endoscopy (C) reveals granulomatous inflammation of the nasal mucosa on the head of the middle turbinate. One month after AmBisome treatment, skin lesions healed completely with mild discoloration and scarring (D and E). Nasal lesions resolved 3 months later after an additional round of AmBisome therapy (F).

organisms (by Giemsa, periodic acid–Schiff, and Ziehl–Neelsen stains, respectively).

On admission, a blood sample and two intralesional biopsies were isolated from the patient: one from a cutaneous lesion and the other from a metastatic lesion in the nasal mucosa. Two standard leishmanial diagnostic procedures (in vitro cultivation and polymerase chain reaction [PCR]) were undertaken on each of the three isolates. *Leishmania* parasites could be expanded from both cutaneous and nasal mucosa specimens, albeit absent in blood samples. PCR amplified a standard leishmanial diagnostic marker (internal transcribed spacer 1 of *Leishmania* small subunit ribosomal RNA).¹³ Direct sequencing of the amplified products was obtained and comparative sequence analysis of the diagnostic PCR products was done by applying the nucleotide BLAST[®] algorithm (<http://blast.ncbi.nlm.nih.gov/Blast.cgi>) (GeneBank[™] sequence database; accession no. JN936955). The alignment of the PCR products categorized both parasite isolates as *L. braziliensis*. Isolates were thereafter assigned World Health Organization format identifiers MHOM/BO/2011/2169 (*Lb2169*, skin lesion) and MHOM/BO/2011/2192 (*Lb2192*, nasal lesion).

Considering that our patient had a severely disseminated form of cutaneous leishmaniasis and an inflamed nasal mucosa, we determined that the *L. braziliensis* parasites from these lesions were infected by LRV1.¹⁴ We completed our study by obtaining pure LRV1 dsRNA after reverse transcription into complementary DNA (cDNA), performing PCR amplification using 10 primers (information available at: http://people.unil.ch/nicolasfasel/suptab1_lbhiv/) and sequencing 4,969 bp of this dsRNA (GenBank accession no. KC862308). Its structure paralleled the open reading frames of previously sequenced LRV1 isolated from *L. guyanensis* parasites (data not shown). An LRV1-specific PCR of parasite cDNA preparations from isolated viral dsRNA of both isolates was sequenced, confirming LRV1 presence in both isolates. The

genetic identity of LRV1 between both isolates supports the assumption that mucosal parasites had migrated from primary skin lesions.

Although the standard first-line treatment of ML relies on pentavalent antimony (sodium stibogluconate or meglumine antimoniate),^{15,16} we opted for a second-line therapy with liposomal amphotericin B,¹⁷ whose efficacy and tolerance profiles are favorable in DL as well as in HIV-coinfected patients and for treatment of antimony-resistant strains.¹⁸ Our choice was motivated by the evolution and severity of the disease, where numerous, large diameter (up to 15 cm) skin lesions had evolved and persisted for over 10 months, together with the potentially disfiguring involvement of the nasal mucosa.

The patient received intravenous liposomal amphotericin B for five successive days at 3 mg/kg (150 mg per infusion) with two additional infusions at days 14 and 21 (cumulative dose: 21 mg/kg, i.e., 1,050 mg). The cutaneous lesions of the limbs and trunk began to heal 2 weeks after treatment initiation and were completely re-epithelialized after 1 month (Figure 1D and E). The nasal mucosa required additional liposomal amphotericin infusions (cumulative dose: 27 mg/kg, i.e., 1,350 mg) to achieve complete healing with no residual deformation of the nasal structure (Figure 1F). Six months posttreatment, the patient had no infectious relapse and displayed only mild discoloration of the healed wounds.

DISCUSSION

This study was the first account of a patient coinfecting with HIV and a strain of *L. braziliensis* carrying the cytoplasmic dsRNA virus, LRV1. The patient presented with a particularly exacerbated form of cutaneous leishmaniasis, with individual metastatic skin lesions measuring up to 15 cm in diameter as well as a further parasitic infestation in the nasal mucosa. Although DL may present with ulcers and/

or mucosal involvement, even in HIV-negative patients,^{19–21} this patient's symptomology was distinct from that of *L. braziliensis* DL²¹ and from HIV/*L. braziliensis* coinfections because of the number of large ulcerated disseminated lesions.²² Although exacerbations of leishmaniasis are common in HIV coinfection due to a collapse of the CD4 T-cell compartment, the patient described here had a low CD4-cell count at the start of cART. Further, cART had no effect on disease progression, contrary to visceral leishmaniasis/HIV coinfection, where restoration of the CD4-cell count usually results in a significant amelioration of disease. Quite oppositely, the patient condition did not improve clinically with progressing cutaneous lesions.

The presence of *Leishmania* along with two viruses (one internal, one external) could underlie this severe form of disease, and may potentially explain some of the unusual manifestations of American tegumentary leishmaniasis caused by *L. braziliensis* or *L. guyanensis* reported in HIV-positive patients,^{23,24} which are especially frequent in regions of South America where LRV1 is known to be most prevalent, such as French Guyana and the Brazilian Amazon.^{25,26} Indeed, HIV and LRV dsRNA may synergize to worsen leishmaniasis, where HIV coinfection not only increases the incidence of *Leishmania* infection, but also the patient's risk of developing metastatic or chronic complications of leishmaniasis.

The retrospective nature of this report and the lack of epidemiological data did not allow us to definitively ascertain the joint detrimental roles of LRV1 and HIV in human leishmanial disease progression. However, we can hypothesize that the clinical presentation reported here of LRV1-carrying *Leishmania* infection is in line with what is observed in relapses in *L. braziliensis*- and *L. guyanensis*-infected patients and in experimental animal models and could explain some of the unusual manifestations of American tegumentary leishmaniasis reported in HIV-positive patients,^{23,24,27} as well as the commonly observed treatment failures and relapses.^{10–12,26} Using PCR conditions and primers described in this study, a large-scale screen for LRV1 as a risk factor in leishmaniasis patients will be instrumental to unlocking the potential of exploiting this nested viral infection for use as a diagnostic and prognostic marker.

Received November 9, 2015. Accepted for publication December 17, 2015.

Published online February 1, 2016.

Acknowledgments: We thank F. Matthew Kuhlmann for advice and critical reading of the manuscript.

Financial support: This work was funded by the grants FNRS no. 3100A0-116665/1, IZ70Z0-131421 and from aIAR to Nicolas Fasel and NIH grants AI29646 and AI099364 to Stephen M. Beverley.

Authors' addresses: Laurent Parmentier, Dermatology, Hôpitaux du Valais, Sierre, Switzerland, E-mail: laurent.parmentier@hospitalvs.ch. Alexia Cusini, Infectious Diseases Unit, Cantonal Hospital, Chur, Switzerland, E-mail: alexia.cusini@ksg.ch. Norbert Müller, Institute of Parasitology, Vetsuisse Faculty Bern, University of Bern, Bern, Switzerland, E-mail: norbert.mueller@vetsuisse.unibe.ch. Haroun Zangger, Mary-Anne Hartley, Chantal Desponds, Patrik Castiglioni, Catherine Ronet, and Nicolas Fasel, Department of Biochemistry, University of Lausanne, Lausanne, Switzerland, E-mails: haroun.zangger@vd.educanet2.ch, hartley.annie@gmail.com, chantal.desponds@unil.ch, patrik.castiglioni@unil.ch, catherine.ronet@unil.ch, and nicolas.fasel@unil.ch. Patrick Dubach, Ear Neck Throat Surgery, Bürgerspital, Solothurn, Switzerland, E-mail: patrick.dubach@spital.so.ch. Stephen M. Beverley, Department of Molecular Microbiology, Washington University School of Medicine, St. Louis, MO, E-mail: beverley@wumsl.edu.

This is an open-access article distributed under the terms of the Creative Commons Attribution License, which permits unrestricted use, distribution, and reproduction in any medium, provided the original author and source are credited.

REFERENCES

- Alvar J, Velez ID, Bern C, Herrero M, Desjeux P, Cano J, Jannin J, den Boer M; WHO Leishmaniasis Control Team, 2012. Leishmaniasis worldwide and global estimates of its incidence. *PLoS One* 7: e35671.
- Zangger H, Hailu A, Desponds C, Lye LF, Akopyants NS, Dobson DE, Ronet C, Ghalib H, Beverley SM, Fasel N, 2014. *Leishmania aethiopica* field isolates bearing an endosymbiotic dsRNA virus induce pro-inflammatory cytokine response. *PLoS Negl Trop Dis* 8: e2836.
- Hartley MA, Drexler S, Ronet C, Beverley SM, Fasel N, 2014. The immunological, environmental, and phylogenetic perpetrators of metastatic leishmaniasis. *Trends Parasitol* 30: 412–422.
- Tarr PI, Aline RF Jr, Smiley BL, Scholler J, Keithly J, Stuart K, 1988. LRV1: a candidate RNA virus of *Leishmania*. *Proc Natl Acad Sci USA* 85: 9572–9575.
- Widmer G, Comeau AM, Furlong DB, Wirth DF, Patterson JL, 1989. Characterization of a RNA virus from the parasite *Leishmania*. *Proc Natl Acad Sci USA* 86: 5979–5982.
- Salinas G, Zamora M, Stuart K, Saravia N, 1996. *Leishmania* RNA viruses in *Leishmania* of the *Viannia* subgenus. *Am J Trop Med Hyg* 54: 425–429.
- Ives A, Ronet C, Prevel F, Ruzzante G, Fuertes-Marraco S, Schutz F, Zangger H, Revaz-Breton M, Lye LF, Hickerson SM, Beverley SM, Acha-Orbea H, Launois P, Fasel N, Masina S, 2011. *Leishmania* RNA virus controls the severity of mucocutaneous leishmaniasis. *Science* 331: 775–778.
- Carvalho EM, Johnson WD, Barreto E, Marsden PD, Costa JL, Reed S, Rocha H, 1985. Cell mediated immunity in American cutaneous and mucosal leishmaniasis. *J Immunol* 135: 4144–4148.
- Silveira FT, Lainson R, De Castro Gomes CM, Laurenti MD, Corbett CE, 2009. Immunopathogenic competences of *Leishmania (V.) braziliensis* and *L. (L.) amazonensis* in American cutaneous leishmaniasis. *Parasite Immunol* 31: 423–431.
- Bourreau E, Ginouves M, Prevot G, Hartley MA, Gangneux JP, Robert-Gagneux F, Dufour J, Sainte-Marie D, Bertolotti A, Pratlong F, Martin R, Schutz F, Couppez P, Fasel N, Ronet C, 2015. Presence of *Leishmania* RNA virus 1 in *Leishmania guyanensis* increases the risk of first-line treatment failure and symptomatic relapse. *J Infect Dis* 213: 105–111.
- Adaui V, Lye LF, Akopyants NS, Zimic M, Llanos-Cuentas A, Garcia L, Maes I, De Doncker S, Dobson DE, Arevalo J, Dujardin JC, Beverley SM, 2015. Association of the endobiont double-stranded RNA virus LRV1 with treatment failure for human leishmaniasis caused by *Leishmania braziliensis* in Peru and Bolivia. *J Infect Dis* 213: 112–121.
- Alvar J, Aparicio P, Aseffa A, Den Boer M, Canavate C, Dedet JP, Gradoni L, Ter Horst R, Lopez-Velez R, Moreno J, 2008. The relationship between leishmaniasis and AIDS: the second 10 years. *Clin Microbiol Rev* 21: 334–359.
- el Tai NO, Osman OF, el Fari M, Presber W, Schonian G, 2000. Genetic heterogeneity of ribosomal internal transcribed spacer in clinical samples of *Leishmania donovani* spotted on filter paper as revealed by single-strand conformation polymorphisms and sequencing. *Trans R Soc Trop Med Hyg* 94: 575–579.
- Zangger H, Ronet C, Desponds C, Kuhlmann FM, Robinson J, Hartley MA, Prevel F, Castiglioni P, Pratlong F, Bastien P, Muller N, Parmentier L, Saravia NG, Beverley SM, Fasel N, 2013. Detection of *Leishmania* RNA virus in *Leishmania* parasites. *PLoS Negl Trop Dis* 7: e2006.
- Reithinger R, Dujardin JC, Louzir H, Pirmez C, Alexander B, Brooker S, 2007. Cutaneous leishmaniasis. *Lancet Infect Dis* 7: 581–596.
- Amato VS, Tuon FF, Bacha HA, Neto VA, Nicodemo AC, 2008. Mucosal leishmaniasis. Current scenario and prospects for treatment. *Acta Trop* 105: 1–9.

17. Machado PR, Rosa ME, Guimaraes LH, Prates FV, Queiroz A, Schriefer A, Carvalho EM, 2015. Treatment of disseminated leishmaniasis with liposomal amphotericin B. *Clin Infect Dis* 61: 945–949.
18. Amato VS, Nicodemo AC, Amato JG, Boulos M, Neto VA, 2000. Mucocutaneous leishmaniasis associated with HIV infection treated successfully with liposomal amphotericin B (AmBisome). *J Antimicrob Chemother* 46: 341–342.
19. Costa JM, Marsden PD, Llanos-Cuentas EA, Netto EM, Carvalho EM, Barral A, Rosa AC, Cuba CC, Magalhaes AV, Barreto AC, 1986. Disseminated cutaneous leishmaniasis in a field clinic in Bahia, Brazil: a report of eight cases. *J Trop Med Hyg* 89: 319–323.
20. Carvalho EM, Barral A, Costa JM, Bittencourt A, Marsden P, 1994. Clinical and immunopathological aspects of disseminated cutaneous leishmaniasis. *Acta Trop* 56: 315–325.
21. Turetz ML, Machado PR, Ko AI, Alves F, Bittencourt A, Almeida RP, Mobashery N, Johnson WD Jr, Carvalho EM, 2002. Disseminated leishmaniasis: a new and emerging form of leishmaniasis observed in northeastern Brazil. *J Infect Dis* 186: 1829–1834.
22. Machado ES, Braga Mda P, Da Cruz AM, Coutinho SG, Vieira AR, Rutowitsch MS, Cuzzi-Maya T, Grimaldi G Jr, Menezes JA, 1992. Disseminated American muco-cutaneous leishmaniasis caused by *Leishmania braziliensis braziliensis* in a patient with AIDS: a case report. *Mem Inst Oswaldo Cruz* 87: 487–492.
23. Lindoso JA, Barbosa RN, Posada-Vergara MP, Duarte MI, Oyafuso LK, Amato VS, Goto H, 2009. Unusual manifestations of tegumentary leishmaniasis in AIDS patients from the New World. *Br J Dermatol* 160: 311–318.
24. Goto H, Lindoso JA, 2010. Current diagnosis and treatment of cutaneous and mucocutaneous leishmaniasis. *Expert Rev Anti Infect Ther* 8: 419–433.
25. Couppie P, Clyti E, Sobesky M, Bissuel F, Del Giudice P, Sainte-Marie D, Dedet JP, Carme B, Pradinaud R, 2004. Comparative study of cutaneous leishmaniasis in human immunodeficiency virus (HIV)-infected patients and non-HIV-infected patients in French Guiana. *Br J Dermatol* 151: 1165–1171.
26. Guerra JA, Coelho LI, Pereira FR, Siqueira AM, Ribeiro RL, Almeida TM, Lacerda MV, Barbosa M, Talhari S, 2011. American tegumentary leishmaniasis and HIV-AIDS association in a tertiary care center in the Brazilian Amazon. *Am J Trop Med Hyg* 85: 524–527.
27. de Souza e Souza I, Naiff RD, Guimaraes TC, Naiff MF, Cupolillo E, Rodrigues WA, Schettini AP, 1998. American cutaneous leishmaniasis due to *Leishmania (Viannia) guyanensis* as an initial clinical presentation of human immunodeficiency virus infection. *J Eur Acad Dermatol Venereol* 10: 214–217.