

Case Report

Response of Brain and Meningeal Metastases to Trastuzumab-Deruxtecan in a Patient with HER2-Low Breast Cancer: A Case Report

Benita Wolf^{a,b} Vincent Dunet^c Estelle Dubruc^d Ana Dolcan^a
Marie Nicod Lalonde^e Luis Schiappacasse^f Khalil Zaman^a

^aDepartment of Oncology, Lausanne University Hospital (CHUV) and University of Lausanne (UNIL), Lausanne, Switzerland; ^bLudwig Institute for Cancer Research Lausanne Branch, Lausanne, Switzerland; ^cDepartment of Radiology, Lausanne University Hospital (CHUV) and University of Lausanne (UNIL), Lausanne, Switzerland; ^dInstitute of Pathology, Lausanne University Hospital (CHUV) and University of Lausanne (UNIL), Lausanne, Switzerland; ^eService of Nuclear Medicine and Molecular Imaging, Lausanne University Hospital (CHUV) and University of Lausanne (UNIL), Lausanne, Switzerland; ^fService of Radio-oncology, Lausanne University Hospital (CHUV) and University of Lausanne (UNIL), Lausanne, Switzerland

Keywords

Brain metastases · Leptomeningeal disease · HER2-low · Trastuzumab-deruxtecan · Case report

Abstract

Nervous system metastases (CNSm) are late events associated with poor outcomes in endocrine-sensitive HER2-negative breast cancer (BC) patients, especially in the presence of leptomeningeal disease (LMD). Effective treatments are extremely limited in this setting. The antibody-drug conjugate, trastuzumab-deruxtecan (T-DXd), which combines the anti-HER2 antibody trastuzumab with a topoisomerase type 1 inhibitor, showed high efficacy not only against HER2-positive but also HER2-low metastatic BCs, expressing HER2 at a lower level. To the best of our knowledge, this is the first report of a patient with metastatic endocrine-sensitive HER2-low BC suffering from BMs associated with LMD and sustained disease control when treated with T-DXd. Several recent case series have reported the activity of T-DXd in patients with HER2-positive disease and brain metastases or LMD, but none in HER2-low patients. This case is particularly relevant since more than 50% of BCs are HER2-low.

© 2023 The Author(s).
Published by S. Karger AG, Basel

Correspondence to:
Khalil Zaman, Khalil.Zaman@chuv.ch

Introduction

Breast cancer (BC) is the second most common cause of central nervous system metastasis (CNSm), with a higher prevalence in patients with triple-negative (25–56%) and human epidermal growth factor receptor 2 (HER2)-positive (53%) BC subtypes [1]. In metastatic hormone receptor-positive BC (HR+, expressing estrogen receptors and/or progesterone receptors), CNSm occurs in 8–15% of patients and is often a late event [1]. Despite the low risk of CNSm per se, its prevalence is relatively high because HR+ BC patients represent two-thirds of all BC patients [2].

CNSm can be divided into at least two categories: parenchymal metastases, usually called brain metastases (BMs) and leptomeningeal disease (LMD). Diagnosis is performed using magnetic resonance imaging (MRI) for BMs and by MRI and/or lumbar puncture with detection of carcinoma cells in cerebrospinal fluid (CSF) cytology for LMD. The sensitivity and specificity of MRI for the diagnosis of LMD range between 66–98% and 77–98%, respectively. Outcomes for patients with LMD (3–5% of BC patients) are poor, with an estimated median overall survival (mOS) of 5.1, 5.6, and 3.0 months in HR+/HER2–, HER2+, and triple-negative BC, respectively. The reported mOS appears longer in patients with BMs, with a mOS of 7.1 months for HR+/HER2–, 18.9 months for HR+/HER2+, 13.1 months for HR–/HER2+, and 4.4 months for TNBC [1]. Other prognostic factors include age, Karnofsky performance status, and number of brain lesions [3].

Over the past decade, the arrival of new therapies has significantly improved outcomes for patients with different BC subtypes, including cyclin-dependent kinase 4/6 (CDK4/6) or poly ADP-ribose polymerases (PARP) inhibitors, antibody-drug conjugates (ADCs) [4], anti-HER2 tyrosine kinase inhibitors, and immunotherapy [5, 6]. Standard treatments for BMs include surgery, stereotactic radiosurgery, and less frequently, whole-brain radiotherapy [1]. Patients undergoing locoregional treatment for CNS seem to have better outcomes [7]. Treatment options for LMD are limited to intrathecal chemotherapy with methotrexate, cytarabine, thiotepa, high-dose intravenous methotrexate, and irradiation of focal lesions or the whole neuroaxis, and lack strong scientific evidence. Notably, liposomal cytarabine is no longer available for intrathecal administration. Systemic therapies were reported to also have some efficacy against CNSm, due to impaired blood-brain barrier (BBB) in this setting [1]. Nevertheless, considering the small size of the cohorts, the absence of control groups, and the inconsistent imaging techniques, these treatments are neither considered standard nor registered for this indication. Until recently, patients with CNSm were excluded from large clinical studies assessing new systemic therapies because of their often poor condition and poor short-term outcomes. An exception is the HER2+ BC subtype [8], where substantial progress has been made with anti-HER2 tyrosine kinase inhibitors in combination with chemotherapy and the ADCs trastuzumab-emtansine and, more recently, trastuzumab-deruxtecan (T-DXd) [8]. At least three trials with small sample sizes reported the activity of T-DXd against HER2+ BMs, with a response rate between 46.2% and 73.3% [8, 9]. In patients with HER2-negative disease, no new treatment option for CNSm was developed until recently, translating into worse outcomes than HER2+ disease [1]. However, scientific progress in HER2+ BC has started to benefit other subtypes, especially in relation to ADCs [10].

Recently, the DESTINY Breast04 trial showed the superiority of T-DXd compared to standard mono-chemotherapy, even in metastatic HER2-negative BC patients expressing HER2 at a low level (HER2-low) as assessed by immunohistochemistry [11]. Notably, at least half of the BC population has HER2-low status [11]. Some cases of BMs in patients with HER2-low BC treated with T-DXd were reported in the DAISY trial.

To the best of our knowledge, this is the first report of a woman with metastatic endocrine-sensitive HER2-low BC treated with T-DXd for LMD and BMs. The CARE Checklist has been completed by the authors for this case report, attached as online supplementary material (for all online suppl. material, see <https://doi.org/10.1159/000534572>).

Case Report

Patient History

A 44-year-old female patient was diagnosed with right-sided multicentric stage IA invasive BC of no special type (NST), grade 2, estrogen receptor 80%, progesterone receptor 60%, HER2 negative (Fig. 1), and Ki67 30%. After mastectomy and sentinel lymph node excision, she received four cycles of adjuvant chemotherapy with docetaxel and cyclophosphamide, followed by endocrine therapy with tamoxifen, then by ovarian function suppression, and exemestane combination.

Three years after the initial diagnosis, the patient presented with bone metastases, confirmed by a biopsy of the iliac bone (Table 1). The patient was treated sequentially for over 33 months with several lines of endocrine therapies and chemotherapies, with relatively short progression-free survival (PFS): palbociclib, fulvestrant, ovarian function suppression (PFS = 9 months), capecitabine (PFS = 5 months), pegylated liposomal doxorubicin (PFS = 6 months), eribuline (PFS = 7 months) gemcitabine and carboplatin (PFS = 2 months), and vinorelbine (PFS = 3 months).

In June 2022, FDG PET/CT showed disease progression in the bone, liver, pleura, and area of the operated breast. The tumor marker CA 15–3 reached 2,055 kU/L. A brain MRI was performed because of numbness in the angle of the left eye (dermatome V2) and the right chin (dermatome V3).

Brain Imaging

MRI, including axial T2-weighted, spin echo, and gradient echo 3D-T1 weighted post-gadolinium, was performed according to current recommendations [8]. These investigations revealed multiple small CNS metastases and dural thickening corresponding to meningeal metastasis (Fig. 2). Diffuse, vividly enhancing dural thickening on post-contrast gradient echo 3D T1-weighted images was consistent with leptomeningeal involvement.

Treatment

The first results of the DESTINY-Breast04 trial were presented at the ASCO annual meeting in 2022 [11]. The patient's insurance supported the treatment with T-DXd, which was started at a standard dose of 5.4 mg/kg. The dosage was decreased to 4.4 mg/kg from the third dose onward because of prolonged neutropenia.

Outcome

After nearly 12 months of treatment, corresponding to 17 cycles, the patient continued her treatment with a partial response of the CNSm, with a significant decrease in meningeal thickness (Fig. 2). MRIs confirmed no BM progression after six, ten, and 13 cycles. The neurological symptoms were resolved. Two novel millimetric brain lesions were observed after 16 cycles, which are being monitored. The systemic lesions regressed rapidly, except for two muscular lesions controlled with localized targeted radiation (Fig. 3). After 13 treatment cycles, some new liver and bone lesions were detected that are currently being treated with selective radiation therapy and the continuation of T-DXd.

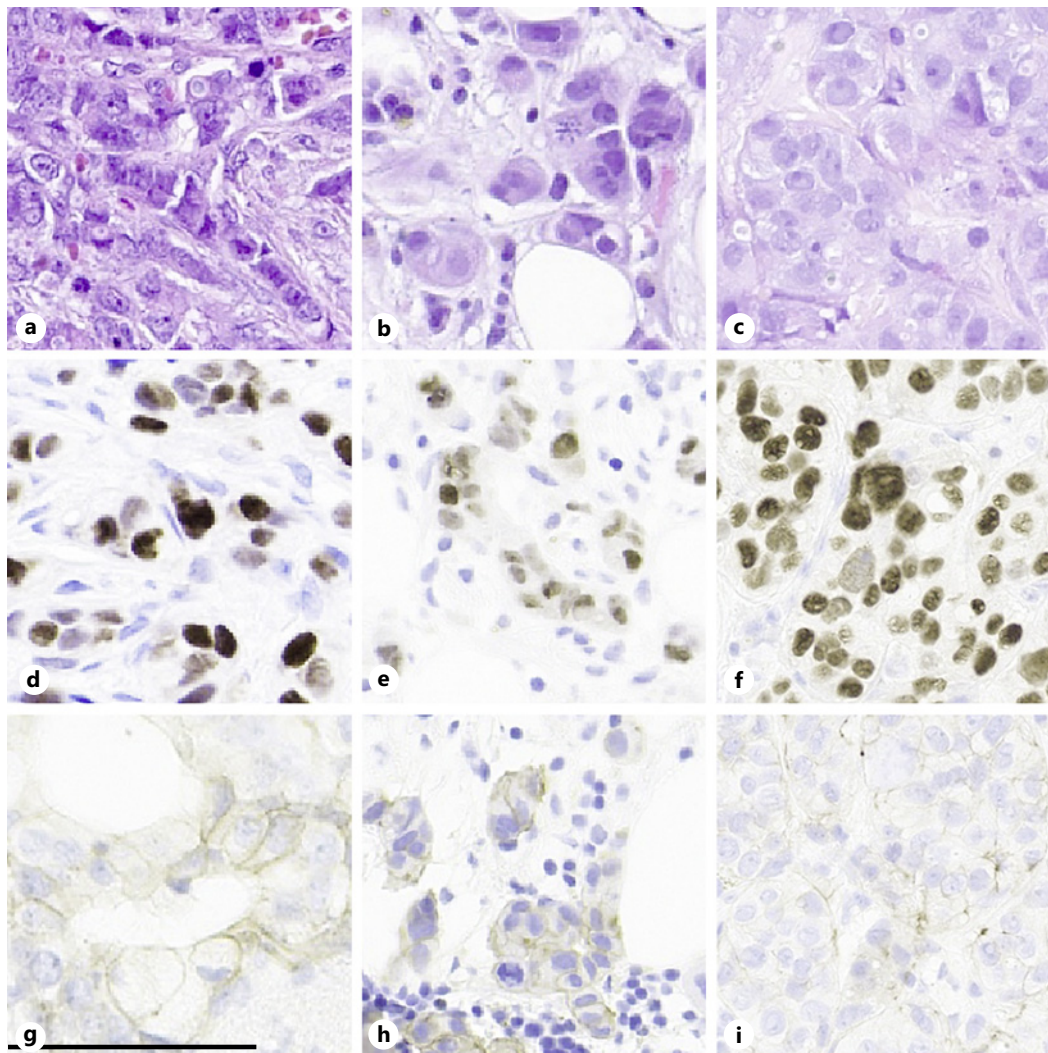


Fig. 1. Histology slides, immunohistochemistry staining of initial tumor and metastasis primary tumor samples (a, d, g) versus iliac bone metastasis (b, e, h) and liver metastasis (c, f, i). Stained for HE (a–c), estrogen receptors (d–f), and HER2 (g–i), showing a score of 2+ (g, h) (negative by FISH, not shown), and a score of 1+ (i). Scale bar: 100 μ m, objective used \times 20. HE, hematoxylin and eosin; FISH, fluorescence in situ hybridization.

Adverse events relating to T-DXd included grade 1 fatigue, grade 1 dysgeusia, and grade 2 neutropenia after dose adaptation. The patient presented with grade 2 alopecia followed by hair regrowth despite the continuation of treatment.

Histopathology Assessment

At three different time points (initial diagnosis, bone metastasis at recurrence, and liver metastasis) during the entire metastatic disease course, the patient underwent tumor tissue analyses each time a HER2-low endocrine-sensitive status was observed (Table 1; Fig. 1). The tumor samples were analyzed twice by next-generation sequencing of a panel of 52 and 400 genes, respectively. No currently targetable mutations were observed, including no somatic pathologic variants of *BRCA1*, *BRCA2*, *HER2*, or *PIK3CA*. One of the two progressing muscular lesions was also biopsied and continued to show HER2-low status (score 2+; fluorescence in situ hybridization [FISH] negative). The chronology of the patient's medical history is summarized in Figure 4.

Table 1. Tissue analyses over the time

Time point	Localization	Hormone receptor status ER/PgR (%)	HER2 status	Comments
Mastectomy (year 0)	Primary BC	80/60	IHC 2+, FISH negative	
Metastatic recurrence (year +3)	Right iliac bone	70/1	IHC 2+, FISH negative	NGS 52 genes: <i>FGFR1</i> amplification
Metastatic progression (year +5)	Liver	90/80	IHC 1+	NSG 400 genes: <i>ESR1</i> mutation, <i>FGFR1</i> amplification

ER, estrogen receptor; PgR, progesterone receptor; HER2, human epidermal growth factor receptor 2; IHC, immunohistochemistry; FISH, fluorescence in situ hybridization; NGS, next-generation sequencing panel of 52 genes.

Clinical Data Collection

The patient's history was collected from her electronic medical files at the Department of Medical Oncology at Lausanne University Hospital CHUV, Lausanne, Switzerland.

Imaging

Brain MRIs were performed by the neuroimaging team in the radiology department. The department of nuclear medicine performed the FDG PET/CT.

Histopathology Analyses

The specimens were fixed in 10% neutral-buffered formalin (6–72 h). Formalin-fixed paraffin-embedded samples were stained with hematoxylin and eosin (Ventana HE 600 system).

IHC was performed with anti-HER2/neu-specific (4B5, rabbit monoclonal, Ventana), anti-ER-specific (SP1, rabbit monoclonal, Ventana), and anti-PR-specific (1E2, rabbit monoclonal, Ventana) antibodies using the Ventana BenchMark automated stainer and revealed by the ultraView DAB detection kit. HER2 status was assessed according to the 2018 ASCO/CAP recommendations.

For all antibodies, an external control (BC) was stained in each batch and positive staining was verified.

ERBB2 (HER2) FISH analysis was performed on a 4- μ m-thick formalin-fixed paraffin-embedded tissue section using a FlexISH ERBB2/CEN 17 Dual Color Probe (Zytovision GmbH, Bremerharven, Germany), according to the manufacturer's protocol. Hybridization signals were analyzed using a Zeiss AxioImager Z2 fluorescence microscope equipped with a Plan-Apochromat $\times 63$ oil immersion objective (Carl Zeiss GmbH, Oberkochen, Germany).

Images were captured using the ISIS digital image analysis system (MetaSystems GmbH, Altlusheim, Germany). ERBB2 and CEP17 copy numbers were recorded in 60 consecutive tumor nuclei.

Discussion

CNSm is a late event in patients with endocrine-sensitive metastatic BC. In particular, LMD correlates with very poor outcomes and a high death rate from neurological complications [12]. We report the first case of a patient with HER2-low BC presenting with LMD with BMs. Notably, the patient had about a 12-month sustained response to intravenous T-DXd, which is especially relevant considering the high frequency of HER2-low status in BC patients with BMs and LMD [13].

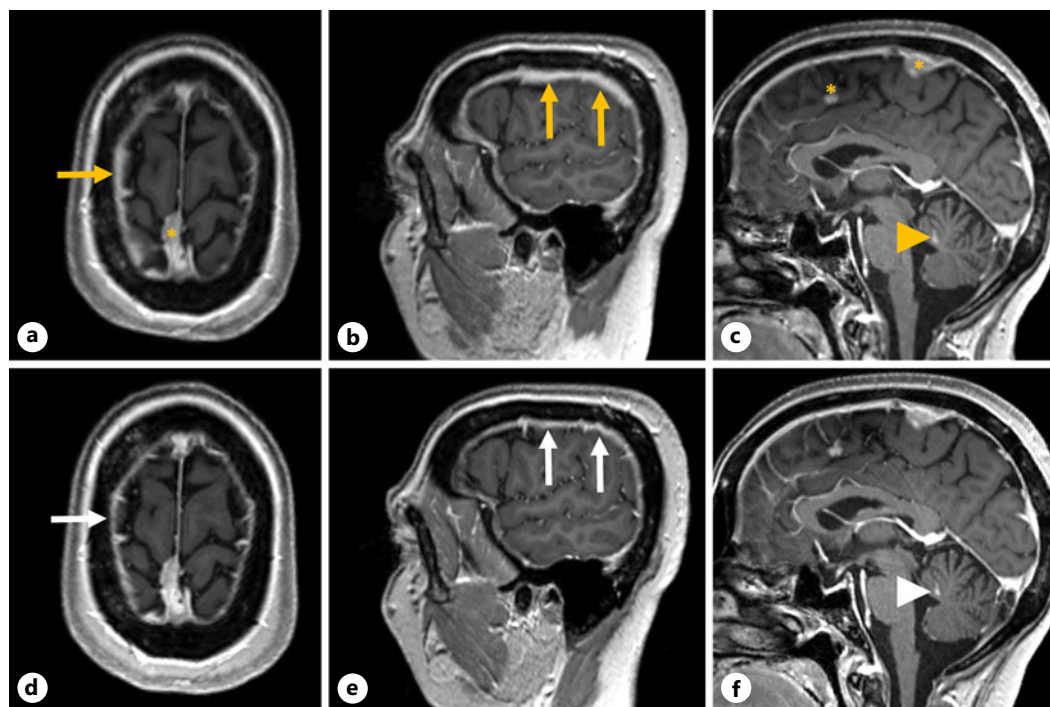


Fig. 2. Baseline and follow-up brain MRI baseline brain MRI (top line, a, b) demonstrated diffuse vividly enhancing dural thickening (orange arrows) on axial (a) and sagittal (b) post-contrast gradient-echo 3D T1-weighted images. Two focal nodular lesions along the anterior and posterior falx (c, orange stars) were considered potential dural metastases or meningiomas, and a nodular enhancing lesion in the vermis corresponded to brain metastasis (orange arrowhead). At the 3-month follow-up brain MRI (bottom line), pachymeningeal thickening significantly decreased from 6 to 3 mm (white arrows) in either the axial (d) or sagittal (e) planes. The dural nodules and vermian metastases are stable in size (f, white arrowhead). The response was stable at a 6-month follow-up brain MRI (not shown). MRI, magnetic resonance imaging.

In collaboration with the Brain Metastasis Task Force of the Breast International Group (BIG), we recently published a survey conducted at 241 sites to obtain better insight into current diagnostic and management strategies for LMD worldwide [14]. The diagnosis of LMD was triggered in 63.1% of centers by suspicious symptoms and, to a lesser extent, by incidental observation of asymptomatic LMD-specific MRI findings. Diagnosis was established using CSF analysis and/or MRI.

New therapies leading to better control of systemic disease, the possibility of iterative treatment of BMs by stereotactic radiosurgery, the increasing use of brain MRI during patient follow-up, and the higher risk of leptomeningeal seeding after BM surgery may, in the near future, increase the incidence of diagnosed LMD [12].

To date, LMD treatment options are few and have limited scientific evidence. Besides systemic corticosteroids to improve symptoms, medications can be delivered through intrathecal injections. However, results for a repeatedly invasive procedure harboring cumulative toxicity risk with concomitant systemic treatment are unpredictable [12]. When administered intravenously or orally, molecules must be smaller than 400–500 Da and have high lipid solubility to pass the BBB. In CNSm, the BBB is impaired, leading to higher permeability. Some cytotoxic agents have shown clinical activity in this setting, including capecitabine, cyclophosphamide, 5-fluorouracil, methotrexate, vincristine, cisplatin, etoposide, vinorelbine, gemcitabine, irinotecan, cisplatin, etoposide, capecitabine-temozolomide, cisplatin-temozolomide, abemaciclib,

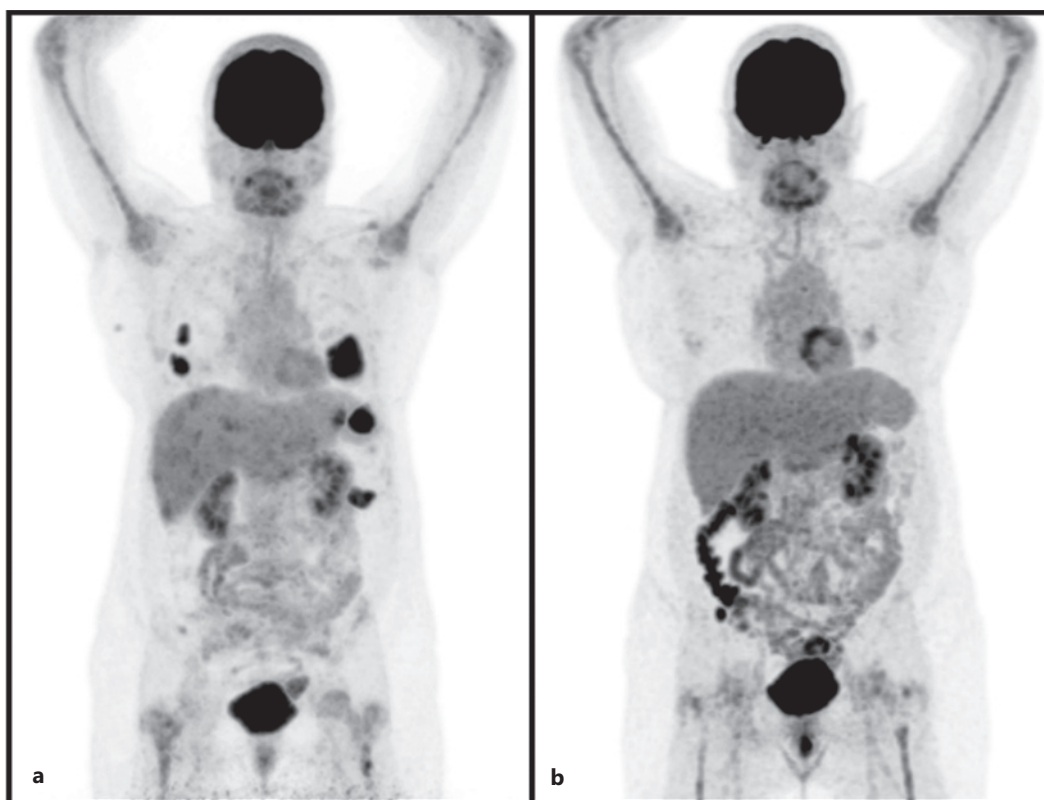


Fig. 3. 18F-FDG PET/CT maximal intensity projection (MIP). Before (a) and after (b) treatment with trastuzumab-deruxtecan showing metabolic response.

and bevacizumab. Nevertheless, there is still a significant difference between drug concentration in systemic blood and CSF, contributing to the ineffectiveness of treatments [9].

Despite this limitation, some new systemic BC treatments have also shown efficacy against CNSm, mainly BMs, based on case series, phase I and II trials [1]. In a phase II study of 58 patients with HR+/HER2- BC, abemaciclib, a CDK4/6 inhibitor, was shown to reach therapeutic concentrations in BMs with an objective intracranial response rate (iORR) of 5.2% and an intracranial clinical benefit rate of 24% [15]. In addition, the antiangiogenic antibody bevacizumab combined with carboplatin showed an iORR of 63% in patients with HER2+ disease [15].

Patients with CNSm have been systematically excluded from large randomized studies assessing new systemic therapies; however, this is about to change, at least for BMs in patients with HER2+ BC. The HER2CLIMB trial recruited 612 patients, including 291 patients with BMs. Adding tucatinib to the trastuzumab-capecitabine combination improved the time to CNS progression from 4.2 to 9.9 months, the iORR from 20 to 47%, and the mOS from 12.5 to 21.6 months [9]. The ongoing DESTINY Breast12 (NCT04739761) trial is investigating the benefits of T-DXd in 250 patients with advanced HER2+ BC and BMs. Currently, patients with HER2+ BMs have the best outcomes in terms of mOS [16].

This progress in HER2+ disease can be translated to a HER2-low BC subpopulation. HER2-low BC was defined as a HER2 score of 1+ or 2+ on immunohistochemistry and no amplification by FISH. It accounts for 40–50% of all BCs [11]. In a cohort of 2,310 HER2-negative BC patients, 60% of the HR+ and 33% of the TNBC population had HER2-low disease

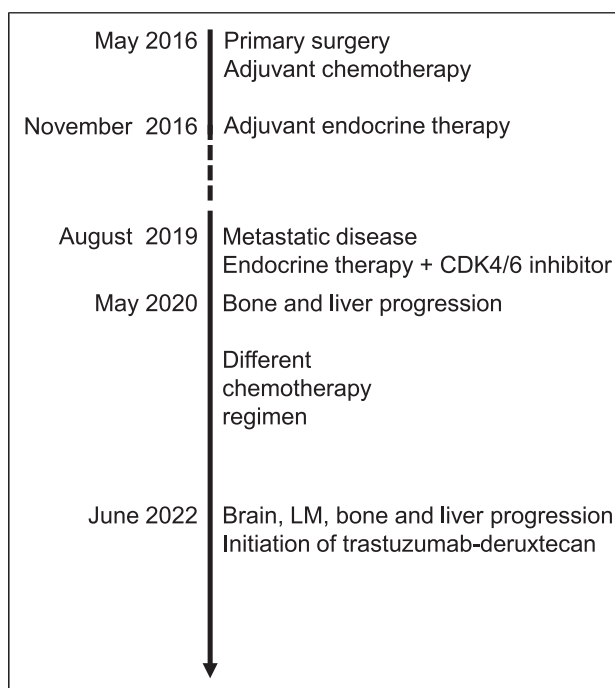


Fig. 4. Chronology of the patient's medical history. LM, leptomeningeal.

[17]. The DESTINY Breast04 trial comparing T-DXd to physician's choice chemotherapy in patients with HR + HER2-low BC showed an impressive improvement of median PFS from 4.7 to 10.1 months and mOS from 17.5 to 23.9 months [11].

Trastuzumab-emtansine (T-DM1) was the first registered ADC comprising the HER2-targeting antibody, trastuzumab, bound via a non-cleavable thioether linker to the potent anti-tubulin drug, maytansine derivative DM1, with a drug-antibody ratio of 3.5:1. T-DM1 was active against HER2+ disease, including BMs, with an iORR exceeding 40% in the KAMILLA trial [9]. T-DM1 showed however no significant efficacy in HER2-low disease [18]. Why the next-generation antibody-drug conjugate, T-DXd, combining a topoisomerase type 1 inhibitor via a cleavable linker to trastuzumab with an 8:1 drug-antibody ratio, is active in the HER2-low setting is not fully clear to date. In the HER2+ subpopulation, T-DXd was shown to be superior to T-DM1, probably with higher activity against MBs when considering the preliminary data in this setting [9, 19]. Treatment with T-DXd has been reported in a small cohort of HER2+ patients suffering from LMD, but not yet in a HER2-low subpopulation [20].

How these ADCs can reach and act in the CNS despite their large size remains under investigation. An intact BBB, including endothelial cells connected by tight junctions, pericytes, astrocytic pedicles, and perivascular microglia, is an obstacle for the delivery of drugs to the CNS. These structures are impaired in a metastatic setting, allowing for higher permeability. Additional hypotheses include endocytosis of ADCs through endothelial cells. Some characteristics of T-DXd could also explain its specific efficacy: high drug-antibody ratio, cleavable linker, long half-life, and the bystander effect that help drug delivery [21].

Our patient had a clear HER2-low status in several samples. Nevertheless, the minimal level of HER2 expression required to respond to T-DXd remains unknown. Indeed, in the phase II DAISY trial, the response rate of metastatic BC patients classified as HER2 zero (less than 10% cells expressing HER2) to T-DXd was 30%, with a median response of 6.8 months [22]. In non-small cell lung cancer, responses to T-DXd are observed in cancers with HER2 mutations and no expression or amplification as in BC. Therefore, the patient profile benefiting from T-DXd could be broader than initially expected. Targeting HER2 can inhibit

HER2 pathway activation, favor antibody-dependent cell-mediated cytotoxicity, initiate other immune responses, or serve as a vehicle for delivering potent cytotoxic drugs to cancer cells. The efficacy of other ADCs, such as sacituzumab govitecan or ladiratumumab vedotin, in HER2-negative mCNS is uncertain [23].

Currently, most CNSm cases are diagnosed as symptomatic [2]. The increasing availability and efficiency of surgery, radiotherapy, and systemic therapies could motivate future brain screening in asymptomatic patients, allowing early multimodal care. As patient outcomes improve with better-defined treatment strategies, their inclusion in clinical studies will become more evident, further accelerating progress. If the impressive activity of T-DXd in HER2+ CNSm and the emerging data in HER2-low CNSm were confirmed, notably by the results of the ongoing trials DESTINY Breast12 (NCT04739761) and DESTINY Breast06 (NCT04494425), systemic treatments could play a more predominant role in the treatment of BMs compared to local treatments such as surgery, which has the disadvantage of being invasive, and sometimes inducing non-reversible neurological adverse events and favoring leptomeningeal dissemination. In the HR+/HER2- population, CNSm is a late event during the metastatic course. In patients who have already been treated with several cytotoxic drugs at the time of BMs diagnosis, their disease becomes more resistant, i.e., lower chance to respond to the subsequent systemic treatment, especially in the brain. In this setting, the arrival of a new therapy, such as T-DXd, with specific properties and interactions with the BBB is welcome. Other strategies such as immunotherapy, ANG1005, a three-paclitaxel complex, new endocrine therapy combinations or derivatives of irinotecan, and different routes of administration are also under investigation.

Conclusion

This clinical case report is the first to show that LMD responds sustainably to T-DXd in HER2-low BC. These results provide new opportunities to explore an unmet need in BC, namely, the poor survival outcomes for HER2-low BC patients with LMD. If these clinical results are confirmed, T-DXd will enable simultaneous treatment of CNS metastases and systemic disease. In addition, T-DXd treatment in this setting would be more convenient than multimodal systemic treatments with radiation, surgery, or intrathecal injections with subsequent difficulties in managing the risks of combined toxicity. This new compound with specific properties also offers the advantage of being active in heavily pretreated BC patients, which is often the case for HR+/HER2 BC presenting with CNS metastases.

Patient Perspective

Following several lines of chemotherapy without a significant response, the patient was very reassured, finally observing a cancer response with durable disease control. The presence of the BM and LMD was also a source of stress, and she reported satisfaction that one drug could control all the breast metastases sites with manageable tolerability.

Acknowledgments

The authors would like to thank the patient and her family for providing us with consent for this project and publication.

Statement of Ethics

Ethical approval is not required for a case report in accordance with our local and national guidelines (Commission Cantonale d'éthique de la recherche sur l'être humain"; <https://www.cer-vd.ch>). The patient was informed orally about this case report project and provided written informed consent for the publication and her medical history, including pathological and radiological images.

Conflict of Interest Statement

Benita Wolf, Vincent Dunet, Estelle Dubruc, Marie Nicod Lalonde, and Luis Schiappacasse declare no conflicts of interest; Ana Dolcan: Advisory Boards for Novartis and PharmaMar and support for participation in congresses by PharmaMar and Lilly; Khalil Zaman: Advisory Boards for AstraZeneca, Daiichi, Exact Sciences, Gilead, Lilly, MSD, Mylan, Novartis, Pierre Fabre, and Seagen. Research funding: Roche; support for participation in international congresses: AstraZeneca, Daiichi, Gilead, Pierre Fabre, Roche. Unrestricted funding for organization of academic symposium: Agendia, AstraZeneca-MSD, Daiichi, Eisai, Exact Sciences, Lilly, Pierre Fabre, Gilead, Novartis, Pfizer, Roche, Seagen, Viatrix/Mylan, Vifor.

Funding Sources

The authors declare no funding for any research relevant to this study. This is an academic work without specific funding.

Author Contributions

B.W.: treated the patient, analyzed and interpreted the patient's case, and co-wrote and edited the manuscript. K.Z.: main treating physician, analyzed and interpreted the patient's case, and co-wrote and edited the manuscript. V.D.: radiologist, analyzed and interpreted the MRI data, contributed to the MRI figures, and co-wrote and reviewed the manuscript. E.D.: responsible pathologist, analyzed and interpreted the histological data, contributed to the histological figure, and co-wrote and reviewed the manuscript. A.D.: treated the patient, collected data, and edited the manuscript. M.N.L. (nuclearist): analyzed the patient's FDG PET/CT images and reviewed the manuscript. L.S.: treated the patient, analyzed and interpreted the data, and reviewed the manuscript.

Data Availability Statement

All data supporting the findings in this case report are contained within the text. Additional data are available upon request from the corresponding author.

References

- 1 Bailleux C, Eberst L, Bachelot T. Treatment strategies for breast cancer brain metastases. *Br J Cancer*. 2021; 124(1):142–55.

- 2 Darlix A, Louvel G, Fraisse J, Jacot W, Brain E, Debled M, et al. Impact of breast cancer molecular subtypes on the incidence, kinetics and prognosis of central nervous system metastases in a large multicentre real-life cohort. *Br J Cancer*. 2019;121(12):991–1000.
- 3 Fontanella C, De Carlo E, Cinausero M, Pelizzari G, Venuti I, Puglisi F. Central nervous system involvement in breast cancer patients: is the therapeutic landscape changing too slowly? *Cancer Treat Rev*. 2016;46:80–8.
- 4 Rizzo A, Cusmai A, Acquafredda S, Rinaldi L, Palmiotti G. Ladiratuzumab vedotin for metastatic triple negative cancer: preliminary results, key challenges, and clinical potential. *Expert Opin Investig Drugs*. 2022;31(6):495–8.
- 5 Santoni M, Rizzo A, Kucharz J, Mollica V, Rosellini M, Marchetti A, et al. Complete remissions following immunotherapy or immuno-oncology combinations in cancer patients: the MOUSEION-03 meta-analysis. *Cancer Immunol Immunother*. 2023;72(6):1365–79.
- 6 Rizzo A, Ricci AD. Biomarkers for breast cancer immunotherapy: PD-L1, TILs, and beyond. *Expert Opin Investig Drugs*. 2022;31(6):549–55.
- 7 Minisini AM, Moroso S, Gerratana L, Giangreco M, Iacono D, Poletto E, et al. Risk factors and survival outcomes in patients with brain metastases from breast cancer. *Clin Exp Metastasis*. 2013;30(8):951–6.
- 8 Stavrou E, Winer EP, Lin NU. How we treat HER2-positive brain metastases. *ESMO Open*. 2021;6(5):100256.
- 9 Lin NU. Expanding the role of systemic therapy for patients with active, HER2-positive breast cancer brain metastases. *ESMO Open*. 2022;7(6):100596.
- 10 von Arx C, De Placido P, Caltavuturo A, Di Rienzo R, Buonaiuto R, De Laurentiis M, et al. The evolving therapeutic landscape of trastuzumab-drug conjugates: future perspectives beyond HER2-positive breast cancer. *Cancer Treat Rev*. 2023;113:102500.
- 11 Modi S, Jacot W, Yamashita T, Sohn J, Vidal M, Tokunaga E, et al. Trastuzumab deruxtecan in previously treated HER2-low advanced breast cancer. *N Engl J Med*. 2022;387(1):9–20.
- 12 Carasu M, Carton M, Darlix A, Pasquier D, Leheurteur M, Debled M, et al. Breast cancer patients treated with intrathecal therapy for leptomeningeal metastases in a large real-life database. *ESMO Open*. 2021;6(3):100150.
- 13 Chehade R, Freeman M, Jerzak K. 53P “HER2-LOW” breast cancer brain metastases: an opportunity for targeted systemic therapies in a high-need patient population. *Ann Oncol*. 2022;33:S145.
- 14 Razi E, Escudero MJ, Palmieri C, Mueller V, Bartsch R, Rossi G, et al. Assessment of the management of carcinomatous meningitis from breast cancer globally: a study by the breast international group brain metastasis Task Force. *ESMO Open*. 2022;7(3):100483.
- 15 Jusino S, Fadul CE, Dillon P. Systematic review of the management of brain metastases from hormone receptor positive breast cancer. *J Neuro Oncol*. 2023;162(1):45–57.
- 16 Sperduto PW, Mesko S, Li J, Cagney D, Aizer A, Lin NU, et al. Survival in patients with brain metastases: summary report on the updated diagnosis-specific graded prognostic assessment and definition of the eligibility quotient. *J Clin Oncol*. 2020;38(32):3773–84.
- 17 Denkert C, Seither F, Schneeweiss A, Link T, Blohmer JU, Just M, et al. Clinical and molecular characteristics of HER2-low-positive breast cancer: pooled analysis of individual patient data from four prospective, neo-adjuvant clinical trials. *Lancet Oncol*. 2021;22(8):1151–61.
- 18 Metzger Filho O, Viale G, Trippa L, Li T, Yardley DA, Mayer IA, et al. HER2 heterogeneity as a predictor of response to neoadjuvant T-DM1 plus pertuzumab: results from a prospective clinical trial. *J Clin Oncol*. 2019;37(15_suppl):502.
- 19 Kabraji S, Ni J, Sammons S, Li T, Van Swearingen AED, Wang Y, et al. Preclinical and clinical efficacy of trastuzumab deruxtecan in breast cancer brain metastases. *Clin Cancer Res*. 2023;29(1):174–82.
- 20 Alder L, Trapani D, Swearingen AV, Kashraw M, Anders C, Lin N, et al. Durable clinical and radiographic responses in a series of patients with HER2+ Breast Cancer (BC) Leptomeningeal Disease (LMD) treated with trastuzumab deruxtecan (T-DXd). *NPJ Breast Cancer*. 2023;9(1):19.
- 21 Mair MJ, Bartsch R, Le Rhun E, Berghoff AS, Brastianos PK, Cortes J, et al. Understanding the activity of antibody-drug conjugates in primary and secondary brain tumours. *Nat Rev Clin Oncol*. 2023;20(6):372–89.
- 22 Epailard N, Lusque A, Pistilli B, André F, Bachelot T, Pierga JY, et al. Antitumor activity of trastuzumab deruxtecan (T-DXd) in patients with metastatic breast cancer (mBC) and brain metastases (BMs) from DAISY trial. *Ann Oncol*. 2022;33(Supplement 7):S656.
- 23 Diéras V, Weaver R, Tolaney SM, Bardia A, Punie K, Brufsky A, et al. Abstract PD13-07: subgroup analysis of patients with brain metastases from the phase 3 ASCENT study of sacituzumab govitecan versus chemotherapy in metastatic triple-negative breast cancer. *Cancer Res*. 2021;81(4_Supplement):PD13-07-PD13-07.