

# About the use of perfusion-weighted magnetic resonance imaging to define patterns of neonatal hypoxic-ischemic encephalopathy

P. Wintermark<sup>1</sup>, N. J. Robertson<sup>2</sup>, A. C. Moessinger<sup>1</sup>, E. De Vita<sup>3</sup>, F. Gudinchet<sup>4</sup>, and R. Meuli<sup>4</sup>

<sup>1</sup>Division of Neonatology, Department of Pediatrics, CHUV, Lausanne, Vaud, Switzerland, <sup>2</sup>Center for Perinatal Brain Research, Institute for Women's Health, University College London, London, United Kingdom, <sup>3</sup>Department of Medical Physics and Bio-Engineering, University College London, London, United Kingdom, <sup>4</sup>Department of Radiology, CHUV, Lausanne, Switzerland

## INTRODUCTION.

Patterns of brain injury in term neonatal encephalopathy have been associated with different clinical presentations and neurodevelopmental outcomes [1]. The explanation for these different patterns remained unclear, but alterations of cerebral perfusion might be an important factor. Our study assesses early brain perfusion pattern of term newborn with hypoxic-ischemic (HI) encephalopathy, in order to determine if perfusion-weighted imaging (PWI) is able to define early after birth the pattern of injury in neonatal encephalopathy.

## PATIENTS AND METHODS.

Seven term newborns, including 2 normal controls and 5 with neonatal HI encephalopathy or a marker of perinatal depression underwent an early (range, 2-4 days) complete MRI study. Newborn were grouped in the 4 patterns of injury on the basis of the predominant site of injury on MRI. PWI were acquired using a 1.5 T MRI scanner, using a dynamic post-contrast T2\* perfusion gradient-echo EPI images (TR/TE: 1220/54ms). 12 Axial sections (slice thickness, 5mm; interslice gap 0.5mm; field of view 200mm x 200mm; matrix size, 128x128 were imaged 40 times every 1.26s. After approximately 15 baseline pictures had been acquired, a bolus of 0.1 mmol/kg of gadolinium contrast was manually intravenously injected, followed by a 5 ml saline injection.

Relative perfusion parameters were obtained from the Siemens Perfusion Analysis Package, based on studies from Ostergaard et al. [2]. In brief, this software used a non parametric deconvolution technique (singular value decomposition, SVD) to estimate flow parameters from the timecourse of the T2\* weighted signal following injection of the contrast agent. A linear relation is assumed between T2\* changes and contrast agent concentration in tissue or arteries. The arterial input function (AIF) for each patient was obtained by manual selection of pixels within the MCA. The relative Cerebral Blood Flow (rCBF) was obtained as the maximum value of the Residue Function obtained by SVD. The relative Cerebral Blood Volume (rCBV) was obtained by integrating the concentration time curves between used selected time-points (typically, corresponding to arrival of contrast agent in region of interest and end of first pass). In order to avoid making assumptions regarding haemodynamic constants, and so that comparisons between subjects could be made more reliably, all relative CBF and CBV values averaged over ROIs for each patient were calculated as ratios to the average of the left and right cerebellar values. The ROIs were grouped into three main categories, and left and right values was presented for each patient in order to highlight asymmetrical lesions: 1) "cortical grey matter", measured in the frontal (GMF), parietal (GMP) and occipital (GMO) regions; 2) "white matter", measured in the anterior (WMA) and posterior (WMP) white matter and in the centrum semiovale (WMCSS); and 3) "deep grey matter", measured in the lentiform nucleus (LENT), the posterior limb of internal capsule (PLIC) and thalamus (THAL).

## RESULTS.

On early ( $\leq 4$  days) PWI-MRI, marked hyperperfusion (increased rCBF and rCBV) was seen in areas of HI brain damage, allowing the classification of children in the different known pattern: one infant demonstrated a normal pattern (Patient 1), one a watershed pattern (Patient 2) with increased rCBF and rCBV ratios in white matter, one a basal ganglia pattern (Patient 3) with increased rCBF and rCBV ratios in deep grey matter, and two a total cortical pattern (Patient 4 and 5) with increased rCBF and rCBV ratios in cortical grey matter, white matter and deep grey matter (especially PLIC and thalamus). These pattern was confirmed on late (9-11 days) conventional MRI (T2-weighted images) and on postmortem examination in all infants. PWI identifies early after birth the future definitive ischemic areas that can be shown on conventional MRI only later.

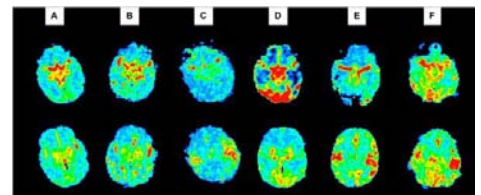
Relative CBF maps of each patient are presented in Figure 1. Figure 2 shows rCBF ratios to cerebellum for each ROI and each patient.

## DISCUSSION.

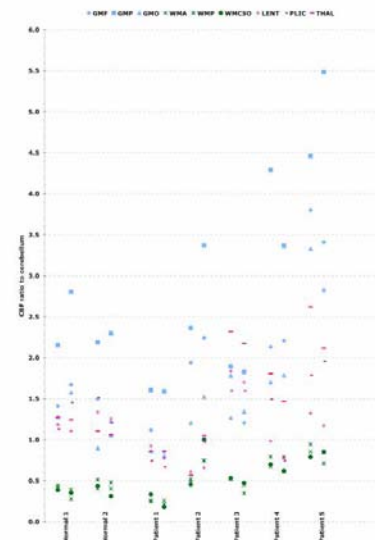
This study demonstrates the different patterns of perfusion-weighted MRI in five cases of HI injury in term newborns. Early PWI performed in the same time as diffusion-weighted imaging (DWI) and conventional imaging defines more precisely the extent of cerebral lesions, the severity of brain lesions, and the exact pattern of HI injury.

In conclusion, MRI pattern of brain injury in neonatal encephalopathy had been shown to help in identifying those newborn who are at higher risk for abnormal outcome. Early PWI-MRI defines the pattern and the severity of injury and has the potential to refine the assignment of prognosis. Additional studies with greater number of patients and follow-up studies are needed to elucidate the exact perfusion pattern in newborns with asphyxia of variable severity, and to know if PWI might be an additional tool to predict early the future neurodevelopmental outcome.

**REFERENCES:** [1] Miller SP, et al., J Pediatr, 146, 453, 2005; [2] Ostergaard L, et al., Magn Reson Med 36, 715, 1996.



**FIGURE 1.** CBF maps. **A:** Normal patient. **B:** Patient 1, with normal pattern. **C:** Patient 2, with watershed pattern. **D:** Patient 3, with basal ganglia pattern. **E** and **F:** Patient 4 and 5, with total cortical pattern.



**FIGURE 2.** Relative CBF for cortical grey matter, white matter and deep grey matter, calculated as ratios to the average of the left and right cerebellar values.