

Dual Microsporidial Infection Due to *Vittaforma corneae* and *Encephalitozoon hellem* in a Patient with AIDS

P. Deplazes, A. Mathis, M. van Saanen, A. Iten, R. Keller, I. Tanner, M. P. Glauser, R. Weber, and E. U. Canning

From the Institute of Parasitology and the Central Laboratory of Electron Microscopy, University of Zürich, and the Division of Infectious Diseases and Hospital Epidemiology, Department of Medicine, University Hospital, Zürich, and the Institute of Microbiology, University of Lausanne, and the Division of Infectious Diseases and Centre Hospitalier Universitaire Vaudois, Lausanne, Switzerland; and the Department of Biology, Imperial College of Science Technology and Medicine, London, United Kingdom

A 46-year-old human immunodeficiency virus–infected Swiss citizen living in Tanzania presented with respiratory, abdominal, and urogenital complaints. Microsporidial spores were isolated from urine and a sinunasal aspirate and were propagated in MRC-5 cell cultures. Western blot analysis and riboprinting identified the sinunasal isolate as *Encephalitozoon hellem*. Electron microscopic investigation of the urine isolate revealed spores with diplokaryotic nuclei and five to six isofilar coils of the polar tube and sporonts with two or three diplokarya. All stages were enveloped by two membranes, corresponding to a cisterna of host endoplasmic reticulum studded with ribosomes. These characteristics have been described for the genus *Vittaforma*. Western blot analysis of this isolate revealed a banding pattern identical to that of the *Vittaforma corneae* reference isolate. Part of the small subunit rRNA gene was amplified, sequenced (239 base pairs), and found to be identical to that of *V. corneae*. This is the second isolation of *V. corneae* and the first description of urinary tract infection due to *V. corneae* in a patient with AIDS.

Microsporidia are intracellular, spore-forming protists that have long been known to cause disease in various animal groups including mammals. Disseminated microsporidial infections have increasingly been recognized in HIV-infected patients; however, only a few microsporidial infections have been described in immunocompetent humans [1], including localized corneal infection due to *Nosema corneum* in one patient [2]. This microsporidian was recently assigned to a new genus, *Vittaforma corneae*, on the basis of its ultrastructure in the liver of experimentally infected athymic mice [3].

In vitro cultivation from diagnostic material has proven to be extremely useful for propagation of rare isolates for further characterization and for their use in animal models of infection. Using these methods, for the first time, we isolated *V. corneae* from the urine of an immunocompromised patient.

Patient and Methods

A 46-year-old HIV-infected Swiss citizen living in Tanzania was evaluated at University Hospital, Lausanne, Switzerland.

land, in 1995 because of fever, fatigue, chronic sinusitis, chronic cough, abdominal pain, urinary frequency, and perineal discomfort. He was receiving antiretroviral therapy and chemoprophylaxis. His CD4 lymphocyte count was $0.01 \times 10^9/L$. A chest roentgenogram, the serum creatinine level, and urinalyses were unremarkable. A CT scan of the head showed congestion of the maxillary and ethmoidal sinuses. No other etiologic agents were identified except for microsporidial spores that were detected by light microscopic examination of chromotrope-stained smears [4] of urine, nasal secretions, sinus aspirate, sputum, and stool specimens. A 6-week course of treatment with albendazole (400 mg twice daily) resulted in abatement of symptoms and a decrease in the mucosal thickening of the maxillary and ethmoidal sinuses in parallel to disappearance of microsporidial spores in respiratory secretions and a decrease in urinary excretion of microsporidial spores.

Isolation of spores from a 2-mL sinus aspirate and 4 mL of urine sediment and subsequent cultivation in human embryonic lung fibroblast (MRC-5) cells were done as previously described [5]. The isolates were designated IPZ:TZ-H13U (urine isolate) and IPZ:TZ-H13S (sinus isolate). Experimental infection of two BALB/c-nu/Alo/Hsd mice with 10^7 spores of IPZ:TZ-H13U and processing of infected monolayers or mice organs for electron microscopy were performed as previously described [6].

Western blot analysis of spore antigens with use of antisera to *Encephalitozoon* species and to spores of IPZ:TZ-H13U was performed as previously described [5]. Spores of the following

Received 15 April 1998; revised 4 August 1998.

Grant support: This work was supported by the Swiss National Science Foundation (3200-049751.96/1).

Reprints or correspondence: Dr. Peter Deplazes, Institute of Parasitology, University of Zürich, Winterthurerstrasse 266A, 8057 Zürich, Switzerland.

Clinical Infectious Diseases 1998;27:1521–4

© 1998 by the Infectious Diseases Society of America. All rights reserved.
1058-4838/98/2706-0031\$03.00

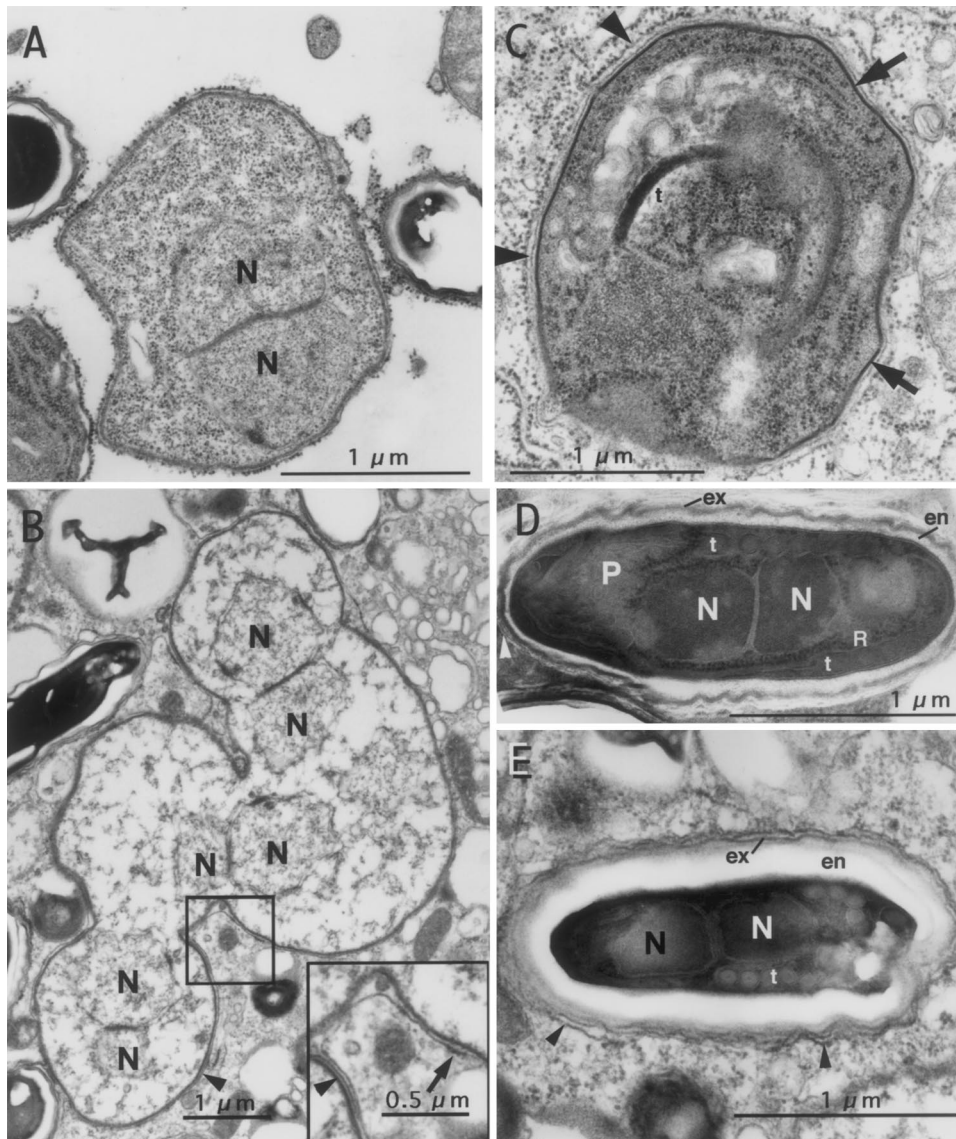


Figure 1. Electron microscopic characterization of the *Vittiforma corneae* isolate IPZ:TZ-H13U obtained from the urine of a patient with AIDS. *A*: Diplokaryotic meront in a disrupted hepatocyte that is still surrounded by a complete cisterna of endoplasmic reticulum, the outer membrane of which bears the ribosomes. *B*: Polysporoblastic sporont with three visible diplokarya in a cultured MRC-5 cell. The two membranes of the enveloping cisternae of endoplasmic reticulum (arrowheads) and the ribosomes on the external membrane (arrow) are visible in patches. *C*: Sporoblast in a hepatocyte that has an electron-dense surface coat (arrows) deposited on the plasma membrane beneath the enveloping cisterna of endoplasmic reticulum (arrowheads). The tubular structure (t) may be a section of the polar tube. *D*: Diplokaryotic spore in a cultured MRC-5 cell with five to six isofilar coils of the polar tube (t) that has a thick endospore (en), a moderately dense exospore (ex), polaroplast membranes (P), and ribosomes (R) within a cisterna of endoplasmic reticulum (arrowhead). *E*: Diplokaryotic spore in a cultured MRC-5 cell that has a thick endospore (en), a moderately dense exospore (ex), and five isofilar coils of the polar tube (t) within a cisterna of endoplasmic reticulum (arrowheads). N = nucleus.

reference isolates were available: *Encephalitozoon cuniculi* strains IPZ:CH-H14 ("rabbit" strain) and IPZ:MX-H5 ("dog" strain); *Encephalitozoon hellem* IPZ:CH-H1 and *Encephalitozoon intestinalis* IPZ:D-H11 (both characterized as previously described [5, 7]); *Nosema algerae* (kindly provided by T. Trammer, Bonn, Germany); and *V. corneae* (the previously described isolate [2]; kindly provided by Dr. E. S. Didier, Covington, LA). All reference isolates (except *N. algerae*) were cultivated in MRC-5 cells for spore production.

Riboprinting of cultured spores of both isolates was performed as described earlier [5]. For further characterization of IPZ:TZ-H13U, two PCR primers targeted to the small subunit (SSU) rRNA gene and designed to be specific to Microsporidia were selected (primer MI1, 5'-CCAGCAGCCGCGGTA-ATAC-3'; primer MI2, 5'-CGCACAATCCACTCCTTGTTG-

3'). The PCR products were directly sequenced with the Stratagene Cyclist Kit (Stratagene, La Jolla, CA).

Results

Intracellular multiplication of the parasites was observed in the cultures 2–3 weeks after inoculation of the sinus aspirate and the urine sediment. Growth characteristics of the isolate from the sinus aspirate (IPZ:TZ-H13S) were reminiscent of those of *E. hellem*. The parasites recovered from the urine sample (IPZ:TZ-H13U) had infiltrative growth, with only few spores being released into the supernatant.

Disseminated (liver, kidney, and spleen) lethal infections were observed 2–3 weeks after experimental infection of two

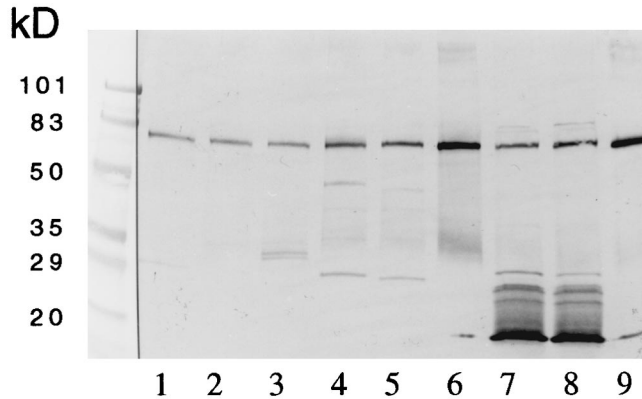


Figure 2. Western blot analysis of purified microsporidial spores. Lane 1, *Encephalitozoon hellem* IPZ:TZ-H13S from a sinusal aspirate from a patient with AIDS; lane 2, *E. hellem* IPZ:CH-H1 (reference isolate); lane 3, *Encephalitozoon intestinalis* IPZ:D-H11; lane 4, *Encephalitozoon cuniculi* IPZ:CH-H14; lane 5, *E. cuniculi* IPZ:MX-H5; lane 6, *Nosema algerae*; lane 7, *Vittaforma corneae* IPZ:TZ-H13U from the AIDS patient's urine; lane 8, *V. corneae* (reference isolate [2]); and lane 9, MRC-5 cells. Pooled sera from three mice immunized with purified spores of IPZ:TZ-H13U were used. (kD = kilodalton)

athymic mice with IPZ:TZ-H13U; these infections were determined by light microscopy of smear preparations.

In the cultures of IPZ:TZ-H13S, spores were *Encephalitozoon*-like (about $2 \times 0.8 \mu\text{m}$ in size), whereas spores of IPZ:TZ-H13U measured $2.9 \times 1.0 \mu\text{m}$. Electron microscopic investigations of IPZ:TZ-H13U with use of infected MRC-5 cells and livers of athymic mice revealed a heavily infected cell cytoplasm with randomly distributed parasites exhibiting one or several pairs of nuclei in a diplokaryotic arrangement, according to the stage of development. In all developmental stages including meronts (figure 1A), sporonts (figure 1B), sporoblasts (figure 1C), and spores (figures 1D and 1E), two membranes corresponding to a cisterna of host endoplasmic reticulum surrounding the parasite were seen; the outer of these two membranes was studded with ribosomes. The ribbonlike sporonts were polysporoblastic (figure 1B). In the spores, the nuclei filled about one-half the diameter, and the remaining space around and posterior to the nuclei was occupied by polyribosomes and five to six isofilar coils of the polar tube. The polaroplast was made up of about 10 closely packed membranes around a central zone of loosely folded membranes. The spore wall was irregular.

Western blot analysis, designed to differentiate *Encephalitozoon* species, identified IPZ:TZ-H13S as *E. hellem*. In contrast, western blot analysis of sera from mice immunized with spores of IPZ:TZ-H13U revealed that the banding patterns for this isolate were identical to those of the reference isolate of *V. corneae* (figure 2).

Riboprinting with spores of IPZ:TZ-H13S yielded a pattern that was identical to that of *E. hellem*. The sequence of the SSU

rRNA gene was 100% identical to that of *E. hellem* IPZ:CH-H1 [7]. A novel riboprint of IPZ:TZ-H13U was obtained (data not shown). With use of primers MI1 and MI2, PCR analysis of DNA from this isolate demonstrated a sequence that was 100% identical to that of *V. corneae* (positions 487–726 of the SSU rRNA gene).

Discussion

The patient described herein had an upper respiratory complaint as well as urogenital symptoms. *Encephalitozoon*-like spores were found in a sinusal aspirate, but spores of a slightly different size and shape were identified in three urine specimens collected on different days. In vitro isolation and further characterization of the isolates revealed that the spores in the sinus aspirate were *E. hellem* and that those in the urine were *V. corneae*. A few spores of the *Encephalitozoon* type were found in the stool. Further sites of infection were not investigated.

It was surprising that *E. hellem* could not be isolated from this patient's urine. In all cases of disseminated *E. hellem* infections reported so far, the kidney was a predominant site of infection, as evidenced by autopsy findings or the number of spores passed in the urine [1, 5]. It is unlikely that *E. hellem* was present in the urine samples because we failed to amplify *E. hellem* DNA from spores in the urine sediment by using *Encephalitozoon*-specific PCR analysis [8].

V. corneae spores in the urine sediment were propagated in vitro, and molecular and immunologic characterization revealed that the isolate was identical to the original isolate of *V. corneae* [2], which we received for comparative analysis after successful cultivation and morphological characterization of our isolate. The spores of our isolate were slightly smaller, and there was no evidence that the polar tube was anisofilar as had been found previously [6]; the smaller diameter coils, however, that were seen by Silveira et al. might have been incompletely formed, or the spore containing the coils could have been abnormal.

Until now, the microsporidian *V. corneae* had been isolated only from a corneal tissue specimen from an immunocompetent patient with keratitis and iritis [2, 9]. Subsequent experimental infection with this isolate in athymic mice [6] and our finding of a urinary tract infection due to *V. corneae* emphasize that this species is capable of surviving at mammalian body temperature in deep tissues, at least in immunocompromised hosts. It is likely that new cases will be found; however, as with most other microsporidia infecting humans, nothing is known about the source of infection.

References

1. Weber R, Bryan RT, Schwartz DA, Owen RL. Human microsporidial infections. *Clin Microbiol Rev* 1994;7:426–61.

2. Shadduck JA, Meccoli RA, Davis R, Font RL. First isolation of a microsporidian from a human patient. *J Infect Dis* **1990**;162:773–6.
3. Silveira H, Canning EU. *Vittaforma corneae* n. comb. for the human microsporidium *Nosema corneum* Shadduck, Meccoli, Davis & Font, 1990, based on its ultrastructure in the liver of experimentally infected athymic mice. *J Eukaryot Microbiol* **1995**;42:158–65.
4. Weber R, Bryan RT, Owen RL, Wilcox CM, Gorelkin L, Visvesvara GS. Improved light-microscopical detection of *Microsporidia* spores in stool and duodenal aspirates. *N Engl J Med* **1992**;326:161–6.
5. Deplazes P, Mathis A, Baumgartner R, Tanner I, Weber R. Immunologic and molecular characteristics of *Encephalitozoon*-like microsporidia isolated from humans and rabbits indicate that *Encephalitozoon cuniculi* is a zoonotic parasite. *Clin Infect Dis* **1996**;22:557–9.
6. Silveira H, Canning EU, Shadduck JA. Experimental infection of athymic mice with the human microsporidian *Nosema corneum*. *Parasitology* **1993**;107:489–96.
7. Mathis A, Michel M, Kuster H, Muller C, Weber R, Deplazes P. Two *Encephalitozoon cuniculi* strains of human origin are infectious to rabbits. *Parasitology* **1997**;114:29–35.
8. Katzwinkel-Wladarsch S, Deplazes P, Weber R, Löscher T, Rinder H. Comparison of polymerase chain reaction with light microscopy for detection of microsporidia in clinical specimens. *Eur J Clin Microbiol Infect Dis* **1997**;16:7–10.
9. Davis RM, Font RL, Keisler MS, Shadduck JA. Corneal microsporidiosis. A case report including ultrastructural observations. *Ophthalmology* **1990**;97:953–7.



This stamp was issued by Ethiopia on 31 January 1991 to publicize World Health Day and the fight against AIDS. It illustrates a man in the stages of the disease. (From the medical philately collection of Dr. J. N. Shanberge, University of Michigan.)