
UNIVERSITE DE LAUSANNE - FACULTE DE BIOLOGIE ET DE MEDECINE

Hôpital Ophtalmique Jules Gonin

**Mitochondrial DNA (mt DNA) A3243G mutation associated with an
annular perimacular retinal atrophy**

THESE

préparée sous la direction du Docteur François Xavier Borruat
Privat Docent, Maître d'Enseignement et de Recherche

et présentée à la Faculté de biologie et de médecine de
l'Université de Lausanne pour l'obtention du grade de

DOCTEUR EN MEDECINE

par

WWW
270
ADJ

Elias ADJADJ

BITE 3575

Médecin diplômé de la Confédération Suisse
Originaire de THônex (GE)

Lausanne

2010

Bibliothèque Universitaire
de Médecine / BiUM
CHUV-BH08 - Bugnon 46
CH-1011 Lausanne

2005 19601

Imprimatur

Vu le rapport présenté par le jury d'examen, composé de

Directeur de thèse Monsieur le Docteur François-Xavier Borruat

Co-Directeur de thèse

Expert

Directrice de l'Ecole doctorale Madame le Professeur Stephanie Clarke

la Commission MD de l'Ecole doctorale autorise l'impression de la thèse de

Monsieur Elias Adjadj

intitulée

*Mitochondrial DNA (mtDNA) A 3243G mutation associated
with an annular perimacular retinal atrophy.*

Lausanne, le 6 juillet 2010

*pour Le Doyen
de la Faculté de Biologie et de Médecine*



*Madame le Professeur Stephanie Clarke
Directrice de l'Ecole doctorale*

Résumé:

Background:

La mutation 3243 de l'ADN mitochondrial est associée avec le syndrome MIDD (surdit , diab te transmis par la m re) et le syndrome MELAS (Myopathie, Enc phalopathie, acidose Lactique et attaques c r brales). Elle est aussi associ e   des troubles cardiaques, digestifs, endo- et exocrines. Nous rapportons deux cas de maculopathie associ e   cette mutation.

Histoire et sympt mes:

Cas 1: il s'agit d'une femme de 60 ans souffrant d'un diab te et d'une surdit  sans plainte visuelle lors de la pr sentation. Son acuit  visuelle  tait de 10/10 des deux yeux.

Cas 2: il s'agit d'une femme de 54 ans souffrant d'une surdit  et d'un diab te qui se plaint d'une baisse de vision principalement de l' il gauche. Son acuit  visuelle  tait de 6/10 pour l' il droit et de 0.5/10 pour l' il gauche.

Les deux patientes pr sentaient une atrophie chorioretinienne ar olaire centrale. La patiente 1 a  t  suivie durant plus de 15 ans. Une  volution lente et progressive de la maculopathie a  t  observ e. Lors de la derni re visite, l'acuit  visuelle  tait de 6/10 dans les deux yeux. Elle pr sentait un handicap marqu  des suites du scotome annulaire.

Th rapie et pronostic:

aucun

Conclusion:

Les deux patientes pr sentaient une atrophie r tinienne annulaire p rimaculaire. Les patients atteints d'une mutation 3243 de l'ADN mitochondrial devraient b n ficier d'un examen du fond d' il   la recherche d'une maculopathie, m me s'ils sont asymptomatiques. Inversement, la d couverte d'une telle maculopathie g ographique devrait sugg rer la possibilit  d'une mutation au locus 3243 de l'ADN mitochondrial, surtout en pr sence d'un diab te et/ou d'une surdit .

Mitochondrial DNA (mtDNA) A 3243G Mutation Associated with an Annular Perimacular Retinal Atrophy

Mitochondriale DNA (mtDNA) A 3243G Mutation assoziiert mit einer ringförmigen perimakulären Netzhautatrophie

Autoren

E. Adjadj, K. Mansouri, F.-X. Borruat

Institut

Hôpital Ophtalmique Jules Gonin, Lausanne, Switzerland

Schlüsselwörter

- MtDNA
- 3243 Punktmutation
- Makula

Key words

- MtDNA
- point mutation 3243
- macular atrophy

Zusammenfassung

Hintergrund: Eine Punktmutation der mitochondrialen DNA ist assoziiert mit dem MIDD Syndrom (maternally inherited diabetes, deafness), mit dem MELAS Syndrom (Myopathie, Enzephalitis, Laktischer Azidose, Schlaganfall), Herz-, Magen-Darm-, endokriner und exokriner Störungen. Wir berichten hier über eine besondere Makulopathie in zwei Patienten mit einer mtDNA 3243 Mutation. Anamnese und Befund: **Fall 1: Eine 40-jährige asymptomatische Patientin wurde auf Diabetes untersucht. Sehschärfe war 10/10 in beiden Augen. Fall 2: Eine 54-jährige Patientin mit Taubheit und Diabetes litt unter Sehverlust. Sehschärfe war 6/10 für das rechte und 0,5/10 für das linke Auge. Beide Patientinnen präsentierten eine chorioretinale ringförmige Atrophie. Fall 1 wurde über 15 Jahre nachuntersucht und präsentierte ein langsames und gemäßigtes Fortschreiten der Makulopathie mit einem Sehverlust auf 6/10 beidseits, begleitet von einem gemäßigt behinderndem ringförmigen Skotom. Die Patientin 2 hatte keine weitere Nachuntersuchung. Therapie und Verlauf: Keine. Schlussfolgerung: Beide Patientinnen präsentierten eine perimakuläre ringförmige Netzhautatrophie. Patienten mit einer 3243 Mutation sollten auf eine Makulopathie untersucht werden, selbst bei asymptomatischem Status. Umgekehrt sollte das Vorliegen einer solchen geografischen Makulopathie auf die Möglichkeit einer Punktmutation des Locus 3243 der mitochondrialen DNA – besonders bei gleichzeitigem Diabetes mellitus und/oder Taubheit – hindeuten.**

Background

The mitochondrial DNA (mtDNA) is composed of 16,569 base pairs that have been fully sequenced

Abstract

Background: A point mutation at the locus 3243 of the mitochondrial DNA (mtDNA) is associated with either the MIDD syndrome (maternally inherited diabetes, deafness), the MELAS syndrome (myopathy, encephalitis, lactic acidosis, stroke) or cardiac, digestive, endocrine or exocrine dysfunctions. We report a peculiar maculopathy in two patients with an mtDNA 3243 mutation. History and Signs: **Case 1: A visually asymptomatic 40-year-old woman was examined for screening of diabetic retinopathy. Visual acuity was 10/10 in both eyes. Case 2: A 54-year-old woman with deafness and diabetes complained of visual loss. Visual acuity was 6/10 for the right eye and 0.5/10 for the left eye. Both patients exhibited a chorioretinal areolar atrophy. Case 1 was followed over 15 years and exhibited a slow progression of the maculopathy with moderate loss of visual acuity to 6/10 in both eyes, but marked handicap from the annular scotoma. Therapy and Outcome: None. Conclusion: Both patients presented a perimacular annular retinal atrophy. Patients harbouring mtDNA 3243 mutation should be examined for the presence of a maculopathy, even if they are asymptomatic. Conversely, the finding of such a geographic maculopathy should suggest the possibility of a point mutation at the locus 3243 of the mitochondrial DNA, especially in the presences of diabetes mellitus and/or deafness.**

[1]. The mtDNA inheritance is almost exclusively maternal [2] with the rare exceptions of some cases with paternal mtDNA transmission [9]. Sperm mitochondria disappear in early embryo-

eingereicht 13.9.2007

akzeptiert 1.12.2007

Bibliografie

DOI 10.1055/s-2008-1027257

Klin Monatsbl Augenheilkd
2008; 225: 462–464 © Georg
Thieme Verlag KG Stuttgart ·
New York · ISSN 0023-2165

Korrespondenzadresse

Dr. F.-X. Borruat

Hôpital Ophtalmique Jules
Gonin, Unité de Neuro-
ophtalmologie
Avenue de France 15
1004 Lausanne, Switzerland
Tel.: ++41/21/6 26 86 60
Fax: ++41/21/6 26 86 66
francois.borruat@ophtal.vd.ch

genesis by selective destruction, inactivation or simple dilution by the vast surplus of oocyte mitochondria. Several significant point mutations have been identified. The 3243 mtDNA point mutation has been associated with: MELAS syndrome (myopathy, encephalopathy, lactic acidosis, stroke), MIDD syndrome (maternally inherited diabetes and deafness), cardiac, digestive, endocrine and exocrine deficits [3, 4, 8, 11]. We report two patients with mtDNA 3243 point mutation who presented a peculiar annular maculopathy.

History and Signs

▼ Patient 1

A 40-year-old woman was referred for ophthalmological control of her diabetes mellitus. She was visually asymptomatic. Her visual acuity was 10/10 in both eyes. There was no diabetic retinopathy, but fundus examination revealed a bilateral annular and perimacular chorioretinal atrophy. Diabetes mellitus was diagnosed at age 30 and a hypoacusia was noticed since age 27 (hearing aids since then). At age 49, lactic acidosis and rhabdomyolysis were discovered during investigations for parainfectious subacute dyspnea. At age 55 she presented a pseudobulbar syndrome and a cerebral MRI showed calcifications of the basal ganglia. Visual impairment was now present, impinging on daily life of the patient (reading, shopping). Her visual acuity was 6/10 in both eyes and an annular perimacular scotoma was present by Goldmann kinetic perimetry (● Fig. 1). Fundus examination revealed a progression of the perifoveolar chorioretinal atrophy. A few haemorrhages were scattered at the posterior pole (early diabetic retinopathy) (● Fig. 2). Oculomotility was mildly symmetrically restricted in all direction of gaze more so far with slow saccades in all directions. A point mutation of the mtDNA at the locus 3243 was then found, and a diagnosis of MELAS was given. Family history was remarkable for diabetes mellitus and deafness in her mother, but genetic testing was not performed.

Patient 2

A 54-year-old woman was referred for investigations of a visual impairment of two years duration. Visual acuity was 6/10 in the right eye and 0.5/10 in the left eye. Colour vision was 12/13 RE and 0/13 LE on Ishihara pseudoisochromatic plates. Pericentral annular scotoma was present in both eyes, more pronounced in the left eye. The sensitivity of the remaining central island of vision was normal in the right eye and decreased in the left eye (● Fig. 3). Fundus examination revealed a well-circumscribed perifoveolar chorioretinal atrophy, more pronounced in the LE. There was no diabetic retinopathy (● Fig. 4). Scotopic and pho-

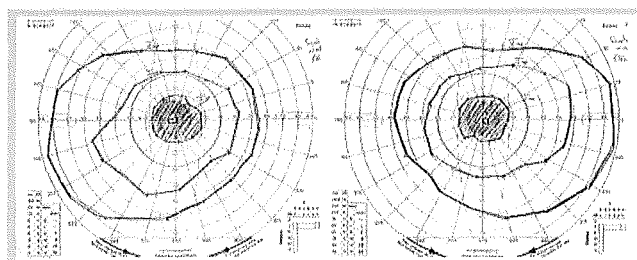


Fig. 1 Patient 1 at age 55. Goldmann kinetic perimetry revealed absolute annular scotoma extending to 15–20 degrees with a remaining island of central vision in both eyes.

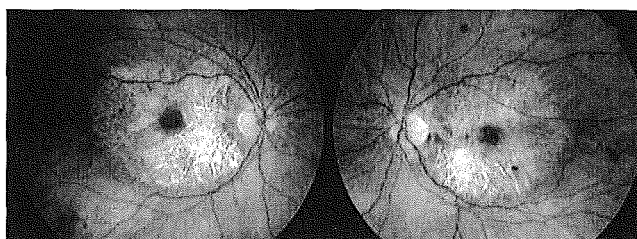

Fig. 2 Patient 1 at age 55. Fundus photography showing perifoveolar chorioretinal atrophy with the preservation of a central island of remaining retina in both eyes. Early diabetic retinopathy was now present (few scattered retinal haemorrhages).

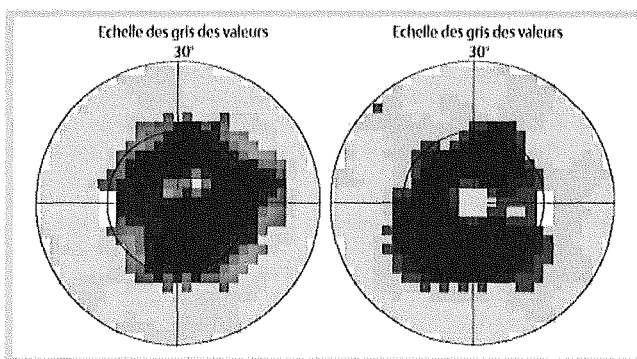


Fig. 3 Patient 2. Threshold automated static perimetry revealed absolute annular scotoma extending to 15 degrees in both eyes with a remaining island of central vision of normal sensitivity in the right eye and decreased sensitivity in the left eye.

topic full field ERG was normal in both eyes. Multifocal ERG was performed only for the RE and showed moderately decreased amplitudes of the central 20 degrees. Bilateral hypoacusia was

	diagnosis	number of patients	age (years) mean ± std dev	sex ratio (M/F)	macular atrophy	visual acuity loss
Sue et al. [11]	MELAS	14	42 ± 17,6	6/8	57%	7,1%
Massin et al. [7]	MIDD	35	49,4 ± 10,5	13/22	85,7%	26%
	MELAS asymptomatic carriers	12	46 ± 2	3/9	66,6%	33,3%
Smith et al. [10]	MIDD	13	49,4	4/9	77%	23%
Latvala et al. [5]	MELAS	26	44 ± 14	5/21	38%	15,4%

Table 1 Presence of macular lesion in patients with 3243 mtDNA point mutation (MELAS: myopathy, encephalitis, lactic acidosis, stroke; MIDD: maternally inherited diabetes, deafness)

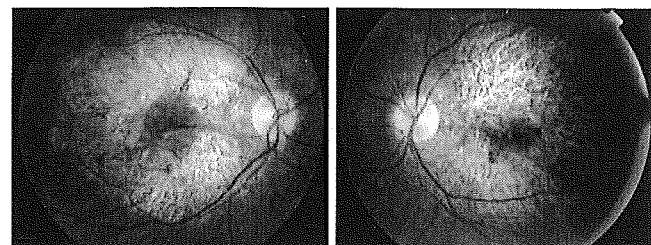


Fig. 4 Patient 2. Fundus photography showing perifoveolar chorioretinal atrophy with the preservation of a central island of remaining retina, more so in the right eye.

present since age 40, with hearing aids since. Non insulin-dependent diabetes mellitus was diagnosed at age 51. Point mutation at 3243 of the mtDNA was found. A diagnosis of MIDD was made.

Family history revealed hypoacusia in her mother, sister and niece, but none suffered from visual loss or diabetes mellitus. Genetic testing was not performed.

Therapy and Outcome

No specific therapy was given. Progressive but slow visual impairment occurred in Case 1 (increased pericentral scotoma and decreased visual acuity), in parallel to the progression of the pericentral chorioretinal atrophy over 15 years of follow-up. No follow-up was available for Case 2.

Discussion

The prevalence of 3243 mtDNA point mutation in the general population is 2.36% [7]. The prevalence of MELAS and MIDD is unknown. However, 0.5 to 2.8% of diabetic patients carry the 3243 mtDNA point mutation, all with hearing loss [4]. Retinal dystrophy is frequently found in MIDD (86%) [4, 8] and has been reported as frequent as 38–57% in two series of 26 and 14 MELAS cases respectively [6, 12]. In both MIDD and MELAS the progression of the retinopathy is slow and visual acuity is usually preserved until the late stage of the disease, as illustrated by our two patients.

Despite the same 3243 mtDNA point mutation, some patients will present MIDD and others MELAS. It looks like MIDD might represent a milder form of the 3243 mtDNA point mutation as MIDD and MELAS share some identical phenotypes (diabetes mellitus, hypoacusia, retinopathy) but MELAS is further associated with encephalopathy, lactic acidosis, and myopathy. Patient 1 suffered from MELAS and exhibited also a global ophthalmoplegia and complained of dysphagia. In one study, four members of a single family with 3243 mtDNA point mutation (one with MELAS) were examined and only one (the patient with MELAS) exhibited a geographical atrophy of the macula [5]. Hence, phenotypic expression varies markedly amongst patients carrying a 3243 point mutation of the mtDNA. There are multiple copies of mtDNA per cell. In some cases, only a fraction of these mtDNA copies carries the mutation (heteroplasmy). Variation of heteroplasmy in different tissues might explain at least partly the observed variations of phenotype [14]. An annular geographic retinal atrophy in the setting of diabetes

mellitus and hearing loss is very suggestive of 3243 mtDNA point mutation. Genetic screening should be performed, at least for genetic counselling. Since mtDNA is maternally transmitted, only women's offspring could be affected by the mutation and the children from affected fathers will most likely not exhibit the disease. In the presence of a maculopathy, full-field ERG can determine whether the retinopathy is limited to the macular area (normal full-field ERG results) or is more diffuse (abnormal full-field ERG results), hence carrying a worse visual prognosis.

Only a few studies addressed the question of treatment. In one study, the long-term treatment of patients with a 3243 point mutation of the mtDNA using co-enzyme Q10 influenced favourably the clinical course of the diabetes, the exercise intolerance and the hearing loss in some patients. However the clinical course of the retinopathy was not affected by the therapy [13]. In another study no effects were demonstrated with L-carnitine [10].

In summary, the retinopathy of patients carrying 3243 mtDNA point mutation involves the pericentral retina, sparing the peripheral retina outside the central 20 degrees. A relentless but slow progression of the annular scotoma is the rule. Nevertheless, visual acuity is usually preserved until the advanced stage of the disease.

Conflict of Interest: None

References

- Anderson S, Bankier AT, Barrell BG et al. Sequence and organisation of the human mitochondrial genome. *Nature* 1982; 290: 457–465
- Egger J, Wilson J. Mitochondrial inheritance in a mitochondrially mediated disease. *N Engl J Med* 1983; 309: 142–146
- Goto Y, Nonaka I, Horai S. A mutation in the tRNA Leu(uuR) gene associated with the MELAS subgroup of mitochondrial encephalomyopathies. *Nature* 1990; 348: 651–653
- Guillausseau PJ, Massin P, Dubois-LaForgue D et al. Maternally inherited diabetes and deafness: a multicenter study. *Ann Intern Med* 2001; 134: 721–728
- Latkany P, Ciulla TA, Cacchillo PF et al. Mitochondrial maculopathy: geographic atrophy of the macula in the MELAS associated A to G3243 mitochondrial DNA point mutation. *Am J Ophthalmol* 1999; 128: 112–114
- Latvala T, Mustonen E, Uusitalo R et al. Pigmentary retinopathy in patients with the MELAS mutation 3243A(G in mitochondrial DNA. *Graefes Arch Clin Exp Ophthalmol* 2002; 240: 795–801
- Manwaring N, Jones MM, Wang JJ et al. Population prevalence of the MELAS A3243G mutation. *Mitochondrion* 2007; 7: 230–233
- Massin P, Virally-Monod M, Vialettes B et al. Prevalence of macular pattern dystrophy in maternally inherited diabetes and deafness. *Ophthalmology* 1999; 106: 1821–1827
- Schwartz M, Vissing J. Paternal inheritance of mitochondrial DNA. *N Engl J Med* 2002; 347: 576–580
- Silvestre-Aillaud P, BenDahan D, Paquis-Fluckinger V et al. Could coenzyme Q10 and L-carnitine be a treatment for diabetes secondary to 3243 mutation of mtDNA? *Diabetologia* 1995; 38: 1485–1486
- Smith PR, Bain SC, Good PA et al. Pigmentary retinal dystrophy and the syndrome of maternally inherited diabetes and deafness caused by the mitochondrial DNA 3243 tRNA(Leu) A to G mutation. *Ophthalmology* 1999; 106: 1101–1108
- Sue CM, Mitchell P, Crimmins DS et al. Pigmentary retinopathy associated with the mitochondrial DNA 3243 point mutation. *Neurology* 1997; 49: 1013–1017
- Suzuki S, Hinokio Y, Ohtomo M et al. The effects of coenzyme Q10 treatment on maternally inherited diabetes mellitus and deafness, and mitochondrial DNA 3243 (A to G) mutation. *Diabetologia* 1998; 41: 584–588
- Takeshima T, Nakashima K. MIDD and MELAS: a clinical spectrum. *Intern Med* 2005; 44: 276–277

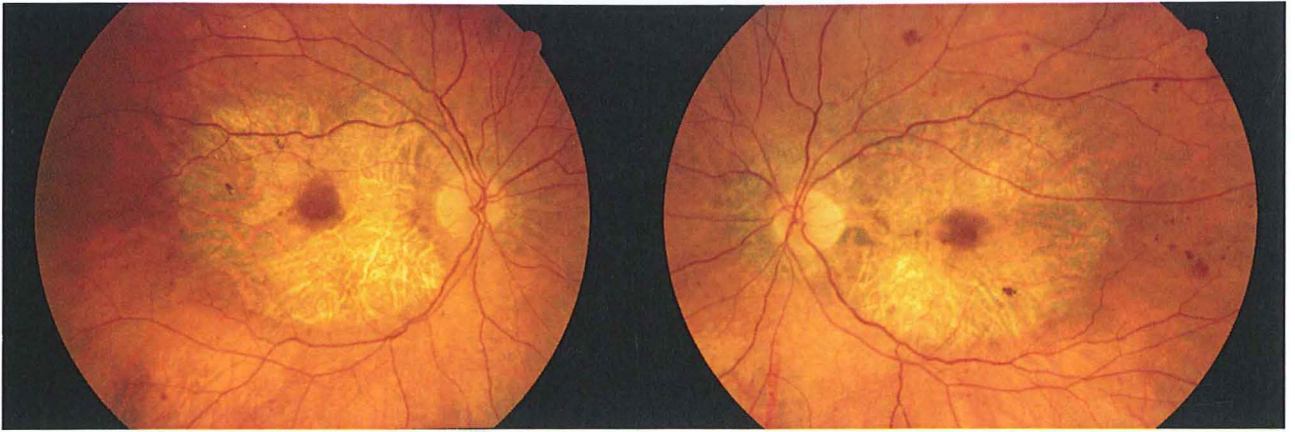


Figure 2: patiente 1 à l'âge de 55 ans; la photo du fonds d'oeil montre une atrophie chorioretinienne périfovéolaire avec préservation d'un îlot central de rétine des deux côtés.

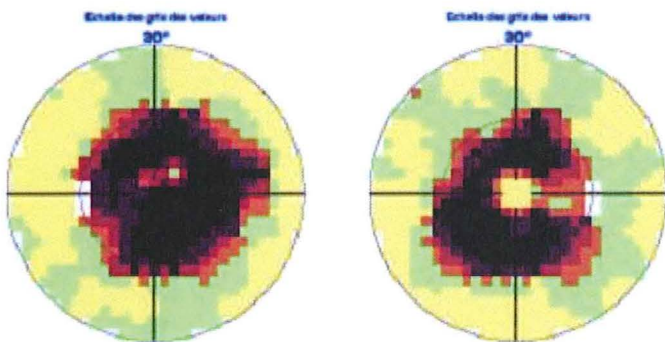


Figure 3: patiente 2; la périmétrie statique automatisée montre un scotome annulaire s'étendant aux 15° dans les deux yeux avec un îlot de vision centrale de sensibilité normale à l'oeil droit et de sensibilité diminuée dans l'oeil gauche

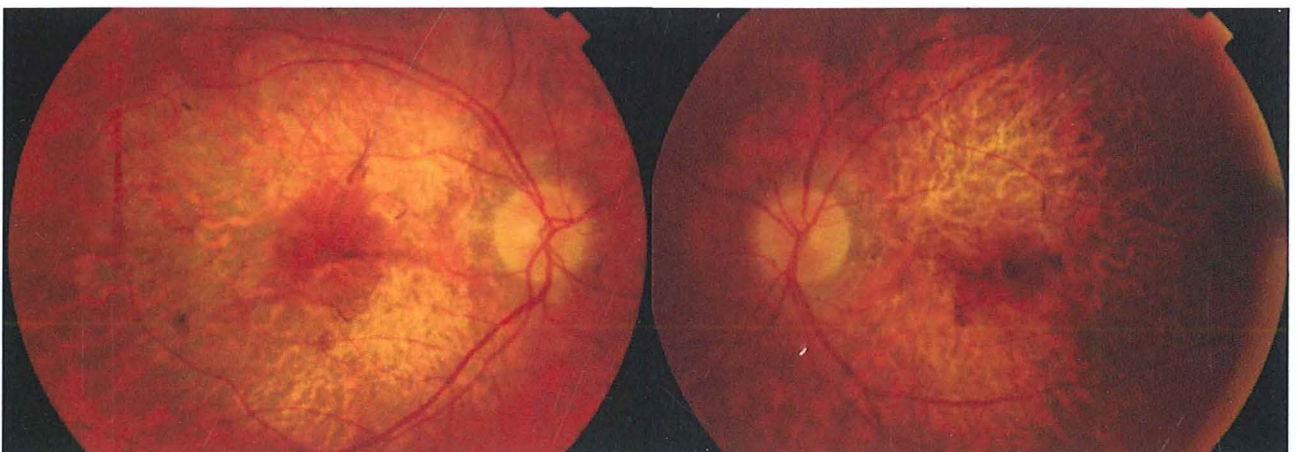

Figure 4: Patiente 2; la photographie du fonds d'oeil montre une atrophie chorioretinienne perifovéolaire avec préservation d'un îlot centrale de rétine, principalement dans l'oeil droit