

## Prevalence and Types of Pitfall in the Assessment of Mitral Isthmus Linear Conduction Block

Ashok J. Shah, Patrizio Pascale, Shinsuke Miyazaki, Xingpeng Liu, Laurent Roten, Nicolas Derval, Amir S. Jadidi, Daniel Scherr, Stephen B. Wilton, Michala Pedersen, Sebastien Knecht, Frédéric Sacher, Pierre Jaïs, Michel Haïssaguerre and Mélèze Hocini

*Circ Arrhythm Electrophysiol.* 2012;5:957-967; originally published online August 31, 2012;  
doi: 10.1161/CIRCEP.112.971259

*Circulation: Arrhythmia and Electrophysiology* is published by the American Heart Association, 7272 Greenville Avenue, Dallas, TX 75231

Copyright © 2012 American Heart Association, Inc. All rights reserved.

Print ISSN: 1941-3149. Online ISSN: 1941-3084

The online version of this article, along with updated information and services, is located on the World Wide Web at:

<http://circep.ahajournals.org/content/5/5/957>

Data Supplement (unedited) at:

<http://circep.ahajournals.org/content/suppl/2012/08/31/CIRCEP.112.971259.DC1.html>

**Permissions:** Requests for permissions to reproduce figures, tables, or portions of articles originally published in *Circulation: Arrhythmia and Electrophysiology* can be obtained via RightsLink, a service of the Copyright Clearance Center, not the Editorial Office. Once the online version of the published article for which permission is being requested is located, click Request Permissions in the middle column of the Web page under Services. Further information about this process is available in the [Permissions and Rights Question and Answer](#) document.

**Reprints:** Information about reprints can be found online at:  
<http://www.lww.com/reprints>

**Subscriptions:** Information about subscribing to *Circulation: Arrhythmia and Electrophysiology* is online at:  
<http://circep.ahajournals.org/subscriptions/>

# Prevalence and Types of Pitfall in the Assessment of Mitral Isthmus Linear Conduction Block

Ashok J. Shah, MD; Patrizio Pascale, MD; Shinsuke Miyazaki, MD; Xingpeng Liu, MD; Laurent Roten, MD; Nicolas Derval, MD; Amir S. Jadidi, MD; Daniel Scherr, MD; Stephen B. Wilton, MD, PhD; Michala Pedersen, MD, PhD; Sebastien Knecht, MD, PhD; Frédéric Sacher, MD; Pierre Jaïs, MD; Michel Haïssaguerre, MD; Mélèze Hocini, MD

**Background**—To identify and understand clinically encountered pitfalls in the assessment of transmitral conduction block using differential coronary sinus and left atrial appendage pacing techniques in patients with left mitral isthmus linear ablation.

**Methods and Results**—All the available assessments of mitral isthmus block were thoroughly reviewed in 271 mitral isthmus ablation procedures undertaken among 236 patients from October 2008 to April 2011. Bidirectional block was established in 186 of 271 (69%) procedures. Careful evaluation of electrograms recorded on the multipolar coronary sinus and ablation catheters was undertaken to identify and understand the characteristics of pitfall, if any. Pitfall was encountered in 55 of 271 (20%) procedures among 51 patients and categorized into 6 types (types 1, 3, 4, and 5 led to spurious diagnosis of block; types 2 and 6 led to erroneous diagnosis of absence of block). There were 14, 10, 17, 2, 15, and 3 (total=61) cases of pitfall types 1 through 6, respectively. Operator recognized 42 of 61 (69%) pitfalls intraprocedurally. Recognition of types 1 and 5 was difficult because of indiscernible electrograms at usual amplifier settings or presence of slow conduction mimicking block.

**Conclusions**—Every fifth assessment of bidirectional block across mitral isthmus linear lesion using differential coronary sinus and left atrial appendage pacing techniques encounters a pitfall, which can lead to erroneous clinical diagnosis of block or absence of block. Recognition of pitfall during the procedure is feasible and necessitates careful distinction of far-field left atrium from the local coronary sinus electrograms besides appropriate adjustments in catheter position and pacing outputs. (*Circ Arrhythm Electrophysiol.* 2012;5:957-967.)

**Key Words:** bidirectional block ■ differential pacing ■ linear ablation ■ mitral isthmus ■ pitfall

The Heart Rhythm Society/European Heart Rhythm Association/European Cardiac Arrhythmia Society expert consensus statement recommends transmural and bidirectional (complete) block across the linear lesion as the end point of left mitral isthmus (MI) ablation.<sup>1</sup> Differential pacing from the coronary sinus (CS) is a commonly used method for the assessment of completeness of MI linear lesion.<sup>1,2</sup> In the seminal paper describing differential pacing technique, the authors reported 100% sensitivity and 75% specificity toward the assessment of completeness of cavotricuspid isthmus linear block using this technique.<sup>2</sup> The differential pacing technique is also used for the evaluation of conduction across the MI linear lesion using 2 catheters in a fixed position, one in the CS epicardially and another across the ablation line endocardially. As in other electrophysiological procedures, epicardial CS electrograms can be used as a surrogate for endocardial left atrial (LA) signals. However, CS activation can differ from the contiguous LA activation. In addition, their respective electrograms can also

mutually vary in amplitude and duration. Sometimes, the signal can be fractionated and multicomponent. Although the evaluation technique is reliable in principle, careful signal analysis and discrimination of the local CS from the far-field LA electrograms are necessary.<sup>3</sup> We evaluated the assessments of linear block across the MI linear lesions performed using conventional pacing techniques to understand and characterize the challenges encountered during this process.

## Clinical Perspective on p 967

### Methods

This retrospective observational study included all patients who underwent left MI linear ablation and assessment of bidirectional block using differential CS and LA appendage (LAA) pacing techniques at our institute from October 2008 to April 2011. The assessment of MI block performed during and at the end of the ablation was reviewed in the procedures included in the study after blinding the reviewers (A.J.S. and P.P.) to the final diagnosis of presence or absence of MI block. Pitfall in the assessment of bidirectional MI

Received February 3, 2012; accepted August 6, 2012.

From the Hôpital Cardiologique du Haut-Lévêque and Université Victor Segalen, Bordeaux II, Bordeaux-Pessac, France.

The online-only Data Supplement is available at <http://circep.ahajournals.org/lookup/suppl/doi:10.1161/CIRCEP.112.971259/-/DC1>.

Correspondence to Ashok J. Shah, MD, Hôpital Cardiologique du Haut-Lévêque, Ave de Magellan, 33604 Bordeaux, France. E-mail drashahep@gmail.com  
© 2012 American Heart Association, Inc.

*Circ Arrhythm Electrophysiol* is available at <http://circep.ahajournals.org>

DOI: 10.1161/CIRCEP.112.971259

block, if any, was identified and categorized into types 1 through 6. The definition of each type is provided below. The prevalence of pitfall and its recognition during the procedure were also determined for each type.

### Electrophysiological Study

Antiarrhythmic medications were discontinued  $\geq 5$  half-lives before ablation, with the exception of amiodarone. For at least 1 month before the procedure, patients took oral anticoagulants and achieved target international normalized ratio of 2 to 3. Transesophageal echocardiography was performed within 5 days to exclude atrial thrombus. Oral anticoagulation was stopped 48 hours before the procedure and resumed on the day after the ablation. After transseptal access, an intravenous bolus of heparin (0.5 mg/kg of body weight) was administered and repeated after 3 to 4 hours if the activated clotting time was  $< 250$  seconds.

Femoral venous access was established under local anesthesia and conscious sedation. A steerable decapolar more often than quadripolar catheter (5-mm electrode spacing, Xtrem, ELA Medical) was placed within the CS. Surface and bipolar endocardial ECGs were continuously monitored at a sweep speed of 100 mm/s and recorded (Labsystem Pro; Bard, Tewksbury, MA). ECG and intracardiac electrograms were filtered from 0.05 to 100 Hz and 30 to 500 Hz, respectively.

### MI Ablation

MI ablation was performed during CS pacing by creating a linear lesion joining the posterior lateral mitral annulus to preferably the left inferior pulmonary vein or more laterally to the base of the LAA.<sup>4</sup> The distal tip of the CS catheter was located at 4 O'clock on the mitral annulus, and pacing was undertaken from the bipole (mostly CS1–2) located immediately septal to the line. Ablation was performed using a 3.5-mm externally irrigated tip catheter (Thermocool, Biosense-Webster, Diamond Bar, CA). The ablation catheter was introduced through the long sheath to gain stability during ablation. The catheter was curved 90° to 180°, and ablation commenced at around 3 to 4 O'clock near the ventricular edge of the mitral annulus. The catheter was dragged gradually back into the sheath while maintaining clockwise torque on the sheath catheter assembly, and the lesion was extended along the isthmus in a linear fashion up to the left inferior pulmonary vein ostium. If this was not successful or technically difficult, a line was drawn laterally up to the base of the LAA. Radiofrequency (RF) energy was delivered for 90 to 120 seconds at each site, with a delivery end point of  $\geq 90\%$  reduction in the amplitude of local electrogram. The stability of the catheter was monitored by intermittent fluoroscopy to

exclude inadvertent displacement especially high on the line where the catheter could drop into the left inferior pulmonary vein or the body of the LAA. The electrograms were continuously monitored on the proximal bipole of the ablation catheter to look for increments in conduction delay from the pacing artifact during ongoing RF application. Splitting of the local potentials, resulting in an increase in the delay from the pacing artifact, was suggestive of an effective local lesion. After initial ablation, endocardial mapping along the line was performed to identify and ablate the gaps defined as sites showing the shortest delay between the pacing artifact and the local electrogram, which could be minimally delayed single, narrow double, or fractionated potential. Endocardial ablation was performed with a flow rate of 17 to 60 mL/min and a target temperature of 45°C (usually  $< 42^\circ\text{C}$ ) with power up to 35 W. Epicardial ablation was undertaken after prolonged energy delivery on the endocardium failed to substantially impact the conduction delay or attain block across the linear lesion. Epicardial ablation was performed in the distal CS with power up to 20 to 25 W.

### Differential Pacing Technique and Bidirectional Block

Pacing was undertaken usually from the distal CS (CS 1–2) bipole lying on the septal side of and immediately below the MI ablation line. The delay from the pacing artifact was recorded on the catheter lying across the line or in the LAA. This delay was compared with the one recorded subsequently by pacing from a more proximal site below the line (usually bipole CS 3–4). If the latter was shorter than the former, a linear block was established. This method is called unidirectional block assessment using differential CS pacing. Next, the block was evaluated in the opposite direction by pacing from the ablation catheter placed lateral to the line (or in the LAA), endocardially. Proximal-to-distal activation sequence was observed along the CS catheter lying septal to the line in the presence of bidirectional conduction block. Differential pacing was not undertaken for assessment of block in this direction.

Pacing from sites not close to the line of block violates the principle of differential pacing. Slow conduction along the linear lesion could be masked in such circumstances (online-only Data Supplement Figure). Although such a situation was avoided carefully as far as possible, it was necessary to pace and record farther from the lesion because of various reasons including inability to capture at the pacing site and indiscernible signal at the recording site close to the lesion.

**Table. Definition of Types of Pitfall and Their Characteristic Features**

Parameter	Linear Block						
	Normal	Pitfall 1	Pitfall 2	Pitfall 3	Pitfall 4	Pitfall 5	Pitfall 6
Definition							
Differential CS pacing: CS 1–2 to LAA $>$ CS 3–4 to LAA	+	+	–	–	–	=/–/+	–
LAA pacing: proximal to distal CS activation	Endo+epi	Epi	Endo+epi	Epi	Endo	In the most part endo+epi	Endo+epi
Features							
Characteristic feature	...	Lack of endocardial capture during CS pacing	Capture on both sides of the line during CS pacing	Conduction across the linear lesion persists endocardially	Conduction across the linear lesion persists epicardially	Slow Conduction persists at least unidirectionally allowing fusion of activation in distal CS during LAA pacing	Recording on the same side of the line as CS pacing
Complete block (actual)	Yes	No	Yes	No	No	No	Yes
Conduction gap	None	Endo	None	Endo	Epi	Endo+Epi	None
Requirement of further ablation in the gap	None	Yes	None	Yes	Yes	Yes	None

CS indicates coronary sinus; LAA, left atrial appendage; endo, endocardial; epi, epicardial.

+ symbolizes presence and – symbolizes absence.

## Pitfall

Careful inspection of electrograms recorded on the decapolar (less frequently, quadripolar) catheter inside the CS during the differential CS and LAA pacing maneuvers for the assessment of transmitral conduction was undertaken. The Table provides the definition and other features of pitfall types 1 through 6.

Briefly, the defining feature of each type of pitfall is mentioned below:

Type 1: Capture of local CS (epicardial) but not contiguous LA (endocardial) simultaneously during differential CS pacing results in spurious diagnosis of complete (endocardial+epicardial) block (Figure 1A and 1B). Endocardial gap is revealed during LAA pacing (Figure 1C) and reascertained by differential CS pacing at higher output to ensure the simultaneous capture of contiguous LA (Figure 1D).

Type 2: Pacing from CS 1–2 results in shorter (or equal) delay to the recording site than pacing from CS 3–4 (Figure 2A and 2B). On the other hand, pacing from the LAA or the site lying across the linear lesion results in proximal-to-distal pattern of CS activation (Figure 2C), suggestive of block. Simultaneous capture on both sides of the line during distal CS pacing results in spurious conclusion of absence of complete block. Differential CS pacing at a lower output to avoid capture across the linear lesion ascertains complete block (Figure 2D).

Type 3: Endocardial conduction gap and epicardial conduction block. Differential CS pacing indicates the absence of linear block, whereas pacing from LAA (across the line) reveals that the transmitral conduction is blocked epicardially with a gap located endocardially (Figure 3).

Type 4: Epicardial conduction gap and endocardial conduction block. Differential CS pacing indicates the absence of linear block (Figure 4), whereas pacing from LAA (across the line) reveals that the transmitral conduction is blocked endocardially with a gap located epicardially (Figure 5A and 5B). The endocardial block is confirmed by differentially pacing from the LA instead of the CS (Figure 5C).

Type 5: The delay to the recording site across the lesion (usually LAA) from CS 1–2 pacing may be equal to, shorter, or longer than from the CS 3–4 pacing (Figure 6A and 6B). Pacing from LAA (across the line) reveals that CS 1–2 activation occurs earlier than or simultaneously with CS 3–4. The remainders of the CS bipoles are activated in the proximal-to-distal direction (Figure 6C).

Type 6: Measurement of delay at the recording site on the same side of the line during CS pacing spuriously leads to the diagnosis of conduction gap. This usually happens on the top of the line in a transmurally blocked isthmus (Figure 7).

In summary, pitfall in the assessment of transmitral isthmus linear block could be responsible for spurious diagnosis of block (types 1, 3, 4, and 5) or false diagnosis of absence of block (types 2 and 6).

## Statistical Analysis

Continuous variables are expressed as mean±SD, if normally distributed, or median with interquartile range, when not. Statistical significance was assessed using the unpaired Student *t* test or Wilcoxon 2-sample test. Categorical variables, expressed as numbers or percentages, were analyzed using the  $\chi^2$  test or Fisher exact test. All tests were 2-tailed, and  $P < 0.05$  was considered statistically significant. SAS software was used for statistical analyses.

## Results

From October 2008 to April 2011, 318 left MI ablation procedures (among 262 patients) were undertaken as a part of index or repeat ablation of atrial fibrillation. Bidirectional assessment of transmitral conduction was recorded and available for review in 271 of 318 MI ablation procedures among 236 of

262 patients. At the end of the procedure, bidirectional block was established in 186 of 271 (69%) procedures.

## Clinical Characteristics

The clinical characteristics of 236 patients (divided into 2 groups: pitfall present and pitfall absent) are provided in online-only Data Supplement Table SI. There was no statistically significant difference in the patient profile, including the clinical type of atrial fibrillation and the echocardiographic dimensions between the patients with and without an observed pitfall.

## Procedural Parameters

In online-only Data Supplement Table SII, the procedural parameters have been compared between the above-cited 2 groups of the study population. Similar proportions of patients in both the groups were subjected to >1 ablation procedure. There was no difference in the total duration of RF energy delivery, procedural duration, and fluoroscopic exposure among the patients in the 2 groups. When the duration of RF ablation for each region (pulmonary vein antrum, roof, MI, CS, and the rest of the LA corpus) was compared individually between the 2 groups, there was no evidence of significant selective ablation in any specific region.

## Prevalence of Pitfall

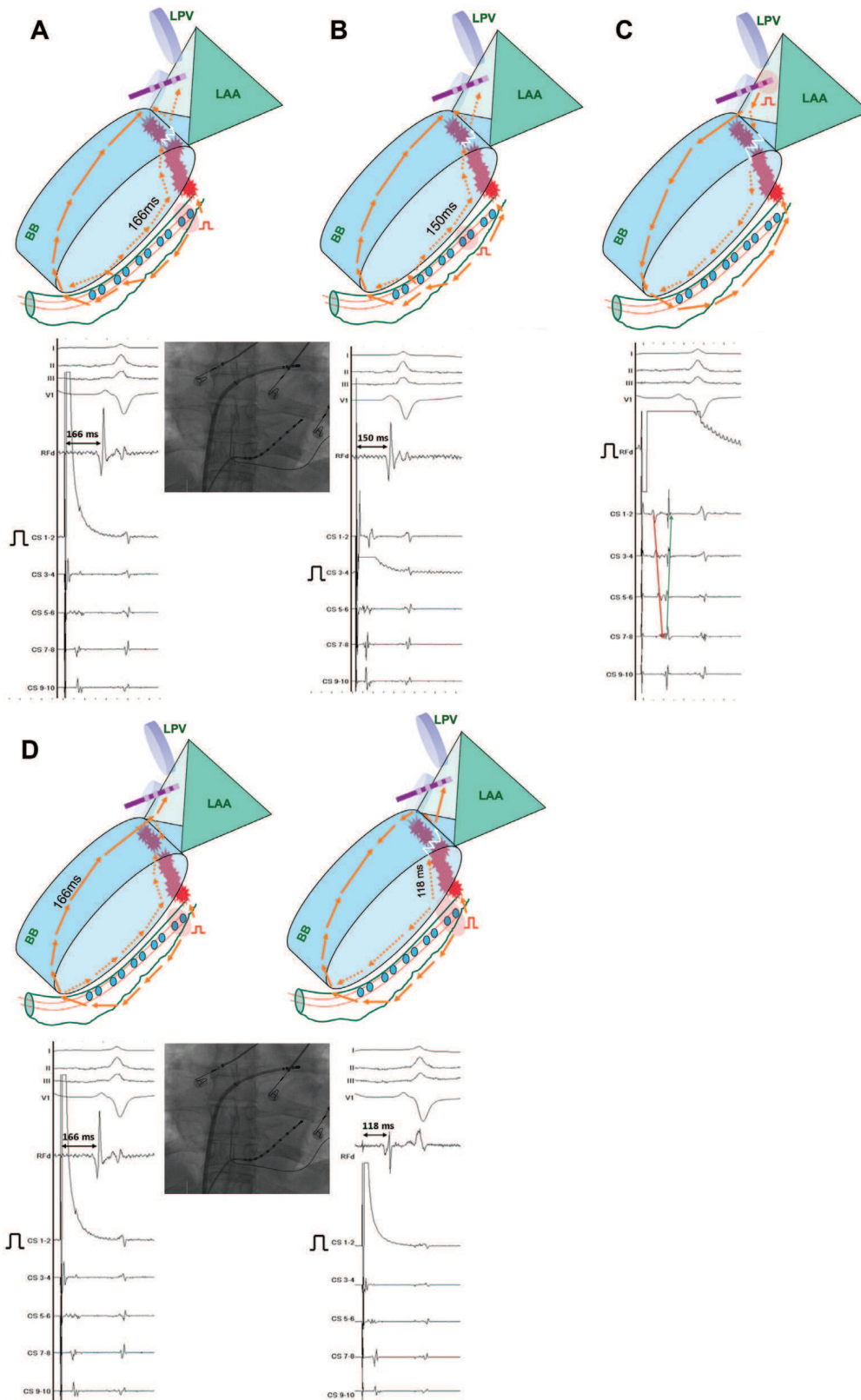
Among 271 procedures with assessment of bidirectional block, 61 pitfalls were encountered in 55 (20%) procedures undertaken in 51 patients. Of the 61 pitfalls, 27 were encountered during the procedure and 34 at the end of the procedure. In 6 patients, 2 different types of pitfall were encountered in the same procedure (types 1 and 3 in 2, types 2 and 3 in another 2, and types 2 and 5 in another 2 procedures).

## Types of Pitfall

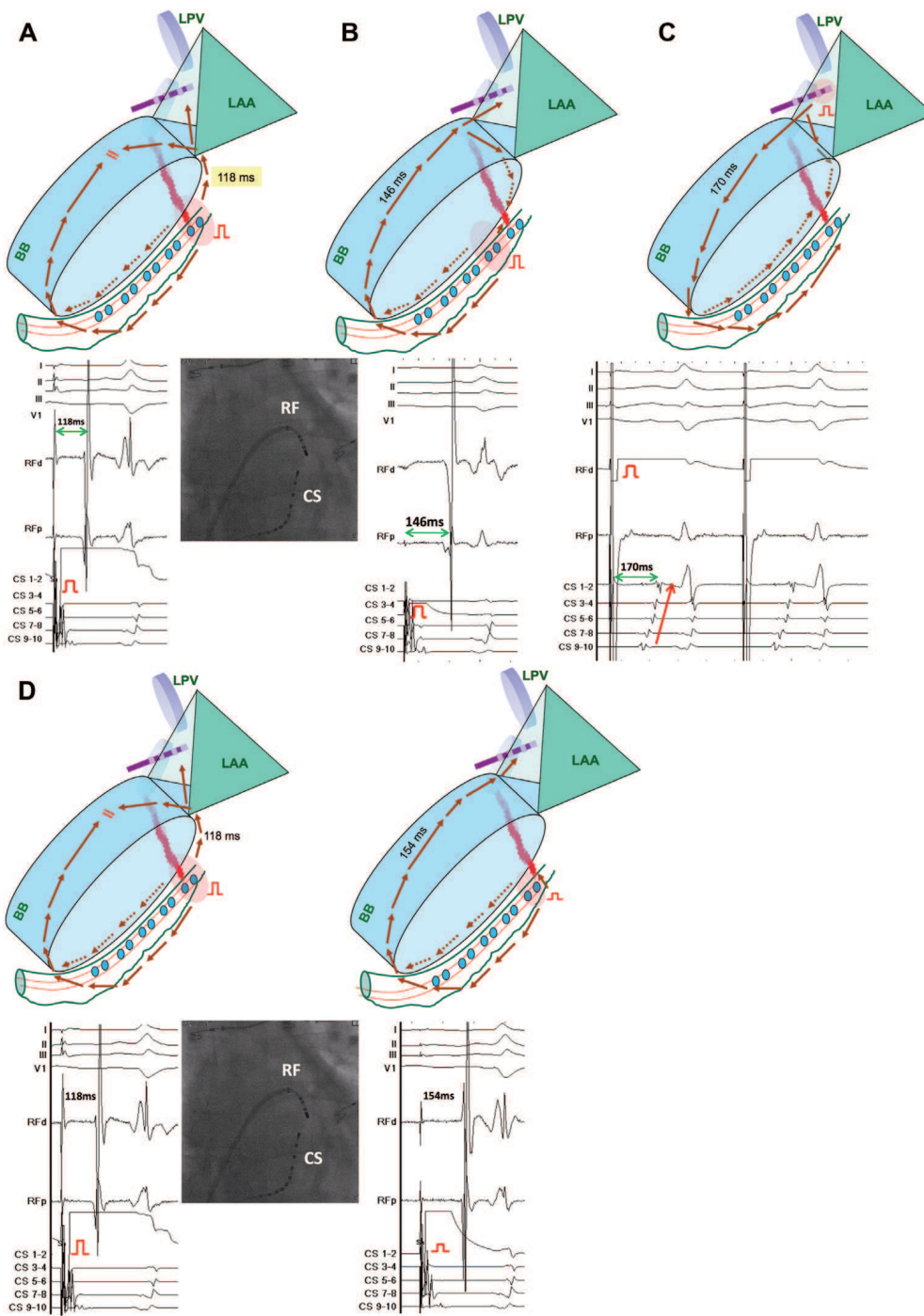
The prevalence of any type of pitfall encountered during the assessment of transmural, bidirectional block across the MI is 55 of 271 (20%) assessments. Based on the types of pitfall, there were 14, 10, 17, 2, 15, and 3 cases of pitfall types 1, 2, 3, 4, 5, and 6 respectively. The prevalence of type 3 was highest (17/271; 6%) and that of types 4 and 6 was lowest (5/271; ≈2% combined).

## Recognition of Pitfall During the Procedure

Among 61 pitfalls encountered during and at the end of the procedure, 42 (69%) were recognized by the operator (online-only Data Supplement Table SIII). Pitfall type 4 was encountered twice and recognized both the times. Pitfall type 3 was recognized in 16 of 17 procedural assessments where it was encountered. Pitfall types 2 and 6 were encountered in 13 assessments, of which 12 were recognized. Type 6 was not recognized in 1 assessment. Pitfall type 5 was encountered 15× and recognized 8×. Pitfall type 1 was encountered 14× and recognized 4×, making it the least recognized pitfall during the procedure.



**Figure 1.** Pitfall 1. Intracardiac electrograms show the assessment of mitral isthmus linear block during the differential coronary sinus (CS) and left atrial appendage (LAA) pacing techniques. They are shown along with the fluoroscopic image and the schema of the mitral annulus of the left atrium (anterior and posterior rings), coronary sinus, left atrial appendage, and left pulmonary veins. **Red stars** represent the linear lesion drawn posterolaterally. The **halo around the pacing bipole** represents the size of the virtual electrode commensurate with the pacing output. The direction of activation of the left atrium and the coronary sinus is represented by **arrows** (**broken arrows** represent posterior conduction). **A** and **B**, Differential CS pacing with local CS capture but not the LA capture is consistent with linear block because delay from CS 1–2 pacing is longer (166 ms) than that from CS 3–4 pacing (150 ms). **C**, LAA pacing reveals pseudoblock pattern with proximal-to-distal activation epicardially but distal-to-proximal activation endocardially. **D**, Comparison of delay during CS capture vs CS and LA capture reveals the underlying endocardial gap conduction. LPV indicates left pulmonary veins; BB, Bachman’s bundle; RF, radiofrequency catheter.



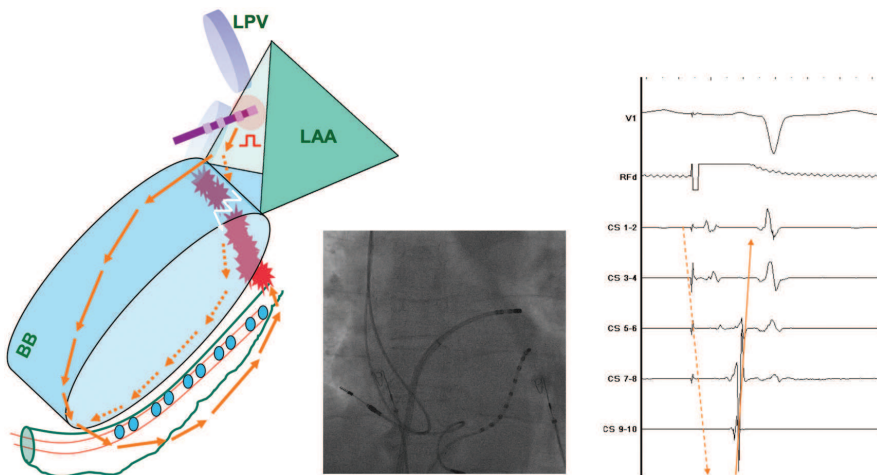
**Figure 2.** Pitfall 2. **A** and **B**, Coronary sinus (CS) pacing with capture across the line of block mimics incomplete block across the line because the delay from CS 1–2 pacing is shorter (118 ms) than that from CS 3–4 pacing (146 ms). **C**, Pacing from left atrial appendage (LAA) confirms block across the linear lesion based on the proximal-to-distal CS activation pattern. **D**, Reducing the output (or repositioning the catheter) for the same patient confirms complete linear block. LPV indicates left pulmonary veins; BB, Bachman’s bundle; RF, radiofrequency catheter.

**Discussion**

**Main Findings**

The prevalence of pitfall in the assessment of MI block using differential CS pacing technique is 1 per 5 (20%) assessments. There are 6 possible types of pitfall, which can be encountered during such an assessment, whose recognition during the procedure is important to plan further ablation. It could be recognized intraprocedurally in 70%, but in 30% of assessments wherein it was present, it was overlooked primarily because of substantial diminution of local electrograms disallowing discernibility at usual amplifier settings.

By virtue of the anatomic location of CS along the posterior mitral annulus and an easy accessibility from the right atrium, CS catheterization allows recording of LA activity without the need for transeptal puncture. Thus, not only that the epicardial CS electrograms can be used as a surrogate for endocardial LA signals but also that the CS catheter can be used to stimulate the contiguous LA myocardium during pacing maneuvers. Based on the above findings, we propose that a reliable differential CS pacing maneuver for the assessment of MI linear block must have 3 necessary features: (1) proximity of the pacing and recording catheters to the opposite sides of the linear



**Figure 3.** Pitfall 3. Radiofrequency (RF) catheter pacing (left atrial appendage [LAA]) reveals proximal-to-distal activation of the epicardial coronary sinus (CS) potentials. Far-field LA potentials show distal-to-proximal activation, suggestive of endocardial gap in the linear lesion. LPV indicates left pulmonary veins; BB, Bachman's bundle.

lesion, (2) simultaneous endocardial LA and epicardial CS capture at each pacing site during CS pacing, and (3) absence of simultaneous capture on both sides of the linear lesion. When the linear block is present, activation wave front generated from pacing bipole CS 3–4 travels anteriorly along the mitral annulus to the recording catheter over a shorter route than that taken by the wave front generated from pacing CS 1–2. LAA pacing results in proximal-to-distal activation of the CS and contiguous endocardium. It is often practically difficult to meet all the requirements of ideal differential CS pacing technique. Consequently,

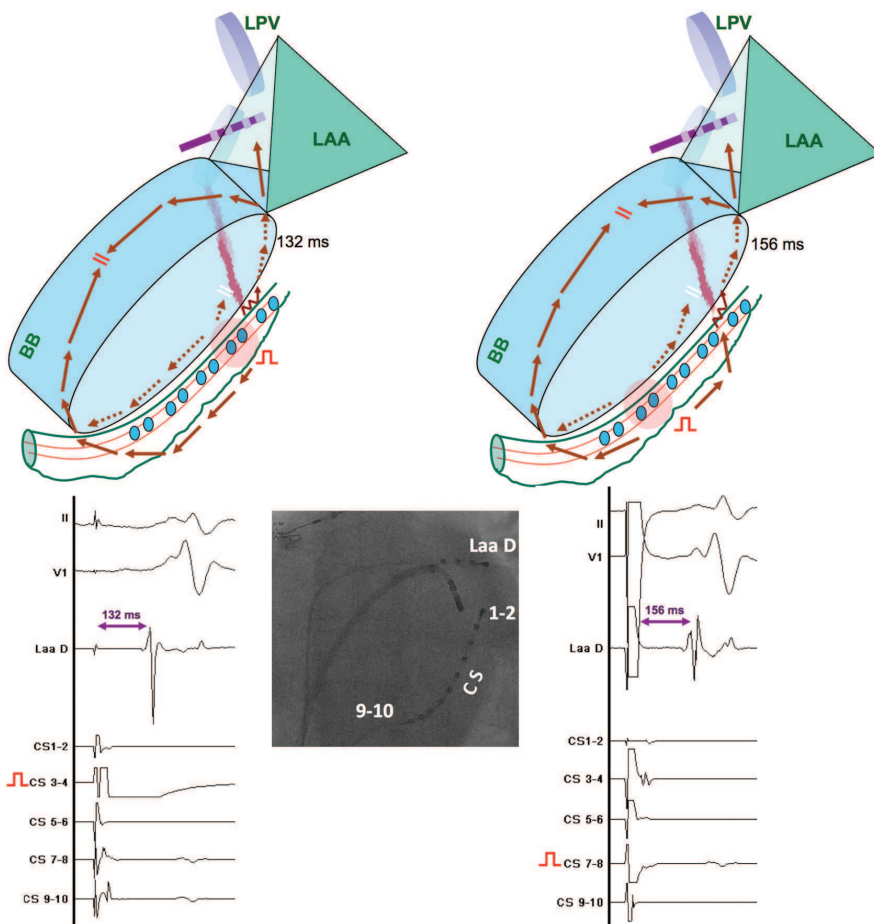
pitfall may occur during such an assessment that can, nonetheless, be recognized during the procedure with vigilant observation.

Below, we highlight the clinically relevant aspects of each of the pitfall types.

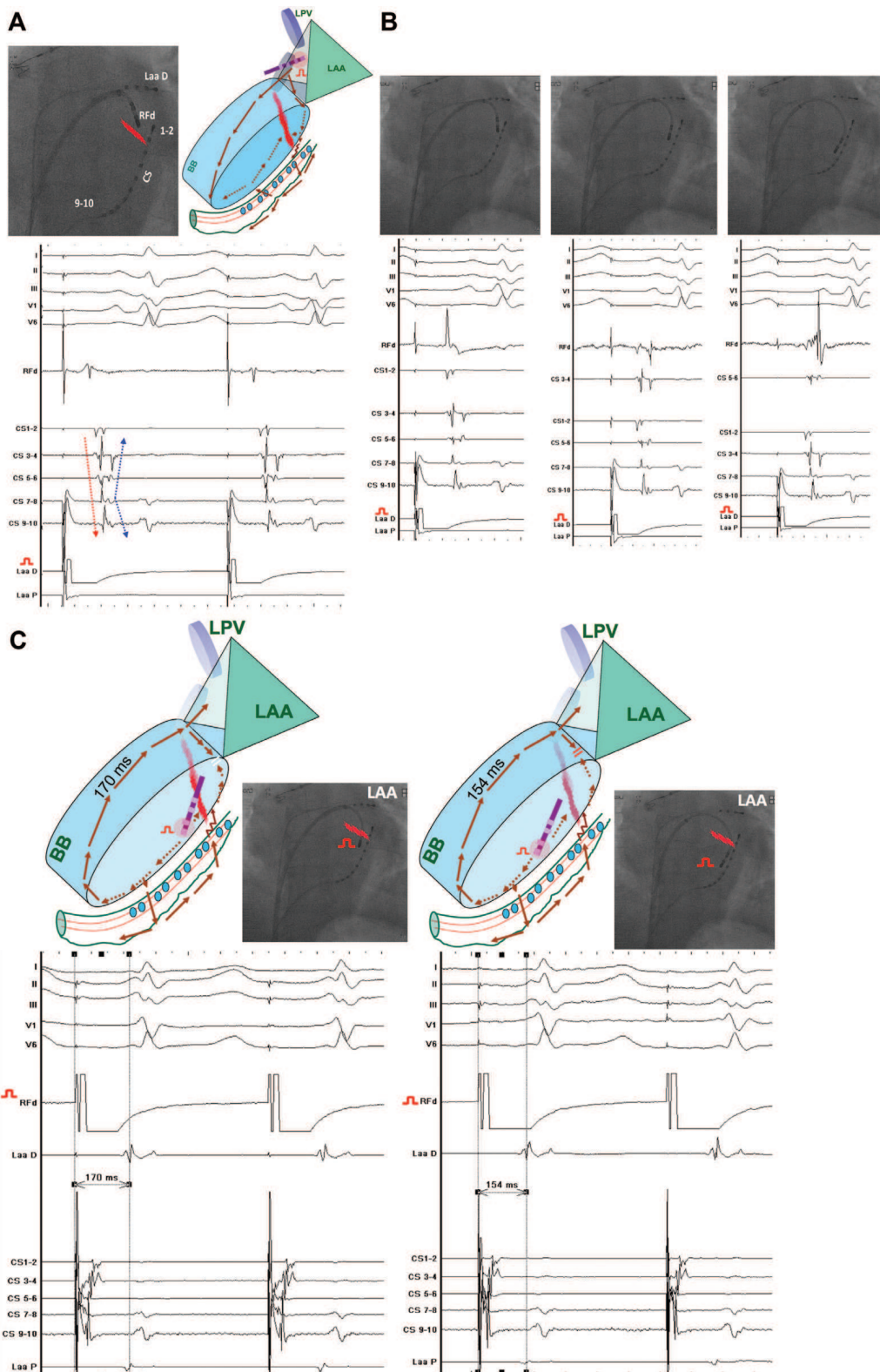
### Pitfall Type 1

#### Cause

Ablation of inferior LA from inside the CS disconnects the LA from CS in the region. Pacing at regular output results in local

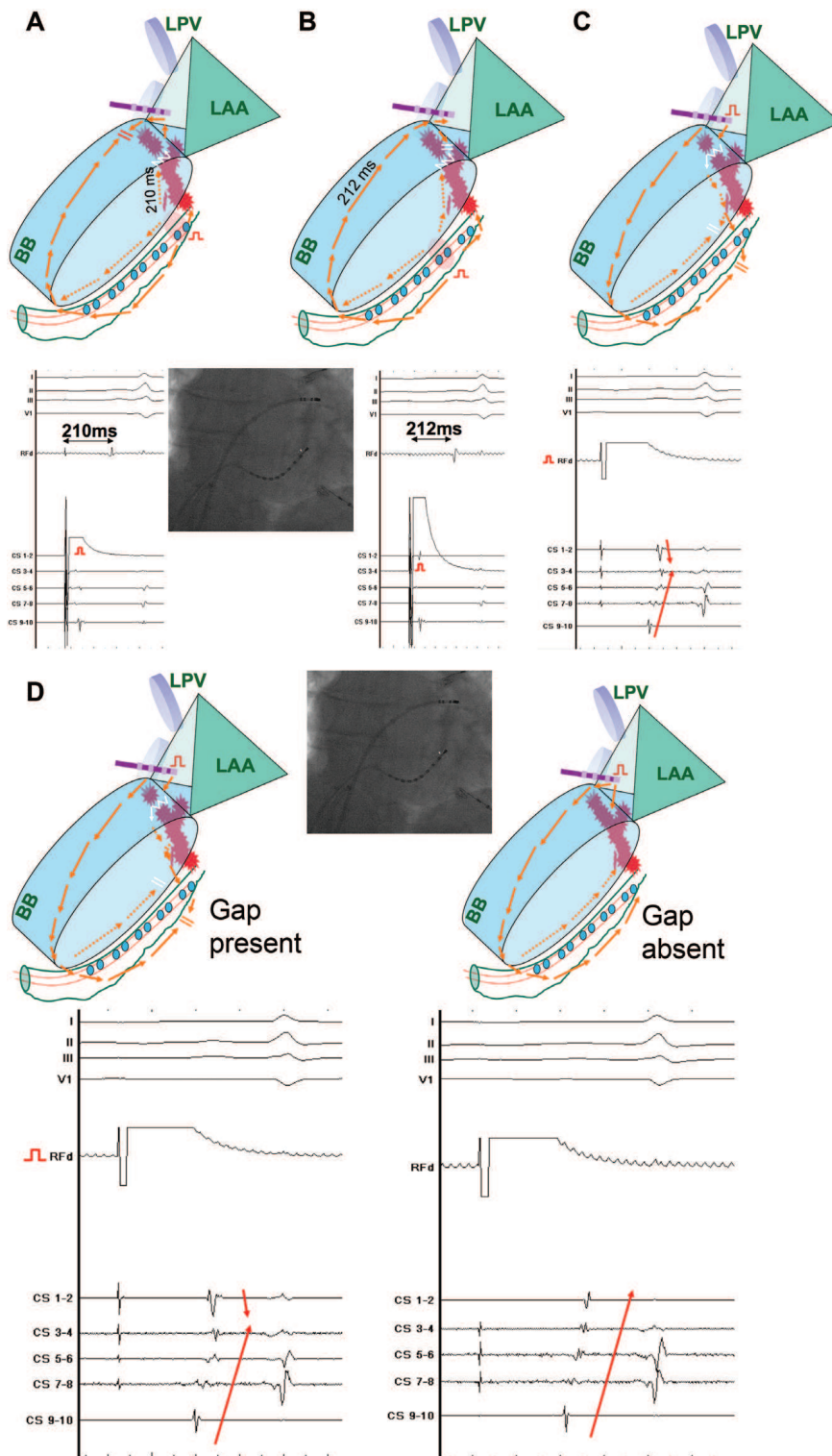


**Figure 4.** Pitfall 4. Differential coronary sinus (CS) pacing from CS 3–4 and CS 7–8 reveals delays, suggestive of absence of complete block. Do note that the linear lesion is undertaken between CS 1–2 and CS 3–4 bipoles, and the epicardial gap between the 2 is manifested by zigzag arrow. LPV indicates left pulmonary veins; BB, Bachman's bundle; LAA, left atrial appendage.



**Figure 5.** Pitfall 4. **A**, Left atrial appendage (LAA) pacing reveals distal-to-proximal coronary sinus (CS) activation epicardially (red arrow) and proximal-to-distal endocardially (blue arrow), suggestive of epicardial gap. CS 1–2 bipole lies across the line with the first component of its potential being endocardial and the second, epicardial. In contrast, the remainders of the CS bipoles record epicardial component before the endocardial (LA) component. The epicardial gap is located near CS 3–4 as evident from sequential activation of the epicardial components of CS 3–4 and CS 1–2. **B**, Endocardial LA recordings on RF from 3 sites correspond to the bipoles CS 1–2, CS 3–4, and CS 5–6 respectively. CS 1–2 bipole lies across the line with the first component of the recorded potential being endocardial and the second, epicardial. The sequence is reversed on the remaining bipoles of CS which lie across the line as evident from the recordings on the CS 3–4 and CS 5–6 bipoles, wherein the first potential is epicardial and the second one is endocardial. **C**, Differential LA (endocardial) pacing from against the same CS bipoles as in Figure 6 reveals absence of endocardial gap on the linear lesion. LPV indicates left pulmonary veins; BB, Bachman’s bundle; RF, radiofrequency catheter.





**Figure 6.** Pitfall 5. **A** and **B**, The delays from coronary sinus (CS) 1–2 and CS 3–4 pacing to the left atrial appendage (LAA) are similar, suggestive of different paths of activation of LAA. **C**, The gap in the linear lesion leads to earlier/on-time activation of CS 1–2 compared with that of CS 3–4 during LAA pacing. **D**, After elimination of gap in the linear lesion shown in **C**, CS activation is completely proximal to distal during LAA pacing, ascertaining that the previous diagnosis of incomplete block was not wrong. LPV indicates left pulmonary veins; BB, Bachman’s bundle; RF, radiofrequency catheter.

CS capture (Figure 1A and 1B), but the corresponding LA tissue cannot be activated rapidly (almost simultaneously) in the absence of local LA-CS connection.

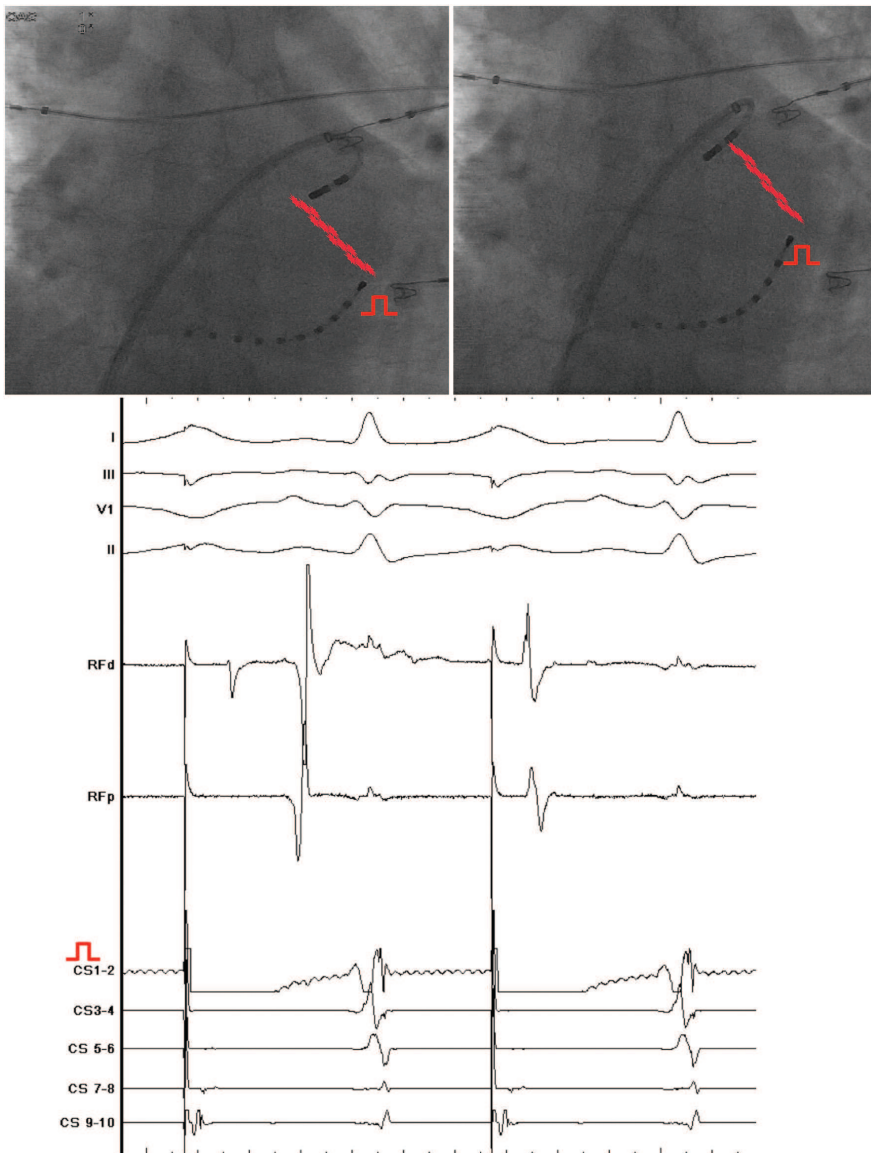
**Clinical Significance**

Pitfall can result in false diagnosis of complete block across the line of ablation. Recognition of absence of LA capture is necessary to avoid this pitfall. The clue that could make the operator suspicious is the identification of distal CS

disconnection during LAA pacing (Figure 1C). This type is not uncommon (1 in 20 assessments). It is least recognized during the procedure because of substantial diminution of LA potentials, making visualization of electrograms difficult at usual amplifier settings.

**Clinical Solution**

Pacing at output higher than the threshold value to ensure capture of endocardial LA, as well as the epicardial CS tissue,



**Figure 7.** Pitfall 6. Ablation catheter flips posteriorly from the left atrial appendage (LAA) during mitral isthmus linear ablation in continuous coronary sinus (CS) pacing. Therefore, the delay is suddenly reduced. This might be confused with recovery of conduction across the gap in the line. The change in catheter position was captured on fluoroscopy. The early component of the first beat on radiofrequency distal represents the far-field activity from across the line. RF indicates radiofrequency catheter.

reveals the gap in conduction (Figure 1D). Differential pacing directly from the endocardium (LA) is another way to confirm the presence of endocardial gap.

**Pitfall Type 2**

*Cause*

Pacing at output higher than that necessary for the local capture can cause wide-area capture such that the site across the linear lesion is stimulated simultaneously with the pacing site. If the pacing bipole is straddling the linear lesion, pacing can capture both the sites across the line.

*Clinical Significance*

False diagnosis of incomplete block may lead to unnecessary continuation of ablation. Recognition of simultaneous capture of 2 sites across the line or the unusually deep position of distal CS bipole can be helpful. This type is encountered once in every 25 assessments but usually recognized during the procedure.

*Clinical Solution*

Pacing at lower output (just above the threshold value) avoids capture of the site across the linear lesion without losing the local capture (Figure 2D). If the pacing output cannot be lowered, the position of pacing dipole may be readjusted to avoid capture across the linear lesion.

**Pitfall Type 3**

*Cause*

Pitfall type 3 is caused by nontransmural block such that the gap is present in the LA endocardium with distal LA-CS disconnection (epicardial block).

*Clinical Significance*

False diagnosis of complete block is based on CS activation pattern during pacing from the LAA. Activations of endocardial LA and epicardial CS musculature occur in mutually opposite directions during LAA pacing. This is the most common type of pitfall in clinical practice.

**Clinical Solution**

The differentiation of slushy endocardial LA potentials from the sharp local CS potentials is important to diagnose pseudo-block across MI.<sup>5</sup>

**Pitfall Type 4****Cause**

Pitfall type 4 is caused by absence of transmural lesion and presence of gap in the epicardial side (CS) of the linear lesion. MI ablation during distal CS pacing is started endocardially from the left atrium, whereas the pacing to determine linear block is undertaken epicardially from within the CS.

**Clinical Significance**

The significance is erroneous diagnosis of absence of block based on epicardial CS activation pattern during pacing from the LAA. Activations of endocardial LA and epicardial CS musculature occur in mutually opposite directions. This is the least common type because ablation from inside the CS usually eliminates the epicardial component of the MI rapidly.

**Clinical Solution**

Differential pacing endocardially from the inferior LA side of the corresponding CS bipoles at output just above the threshold helps avoid epicardial capture and demonstrates endocardial block (Figure 5C). Eventually, RF ablation should be targeted at the epicardial gap from within the CS.

**Pitfall Type 5****Cause**

Pitfall type 5 is caused by slow conduction across the gap in the linear lesion. If the CS catheter cannot be positioned such that its distal bipole lies close the linear lesion, pitfall type 5 can be missed during LAA pacing.

**Clinical Significance**

This is the most misleading of all types because such a pattern of CS activation on LAA pacing closely resembles the blocked pattern of proximal-to-distal CS even when the block is absent. It is seen once every 20 assessments. Almost 50% of this type of pitfall wherein differential CS pacing is suggestive of block (unidirectional block) is not recognized as pitfall during the procedure.

**Clinical Solution**

Pacing and recording close to the linear lesion are necessary to recognize this pitfall because recognition of pitfall during the procedure could prompt the need for further ablation. Continued ablation closes the gap which is marked by complete proximal-to-distal pattern of CS activation during LAA pacing, with CS 1–2 getting activated clearly after CS 3–4 (Figure 6D).

**Pitfall Type 6****Cause**

Pitfall type 6 is due to the position of RF catheter on the same side of the line as the CS pacing bipole. This error is likely to occur when the RF catheter is lying on the top of the line. Extensive ablation may diminish the amplitude of 1 of the 2 components of double potential usually observed on the line.

Single potential at the recording site often gives this pitfall a miss (Figure 7).

**Clinical Significance**

In the presence of block, such a positional error can be interpreted as a gap, leading to unnecessary further ablation. Although rarely encountered in experienced hands, it is usually easy to recognize. It should be differentiated from true gap, which is also more common on the top of line.<sup>6</sup>

**Clinical Solution**

Recognition of change in the configuration of electrogram recorded on the proximal bipole of RF catheter at the moment when the catheter drops posterior to the linear lesion is important (Figure 7). Careful repositioning of the catheter will ascertain the block without any further ablation. The most likely differential, namely the recovery of conduction (gap) should be ruled out.

**Conclusions**

Every fifth assessment of bidirectional complete block across the MI linear ablation using the differential CS pacing technique from the epicardium and the LAA pacing technique encounters a pitfall. Pitfall in the assessment can lead to erroneous clinical diagnosis of block or absence of block across the MI linear lesion. Recognition of pitfall during the procedure necessitates careful identification of LA electrograms distinctly from the local CS electrograms besides appropriate adjustments in catheter position and pacing outputs.

Although pitfalls in conventional technique for the assessment of MI block are highly prevalent, they can be recognized and fixed during the procedure. It emphasizes the influence of LA-CS muscle connections not only in the arrhythmogenesis of atrial fibrillation<sup>7</sup> and atrial thrombosis but also in the electrophysiological maneuvers undertaken to evaluate the procedural success.

**Acknowledgments**

We thank Valerie Aurillac-Lavignolle and Dr Hui Wang for investing their valuable time to provide expert statistical assistance.

**Disclosures**

None.

**References**

1. Calkins H, Brugada J, Packer DL, Cappato R, Chen SA, Crijns HJ, Damiano RJ Jr, Davies DW, Haines DE, Haissaguerre M, Iesaka Y, Jackman W, Jais P, Kottkamp H, Kuck KH, Lindsay BD, Marchlinski FE, McCarthy PM, Mont JL, Morady F, Nademanee K, Natale A, Pappone C, Prystowsky E, Raviele A, Ruskin JN, Shemin RJ; Heart Rhythm Society; European Heart Rhythm Association; European Cardiac Arrhythmia Society; American College of Cardiology; American Heart Association; Society of Thoracic Surgeons. HRS/EHRA/ECAS expert consensus statement on catheter and surgical ablation of atrial fibrillation: recommendations for personnel, policy, procedures and follow-up. A report of the Heart Rhythm Society (HRS) Task Force on Catheter and Surgical Ablation of Atrial Fibrillation developed in partnership with the European Heart Rhythm Association (EHRA) and the European Cardiac Arrhythmia Society (ECAS); in collaboration with the American College of Cardiology (ACC), American Heart Association (AHA), and the Society of Thoracic Surgeons (STS). Endorsed and approved by the governing bodies of the American College of Cardiology, the American Heart Association, the European Cardiac Arrhythmia Society, the European Heart Rhythm

- Association, the Society of Thoracic Surgeons, and the Heart Rhythm Society. *Europace*. 2007;9:335–379.
2. Shah D, Haïssaguerre M, Takahashi A, Jaïs P, Hocini M, Clémenty J. Differential pacing for distinguishing block from persistent conduction through an ablation line. *Circulation*. 2000;102:1517–1522.
  3. Antz M, Otomo K, Arruda M, Scherlag BJ, Pitha J, Tondo C, Lazzara R, Jackman WM. Electrical conduction between the right atrium and the left atrium via the musculature of the coronary sinus. *Circulation*. 1998;98:1790–1795.
  4. Jaïs P, Hocini M, Hsu LF, Sanders P, Scavee C, Weerasooriya R, Macle L, Raybaud F, Garrigue S, Shah DC, Le Metayer P, Clémenty J, Haïssaguerre M. Technique and results of linear ablation at the mitral isthmus. *Circulation*. 2004;110:2996–3002.
  5. Takatsuki S, Extramiana F, Hayashi M, Leenhardt A. Conduction through the lateral mitral isthmus: block or pseudoblock. *J Cardiovasc Electrophysiol*. 2008;19:98–99.
  6. Rostock T, O'Neill MD, Sanders P, Rotter M, Jaïs P, Hocini M, Takahashi Y, Sacher F, Jönsson A, Hsu LF, Clémenty J, Haïssaguerre M. Characterization of conduction recovery across left atrial linear lesions in patients with paroxysmal and persistent atrial fibrillation. *J Cardiovasc Electrophysiol*. 2006;17:1106–1111.
  7. Chauvin M, Shah DC, Haïssaguerre M, Marcellin L, Brechenmacher C. The anatomic basis of connections between the coronary sinus musculature and the left atrium in humans. *Circulation*. 2000;101:647–652.

### CLINICAL PERSPECTIVE

The current guidelines on the ablation of atrial fibrillation recommend transmural and bidirectional (complete) block across the linear lesion as the end point of left mitral isthmus ablation. We retrospectively evaluated the assessments (based on differential pacing from the coronary sinus followed by left appendage pacing) of linear block across the mitral isthmus linear lesions in 271 mitral isthmus ablation procedures undertaken among 236 patients to understand and characterize the challenges encountered during this clinical process. Bidirectional block was established in 186 of 271 (69%) procedures. Pitfall was encountered in 55 of 271 (20%) procedures among 51 patients and categorized into 6 types (types 1, 3, 4, and 5 led to spurious diagnosis of block; types 2 and 6 led to erroneous diagnosis of absence of block). There were 14, 10, 17, 2, 15, and 3 (total=61) cases of pitfall types 1 through 6, respectively. Six patients had 2 pitfalls in the same assessment (2 patients with each of types 1 and 3, 2 and 3, and 2 and 5). Operator recognized 42 of 61 (69%) pitfalls intraprocedurally. The most difficult-to-recognize types were types 1 and 5, and the difficulty was because of indiscernible local electrograms at usual amplifier settings or presence of slow conduction mimicking block. The clinical significance of intraprocedural recognition of pitfall(s) in the mitral isthmus linear block assessment is obvious and necessitates careful distinction of far-field left atrium from the local coronary sinus electrograms besides appropriate adjustments in catheter position and pacing outputs.

SUPPLEMENTAL MATERIAL

Supplementary Table 1: Baseline Characteristics

Parameter	Pitfall Present	Pitfall Absent	P-value
Age (y)	57 ± 9	59 ± 10	0.19
Male (%)	48 (92)	162 (87)	0.22
Paroxysmal AF (%)	14 (27)	52 (28)	1.0
Hypertension (%)	11 (22)	62 (33)	0.12
Diabetes Mellitus (%)	1 (2)	6 (3)	1.0
Previous Stroke (%)	4 (8)	10 (5)	0.5
Idiopathic Cardiomyopathy (%)	5 (10)	10 (5)	0.3
Valvular heart Disease (%)	6 (12)	19 (10)	0.79
Left Ventricular EDD (mm)	55 ± 6	54 ± 7	0.35
Left Ventricular ESD (mm)	37 ± 7	37 ± 8	1
Left Ventricular EF (%)	55 ± 14	58 ± 13	0.15
Left Atrial size (mm)	49 ± 7	47 ± 8	0.1

AF – Atrial Fibrillation, EDD – End-diastolic dimension, ESD – End-systolic dimension,  
 EF – Ejection Fraction

Supplementary Table 2: Procedural Parameters

Parameter	Pitfall Present	Pitfall Absent	P-value
Patients with second or subsequent procedure(s) (%)	33 (60)	130 (60)	1
Duration of RF Delivery (min)			
Pulmonary vein Isolation	27 (9, 39)	23 (8, 41)	0.7
Left atrial defragmentation	12 (2, 24)	10 (1, 21)	0.54
Coronary sinus	4 (0, 7.5)	3 (0, 6)	0.41
Roof lesion	5 (0, 10)	5 (0, 10)	0.85
Mitral Isthmus lesion	16 (6, 25)	14 (6, 22)	0.56
TOTAL	81.5 (39, 109)	70.5 (43, 97)	0.49
Duration of Procedure (min)	240 (190, 290)	240 (180, 305)	0.84
Fluoroscopic Exposure (DAP, mGycm <sup>2</sup> )	41964 (26394, 59126)	44223 (26628, 76144)	0.44

RF - RadioFrequency energy, DAP - Dose Area Product

Supplementary Table 3: Pitfalls and their recognition during the procedure

<b>Pitfall type</b>	<b>Recognized during the procedure</b>	<b>Not recognized during the procedure</b>	<b>Total</b>
1	4 (29%)	10	14
2	10 (100%)	0	10
3	16 (94%)	1	17
4	2 (100%)	0	2
5	8 (53%)	7	15
6	2 (67%)	1	3
Sum	42 (69%)	19	61



## Supplementary Figure Legend

Pacing and Recording not close to the linear lesion can lead to difficulty in differentiating slowly conducting linear lesion from a completely blocked linear lesion. A: LAA pacing reveals proximal to distal activation of the CS suggestive of blocked MI line (red star).

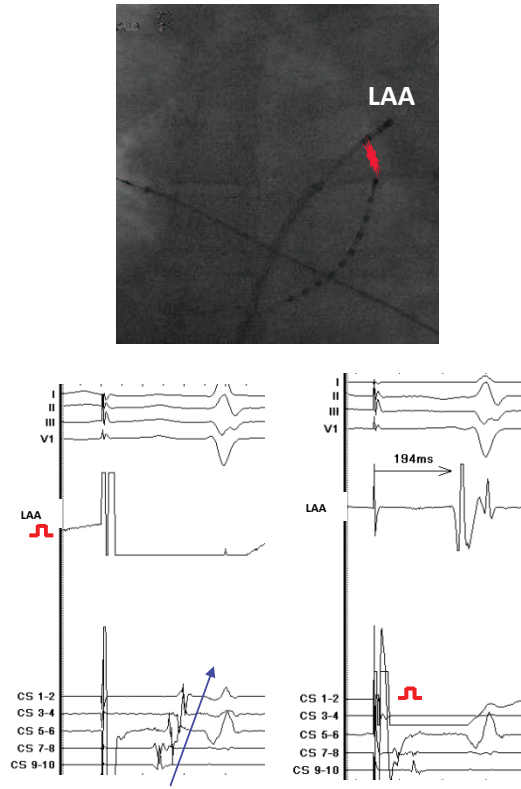
B: Pacing from the distal CS and recording from a site closer to the line than LAA reveals slow conduction and absence of block.

On distal CS pacing, the activation of the site closer to the linear lesion (212ms) occurs by the wavefront traversing the ablation line while the LAA is activated (194ms) by a wavefront travelling from the septum over the roof of the left atrium.

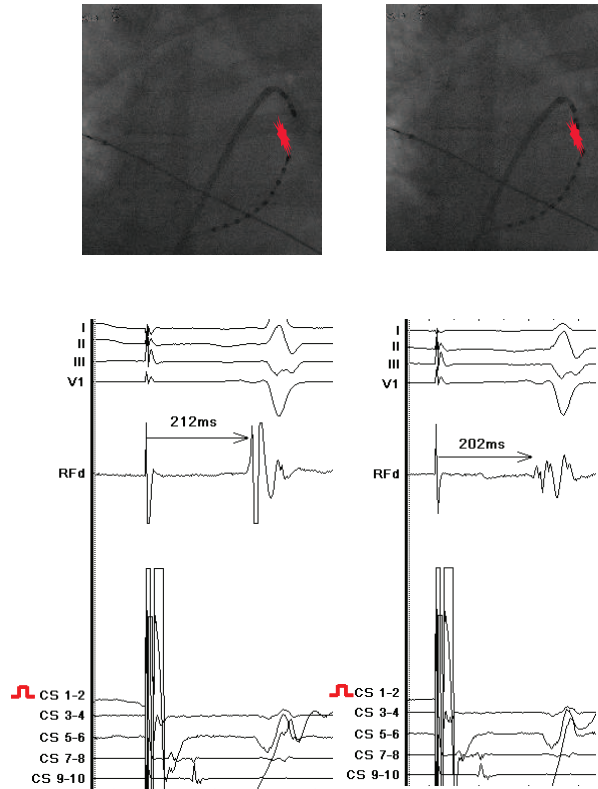
(Abbreviations: LAA – Left atrial Appendage, CS – Coronary sinus)

# Supplementary Figure

A



B



Acknowledgment permissions (obtained by email)

MS ID#: CIRCAE/2012/971259

MS TITLE: Prevalence and Types of Pitfall in the Assessment of Mitral Isthmus Linear Conduction Block

Mon, Jul 9, 2012 at 2:16 PM

**AURILLAC Valerie** <valerie.aurillac@chu-bordeaux.fr>

To: ashok shah <drashahep@gmail.com>

Dear Ashok,

I thank you very much.

I give you my permission to put my name in the acknowledgement section: Valérie Aurillac-Lavigne

Best regards,

Valérie

MS ID#: CIRCAE/2012/971259

MS TITLE: Prevalence and Types of Pitfall in the Assessment of Mitral Isthmus Linear Conduction Block

Mon, Jul 9, 2012 at 8:46 PM

**H Wang** <bio.email@gmail.com>  
To: ashok shah <drashahep@gmail.com>

Dr. Shah,

Thank you for acknowledging me. You have my permission. Here is my information:

Hui Wang, Ph.D. in Pharmacology and MS in Biostatistics  
Analyst in Biogenidec

Thanks again,

Hui