



UNIL | Université de Lausanne

Unicentre

CH-1015 Lausanne

<http://serval.unil.ch>

Year : 2022

The role of exercise testing in congenital heart disease patients after coronary artery reimplantation

Chalverat Maëlle

Chalverat Maëlle, 2022, The role of exercise testing in congenital heart disease patients
after coronary artery reimplantation

Originally published at : Thesis, University of Lausanne

Posted at the University of Lausanne Open Archive <http://serval.unil.ch>

Document URN : urn:nbn:ch:serval-BIB_723CB864A0FD6

Droits d'auteur

L'Université de Lausanne attire expressément l'attention des utilisateurs sur le fait que tous les documents publiés dans l'Archive SERVAL sont protégés par le droit d'auteur, conformément à la loi fédérale sur le droit d'auteur et les droits voisins (LDA). A ce titre, il est indispensable d'obtenir le consentement préalable de l'auteur et/ou de l'éditeur avant toute utilisation d'une oeuvre ou d'une partie d'une oeuvre ne relevant pas d'une utilisation à des fins personnelles au sens de la LDA (art. 19, al. 1 lettre a). A défaut, tout contrevenant s'expose aux sanctions prévues par cette loi. Nous déclinons toute responsabilité en la matière.

Copyright

The University of Lausanne expressly draws the attention of users to the fact that all documents published in the SERVAL Archive are protected by copyright in accordance with federal law on copyright and similar rights (LDA). Accordingly it is indispensable to obtain prior consent from the author and/or publisher before any use of a work or part of a work for purposes other than personal use within the meaning of LDA (art. 19, para. 1 letter a). Failure to do so will expose offenders to the sanctions laid down by this law. We accept no liability in this respect.



UNIL | Université de Lausanne

Faculté de biologie
et de médecine

UNIVERSITE DE LAUSANNE - FACULTE DE BIOLOGIE ET DE MEDECINE

Département cœur-vaisseaux

Service de cardiologie

**The role of exercise testing in congenital heart disease patients after
coronary artery reimplantation**

THESE

préparée sous la direction du Dr. Tobias Rutz

et présentée à la Faculté de biologie et de médecine de
l'Université de Lausanne pour l'obtention du grade de

DOCTEUR EN MEDECINE

par

Maëlle CHALVERAT

Médecin diplômée de la Confédération Suisse
Originaire de Châtillon (Jura/Suisse)

Lausanne
2022

Imprimatur

Vu le rapport présenté par le jury d'examen, composé de

Directeur.trice de thèse

Dr Tobias Rutz

Co-Directeur.trice de thèse

Expert.e

Prof. Roger Hullin

**Vice-Directeur de l'Ecole
doctorale**

Prof. John Prior

la Commission MD de l'Ecole doctorale autorise l'impression de la thèse de

Madame Maëlle Chalverat

intitulée

***The role of exercise testing in congenital heart
disease patients after coronary artery reimplantation***


Lausanne, le 3 février 2022

*pour Le Doyen
de la Faculté de Biologie et de Médecine*


**Monsieur le Professeur John Prior
Vice-Directeur de l'Ecole doctorale**

Contents lists available at [ScienceDirect](https://www.sciencedirect.com)

International Journal of Cardiology Congenital Heart Disease

journal homepage: www.journals.elsevier.com/international-journal-of-cardiology-congenital-heart-disease

The role of exercise testing in congenital heart disease patients after coronary artery reimplantation

Maëlle Chalverat^a, Judith Bouchardy^a, Coralie Blanche^b, Etienne Pruvot^a, Nicole Sekarski^c, Patrick Yerly^a, Tobias Rutz^{a,*}^a Service of Cardiology, Lausanne University Hospital and University of Lausanne, Lausanne, Switzerland^b Service of Cardiology, University Hospitals of Geneva, Geneva, Switzerland^c Paediatric Cardiology Unit, Lausanne University Hospital and University of Lausanne, Lausanne, Switzerland

ARTICLE INFO

Keywords:

Ross procedure
Arterial switch operation
Coronary artery reimplantation

ABSTRACT

Introduction: The Ross procedure requires like the arterial switch operation (ASO) coronary artery reimplantation. There is no information on coronary artery stenosis at the site of the reimplantation in Ross patients as has been described for ASO patients. This study assessed therefore the prevalence of positive exercise tests (pETs) suggesting myocardial ischemia in Ross and ASO patients in comparison to tetralogy of Fallot patients (TOF), the latter not undergoing coronary artery reimplantation. The study evaluated further, whether a coronary artery complication was confirmed by a supplementary non- and/or invasive evaluation.

Methods: Results of exercise tests, echocardiography, coronary computed tomography (CCT) and coronary angiography (CA) were retrospectively reviewed in 30 Ross, 14 ASO and 30 TOF patients.

Results: Exercise capacity did not differ between groups. There was a trend to more frequent pETs in Ross patients (Ross vs. ASO vs. TOF, N, %): 8 (27) vs. 1 (7) vs. 2 (7) $p = 0.062$. CCT was performed in 30% Ross, 21% ASO, 3% TOF ($p = 0.023$); CA in 20% Ross, 21% ASO and 13% TOF patients ($p = 0.727$). None of these investigations revealed a coronary artery stenosis. Patients with pET showed a higher right ventricular outflow tract (RVOT) gradient (44 ± 30 vs. 22 ± 13 mmHg, $p = 0.004$) and more frequently a severe RVOT stenosis (27 vs. 0%, $p < 0.006$).

Conclusions: pETs are rather related to RVOT stenosis than to coronary artery complications after Ross procedure, ASO and TOF repair. The role of exercise testing for detection of myocardial ischemia is limited and should be restricted to evaluation of exercise capacity.

Introduction

Several congenital heart disease (CHD) defects require coronary artery reimplantation at the time of surgical correction e.g. arterial switch operation (ASO) for transposition of great arteries (TGA) and Ross procedure for aortic valve diseases being the most frequent. The Ross operation, introduced in 1967, consists of excision of the pulmonary valve and its implantation in the aortic position [1,2]. A homograft or a valved conduit replaces the excised pulmonary valve. This procedure requires excision and consequently reimplantation of the coronary arteries in the neo-aortic root. The operation offers the advantages of avoidance of anticoagulation, potential for growth and excellent hemodynamics [2,3]. Although the survival is excellent with 98% after 15 years, long-term complications include degeneration of the pulmonary

homograft and neo-aortic root dilatation with consecutive regurgitation requiring reintervention [3-9]. Little, however, is known with regard to coronary artery stenosis after reimplantation in Ross procedure [10]. This type of complication has been described in ASO patients, in which late coronary artery stenosis due to distortion at the reimplantation site was found in up to 6–10% of patients [11,12].

Guidelines recommend regular exercise testing during follow-up for CHD patients [13,14]. The aim of this study was therefore to define the prevalence of positive exercise tests after Ross procedure and ASO in comparison to a control group of patients with tetralogy of Fallot (TOF) patients, who do not undergo coronary artery reimplantation during repair.

* Corresponding author. Service of Cardiology, Lausanne University Hospital and University of Lausanne, Rue du Bugnon 46, 1011 Lausanne, Switzerland.

E-mail address: tobias.rutz@chuv.ch (T. Rutz).<https://doi.org/10.1016/j.ijchd.2021.100137>

Received 4 January 2021; Received in revised form 9 April 2021; Accepted 10 April 2021

2666-6685/© 2021 The Authors. Published by Elsevier B.V. This is an open access article under the CC BY-NC-ND license (<http://creativecommons.org/licenses/by-nc-nd/4.0/>).

Methods

This is an observational and retrospective study including patients of the University Hospitals of Lausanne and Geneva, Switzerland. The local ethics committees approved the study and the need for informed consent was waived. The study protocol conforms to the ethical guidelines of the 1975 Declaration of Helsinki.

Study population

Adult patients (>18 years) after Ross procedure, ASO and TOF repair were included. Patients had performed at least one exercise test. Time between surgical repair and last follow-up had to be more than one month. The only exclusion criterion was the presence of surgery on coronary arteries in TOF patients. Patient characteristics data were collected from the last report on outpatient visit/hospitalization. For each patient, the last available echocardiography, all cardiac computed tomography (CCT), magnetic resonance (CMR), exercise tests and coronary angiography reports were obtained.

For a comparative analysis, the control group (TOF) was subsequently selected to obtain three comparable groups by age (± 2 years) and sex.

Exercise testing

Treadmill exercise tests with a modified Bruce protocol or cardiopulmonary exercise tests were performed [15]. Data on maximal charge (METS/Watt), blood pressure increase and heart rate was collected. The percentage of the maximal predicted charge and heart rate was calculated.

Exercise tests were considered positive in case of typical chest pain or significant ECG changes i.e. horizontal or downsloping ST segment depression of ≥ 1 mm at 80 ms after the J point on the electrocardiogram during or after exertion and/or development of a new negative T-wave [16]. In case of pre-existing right bundle branch block (RBBB), chest ECG leads without pre-existing changes were used for evaluation of new, exercise-induced ECG changes [17].

Statistical analysis

Normality was tested by the Shapiro-Wilk test. Between-group comparisons of continuous variables were performed by student's t-test, the factorial analysis of variance (ANOVA) with Bonferroni post-hoc analysis or Kruskal-Wallis test, where appropriate. Categorical variables were compared by Chi square test. Results are indicated in frequencies and percentage, means \pm standard deviation or median and ranges, where appropriate. Statistical significance was set to a *p*-value of <0.05. Analyses were performed using SPSS statistic software (version 24, IBM™ Chicago, USA).

Results

Patient characteristics

A total of 74 adult patients were included in the analysis, 30 in each Ross and TOF group and 14 in the ASO group. The matching by age extended to up to ± 5 years in 2 TOF patients and 1 TOF patient did not meet the criteria for the gender.

The indication for the Ross procedure was aortic stenosis in 15 patients (50%), aortic insufficiency in 7 patients (23.3%) and both, aortic insufficiency and stenosis in 8 patients (26.7%).

Demographic and clinical patient characteristics are summarized in Table 1. Age at last follow-up, gender, weight, height, BMI, body surface and medical treatment did not differ between groups. Age at the initial surgery and last follow-up since surgical repair were significantly higher in the Ross compared to ASO and TOF groups. All reinterventions were performed for stenosis of the right ventricular outflow tract in Ross

Table 1

Patient characteristics.

	Ross (n = 30)	ASO (n = 14)	TOF (n = 30)	<i>p</i> -value
Women, N (%)	14 (46.7)	3 (31.4)	12 (40)	0.277
Weight (kg)	72 \pm 14	63 \pm 15	69 \pm 12	0.169
Height (cm)	171 \pm 10	174 \pm 7	174 \pm 10	0.402
BMI (kg/m ²)	23.3 (18.6–36.9)	19.4 (16.6–32.9)	23.4 (17.5–28.3)	0.052
Body surface area (m ²)	1.8 (1.4–2.3)	1.7 (1.5–2.2)	1.9 (1.4–2.4)	0.287
Age at latest follow-up (years)	22 (17–47)	20 (14–32)	23 (17–48)	0.463
Age at the time of surgery (years)	14 (2–31)	0 (0–1)	1 (0–9)	< 0.001 ^a
Time since surgical repair (years)	8 (0–20)	18 (6–30)	20 (8–41)	< 0.001 ^b
Cardiovascular treatment, N (%)	7 (23.3)	2 (14.3)	7 (23.3)	0.760
Type of treatment, N (%)				0.276
a) Beta-blockers	2 (6.7)	0 (0)	3 (10)	
b) ACEI/ARB	3 (10)	0 (0)	0 (0)	
c) Diuretics	0 (0)	0 (0)	0 (0)	
d) a) + b) + c)	1 (3.3)	2 (14.3)	1 (3.3)	
e) Aspirin	0 (0)	0 (0)	1 (3.3)	
Anticoagulation, N (%)	0 (0)	1 (7.1)	1 (3.3)	0.381
Reintervention rate, N (%)	7 (23.3)	6 (42.9)	17 (56.7)	0.031

Data are means \pm standard deviation or median and ranges where appropriate. **Abbreviations:** ACEI = Angiotensin-converting enzyme inhibitors, ASO = atrial switch operation, ARB = Angiotensin II receptor blockers, TOF = tetralogy of Fallot.

^a *p* < 0.001 for Ross vs. TGA and Ross vs. TOF.

^b *p* < 0.001 for Ross vs. TOF and *p* = 0.029 for Ross vs. TGA.

patients. Reinterventions were more frequently performed in ASO patients.

Paraclinical exams at the last follow-up

Exercise testing

Results of last exercise tests are summarized in Table 2. Fifty-one patients performed cardiopulmonary exercise tests (CPET) and 23 treadmill exercise tests. Percentages of maximal predicted charge and heart rate did not differ between groups.

One exercise test was clinically and ten electrically positive as defined

Table 2

Exercise testing.

	Ross (n = 30)	ASO (n = 14)	TOF (n = 30)	<i>p</i> -value
Exercise test, N (%)	30 (100)	14 (100)	30 (100)	
Percentage of predicted METs/Watt	93 \pm 22	105 \pm 21	94 \pm 29	0.653
Percentage of predicted maximal heart rate	91 (68–103)	92 (80–100)	88 (59–98)	0.088
Resting ECG changes, N (%)	6 (20)	3 (21.4)	16 (53.3)	0.013
Retrosternal pain during physical activity, N (%)	0 (0)	1 (7.1)	0 (0)	0.114
Positive test, N (%)	8 (26.7)	1 (7.1)	2 (6.7)	0.062
Consecutive investigation in case of positive exercise test, N (%)	6 (75)	1 (100)	1 (100)	0.632
Type of investigation				0.424
• CMR, N (%)	1 (16.7)	0 (0)	1 (100)	
• Cardiac CT, N (%)	4 (66.7)	1 (100)	0 (0)	
• Coronary angiography, N (%)	1 (16.7)	0 (0)	0 (0)	

Data are means \pm standard deviation or median and ranges where appropriate. **Abbreviations:** ASO = atrial switch operation, CMR = cardiac magnetic resonance, Cardiac CT = cardiac computer tomography, ECG = electrocardiogram, MET = metabolic equivalent, TOF = tetralogy of Fallot.

before. Ross patients showed a trend to higher number of positive exercise test as compared to ASO and TOF patient. Among patients with positive exercise tests, 6 Ross, one ASO and one TOF patient underwent subsequent investigation to detect coronary stenosis. Four Ross patients (66.7%) had a cardiac CT, 1 (16.7%) a CMR and 1 (16.7%) a coronary angiography.

Echocardiography and cardiac magnetic resonance

Table 3 describes data from the last echocardiography and CMR for all patients. Ross patients had a higher mean aortic valve gradient and a

Table 3

Echocardiography and cardiac magnetic resonance.

	Ross (n = 30)	ASO (n = 14)	TOF (n = 30)	p-value
Echocardiography, N (%)	30 (100)	13 (92.9)	30 (100)	0.114
Dilatation of the aortic root, N (%)	23 (76.7)	5 (35.7)	15 (50)	0.022
Aortic insufficiency, N (%)	26 (86.7)	8 (57.1)	6 (20)	<0.001
Maximum aortic valve gradient (mmHg)	6.9 (3.6–29.7)	4.6 (2.8–24.9)	4.4 (1.8–8.9)	0.008 ^a
Maximum pulmonary valve gradient (mmHg)	25 (9.5–108.7)	25.9 (2.7–35.5)	17.1 (5.5–54.3)	0.167
Right ventricular systolic pressure due to tricuspid insufficiency (mmHg)	31.7 (18–86.8)	25.8 (12–68.4)	29.6 (15.2–82.5)	0.478
Pulmonary/RV-PA conduit stenosis, N (%)	22 (73.3)	5 (35.7)	13 (59.1)	0.209
Degree of stenosis				0.614
• Mild, N (%)	12 (54.5)	3 (60)	8 (61.5)	
• Moderate, N (%)	7 (31.8)	2 (40)	5 (38.5)	
• Severe, N (%)	3 (13.6)	0 (0)	0 (0)	
Pulmonary/RV-PA conduit insufficiency, N (%)	18 (60)	9 (64.3)	21 (70)	0.277
Degree of pulmonary insufficiency				0.181
• Mild, N (%)	11 (61.1)	5 (55.6)	12 (57.1)	
• Moderate, N (%)	7 (38.9)	4 (44.4)	5 (23.8)	
• Severe, N (%)	0 (0)	0 (0)	4 (19)	
Right ventricular systolic function				0.033
• Good, N (%)	28 (93.3)	12 (92.3)	21 (70)	0.033
• Mild dysfunction, N (%)	2 (6.7)	1 (7.7)	9 (30)	0.033
• Moderate dysfunction, N (%)	0 (0)	0 (0)	0 (0)	
• Severe dysfunction, N (%)	0 (0)	0 (0)	0 (0)	
CMR, N (%)	28 (93.3)	10 (71.4)	28 (93.3)	0.059
LVEF (%)	60 ± 6	61 ± 7	56 ± 6	0.072
RVEF (%)	55 ± 7	55 ± 8	45 ± 8	< 0.001 ^b
LV end-diastolic volume (cc/m ²)	87 (47–145)	84 (67–116)	83 (41–101)	0.360
RV end-diastolic volume (cc/m ²)	94 ± 26	101 ± 12	123 ± 25	< 0.001 ^c
Pulmonary regurgitation fraction (%)	9 (1–59)	29 (15–60)	30 (1.5–45)	0.007 ^d
Wall motion abnormalities disorder, N (%)	2 (7.7)	0 ± 0	1 (3.7)	0.629
Myocardial fibrosis, N (%)	7 (33.3)	1 (14.3)	9 (33.3)	0.595
Type of fibrosis				0.624
• Transmural, N (%)	0 (0)	0 (0)	1 (11.1)	
• Non-transmural, N (%)	7 (100)	1 (100)	8 (89.9)	
• Ischemic, N (%)	3 (14.3)	0 (0)	2 (7.7)	

Data are means ± standard deviation or median and ranges where appropriate. **Abbreviations:** ASO = atrial switch operation, LVEF = left ventricular ejection fraction, RV = right ventricle, RVEF = right ventricular ejection fraction, RV-PA conduit = right ventricle to pulmonary conduit, TOF = tetralogy of Fallot.

^a p = 0.003 for Ross vs. TOF.

^b p < 0.001 for Ross vs. TOF and ASO vs. TOF.

^c p < 0.001 for Ross vs. TOF.

^d p = 0.002 for Ross vs. TOF.

trend towards a more severe right ventricular (RV) outflow tract (RVOT)/pulmonary/RV to pulmonary artery (PA) conduit stenosis. RV ejection fraction was lower and RV end-diastolic volume was larger in TOF compared to Ross and ASO patients, probably due to the significantly more severe degree of pulmonary regurgitation in the TOF group. Left ventricular volumes and function did not differ significantly between groups. There were no differences with regard to wall motion abnormalities or myocardial scar between groups. No patient presented myocardial ischemia on CMR.

Cardiac computed tomography (CCT) and coronary angiography

A total of thirteen patients underwent a CCT or a coronary angiography, respectively. CCT was performed in 9 (30%) Ross patients, 3 (21%) ASO and 1 (3.3%) TOF patients (p = 0.023). Six (20%) Ross patients, 3 (21%) ASO and 3 (13%) TOF patients (p = 0.727) underwent coronary angiography. No coronary artery stenosis was detected by any of the exams.

Predictors of positive exercise tests

The clinical, echocardiographic and CMR parameters indicated in Tables 1–3 were compared between both groups of patients with positive and negative exercise tests. Patients with positive exercise tests showed a significantly higher maximum RVOT/RV-PA/pulmonary valve gradient and higher prevalence of a severe RVOT/RV-PA/pulmonary valve stenosis than patients with normal exercise tests (Table 4, Figs. 1 and 2). None of the other parameters differed significantly between groups with positive and negative exercise tests (data not shown).

The prevalence of positive exercise tests did not differ between groups of Ross patients when differentiating according to the indication for surgery. Four (26%) patients with initial aortic stenosis, two (29%) with aortic regurgitation and two (25%) with mixed aortic disease (both regurgitation and stenosis) had a positive exercise test (p = 0.988).

Discussion

This study demonstrates in Ross patients a trend towards a higher prevalence of positive exercise tests suggesting myocardial ischemia in comparison to ASO and TOF patients. Nevertheless, no coronary artery stenosis was detected by any complementary non- or invasive exam and positive exercise tests were related to the presence of a stenosis of the RVOT or pulmonary valve.

Since the introduction of the ASO for TGA concern raised with regard to complications due to the, sometimes complex, transfer of coronary arteries during the surgical intervention early in life. Some series revealed frequent coronary artery lesions which were discussed to be responsible for sudden cardiac deaths (SCD) observed in this population [18–20]. The anatomic relationship between the coronary arteries and the great arteries appears to play an important role for the development of coronary obstructions late after repair [11].

Although the outcome after the Ross procedure is excellent, a recent study including 793 patients, however, revealed a rate of unexplained SCD of 0.015% [21]. Even if the reimplantation of coronary arteries during the Ross procedure is less complex than during the ASO, one could

Table 4

Comparison between positive and negative exercise tests.

	Positive exercise tests (n = 11)	Negative exercise tests (n = 63)	p-value
Pulmonary valve maximal gradient (mmHg)	44 ± 30	22 ± 13	0.004
Pulmonary/RV-PA conduit stenosis degree, N (%)	1.8 (1.4–2.3)	1.7 (1.5–2.2)	<0.001
• Mild, N (%)	1 (9.1)	27 (42.8)	0.161
• Moderate, N (%)	4 (36.3)	11 (17.4)	0.301
• Severe, N (%)	3 (27.3)	0 (0)	0.006

Abbreviations: RV-PA conduit = right ventricular to pulmonary artery conduit.

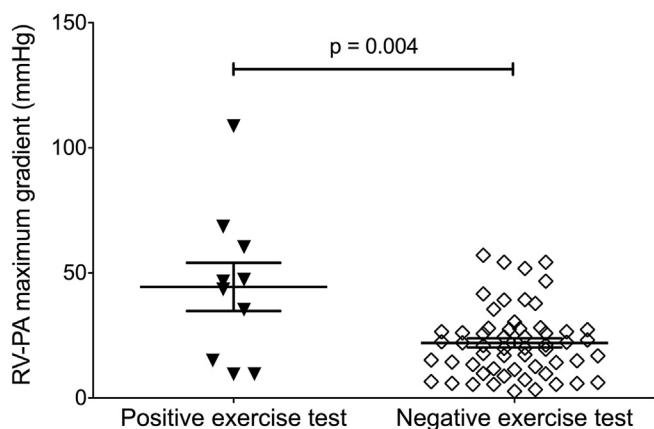


Fig. 1. Comparison of maximum RV-PA gradient between patients with positive and negative exercise tests.

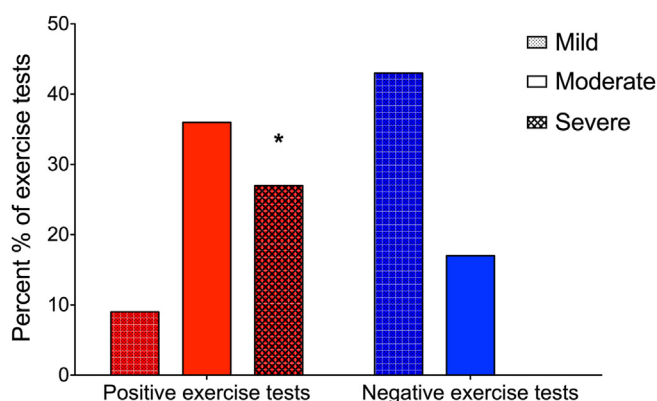


Fig. 2. Comparison of distribution of RV-PA stenosis between groups with positive and negative exercise tests. *p = 0.006 for comparison of prevalence of severe stenosis between both groups.

speculate that coronary artery distortion with consecutive obstruction could explain some of the observed SCD, in particular in patients who underwent the procedure at very young age.

The good news is therefore that, in line with recent studies focussing on ASO patients, our study did not find signs for relevant coronary artery complications neither in Ross nor in ASO patients. E.g. Tobler et al. could not demonstrate any signs of myocardial ischemia in adult TGA patients after ASO [22]. A recent meta-analysis supports these observations. The authors concluded that routine exercise testing or imaging of coronary arteries does not appear to be necessary to prevent SCD in TGA patients after ASO and more conservative management strategy by clinical evaluation and periodic echocardiography could be reasonable given the low mortality rate [23].

Current guidelines for CHD recommend surveillance of exercise capacity by physiological exercise testing in all three patient groups (Ross, ASO and TOF) included in this study [13]. Little is known, however, on the relevance of, in particular electrically positive exercise tests which could suggest myocardial ischemia. Our study provides therefore important information and guidance for physicians for the interpretation of positive exercise tests in these patients. The whole clinical picture of the patient and in particular the presence of right-sided lesions have to be taken into consideration. Based upon our results, even if coronary angiography remains the gold standard for the detection of coronary artery disease, the low prevalence of coronary artery complications in these patients does not appear to justify the 2% risk of complication of such an invasive investigation [18,24]. We usually opt for a non-invasive exam such as CMR or CCT, if the clinical suspicion is high for myocardial

ischemia. As previously discussed, adenosine stress CMR has been used in ASO patients not revealing any clinical relevant ischemia [22]. A further recent study evaluated children after ASO with adenosine stress echocardiography and technetium 99m-Sestamibi Myocardial Perfusion without evidence of ischemia [25]. However, one could discuss whether vasodilator stress testing is the appropriate technique to detect ischemia in patients after coronary artery reimplantation. As ischemia could be the result of dynamic changes during exercise due to e.g. coronary artery distortion at the implantation site, the vasodilator technique, which is highly reliable for detection of classical, atherosclerotic stenosis, might miss such a complication [26]. To avoid ionizing radiation techniques in this young population, the use of e.g. dobutamine or physical stress CMR or echocardiography is an alternative allowing evaluation of stress induced wall-motion abnormalities after coronary reimplantation [27-29]. Interestingly, a study using dobutamine stress echocardiography found wall motion abnormalities in young ASO [30]. As all patients had normal coronary angiograms, the authors speculated that rather a global left ventricular dysfunction than coronary artery complications explained their findings. A physical stress echocardiography in children after Ross procedure did not observe new pathological wall motion abnormalities [31].

Our findings are also in line with the recent European Society of Cardiology (ESC) Guidelines on Chronic Coronary Syndromes (CCS) [26]. Exercise ECG testing is no longer recommended for the detection of coronary artery stenosis due to its poor specificity and sensitivity [26, 32].

False positive exercise tests can be explained by several mechanisms. First, pathologies of the pulmonary valve and/or the RVOT limit interpretation of the electrocardiographic response to exercise. As shown in our study, patients with positive exercise test had a significantly higher prevalence of pulmonary valvular/RVOT/RV-PA conduit stenosis. Increase of the pulmonary valve gradient leads to a right ventricular pressure overload, consecutive subendocardial hypoperfusion and finally ischemia when maximal coronary vasodilation is achieved [33]. This results in ECG modifications and ultimately false positive exercise test in the absence of obstructive epicardial coronary artery disease.

One could also speculate that cardiac memorizing of ECG changes before the surgical intervention could play a role. Unfortunately, pre-surgical exercise tests were available only for three Ross patients, however, two of these patients showed exercise-induced ECG changes in the same territory before and after surgical correction.

Myocardial fibrosis and scar is frequently found in patients after surgical repair of CHD [34]. Similarly to what has been previously described, some of our patients presented myocardial fibrosis but only in five patients typical for an ischemic origin. However, fibrosis was not related to positive exercise tests.

Despite a successful correction of aortic stenosis during the Ross procedure, one could expect that this condition would be associated with more positive exercise tests due to risk of persistent pathological ventricular hypertrophy [35]. Nevertheless, our results did not show a higher prevalence of positive exercise tests in these patients compared to those operated for aortic regurgitation or mixed aortic disease.

Unlike the Ross procedure and the ASO, the TOF correction does not involve coronary artery reimplantation. Coronary events in this group of patients are therefore poorly described [36]. No coronary artery disease was found in this population in the present study. TOF patients presented with larger RV with diminished systolic function compared to the both other groups. These complications are frequent and explained by the initial surgical correction often leading to significant pulmonary regurgitation [37-39]. The resulting chronic volume overload of the RV leads to ventricular dilatation rather than to RV hypertrophy, which might explain why TOF patients presented less frequently (false) positive exercise tests as exercise induced subendocardial ischemia is more likely to be found in pathological hypertrophy due to e.g. RVOT stenosis.

Limitations

This study is limited by its retrospective nature and relatively small population size. Thus, the comparison of variables between patients is sometimes inhomogeneous although we were able to match the Ross and TOF groups. Even though patients received regular follow-up, individualized management limited the availability of certain tests, such as CMR, CCT and coronary angiography. Indeed, only symptomatic patients benefited from invasive examination for coronary artery disease.

CHD patients often present with changes of resting ECGs limiting their interpretation during exercise tests. Most often, RBBB are found in patients with RV pathologies like the present patient population. However, the presence of a RBBB does not preclude the interpretation of ECG leads not concerned from changes induced by the RBBB [40-42]. No patient had left bundle branch block.

Like the majority of studies on CHD, outcomes were evaluated at medium term [3]. Extending this project on a larger number of individuals with long-term objectives would be interesting. However, this study shall give an orientation about prevalence of positive exercise tests in our patient population and could serve as a basis for standardizing follow-up for future prospective studies.

Conclusion

Our study does not reveal any coronary artery complication after coronary artery reimplantation during surgical correction for CHD. Exercise testing has a poor specificity in detection of coronary artery stenosis and positive exams appear rather to be related to RVOT pathologies than to coronary artery complications and its role should be restricted to evaluation of exercise capacity. Given the low prevalence of coronary artery complications, non-invasive investigations should be favoured before proceeding to invasive procedures.

Declaration of competing interest

The authors declare that they have no known competing financial interests or personal relationships that could have appeared to influence the work reported in this paper.

References

- Ross D. Replacement of aortic and mitral valves with a pulmonary autograft. *Lancet* 1967 Nov 4;290(7523):956–8.
- Ouzounian M, Mazine A, David TE. The Ross procedure is the best operation to treat aortic stenosis in young and middle-aged adults. *J Thorac Cardiovasc Surg* 2017 Sep;154(3):778–82.
- Best KE, Rankin J. Long-term survival of individuals born with congenital heart disease: a systematic review and meta-analysis. *J Am Heart Assoc* 2016 Jun;5(6):e002846.
- Brown JW, Ruzmetov M, Shahriari A, Rodefeld MD, Mahomed Y, Turrentine MW. Midterm results of Ross aortic valve replacement: a single-institution experience. *Ann Thorac Surg* 2009 Aug;88(2):601–7. 608.
- Andreas M, Wiedemann D, Seebacher G, Rath C, Aref T, Rosenhek R, et al. The Ross procedure offers excellent survival compared with mechanical aortic valve replacement in a real-world setting. *Eur J Cardio Thorac Surg* 2014 Sep 1;46(3):409–14.
- Mookhoek A, de Kerchove L, El Khoury G, Weimar T, Luciani GB, Mazzucco A, et al. European multicenter experience with valve-sparing reoperations after the Ross procedure. *J Thorac Cardiovasc Surg* 2015 Nov;150(5):1132–7.
- David TE, David C, Woo A, Manlihot C. The Ross procedure: outcomes at 20 years. *J Thorac Cardiovasc Surg* 2014 Jan;147(1):85–93.
- David TE. Reoperations after the Ross procedure. *Circulation* 2010 Sep 21;122(12):1139–40.
- Frigiola A, Ranucci M, Carlucci C, Giamberti A, Abella R, Di Donato M. The Ross procedure in adults: long-term follow-up and echocardiographic changes leading to pulmonary autograft reoperation. *Ann Thorac Surg* 2008 Aug;86(2):482–9.
- Böhm JO, Hemmer W, Rein J-G, Horke A, Roser D, Blumenstock G, et al. A single-institution experience with the Ross operation over 11 years. *Ann Thorac Surg* 2009 Feb;87(2):514–20.
- Ou P, Khraiche D, Celermajer DS, Agnoletti G, Le Quan Sang K-H, Thalabard JC, et al. Mechanisms of coronary complications after the arterial switch for transposition of the great arteries. *J Thorac Cardiovasc Surg* 2013 May;145(5):1263–9.

- Tsuda T, Bhat AM, Robinson BW, Baffa JM, Radtke W. Coronary artery problems late after arterial switch operation for transposition of the great arteries. *Circ J Off Jpn Circ Soc* 2015;79(11):2372–9.
- Baumgartner H, De Backer J, Babu-Narayan SV, Budts W, Chessa M, Diller G-P, et al. ESC Guidelines for the management of adult congenital heart disease. *Eur Heart J* [Internet]. 2020. 2020 Aug 29 [cited 2020 Nov 14]; Available from, <https://academic.oup.com/eurheartj/advance-article/doi/10.1093/eurheartj/ehaa554/5898606>.
- Stout KK, Daniels CJ, Aboulhosn JA, Bozkurt B, Broberg CS, Colman JM, et al. AHA/ACC guideline for the management of adults with congenital heart disease: a report of the American college of cardiology/American heart association task force on clinical practice guidelines. *J Am Coll Cardiol* 2018;73(12):e81–192. 2019 02.
- Bruce RA, Kusumi F, Hosmer D. Maximal oxygen intake and nomographic assessment of functional aerobic impairment in cardiovascular disease. *Am Heart J* 1973 Apr;85(4):546–62.
- Fletcher GF, Ades PA, Kligfield P, Arena R, Balady GJ, Bittner VA, et al. Exercise standards for testing and training: a scientific statement from the American heart association. *Circulation* 2013 Aug 20;128(8):873–934.
- Gertsch M. The ECG [internet]. Berlin, Heidelberg: Springer Berlin Heidelberg; 2004 [cited 2020 Nov 14]. Available from, <http://link.springer.com/10.1007/978-3-662-10315-9>.
- Raisky O, Bergoend E, Agnoletti G, Ou P, Bonnet D, Sidi D, et al. Late coronary artery lesions after neonatal arterial switch operation: results of surgical coronary revascularization. *Eur J Cardio-Thorac Surg Off J Eur Assoc Cardio-Thorac Surg*. 2007 May;31(5):894–8.
- Angeli E, Raisky O, Bonnet D, Sidi D, Vouhé PR. Late reoperations after neonatal arterial switch operation for transposition of the great arteries. *Eur J Cardio-Thorac Surg Off J Eur Assoc Cardio-Thorac Surg*. 2008 Jul;34(1):32–6.
- Bonhoeffer P, Bonnet D, Piéchaud JF, Stümper O, Aggoun Y, Villain E, et al. Coronary artery obstruction after the arterial switch operation for transposition of the great arteries in newborns. *J Am Coll Cardiol* 1997 Jan;29(1):202–6.
- Sharifulin R, Bogachev-Prokophiev A, Zheleznev S, Demin I, Pivkin A, Afanasyev A, et al. Factors impacting long-term pulmonary autograft durability after the Ross procedure. *J Thorac Cardiovasc Surg* 2018 Jun 4.
- Tobler D, Motwani M, Wald RM, Roche SL, Verocai F, Iwanochko RM, et al. Evaluation of a comprehensive cardiovascular magnetic resonance protocol in young adults late after the arterial switch operation for d-transposition of the great arteries [Internet]. *J Cardiovasc Magn Reson* 2014 Dec [cited 2017 Mar 3];16(1). Available from, <http://jcmr-online.biomedcentral.com/articles/10.1186/s12968-014-0098-5>.
- van Wijk SWH, van der Stelt F, Ter Heide H, Schoof PH, Doevendans PAFM, Meijboom FJ, et al. Sudden death due to coronary artery lesions long-term after the arterial switch operation: a systematic review. *Can J Cardiol* 2017;33(9):1180–7.
- Tavakol M, Ashraf S, Brenner SJ. Risks and complications of coronary angiography: a comprehensive review. *Global J Health Sci* 2012 Jan 1;4(1):65–93.
- Kumar K, Sharma A, Patel C, Ramakrishnan S, Das S, Sangdup T, et al. Feasibility and utility of adenosine stress echocardiography in children following post-arterial switch operation: a comparison with technetium 99m-sestamibi myocardial perfusion SPECT (MPS). *Pediatr Cardiol* 2021 Jan 29.
- Knuuti J, Wijns W, Saraste A, Capodanno D, Barbato E, Funck-Brentano C, et al. ESC Guidelines for the diagnosis and management of chronic coronary syndromes. *Eur Heart J* 2019;41(3):407–77. 2020 Jan 14.
- Kilner PJ, Geva T, Kaemmerer H, Trindade PT, Schwitzer J, Webb GD. Recommendations for cardiovascular magnetic resonance in adults with congenital heart disease from the respective working groups of the European Society of Cardiology. *Eur Heart J* 2010 Apr;31(7):794–805.
- Ernis P. Stress echocardiography: an overview for use in pediatric and congenital cardiology. *Congenit Heart Dis* 2017 Sep;12(5):624–6.
- Brothers JA, McBride MG, Selim MA, Marino BS, Tomlinson RS, Pampaloni MH, et al. Evaluation of myocardial ischemia after surgical repair of anomalous aortic origin of a coronary artery in a series of pediatric patients. *J Am Coll Cardiol* 2007 Nov;50(21):2078–82.
- Hui L. Assessment of left ventricular function long term after arterial switch operation for transposition of the great arteries by dobutamine stress echocardiography. *Heart* 2005 Jan 1;91(1):68–72.
- Pauliks LB, Brian Clark J, Rogerson A, DiPietro A, Myers JL, Cyran SE. Exercise stress echocardiography after childhood Ross surgery: functional outcome in 26 patients from a single institution. *Pediatr Cardiol* 2012 Jun;33(5):797–801.
- Legendre A, Losay J, Touchot-Koné A, Serraf A, Belli E, Piot JD, et al. Coronary events after arterial switch operation for transposition of the great arteries. *Circulation* 2003 Sep 9;108(Suppl 1):II86–190.
- Greyson CR. The right ventricle and pulmonary circulation: basic concepts. *Rev Esp Cardiol Engl Ed* 2010 Jan;63(1):81–95.
- Babu-Narayan SV, Kilner PJ, Li W, Moon JC, Goktekin O, Davlouros PA, et al. Ventricular fibrosis suggested by cardiovascular magnetic resonance in adults with repaired tetralogy of fallot and its relationship to adverse markers of clinical outcome. *Circulation* 2006 Jan 24;113(3):405–13.
- Beach JM, Mihaljevic T, Rajeswaran J, Marwick T, Edwards ST, Nowicki ER, et al. Ventricular hypertrophy and left atrial dilatation persist and are associated with reduced survival after valve replacement for aortic stenosis. *J Thorac Cardiovasc Surg* 2014 Jan;147(1):362–369.e8.
- Egbe AC, Ananthaneni S, Jadav R, Kothapalli S, Rihal CS, Masood M, et al. Coronary artery disease in adults with tetralogy of Fallot. *Congenit Heart Dis* 2019 May;14(3):491–7.
- Geva T. Indications for pulmonary valve replacement in repaired tetralogy of fallot: the quest continues. *Circulation* 2013 Oct 22;128(17):1855–7.

- [38] Geva T. Repaired tetralogy of Fallot: the roles of cardiovascular magnetic resonance in evaluating pathophysiology and for pulmonary valve replacement decision support. *J Cardiovasc Magn Reson Off J Soc Cardiovasc Magn Reson* 2011 Jan 20; 13:9.
- [39] Bouzas B. Pulmonary regurgitation: not a benign lesion. *Eur Heart J* 2004 Dec 14; 26(5):433–9.
- [40] Yen RS, Miranda C, Froelicher VF. Diagnostic and prognostic accuracy of the exercise electrocardiogram in patients with preexisting right bundle branch block. *Am Heart J* 1994 Jun;127(6):1521–5.
- [41] Wangsnes KM, Gibbons RJ. Optimal interpretation of the supine exercise electrocardiogram in patients with right bundle branch block. *Chest* 1990 Dec; 98(6):1379–82.
- [42] Whinnery JE, Froelicher VF, Longo MR, Triebwasser JH. The electrocardiographic response to maximal treadmill exercise of asymptomatic men with right bundle branch block. *Chest* 1977 Mar;71(3):335–40.