


Successful closure of transcatheter aortic valve replacement-induced Gerbode defect with valve-in-valve technique: A case report

Ioannis Skalidis MD^{1,2}  | Michalis Hamilos MD, PhD¹ |
Stylianos Petousis MD, PhD¹ | George Kochiadakis MD, PhD¹ |
Emmanouil Skalidis MD, PhD¹

¹Department of Cardiology, University Hospital of Heraklion, Crete, Greece

²Department of Cardiology, Lausanne University Hospital, Lausanne, Switzerland

Correspondence

Ioannis Skalidis, MD, Department of Cardiology, Lausanne University Hospital, Rue du Bugnon 46, 1011, Lausanne, Switzerland.
Email: skalidis7@gmail.com

Abstract

We present the first documented case of a successful closure of a transcatheter aortic valve replacement (TAVR)-induced Gerbode defect using a valve-in-valve approach. A 90-year-old female with severe aortic stenosis underwent TAVR. Following post-dilatation, the patient experienced hemodynamic deterioration and collapse due to tamponade and sub-annular rupture leading to hemodynamic deterioration and the development of a Gerbode defect with communication between the left ventricle and right atrium. Hemodynamic stabilization was achieved through pericardiocentesis, followed by the low implantation of a second valve, effectively sealing the rupture. This case showcases a valuable alternative for managing rare challenging complications during TAVR procedures.

KEYWORDS

AOD—aortic disease, AVDP—aortic valve disease, percutaneous intervention, TVI—transcatheter valve implantation

1 | INTRODUCTION

Transcatheter aortic valve replacement (TAVR) has transformed aortic stenosis treatment through minimally invasive procedures. While generally successful, TAVR can entail rare complications, such as Gerbode defects, involving abnormal ventricular-atrial communication. This report presents a novel case of TAVR-induced Gerbode defect closure using a valve-in-valve technique, emphasizing the significance of prompt intervention and innovative solutions in addressing intricate complications. As TAVR continues to advance, understanding and managing uncommon scenarios like Gerbode defects contribute to refining procedural safety and effectiveness.

2 | CASE PRESENTATION

A 90-year-old female with New York Heart Association class III symptoms and multiple episodes of syncope presented with severe aortic stenosis. The maximum pressure gradient across the aortic valve was measured at 110 mmHg, and the EuroSCORE II was 3.72%. Computer tomography imaging revealed a heavy calcified aortic valve with a minimum diameter of 17.5 mm and a maximum diameter of 24.6 mm (Figure 1A). The annulus perimeter was 68.1 mm.

After balloon dilatation with a 20 mm Z-MED II balloon (Braun Interventional Systems Inc.), which achieved almost complete sealing of the valve, the decision was made to implant an Evolut R 26 mm

This is an open access article under the terms of the [Creative Commons Attribution-NonCommercial-NoDerivs](https://creativecommons.org/licenses/by-nc-nd/4.0/) License, which permits use and distribution in any medium, provided the original work is properly cited, the use is non-commercial and no modifications or adaptations are made.

© 2023 The Authors. *Catheterization and Cardiovascular Interventions* published by Wiley Periodicals LLC.

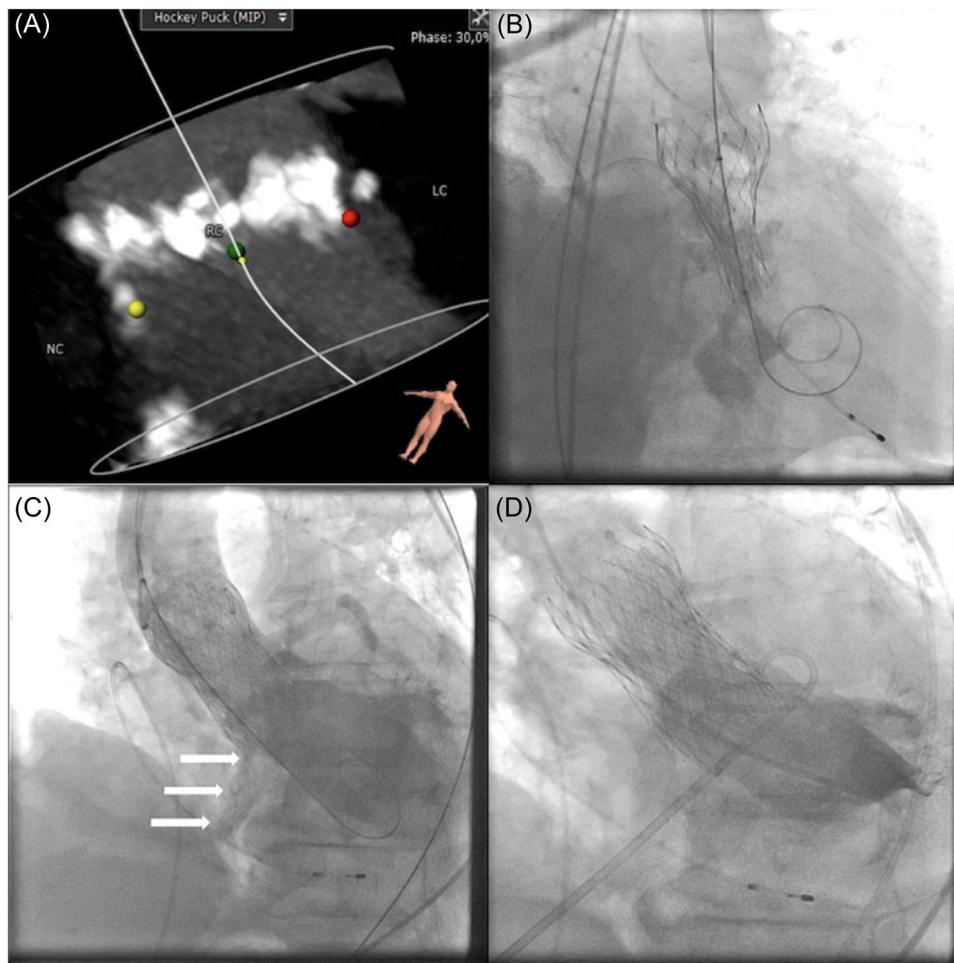


FIGURE 1 (A) Calcium distribution in the left anterior oblique 37° and caudal 7° projections. (B) Under-expanded Evolut R 26 mm in the right anterior oblique projection, observed before inflation of the 22 mm balloon. (C) Iatrogenic Gerbode defect highlighted by contrast flow into the right atrium, indicated by white arrows. (D) Successful sealing of perforation following low implantation of the second valve.

valve (Medtronic). However, post-dilatation with 20 and 22 mm balloons was necessary due to significant restriction and under-expansion of the prosthetic valve (Figure 1B) (Video S1).

Immediately following the post-dilatation, the patient experienced hemodynamic deterioration and collapse. The patient was intubated, and Cardio-Pulmonary-Resuscitation was immediately initiated. Further assessment with echocardiography revealed tamponade and a sub-annular communication between the left ventricle and right atrium, which was equally observed in aortography (Figure 1C) (Video S2). Ventriculography also confirmed the presence of communication, as evidenced by contrast opacification of the right atrium, suggesting a Gerbode defect (Video S3). After high dose of inotropes and vasoconstrictives administration, pericardiocentesis and autologous blood transfusion, the patient was briefly stabilized. Given the high operative risk, and after discussion with the cardiac surgery team, the decision to percutaneously manage the complication was made. Since specific occluder devices were not available at the catheterization laboratory, a second valve was implanted using a low implantation technique, guided by fluoroscopy, with the target depth of the second valve at 10 mm below the first valve allowing the protective skirt to

cover the rupture. Ventriculography confirmed the successfully sealing of the perforation using the valve-in-valve technique with immediate clinical and hemodynamic amelioration and without further complications. The patient was extubated the following day, without any circulatory support and discharged 5 days later (Figure 1D) (Video S4).

3 | DISCUSSION

In this case, we present a unique and rare complication of TAVR: the development of a Gerbode defect.¹ The Gerbode defect is characterized by a communication between the left ventricle and right atrium, and it is typically associated with infective endocarditis, trauma, or congenital abnormalities. This is the first reported case of a TAVR-induced Gerbode defect successfully closed using a valve-in-valve approach.

The development of a Gerbode defect during TAVR can be attributed to several potential factors.² Previous reports have suggested that severe, asymmetric calcification of the native valve, an elliptic aortic annulus, oversizing of the valve, or higher placement

of the valve may contribute to the occurrence of this complication.² Direct trauma to the septum from the implanted valve, compounded by further annulus dilation, may also play a role.

In our case, the patient exhibited severe aortic stenosis with heavy calcification that might have predisposed the patient to an increased risk of complications during TAVR. Despite balloon dilatation with a 20 mm balloon achieving almost complete sealing of the valve, post-dilatation was necessary due to significant restriction and under-expansion of the prosthesis. It was during this post-dilatation phase that the Gerbode defect occurred, leading to hemodynamic deterioration and collapse (Figure 1C) (Video S2).

The prompt recognition and management of the Gerbode defect were crucial for achieving hemodynamic stabilization. Pericardiocentesis was performed to stabilize the patient, followed by the low implantation of a second valve using a valve-in-valve technique. While there is currently no bibliographic evidence supporting this approach, we believed that the protective skirt of the second valve could effectively seal the defect and restore normal cardiac function (Figure 1D) (Video S4).

The utilization of a valve-in-valve approach during the acute phase for the treatment of TAVR-induced Gerbode defects is a valuable learning point from this case report, offering a minimally invasive solution and avoiding the need for more invasive surgical interventions. While additional research is needed to establish optimal management strategies for TAVR-induced Gerbode defects, our case provides valuable insights into the potential efficacy of a valve-in-valve approach in the acute phase, highlighting the importance of considering alternative treatment options for rare complications encountered during TAVR.^{3,4}

4 | CONCLUSION

Our case report presents the successful closure of a TAVR-induced Gerbode defect using a valve-in-valve approach during the acute phase. This rare complication highlights the importance of recognizing and promptly managing unforeseen complications during TAVR procedures. The valve-in-valve technique proved effective in achieving hemodynamic stabilization and avoiding more invasive surgical interventions. Further research is warranted to enhance our

understanding of the mechanisms, risk factors, and optimal management strategies for this rare complication.

CONFLICT OF INTEREST STATEMENT

The authors declare no conflicts of interest.

DATA AVAILABILITY STATEMENT

The data that support the findings of this study are available from the corresponding author upon reasonable request.

ORCID

Ioannis Skalidis  <http://orcid.org/0000-0002-4374-0389>

REFERENCES

1. Ando T, Holmes AA, Taub CC, Slovut DP, DeRose JJ. Iatrogenic ventricular septal defect following transcatheter aortic valve replacement: a systematic review. *Heart, Lung Circ.* 2016;25(10):968-974. doi:10.1016/j.hlc.2016.03.012
2. Taha FA, Alnozha F, Amoudi O, Almutairi M, Abuelatta R. Transcatheter closure of residual and iatrogenic ventricular septal defects: tertiary center experience and outcome. *Pediatr Cardiol.* 2022;43(2):308-323.
3. Skalidis I, Roux O, Rotzinger DC, et al. Endovascular stent grafting for descending thoracic aortic rupture during TAVR. *JACC: Cardiovascular Interventions*. 2022;15(18):1880-1882.
4. Rouleau SG, Brady WJ, Koyfman A, Long B. Transcatheter aortic valve replacement complications: a narrative review for emergency clinicians. *Am J Emerg Med.* 2022;56:77-86.

SUPPORTING INFORMATION

Additional supporting information can be found online in the Supporting Information section at the end of this article.

How to cite this article: Skalidis I, Hamilos M, Petousis S, Kochiadakis G, Skalidis E. Successful closure of transcatheter aortic valve replacement-induced Gerbode defect with valve-in-valve technique: a case report. *Catheter Cardiovasc Interv.* 2023;102:1386-1388. doi:10.1002/ccd.30882