

# Choroidal Vascular Changes on Ultrawidefield Indocyanine Green Angiography in Central Serous Chorioretinopathy

## CERTAIN Study Report 1

Laurenz J.B. Pauleikhoff, MD,<sup>1,2</sup> Roselie M.H. Diederens, MD, PhD,<sup>1</sup> Jennifer M. Chang-Wolf, MD,<sup>1</sup> Annette C. Moll, MD, PhD,<sup>1</sup> Reinier O. Schlingemann, MD, PhD,<sup>1,3,4</sup> Elon H.C. van Dijk, MD, PhD,<sup>5</sup> Camiel J.F. Boon, MD, PhD<sup>1,5</sup>

**Purpose:** Choroidal venous overload was recently suggested to be a pathogenetic factor in central serous chorioretinopathy (CSC). Manifestations of venous overload on ultrawidefield indocyanine green angiography (UWF ICGA) include asymmetric arterial choroidal filling (AACF), enlarged choroidal vessels (“pachyvessels”), and asymmetric venous drainage (AVD) leading to choroidal intervortex venous anastomoses (CVAs) accompanied by choroidal vascular hyperpermeability (CVH). The purpose of the current study is to assess the presence of these signs of venous overload in a large cohort of CSC patients.

**Design:** Monocentric retrospective cohort study.

**Participants:** Consecutive CSC patients seen at a large tertiary referral center.

**Methods:** For the CERTAIN study, patients underwent a standardized imaging protocol including UWF ICGA. Features of choroidal venous overload were graded for each eye individually by 2 independent graders and, in case of disagreement, by a third grader.

**Main Outcome Measures:** Presence of AACF, pachyvessels, AVD, CVA, and CVH.

**Results:** In total, 178 eyes of 91 patients were included in this study. Mean patient age was 47.6 ( $\pm$  12.0) years and 75 patients (82%) were male. The 116 eyes (65%) that showed subretinal fluid were considered affected (bilateral disease in 29 patients). In affected eyes, AACF was present in 62 eyes (85% of gradable eyes), pachyvessels in 102 eyes (88%), AVD in 81 eyes (74%), CVA in 107 eyes (94%), and CVH in 100% of affected eyes. For fellow eyes, prevalence of pachyvessels (94%), AVD (67%), and CVA (90%) was similar to affected eyes, whereas CVH was present in 85% of fellow eyes. Intergrader agreement was excellent for CVH (94%), and 74%–82% for all other criteria. Patients with pachyvessels and AVD in 1 eye were more likely to also show the same characteristic in the fellow eye (odds ratios 22.2 and 9.9,  $P < 0.01$ ).

**Conclusions:** Signs of venous overload are seen in the vast majority of CSC patients, both in affected and unaffected eyes. Although pachyvessels, AVD, and CVA are observed frequently, CVH was observed in all affected eyes, showed excellent intergrader reliability, and is diagnostic for CSC. This supports the concept of choroidal venous overload as a major factor in CSC pathogenesis.

**Financial Disclosure(s):** Proprietary or commercial disclosure may be found in the Footnotes and Disclosures at the end of this article. *Ophthalmology Retina* 2024;8:254-263 © 2023 by the American Academy of Ophthalmology. This is an open access article under the CC BY license (<http://creativecommons.org/licenses/by/4.0/>).



Supplemental material available at [www.opthalmologyretina.org](http://www.opthalmologyretina.org).

Central serous chorioretinopathy (CSC) is one of the most common causes of fluid leakage in the posterior pole and primarily affects men between the ages of 20 and 60.<sup>1</sup> It is characterized by an accumulation of subretinal fluid (SRF), which in chronic cases can cause irreversible vision loss in conjunction with photoreceptor and retinal pigment epithelium (RPE) atrophy. The exact etiology of CSC remains unknown, but choroidal abnormalities, RPE

defects, and consecutive SRF leakage are assumed to play an important role.<sup>2–5</sup>

Indocyanine green angiography (ICGA) has improved our understanding of CSC by visualizing choroidal vascular changes. Early on, it was reported that asymmetric arterial choroidal filling (AACF) with the presence of flow voids during early-phase ICGA<sup>6,7</sup> and choroidal vascular hyperpermeability (CVH) as shown by mid- and late-phase

hyperfluorescence on ICGA<sup>8,9</sup> are common in CSC patients. More recently, ultrawidefield (UWF) ICGA was introduced, which allows for better visualization of the peripheral choroid. Based on this imaging, it was reported that CSC patients show a dilation of choroidal veins (“pachyvessels”),<sup>10,11</sup> choroidal venous anastomoses not respecting the watershed zone (CVA) between different vortex vein quadrants,<sup>12–14</sup> and asymmetric venous drainage (AVD) leading to enlarged or deflated vortex vein ampullae.<sup>10,11,15</sup> Some of these changes can also be observed on enhanced-depth imaging OCT (EDI-OCT), where many CSC patients show pachyvessels and CVA in combination with an increased choroidal thickness, which has been termed “pachychoroid” (i.e., “thick choroid”).<sup>5</sup> Importantly, choroidal thickening can also be observed in other retinal diseases that have collectively been termed the “pachychoroid disease spectrum.”<sup>16</sup> Besides CSC, members of this spectrum include pachychoroid pigment epitheliopathy,<sup>17</sup> pachychoroid neovasculopathy,<sup>18</sup> polypoidal choroidal vasculopathy,<sup>19</sup> peripapillary pachychoroid syndrome,<sup>20</sup> and, arguably, focal choroidal excavation.<sup>5</sup>

Remarkably, some of the ICGA phenomena described in CSC had previously been observed in patients with vortex vein occlusion or carotid cavernous sinus fistulas,<sup>21,22</sup> both of which cause an increase in choroidal venous pressure due to a blockade of venous drainage. This blockade causes choroidal venous enlargement (pachyvessels) and obstruction of some vortex vein quadrants more than others (AVD), which may consequently be compensated by choroidal intervortex venous anastomoses (CVAs). Due to the angiographic similarities between these diseases and CSC, this “venous overload choroidopathy” was hypothesized to play a role in CSC pathogenesis, where outflow obstruction was supposedly caused by a thickened sclera.<sup>4,23</sup>

This study aimed to assess the presence of various signs associated with possible venous overload on UWF ICGA images of 1 of the largest European cohorts of consecutive CSC patients referred to a tertiary referral center in affected eyes with (a history of) SRF and in fellow eyes without SRF.

## Methods

### Patients

The CERTAIN (Central sErous choRioretinopathy wIde-field aNgiography) study is a retrospective monocentric cohort study on consecutive patients that were referred to Amsterdam University Medical Centers with a clinical suspicion of CSC between September 1, 2021, and November 30, 2022. All patients were seen in retina clinics and underwent a standardized imaging protocol as part of their standard of care. Patient records were then retrospectively assessed on whether they met the eligibility criteria outlined below. The study was approved by the local ethics committee (Leiden University Medical Center ethics committee vote P14.297) and adhered to the tenets of the Declaration of Helsinki. The local ethics committee ruled that informed consent from each patient was not necessary due to the retrospective nature of the study.

### Main Inclusion and Exclusion Criteria

The main inclusion criteria were an age > 18 years and adherence to the imaging protocol as outlined below, including UWF imaging. The diagnosis of CSC was confirmed at the clinic visit by

experienced medical retina consultants (C.J.B., R.M.H.D., A.M., and R.S.) based on clinical examination and full multimodal imaging. Diagnostic criteria included current or previous SRF visible on an EDI-OCT scan and 1 or more regions of active focal leakage combined with RPE window defects visible on fundus fluorescein angiography (FFA). On “standard,” 55-degree ICGA, hyperfluorescent changes with an indistinct border, characteristic of diseases that are part of the pachychoroid disease spectrum, had to be present.<sup>17–19</sup> Both patients with acute and chronic CSC were included in this study. Main exclusion criteria were concomitant ophthalmic diseases that did not allow for an adequate UWF ICGA, such as severe cataract, or diseases of the posterior pole that compromised grading, such as proliferative diabetic retinopathy. In cases of suspected choroidal neovascularization (CNV), patients with a CNV without any clinical signs of CSC (idiopathic CNV) were excluded from the study. Eyes with signs of CSC and a secondary CNV were excluded from grading, whereas the respective fellow eyes with CSC but no evidence of CNV were included in the study. A suspicion of secondary CNV had to be confirmed by swept-source OCT angiography (ZEISS PLEX Elite 9000, Carl Zeiss Meditec Inc).

### Clinical Examinations

Electronic medical records were screened for patient demographics, ophthalmic medical history, and best-corrected visual acuity (BCVA). We considered eyes as affected if there was a reported history or current presence of SRF upon OCT. In contrast, eyes that had never shown SRF on OCT were considered fellow eyes. One grader (L.J.B.P.) assessed presence of diffuse atrophy of the retinal pigment epithelium,<sup>24</sup> defined as granular RPE window defects on mid-phase UWF fundus fluorescein angiography (FFA) and concomitant UWF fundus autofluorescence, hypoafluorescence, and posterior cystoid retinal degeneration,<sup>25</sup> defined as cystoid cavities mainly in the outer retina on EDI-OCT without evidence of CNV or associated leakage on UWF FFA. Imaging examples for each of these phenomena have been previously published.<sup>26</sup> Fundus fluorescein angiography leakage patterns were graded as either showing focal or diffuse leakage as reported previously by the same grader.<sup>27</sup> We measured subfoveal choroidal thickness in all cases where a central EDI-OCT scan taken at the time of UWF ICGA allowed for the detection of a hyperreflective border that demarcates the choroidal–scleral interface.

### Imaging Protocol

Patients underwent a standardized imaging protocol that included an EDI-OCT (Heidelberg Spectralis HRA2, Heidelberg Engineering), UWF fundus autofluorescence, UWF FFA, and UWF ICGA (all UWF imaging: Optos California, Optos plc). For UWF ICGA, multiple images were taken during the first 4 minutes after injection of indocyanine green, as well as after 10, 15, and 25 minutes. Because AACF could only be assessed on UWF ICGA images taken within the first few seconds after appearance of the dye, these were only performed on the affected or, in bilateral cases, the more severely affected eye. Ultrawidefield ICGA images were considered very early–phase when arterial filling could be observed (usually within the first 15 seconds after injection of the dye), early-phase when the choroidal venous vasculature was visible (usually from 30 seconds to 4 minutes after injection of the dye), mid-phase when fading of choroidal vessels as well as beginning choroidal hyperpermeability was observed (usually between 5 and 15 minutes), and late-phase when the choroidal vasculature appeared hypofluorescent and only choroidal hyperpermeability remained (usually at approximately 25 minutes after dye injection).

## Grading of Signs of Venous Overload

Ultrawidefield ICGA images were graded separately on each eye for the presence of AACF, pachyvessels, AVD, CVA, and CVH.

For the purpose of grading, the following definitions of each phenomenon were used:

- AACF: asymmetric arterial choroidal filling with  $\geq 1$  area of flow voids (delayed arterial filling).<sup>7</sup>
- Pachyvessels: central or paracentral vessels whose diameter did not decrease sufficiently between the vortex vein ampulla and the central watershed zone.<sup>10</sup>
- CVA: anastomotic vessels crossing the central watershed zone between the temporal superior and temporal inferior quadrants. In cases in which no individual vessels were distinguishable, an indistinguishable watershed zone was considered as a sign of CVA, whereas a clearly demarcated watershed zone was considered to indicate no CVA.<sup>12</sup>
- AVD: one or more enlarged or deflated vortex vein quadrants compared with the other vortex veins.<sup>15</sup>
- CVH: Mid- to late-phase focal or diffuse dye leakage on UWF ICGA was considered CVH.<sup>9</sup>

Imaging examples of these gradings are shown in [Figure 1](#). The grading was performed by 2 independent graders (L.J.B.P. and R.M.H.D.). In case of disagreement, a third grader (J.M.C.-W.) performed the deciding vote. All 3 graders were provided with reference imaging examples of each phenomenon as training before grading for this study. Asymmetric venous drainage could only be assessed when at least part of all vortex vein ampullae was captured on the early-phase UWF ICGA images.

## Statistical Analysis

Statistical analysis was performed using R software (version 4.2.2).<sup>23</sup> Best-corrected visual acuity measured on Snellen charts was converted to logarithm of the minimum angle of resolution (logMAR) BCVA using  $\log\text{MAR} = -\log(\text{Snellen fraction})$ . Statistical significance was tested using unpaired *t* tests for continuous variables and chi-squared tests for categorical variables. Fisher exact test was used if 1 of the categorical variables had 0 reads. Odds ratios were calculated using the *epitools* package and Fisher exact test *P*-values are reported. A *P*-value of  $< 0.05$  was considered statistically significant. No correction for multiple testing was performed due to the exploratory setting of this study.<sup>28</sup>

## Results

### Demographic and Baseline Characteristics

In total, 118 consecutive patients who were referred to our hospital with a suspicion of CSC were evaluated for this study. In 20 patients, the diagnosis of CSC was not confirmed at our center (7 idiopathic CNV, 5 age-related macular degeneration, 8 other chorioretinal diseases), and 7 patients did not undergo UWF ICGA (3 had the angiography performed at another center without UWF imaging, 3 had a 55° angiography performed instead, 1 did not show up). The remaining 178 eyes of 91 patients were included in this study because 4 eyes with suspected unilateral secondary CNV associated with CSC were excluded from the analysis. The patient flow from screening of patient records to study inclusion can be seen in [Figure S2](#) (available at [www.opthalmologyretina.org](http://www.opthalmologyretina.org)).

Of the included patients, 75 were male (82%), and mean patient age was 47.6 years (standard deviation [SD], 12.0 years). Median duration of symptoms at the time of angiography was 6 months

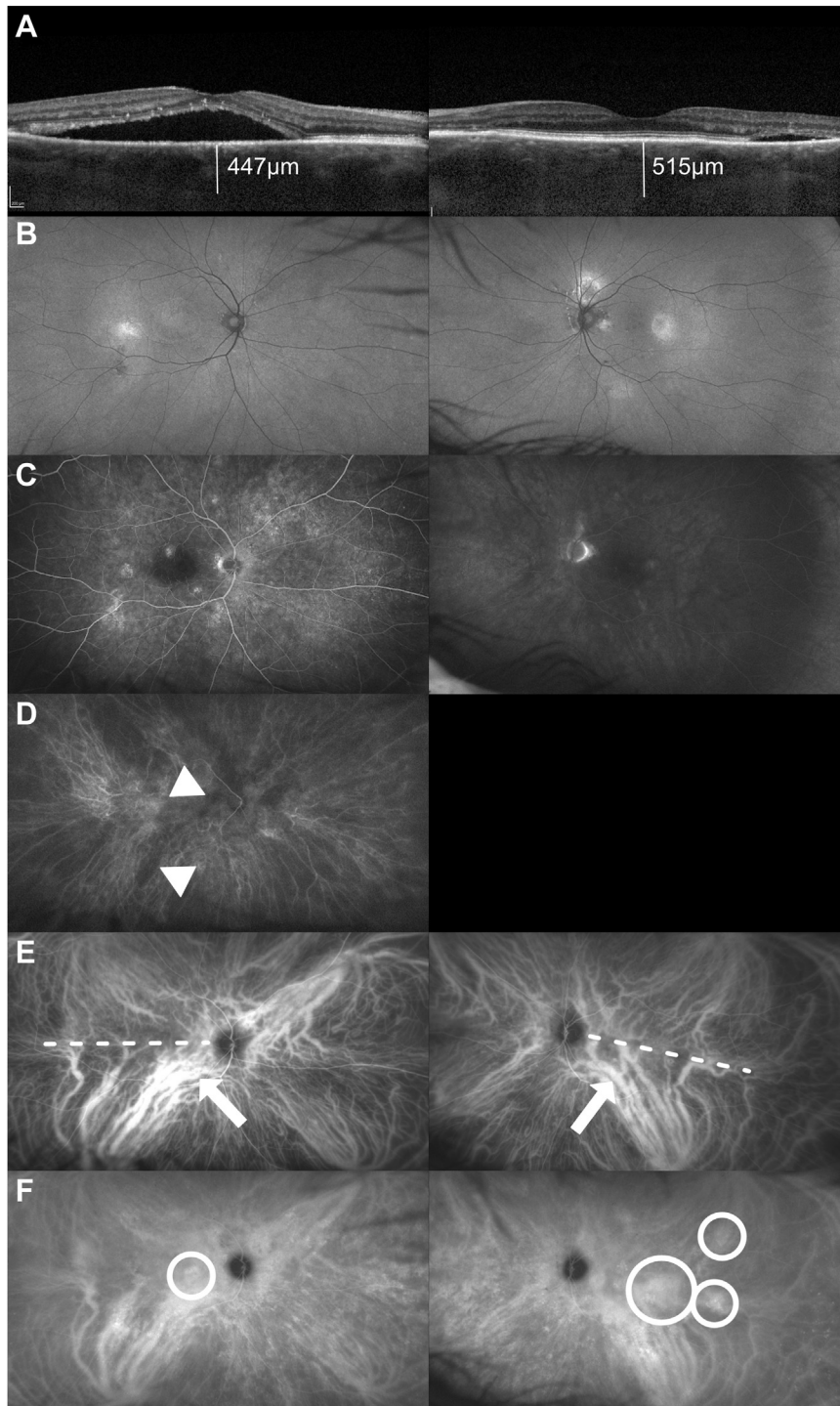
(interquartile range, 4–12 months), and 27 patients (29%) had a history of steroid use before the onset of symptoms. A history of or current SRF on OCT was present in 116 eyes (65%), which were thus considered affected, whereas 62 eyes (35%) had never shown SRF and were considered fellow eyes. Mean logMAR BCVA was 0.11 (SD, 0.23; Snellen equivalent  $\approx 20/25$ ) in affected eyes and  $-0.07$  (SD, 0.10; Snellen equivalent  $\approx 20/15$ ) in fellow eyes. In affected eyes, FFA leakage pattern was focal in 99 eyes (85%) and diffuse in 17 eyes (15%). Five fellow eyes (8%) showed leakage on FFA, all showing a focal leak due to singular serous RPE detachments. Choroidal thickness was significantly higher in the affected eyes than in the fellow eyes (361  $\mu\text{m}$  [SD, 99  $\mu\text{m}$ ] vs. 325  $\mu\text{m}$  [SD, 101  $\mu\text{m}$ ],  $P = 0.03$ ). Of note, 26% (24/94) of affected eyes and 40% (23/58) of fellow eyes showed a choroidal thickness of  $< 300 \mu\text{m}$ . Choroidal thickness was not assessable due to insufficient image quality in 26 eyes. Baseline characteristics can be found in [Table 1](#).

### Choroidal Venous Abnormalities

Regarding the presence of various signs of choroidal venous abnormalities in our cohort, we found AACF in 85% (62/73, no very early UWF ICGA image available for the remaining 43 affected eyes and for all fellow eyes), pachyvessels in 88% (102/116), CVA in 94% (107/116), AVD in 74% (81/110, not gradable in 6 eyes because not all vortex vein ampullae were captured), and CVH in 100% (116/116) of affected eyes ([Fig 3](#)). In total, 8 eyes of 7 patients showed CVH without any other sign of venous overload (see [Fig S4](#) for examples, available at [www.opthalmologyretina.org](http://www.opthalmologyretina.org)). Unaffected fellow eyes showed similar rates of pachyvessels (94%) and CVA (90%) compared with affected eyes, whereas slightly fewer fellow eyes showed AVD (67%) and CVH (85%). Asymmetric arterial choroidal filling could not be assessed in any fellow eyes because none of them had very early-phase UWF ICGA images taken (see [Table S2](#), available at [www.opthalmologyretina.org](http://www.opthalmologyretina.org)). We saw an intergrader agreement of 82% (60/73) regarding presence of AACF, 78% (139/178) on presence of pachyvessels, 76% (135/178) on CVA, 74% (124/168) on AVD, and 94% (168/178) on CVH.

We also assessed how the presence of any feature in the right eye impacted the likelihood of the same feature in the left eye. This revealed that patients whose right eye showed pachyvessels had 22.2 times higher odds of also showing pachyvessels in their left eye (confidence interval, 4.1–146.8;  $P < 0.01$ ). The same held true for those with AVD in the right eye, with 9.9 times higher odds of AVD in the left eye (confidence interval, 3.3–33.7;  $P < 0.01$ ). Interestingly, this was not the case for CVA (odds ratio, 1.9; confidence interval, 0.1–14.2;  $P = 0.50$ ) and not assessable for CVH because all patients showed CVH in  $\geq 1$  eye.

No statistically significant association was found between the various signs of venous overload and mean logMAR BCVA at baseline, gender, or FFA leakage pattern ([Table S3](#), available at [www.opthalmologyretina.org](http://www.opthalmologyretina.org)). Presence of pachyvessels (mean age: 47.8 years for patients with pachyvessels vs. 43.4 years for those without,  $P = 0.074$ ), CVA (mean age: 47.6 years vs. 44.4 years,  $P = 0.222$ ), and CVH (mean age: 47.7 years vs. 41.6 years,  $P = 0.109$ ) were more frequently seen in older patients, although this was not statistically significant. For patients with AVD vs. those without, this difference was statistically

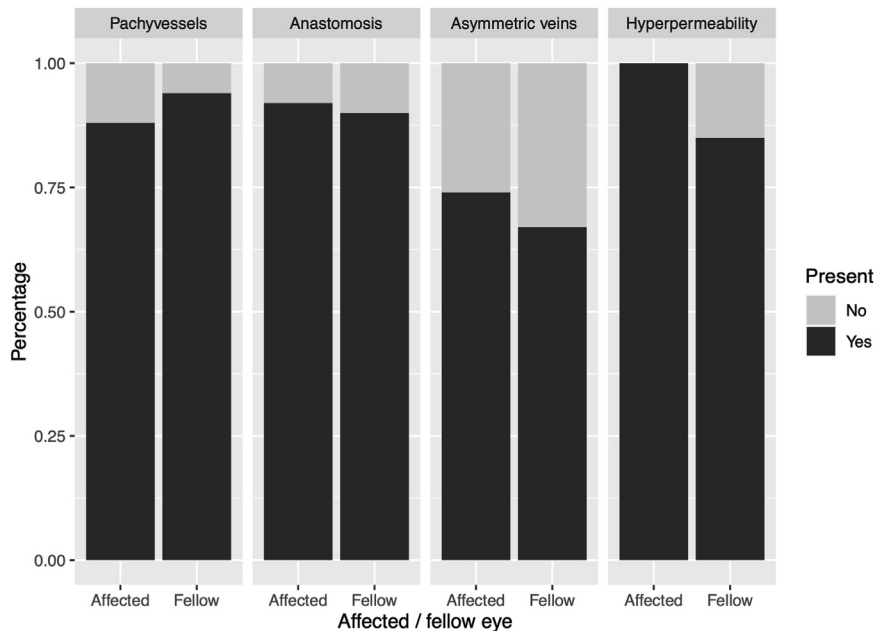


**Figure 1.** Multimodal ultrawidefield (UWF) imaging of different signs of venous overload in central serous chorioretinopathy. **A**, Enhanced-depth imaging OCT showing foveal subretinal fluid in the right eye and temporal to the macula in the left eye, as well as an increased choroidal thickness of 447  $\mu\text{m}$  the right and 515  $\mu\text{m}$  in the left eye. **B**, Fundus autofluorescence reveals hyperfluorescent changes temporal to the fovea in both eyes and above the optic disc in the left eye. **C**, Mid-phase (right) and late-phase (left) fundus fluorescein angiography showed multiple spots of pinpoint leakage in the right eye and 2 more indistinct areas (above the optic disc and temporal to the macula) in the left eye. **D**, Very early-phase UWF indocyanine green angiography (ICGA) shows areas of delayed arterial filling (arrow head) in the right eye. **E**, Early-phase UWF ICGA reveals enlarged choroidal veins (“pachyvessels”; arrows) that form anastomoses across the watershed zone (dotted line) between different vortex vein drainage areas in the macula and around the optic disc. An asymmetric distribution of the vortex vein drainage can be observed in both eyes, either favoring both the temporal inferior and nasal superior (right eye) or the temporal inferior quadrant only (left eye). **F**, Mid-phase UWF ICGA shows a single, focal area of choroidal hyperpermeability (left eye, circle) or multiple areas of choroidal hyperpermeability (right eye, circles).

Table 1. Baseline Characteristics of Patients Included in this Study

Patient Demographics	Eyes	Subgroup	Value
Age (yrs, mean ± SD)			47.6 ± 12.0
Gender (n, %)		Male	75/91 (82%)
		Female	16/91 (18%)
Duration of symptoms (mos, IQR)			6 (4 - 12)
Previous use of steroids (n, %)		Systemic	8/91 (9%)
		Topical	18/91 (20%)
		None	65/91 (71%)
Initial logMAR BCVA (mean ± SD)		Affected eye	0.11 ± 0.23
		Fellow eye	-0.07 ± 0.10
Diffuse RPE atrophy (n, %)	Affected eye	Yes	25/116 (22%)
		No	91/116 (77%)
	Fellow eye	Yes	0/62 (0%)
		No	62/62 (100%)
Posterior cystoid retinal degeneration (n, %)	Affected eye	Yes	7/116 (6%)
		No	109/116 (94%)
	Fellow eye	Yes	0/62 (0%)
		No	62/62 (100%)
FFA leakage pattern (n, %)	Affected eye	Focal	99/116 (85%)
		Diffuse	17/116 (15%)
		None	0/116 (0%)
	Fellow eye	Focal	5/62 (8%)
		Diffuse	0/62 (0%)
		None	57/62 (92%)
Choroidal thickness (mean ± SD)	Affected eye		361 ± 99 μm
	Unaffected eye		325 ± 101 μm

BCVA = best-corrected visual acuity; FFA = fundus fluorescein angiography; IQR = interquartile range; logMAR = logarithm of the minimum angle of resolution; RPE = retinal pigment epithelium; SD = standard deviation. The cohort showed a male preponderance and 27% of patients had a history of corticosteroids. Diffuse atrophy of the retinal pigment epithelium and posterior retinal degeneration are only seen in a minority of affected eyes (22% and 7%, respectively). Fundus fluorescein angiography showed a focal leakage pattern in most affected eyes (82%).



**Figure 3.** Presence of various signs of venous overload in the overall cohort. Bar chart showing the percentage of eyes exhibiting a certain feature of venous overload for affected and fellow eyes. Presence of a sign is shown in dark gray, whereas absence is denoted by a light gray color. A large proportion of patients showed pachyvessels and anastomoses not respecting the central watershed zones in both affected as well as fellow eyes. Asymmetric veins were seen in a lesser percentage of both affected and fellow eyes, whereas choroidal hyperpermeability was seen in all affected and the vast majority of fellow eyes.

significant (mean age: 48.5 years vs. 44.6 years, respectively;  $P = 0.039$ ).

## Discussion

Based on this study on 1 of the largest European cohorts of consecutive CSC patients so far, we conclude that signs of venous overload on UWF ICGA such as AAFC, pachyvessels, CVA, and AVD are seen in the vast majority of patients in both affected and fellow eyes without SRF. Choroidal vascular hyperpermeability on UWF ICGA was seen in all affected and almost all fellow eyes and was confirmed as a key diagnostic feature of CSC. This supports the hypothesis that venous overload may play an important part in the pathogenesis of CSC.

Our results are in accordance with a study by Bacci et al<sup>29</sup> on UWF ICGA imaging of 52 patients with various diseases within the pachychoroid disease spectrum, which found that 88% of eyes showed CVA (88% in our study). At the same time, CVH was observed in all eyes with pachychoroid-related diseases (100% in our study). Asymmetric venous drainage in the macular region was seen in 59% of eyes in the study by Bacci et al,<sup>29</sup> which was slightly less than the proportion we observed in eyes affected by CSC (74%). Other reports found pachyvessels in 83% of CSC eyes and, based on en-face OCT imaging, CVA in 79% of patients,<sup>14,15</sup> noting that asymmetry of venous drainage was observed more often in eyes with CSC than in fellow eyes without CSC, which was echoed by our results (AVD present in 74% of affected vs. 67% of fellow eyes). Our findings and previous smaller reports consistently show that between 70% and up to 100% of affected eyes and even most, as of yet unaffected, fellow eyes of CSC patients show signs of venous overload choroidopathy.

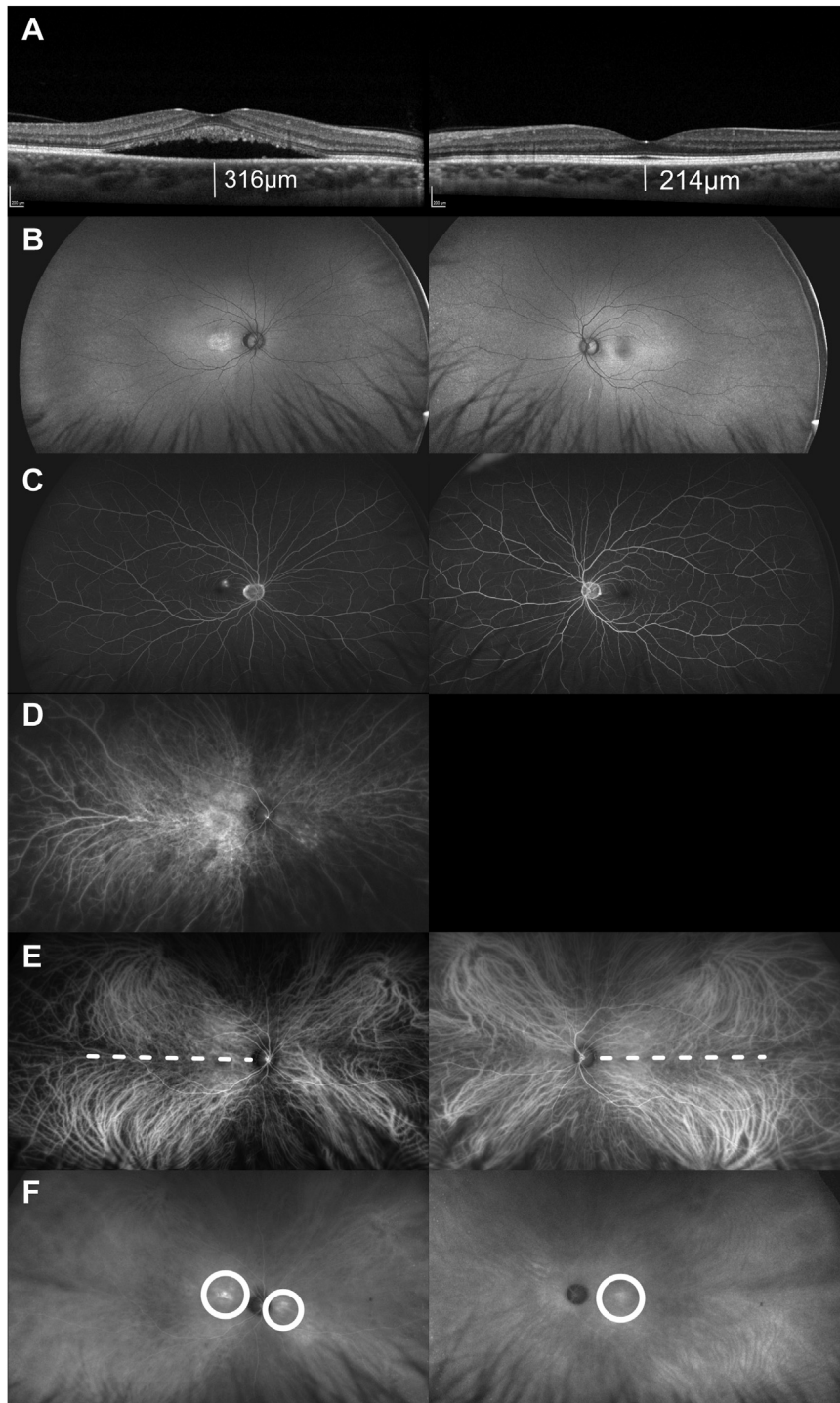
Regarding the underlying cause of venous overload, Spaide et al<sup>4</sup> suggested that increased scleral thickness could obstruct venous outflow and cause consecutive venous overload.<sup>30</sup> According to this concept, the outflow obstruction leads to thickened choroidal veins (pachyvessels) and congested vortex vein quadrants (leading to AVD), whereas intervortex venous anastomoses may represent a collateral drainage pathway aimed at compensating for reduced choroidal venous outflow from 1 or more quadrants. This idea is supported by a report on patients who underwent scleral buckling surgery for retinal detachment and experienced a presumed iatrogenic vortex vein occlusion. Postoperative widefield ICGA showed vortex vein anastomoses in 10 out of 12 eyes 3 months after these vortex vein occlusions.<sup>31</sup> These eyes also showed diffuse ICGA hyperfluorescence in the quadrant where the vortex vein occlusion had occurred. It is also supported by data from a mouse as well as a monkey model,<sup>32,33</sup> whereby the surgical occlusion of choroidal vortex veins resulted in the dilation of choroidal veins, choroidal thickening, and focal RPE degeneration, all of which can also be observed in CSC patients. However, scleral thickening and subsequent congestion do not necessarily explain the pattern of

patchy, localized, and multifocal CVH that can be observed in CSC patients.

A possible explanation for this multifocal CVH pattern could be shunting of blood flow from the choroidal arterial to the venous system via arteriovenous anastomoses.<sup>3</sup> Where these anastomoses connect to the venous system, they could cause localized areas of increased choroidal venous pressure, where subsequent choroidal fluid exudation and thus CVH may occur. Arterial filling may subsequently be delayed in these areas of increased choroidal venous pressure, which may explain the arterial flow voids we observed in 84% of CSC patients and that have also been reported previously.<sup>7</sup> Importantly, a similar type of arteriovenous fistula in the dura mater and surgically created arteriovenous shunts are associated with similar risk factors as CSC, most importantly previous corticosteroid use, and a male preponderance.<sup>3</sup> Lastly, the increased blood flow through these anastomoses may also exacerbate choroidal venous overload independent of outflow obstruction. Choroidal arteriovenous anastomoses may therefore also play an important role in the development of venous overload.

From a clinical perspective, diagnosing CSC can be challenging because many different diseases may cause a serous maculopathy.<sup>34</sup> Based on our results, signs of venous overload could also aid in the differential diagnosis of CSC. However, how frequently these signs can be observed in healthy controls must be considered when assessing their sensitivity. Intervortex venous anastomoses, for example, were reported to be present in between 35% and 44% of healthy control eyes,<sup>29,35</sup> whereas asymmetric choroidal veins were reported in 38% of healthy controls.<sup>11</sup> These can thus also be considered normal variants and not necessarily pathogenic. Choroidal vascular hyperpermeability, in contrast, was found in only 3 out of 26 eyes (12%) of healthy controls, making it much less common in unaffected patients than other signs of venous overload.<sup>29</sup>

These signs may also aid in the differential diagnosis of other pachychoroid spectrum diseases.<sup>5</sup> For the definition of a pachychoroid (literally translated from Greek: “thick choroid”), some authors have focused on a choroidal thickness above a certain value as a defining feature.<sup>36</sup> The most commonly proposed threshold of 300  $\mu\text{m}$  of subfoveal choroidal thickness would, however, imply that about 25% of affected eyes in our cohort would not meet the definition criteria of a “pachychoroid,” even though CSC is almost universally considered an integral part of the pachychoroid disease spectrum. At the same time, many healthy eyes also show a choroidal thickness of  $> 300 \mu\text{m}$ ,<sup>37</sup> which has since been termed “uncomplicated pachychoroid.” Whether these eyes ever develop a functional deterioration or subretinal fluid remains to be elucidated. However, based on the low prevalence of CSC, we predict that this is the case in only a very small proportion of cases. As Spaide et al<sup>38</sup> suggest, a “pachychoroid” per se may therefore not be considered pathological. Our findings reiterate that the large variation in choroidal thickness of healthy patients may be an important confounder when interpreting suspected pachychoroid-related pathology.<sup>36</sup>



**Figure 5.** Ultrawidefield (UWF) imaging of central serous chorioretinopathy showing very few signs of venous overload, except choroidal hyperpermeability. **A**, Enhanced-depth imaging OCT shows central subretinal fluid (SRF) in the right eye and no SRF in the left eye. Choroidal thickness is 316  $\mu\text{m}$  in the right and 241  $\mu\text{m}$  in the left eye. **B**, Fundus autofluorescence reveals a central increase in signal in the right eye with very little change in the left eye. **C**, Fundus fluorescein angiography shows a small area of focal, pinpoint leakage centrally in the right eye and no leakage in the left eye. **D**, Very early-phase UWF indocyanine green angiography (ICGA) shows mostly homogenous filling of the central choroid. **E**, Early-phase UWF ICGA shows mostly symmetric venous drainage without significant enlargement of choroidal veins or asymmetric choroidal drainage and few anastomoses crossing the watershed zone (dotted lines). **F**, Late-phase UWF ICGA shows choroidal hyperpermeability in the center and nasal to the optic disc in the right eye (circles) and an area of central hyperpermeability in the left eye (circle).

As suggested by Cheung et al,<sup>5</sup> it therefore seems warranted to define pachychoroid-related disease not just based on a simple measure of choroidal thickness. If there is a shared underlying etiology of these diseases, we believe that CVH should be considered its hallmark feature since it was found in 100% of affected and even in 85% of fellow eyes without CSC. Specifically analyzing patients with polypoidal choroidal vasculopathy may seem warranted because there appears to be an overlap between the clinical spectra of polypoidal choroidal vasculopathy and CSC.<sup>39</sup> Moreover, in healthy controls, CVH on ICGA has been reported to occur far less often (11%) than other signs of venous overload such as intervortex venous anastomoses (35%).<sup>29</sup> Lastly, we also achieved significantly higher intergrader reliability when assessing CVH (94%) compared with any other feature that was graded, such as AAFC (82%), pachyvessels (78%), CVA (76%), and AVD (74%). CVH could therefore yield higher specificity, sensitivity, and reproducibility when diagnosing CSC than choroidal thickness, pachyvessels, CVA, or AVD (Fig 5).

Because we also observed signs of venous overload in fellow eyes without SRF and some of these signs can be observed in healthy controls, a specific interindividual variation in RPE characteristics and vulnerability may further influence whether individuals develop RPE damage and SRF leakage due to the underlying choroidal anatomy and (dys)function. These interindividual differences may also explain why several patients showed CVH without any other signs of venous overload (see Fig S4). Interestingly, several genetic risk factors, most notably in the complement system (e.g., complement factor H gene), have been consistently found in CSC patient cohorts from various ethnic backgrounds.<sup>40,41</sup> The role of these genetic factors in the pathogenesis of CSC remains to be elucidated.

Limitations of our study include its retrospective nature and the manual grading that was performed. Because many signs of venous overload choroidopathy, such as pachyvessels, do not have quantifiable thresholds that allow for automated analysis (i.e., how large does a venous vessel have to be to classify as a “pachyvessel”?), 2 independent graders and, in cases of disagreement, a third grader evaluated all the images. Moreover, all graders were provided with imaging examples of the phenomena. Nevertheless, we saw only moderate intergrader agreement for pachyvessels, CVA, AAFC, and AVD, most likely due to the subjective nature of these phenomena. Especially for AVD assessment, the impact of image acquisition on grading should also be taken into account (see Fig S6, available at [www.ophtalmologyretina.org](http://www.ophtalmologyretina.org)), which is why we graded this feature only when all vortex vein ampullae were captured on an image. Because the presence of CVH is part of a set of various diagnostic criteria for CSC, it may also have influenced patient selection. Moreover, we did not find an association between the presence of various signs of venous overload and baseline characteristics such as BCVA at presentation, gender, or FFA leakage pattern, and further reports are needed to assess their impact on clinical outcomes.

In conclusion, our results suggest that choroidal dysfunction in the context of venous overload choroidopathy is a major pathogenetic factor in the development of CSC. We also show that CVH is present in the affected eyes of CSC patients, which can be reliably assessed on ICGA and should thus be considered a major diagnostic criterion for CSC. Future reports will need to assess its frequency in healthy controls and other retinal diseases to evaluate its usefulness for the differential diagnosis of CSC and other members of the pachychoroid disease spectrum. In our experience, the presence of CVH is an important differential diagnostic imaging criterion to establish the diagnosis of true CSC.

## Footnotes and Disclosures

Originally received: July 10, 2023.

Final revision: October 1, 2023.

Accepted: October 9, 2023.

Available online: October 13, 2023. Manuscript no. ORET-D-23-00448R2.

<sup>1</sup> Department of Ophthalmology, Amsterdam University Medical Centers, Amsterdam, The Netherlands.

<sup>2</sup> Eye Center, Medical Center – University of Freiburg, Faculty of Medicine, University of Freiburg, Germany.

<sup>3</sup> Ocular Angiogenesis Group, Amsterdam University Medical Centers, Amsterdam, The Netherlands.

<sup>4</sup> Department of Ophthalmology, University of Lausanne, Jules-Gonin Eye Hospital, Fondation Asile des Aveugles, Lausanne, Switzerland.

<sup>5</sup> Department of Ophthalmology, Leiden University Medical Center, Leiden, The Netherlands.

Disclosure(s):

All authors have completed and submitted the ICMJE disclosures form.

The authors have made the following disclosure(s): R.O.S.: Grants – Novartis; Consulting – Apellis, Boeinger Ingelheim; Payment or honoraria – Bayer, Novartis; Leadership or fiduciary role – Euretina Board member, EASDec Board member.

L.J.B.P.: Grants – Deutsche Forschungsgesellschaft (DFG).

The other authors have no proprietary or commercial interest in any materials discussed in this article.

L.J.B.P. was supported by the German Research foundation (DFG, Grant PA 4282/1-1). This funding organization provided unrestricted grants and had no role in the design or conduct of this research.

Parts of this work were presented at the Association for Research in Vision and Ophthalmology Annual Meeting, April 23–27, 2023, New Orleans, Louisiana.

**HUMAN SUBJECTS:** Human subjects were included in this study. The study was approved by the local ethics committee and adhered to the tenets of the Declaration of Helsinki. The local ethics committee ruled that informed consent from each patient was not necessary due to the retrospective nature of the study.

No animal subjects were used in this study.

Author Contributions:

Conception and design: Pauleikhoff, Diederer, Schlingemann, van Dijk, Boon

Data collection: Pauleikhoff, Diederer, Chang-Wolf, Boon

Analysis and interpretation: Pauleikhoff, Diederer, Chang-Wolf, van Dijk, Boon

Obtained funding: Pauleikhoff, Boon



Overall responsibility: Pauleikhoff, Diederer, Chang-Wolf, Moll, Schlingemann, van Dijk, Boon

Abbreviations and Acronyms:

**AACF** = asymmetric arterial choroidal filling; **AVD** = asymmetric venous drainage; **BCVA** = best-corrected visual acuity; **CNV** = choroidal neovascularization; **CSC** = central serous chorioretinopathy; **CVA** = choroidal venous anastomoses; **CVH** = choroidal vascular hyperpermeability; **EDI-OCT** = enhanced-depth imaging OCT; **FFA** = fundus fluorescein angiography; **ICGA** = indocyanine green angiography; **logMAR** = logarithm

of the minimum angle of resolution; **RPE** = retinal pigment epithelium; **SD** = standard deviation; **SRF** = subretinal fluid; **UWF** = ultrawidefield.

Keywords:

Central serous chorioretinopathy, Indocyanine green angiography, Ultrawidefield ICGA, Venous overload choroidopathy.

Correspondence:

Camiel J.F. Boon, MD, PhD, FEBO, Department of Ophthalmology, Amsterdam University Medical Centers, PO Box 22660, 1100 DD Amsterdam, The Netherlands. E-mail: [Camiel.boon@amsterdamumc.nl](mailto:Camiel.boon@amsterdamumc.nl)

## References

- Pauleikhoff L, Agostini H, Lange C. [Central serous chorioretinopathy]. *Ophthalmologe*. 2021;118:967–980.
- van Rijssen TJ, van Dijk EHC, Yzer S, et al. Central serous chorioretinopathy: towards an evidence-based treatment guideline. *Prog Retin Eye Res*. 2019;73:100770.
- Brinks J, van Dijk EHC, Meijer OC, et al. Choroidal arteriovenous anastomoses: a hypothesis for the pathogenesis of central serous chorioretinopathy and other pachychoroid disease spectrum abnormalities. *Acta Ophthalmol*. 2022;100:946–959.
- Spaide RF, Gemmy Cheung CM, Matsumoto H, et al. Venous overload choroidopathy: A hypothetical framework for central serous chorioretinopathy and allied disorders. *Prog Retin Eye Res*. 2022, 100973.
- Cheung CMG, Lee WK, Koizumi H, et al. Pachychoroid disease. *Eye (Lond Engl)*. 2019;33:14–33.
- Prünke C. Indocyanine green angiographic findings in central serous chorioretinopathy. *Int Ophthalmol*. 1995;19:77–82.
- Prünke C, Flammer J. Choroidal capillary and venous congestion in central serous chorioretinopathy. *Am J Ophthalmol*. 1996;121:26–34.
- Ramtohul P, Cabral D, Oh D, et al. En face ultrawidefield OCT of the vortex vein system in central serous chorioretinopathy. *Ophthalmol Retina*. 2023;7:346–353.
- Sakurada Y, Leong BCS, Parikh R, et al. Association between choroidal caverns and choroidal vascular hyperpermeability in eyes with pachychoroid diseases. *Retina*. 2018;38:1977–1983.
- Kishi S, Matsumoto H. A new insight into pachychoroid diseases: remodeling of choroidal vasculature. *Graefes Arch Clin Exp Ophthalmol*. 2022;260:3405–3417.
- Hiroe T, Kishi S. Dilatation of asymmetric vortex vein in central serous chorioretinopathy. *Ophthalmol Retina*. 2018;2:152–161.
- Matsumoto H, Hoshino J, Mukai R, et al. Vortex vein anastomosis at the watershed in pachychoroid spectrum diseases. *Ophthalmol Retina*. 2020;4:938–945.
- Spaide RF, Ledesma-Gil G, Gemmy Cheung CM. Intervortex venous anastomosis in pachychoroid-related disorders. *Retina*. 2021;41:997–1004.
- Fernández-Vigo JI, Rego-Lorca D, Moreno-Morillo FJ, et al. Intervortex venous anastomosis in the macula in central serous chorioretinopathy imaged by en face optical coherence tomography. *J Clin Med*. 2023;12:2088.
- Pang CE, Shah VP, Sarraf D, Freund KB. Ultra-widefield imaging with autofluorescence and indocyanine green angiography in central serous chorioretinopathy. *Am J Ophthalmol*. 2014;158:362–371.e2.
- Siedlecki J, Schworm B, Priglinger SG. The pachychoroid disease spectrum—and the need for a uniform classification system. *Ophthalmol Retina*. 2019;3:1013–1015.
- Warrow DJ, Hoang QV, Freund KB. Pachychoroid pigment epitheliopathy. *Retina*. 2013;33:1659–1672.
- Pang CE, Freund KB. Pachychoroid neovascularopathy. *Retina*. 2015;35:1–9.
- Dansingani KK, Gal-Or O, Sadda SR, et al. Understanding aneurysmal type 1 neovascularization (polypoidal choroidal vasculopathy): a lesson in the taxonomy of “expanded spectra”—a review. *Clin Experiment Ophthalmol*. 2018;46:189–200.
- Phasukkijwatana N, Freund KB, Dolz-Marco R, et al. Peripapillary pachychoroid syndrome. *Retina*. 2018;38:1652–1667.
- Mantel I, Schalenbourg A, Zografos L. Evanescent vaso-occlusive choroidal pseudo-tumor with acute painful onset: a presumed vortex vein occlusion. *Graefes Arch Clin Exp Ophthalmol*. 2014;252:753–759.
- Fuzzard DRW, Gin TJ, Hardy TG, Harper CA. Subretinal fluid and choroidal venous congestion secondary to a presumed dural cavernous sinus fistula. *Clin Exp Ophthalmol*. 2020;48:517–519.
- Zarnegar A, Ong J, Matsyrajya T, et al. Pathomechanisms in central serous chorioretinopathy: a recent update. *Int J Retina Vitreous*. 2023;9:3.
- Mohabati D, van Rijssen TJ, van Dijk EH, et al. Clinical characteristics and long-term visual outcome of severe phenotypes of chronic central serous chorioretinopathy. *Clin Ophthalmol*. 2018;12:1061–1070.
- Mohabati D, Hoyng CB, Yzer S, Boon CJF. Clinical characteristics and outcome of posterior cystoid macular degeneration in chronic central serous chorioretinopathy. *Retina*. 2020;40:1742–1750.
- Mohabati D, van Dijk EH, van Rijssen TJ, et al. Clinical spectrum of severe chronic central serous chorioretinopathy and outcome of photodynamic therapy. *Clin Ophthalmol*. 2018;12:2167–2176.
- van Rijssen TJ, van Dijk EHC, Scholz P, et al. Focal and diffuse chronic central serous chorioretinopathy treated with half-dose photodynamic therapy or subthreshold micropulse laser: PLACE trial report No. 3. *Am J Ophthalmol*. 2019;205:1–10.
- Armstrong RA. When to use the Bonferroni correction. *Ophthalmic Physiol Opt*. 2014;34:502–508.
- Bacci T, Oh DJ, Singer M, et al. Ultra-widefield indocyanine green angiography reveals patterns of choroidal venous insufficiency influencing pachychoroid disease. *Invest Ophthalmol Vis Sci*. 2022;63:17.

30. Imanaga N, Terao N, Nakamine S, et al. Scleral thickness in central serous chorioretinopathy. *Ophthalmol Retina*. 2021;5: 285–291.
31. Takahashi K, Kishi S. Remodeling of choroidal venous drainage after vortex vein occlusion following scleral buckling for retinal detachment. *Am J Ophthalmol*. 2000;129: 191–198.
32. Matsumoto H, Mukai R, Saito K, et al. Vortex vein congestion in the monkey eye: A possible animal model of pachychoroid. *PLOS ONE*. 2022;17:e0274137.
33. Matsumoto H, Mukai R, Hoshino J, et al. Choroidal congestion mouse model: could it serve as a pachychoroid model? *PLOS ONE*. 2021;16:e0246115.
34. van Dijk EHC, Boon CJF. Serous business: delineating the broad spectrum of diseases with subretinal fluid in the macula. *Prog Retin Eye Res*. 2021;84:100955.
35. Hoshino J, Matsumoto H, Mukai R, et al. Variation of vortex veins at the horizontal watershed in normal eyes. *Graefes Arch Clin Exp Ophthalmol*. 2021;259:2175–2180.
36. Spaide RF. The ambiguity of pachychoroid. *Retina*. 2021;41: 231–237.
37. Ikuno Y, Kawaguchi K, Nouchi T, Yasuno Y. Choroidal thickness in healthy Japanese subjects. *Invest Ophthalmol Vis Sci*. 2010;51:2173–2176.
38. Spaide RF, Ledesma-Gil G. Choriocapillaris vascular parameters in normal eyes and those with pachychoroid with and without disease. *Retina*. 2021;41:679–685.
39. Zhang X, Lim CZF, Chhablani J, Wong YM. Central serous chorioretinopathy: updates in the pathogenesis, diagnosis and therapeutic strategies. *Eye Vis (Lond)*. 2023;10:33.
40. Schellevis RL, van Dijk EHC, Breukink MB, et al. Role of the complement system in chronic central serous chorioretinopathy: a genome-wide association study. *JAMA Ophthalmol*. 2018;136:1128–1136.
41. Miki A, Kondo N, Yanagisawa S, et al. Common variants in the complement factor H gene confer genetic susceptibility to central serous chorioretinopathy. *Ophthalmology*. 2014;121: 1067–1072.