

# The Impact of Superior Labral Anterior to Posterior Lesions on Functional Status in Shoulder Instability

## A Multicenter Cohort Study

Cinzia Gaudelli,\* MD, FRCSC, Jonah Hébert-Davies,† MD, FRCSC, Frédéric Balg,‡ MD, FRCSC, Stéphane Pelet,§ MD, PhD, Ali Djangiri,|| MD, Véronique Godbout,¶ MD, MA, FRCSC, and Dominique M. Rouleau,\*# MD, MSc, FRCSC

*Investigation performed at Hôpital du Sacré-Coeur de Montréal, Montreal, Canada*

---

**Background:** Type IV superior labral anterior to posterior (SLAP) lesions, which are superior labral detachments associated with Bankart tears, are reported to occur in up to 25% of recurrent shoulder instability patients. However, the clinical implications of this finding are debatable.

**Purpose:** To determine whether there are any functional differences between anterior instability patients with and without type IV SLAP lesions at the time of presentation and at short-term follow-up after surgical intervention.

**Study Design:** Cohort study; Level of evidence, 2.

**Methods:** A prospective, multicenter database was established to follow the clinical evolution of patients with shoulder instability. Patients were diagnosed as having a type IV SLAP lesion at the time of arthroscopic Bankart surgery (SLAP+). These patients were compared with a group of patients who simply had a Bankart lesion (SLAP-). The 2 groups had their functional outcomes (Western Ontario Shoulder Instability Index [WOSI]; Disability of the Arm, Shoulder, and Hand [QuickDASH]; and Walch-Duplay) compared prior to surgery and 1 year postoperatively.

**Results:** A total of 103 subjects were included in the study; of these, 56 (43 men, 13 women) completed 1-year follow-up. Twenty-three subjects had a type IV SLAP tear, and most had this repaired along with their Bankart lesion. At baseline, SLAP+ subjects had inferior QuickDASH scores compared with SLAP- subjects (37.8 vs 29.0) as well as poorer pain subscores on both the WOSI and QuickDASH. At 1-year follow-up, however, there were no significant differences in any of the outcome measures.

**Conclusion:** A type IV SLAP lesion can be expected in 22% of patients with recurrent shoulder instability. This finding implies that at baseline, the patient will have slightly worse functional scores related to pain. However, following surgical management of the labral pathology, these patients will have equivalent functional outcomes at short-term follow-up.

**Clinical Relevance:** With surgical management of the superior and anteroinferior labrum, patients with type IV SLAP lesions will do as well as those with only Bankart tears. Thus, the presence of SLAP lesions should not alter the decision to provide surgical management and should not change the prognosis for a specific patient.

**Keywords:** SLAP tear; shoulder instability; functional outcome measures

---

Superior labral anterior to posterior (SLAP) tears were first classified by Snyder et al<sup>14</sup> into 4 categories. However, this initial description did not encompass all possible permutations. Maffet et al<sup>12</sup> added to this classification and defined the type IV lesion, that is, a detachment of the superior labrum associated with a Bankart lesion (Figure 1). They found this lesion in 2% of subjects in their series, which

consisted of patients presenting to their center for either diagnostic or therapeutic arthroscopy. It has been reported to occur in up to 25% of patients with symptomatic, recurrent shoulder instability.<sup>4</sup> Thus, a type IV SLAP lesion is not uncommon in patients presenting for surgical management of shoulder instability.

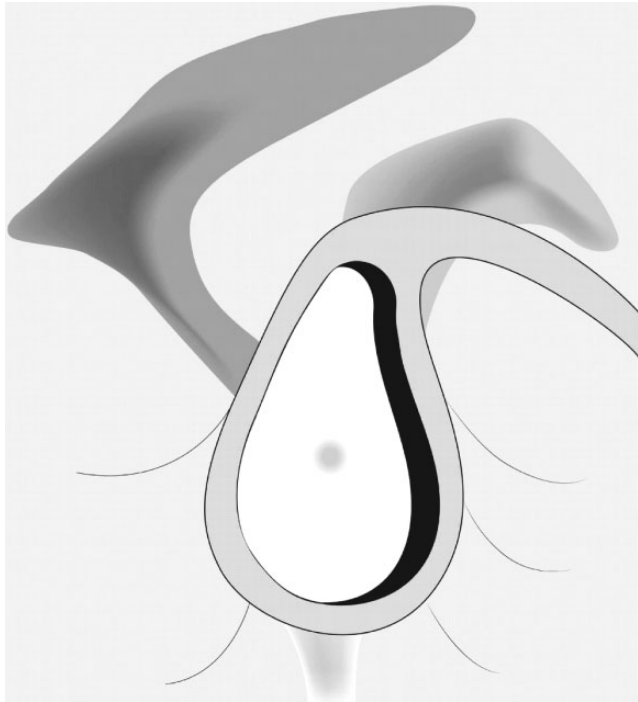Much controversy surrounds the diagnosis of a SLAP lesion, but arthroscopy is regarded as the gold standard. Physical examination is not reliable<sup>5</sup>; magnetic resonance arthrography is the best imaging modality but has limitations as well—its sensitivity has been reported to be from

---

The Orthopaedic Journal of Sports Medicine, 2(10), 2325967114554195  
DOI: 10.1177/2325967114554195  
© The Author(s) 2014

---

This open-access article is published and distributed under the Creative Commons Attribution - NonCommercial - No Derivatives License (<http://creativecommons.org/licenses/by-nc-nd/3.0/>), which permits the noncommercial use, distribution, and reproduction of the article in any medium, provided the original author and source are credited. You may not alter, transform, or build upon this article without the permission of the Author(s). For reprints and permission queries, please visit SAGE's Web site at <http://www.sagepub.com/journalsPermissions.nav>.



**Figure 1.** Representation of a type IV superior labral anterior to posterior (SLAP) lesion. There is a superior labral detachment in addition to the anteroinferior Bankart lesion.

86.4% to 90.9% and specificity from 50.0% to 93.3%.<sup>1,8,9</sup> The treatment of SLAP lesions is also controversial, with several options available: One can debride the lesion, perform a labral repair, or even perform a tenotomy or tenodesis of the long head of the biceps tendon. Additionally, how to go about repairing a SLAP lesion is controversial: it can be repaired either before or after the Bankart lesion. Recently, however, a retrospective review showed no difference in functional outcome at a minimum of 2-year follow-up between these 2 different repair methodologies.<sup>10</sup>

Symptoms associated with Bankart lesions typically do not include chronic pain but rather functional limitations that arise from symptoms of instability. In contrast, SLAP lesions frequently present with pain. We thus postulate that patients with type IV SLAP lesions exhibit pain along with their instability symptoms. We designed this study to identify from an international, multicenter cohort of shoulder instability subjects with associated SLAP lesions. We then sought to determine whether there were any differences in functional outcome measures both at presentation and at 1-year follow-up after shoulder stabilization surgery.

## METHODS

### Study Inclusion

A multicenter, international cohort was established, and patients were recruited for the cohort from July 2009 to June 2012 from 5 centers in Canada and Switzerland. They were included if they had a diagnosis of symptomatic shoulder instability, were able to communicate in either English or French, and were scheduled for a surgical stabilization procedure. Informed consent, or assent in the case of minors, was obtained prior to enrollment in the study. Subjects were included in this study if they had anterior instability, completed the preoperative questionnaires, and underwent arthroscopic Bankart repair. Subjects who underwent a Latarjet or other bone block procedure were excluded from the analysis, as this surgical approach does not permit SLAP identification.

### Data Collection

Demographic data as well as data pertaining to the number of shoulder dislocations were collected at the initial patient visit. Preoperative functional outcome measures were also collected, and included the Western Ontario Shoulder Instability Index (WOSI); Disability of the Arm, Shoulder, and Hand (QuickDASH); and Walch-Duplay scores.<sup>3,11,15</sup>

The WOSI is a validated outcome measure specifically designed for shoulder instability, with a minimum score of 0 (indicating best possible function) and a maximum score of 2100 (indicating worst possible function). It consists of 21 questions divided into 4 domains: physical symptoms; sports, recreation, and work; lifestyle; and emotions. The QuickDASH is also a validated outcome measure that quantifies the disability of the entire upper extremity, regardless of the cause of the limitations. It is a shorter form of the DASH score. Like the WOSI, a lower score on the QuickDASH represents a better functional outcome, with a maximum score of 100. The QuickDASH consists of 11 questions divided into 3 domains: physical, symptoms, and social functions. There are 2 optional sections related to work activities and sports/music. Both the QuickDASH and the WOSI are solely patient administered. The Walch-Duplay is a nonvalidated outcome measure that combines subjective patient responses with objective, physician-measured range of motion assessments. It is comprised of 4 domains: daily activity, stability, pain, and mobility. The minimum score, indicating the worst possible function, is -25, and the maximum score is 100. A poor functional outcome is defined as a score  $\leq 50$ , medium as 51 to 75, good as 76 to 90, and excellent as  $>90$ .

# Address correspondence to Dominique M. Rouleau, MD, MSc, FRCSC, Hôpital du Sacré-Coeur de Montréal, 5400 Boulevard Gouin Ouest, Montréal, Québec H4J 1C5, Canada (e-mail: dominique\_rouleau@umontreal.ca).

\*Université de Montréal and Hôpital du Sacré-Coeur de Montréal, Montréal, Québec, Canada.

† Université de Montréal, Montréal, Québec, Canada.

‡ Centre Hospitalier Universitaire de Sherbrooke, Sherbrooke, Québec, Canada.

§ Centre Hospitalier Affilié Universitaire de Québec, Québec, Canada.

|| Centre Hospitalier Universitaire de Vaudois, Lausanne, Switzerland.

¶ Centre Hospitalier de l'Université de Montréal, Montréal, Québec, Canada.

The authors declared that they have no conflicts of interest in the authorship and publication of this contribution.

The WOSI, QuickDASH, and Walch-Duplay scores all have questions specifically relating to pain. The WOSI has 2 questions: one about pain experienced with overhead activities, and the other about how much aching or throbbing is experienced in the affected shoulder. The QuickDASH also has 2 questions: one asks how much pain is experienced in the affected upper extremity, and the other how much trouble the patient has sleeping because of pain in the arm. The Walch-Duplay only has 1 question specific to pain; the examiner asks the patient how much pain is experienced and assigns a numerical value depending on whether the patient experiences no pain (0 points), activity-related pain (15 points), or unrelenting pain (25 points).

The subjects also had their Instability Severity Index Score (ISIS) calculated prior to undergoing surgery. This is a validated score designed to predict the occurrence of recurrent instability after an arthroscopic Bankart repair.<sup>2,13</sup>

### Diagnosis of SLAP Lesions

For the purpose of this study, SLAP lesions were diagnosed solely at the time of arthroscopic stabilization of the Bankart lesion. The treating surgeon had access to any preoperative imaging available, but the results of this imaging were not evaluated in the context of this study. The diagnosis of a SLAP lesion was made when at least one of the following criteria was present: a superior sublabral sulcus >5 mm in depth, a bare superior labral footprint, a displaceable biceps root, or a positive peel-back sign. There were no defined treatment algorithms, and surgeons used their preferred method for addressing the lesion. Data regarding the treatment provided were collected.

### Follow-up

Subjects followed the postoperative recommendations provided by their treating surgeon. There were no standardized protocols for rehabilitation, and patients were evaluated at 6 months and 1 year as part of the cohort. At 1-year follow-up, subjects completed WOSI and QuickDASH questionnaires as well as had their Walch-Duplay scores calculated. Participating surgeons are also required to report any episodes of recurrent instability.

### Statistics

Descriptive statistics were compiled and analyses performed using SPSS version 19.0 (IBM SPSS Inc). Prior to analysis, a Levene test for the equality of variances was carried out on the various variables. Independent-samples *t* tests were then carried out to determine the differences between SLAP+ and SLAP- subjects for the variables selected, as well as the demographic data. Significance was set at  $P \leq .05$ . Nonparametric statistical analyses (Mann-Whitney) were also performed to reduce the likelihood of confounders.

This study was approved by the institutional ethics board at each participating center.

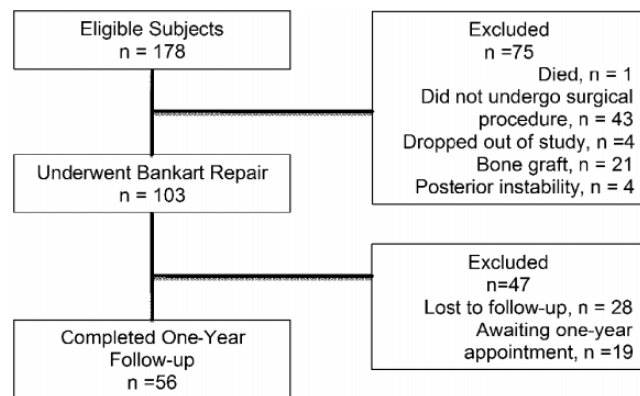


Figure 2. Subject flowchart.

TABLE 1  
Demographic Data<sup>a</sup>

	SLAP+ Group	SLAP- Group	<i>P</i> <sup>b</sup>
No. of participants			
Initial	23	80	
At 1-year follow-up	13	43	
Mean age, y	34	29	.03
Sex, n (%)			
Male	17 (73.9)	58 (72.5)	.89
Female	6 (26.1)	22 (27.5)	
ISIS score	2.7	3.4	.11
Number of dislocations <sup>c</sup>	14.0	18.5	.65

<sup>a</sup>ISIS, Instability Severity Index Score; SLAP+, patients were diagnosed as having a type IV superior labral anterior to posterior (SLAP) lesion at the time of arthroscopic Bankart surgery; SLAP-, patients who simply had a Bankart lesion.

<sup>b</sup>Independent-samples *t* test.

<sup>c</sup>The number of dislocations is the average of self-reported episodes of instability encountered by the subject at presentation.

### RESULTS

There were 178 subjects from 5 different centers in the cohort at the time of the study. Of these, 103 met study inclusion and exclusion criteria, completed baseline questionnaires, and underwent surgical stabilization. Twenty-three subjects had a type IV SLAP lesion (SLAP+). Of the subjects undergoing surgery, 28 were lost to follow-up, and the remaining subjects have not reached their final follow-up, leaving 56 subjects (13 with a SLAP lesion [SLAP+] and 43 without [SLAP-]) who completed 1-year postoperative follow-up questionnaires. A subject flowchart is shown in Figure 2.

Demographic data are presented in Table 1. The majority of subjects (>70%) were male, and on average, each subject had 14 dislocations prior to enrollment in the study; this was similar for both groups. The average age for the SLAP+ group was 34 years, while for the SLAP- group, it was 29 years, which was statistically significant ( $P = .03$ ). Of the 23 subjects that had a type IV SLAP lesion, 21 had a repair of the SLAP tear, 1 had a biceps tenodesis, and 1 had

TABLE 2  
Functional Outcome Measures<sup>a</sup>

	Baseline (N = 103)			At 1-Year Follow-up (n = 56)		
	SLAP+ Group	SLAP- Group	P <sup>b</sup>	SLAP+ Group	SLAP- Group	P <sup>b</sup>
WOSI	1240.3 ± 385	1132.1 ± 367	.23	371.3 ± 333	526.1 ± 444	.34
WOSI, pain subscore	82.6 ± 41.8	63.9 ± 47	.05	35.1 ± 46.9	35.5 ± 40.3	.96
QuickDASH	37.8 ± 18.3	29.0 ± 16.8	.05	12.4 ± 9.7	16.1 ± 16.9	.73
QuickDASH, pain subscore	5.13 ± 1.9	4.4 ± 1.7	.12	3.07 ± 0.86	3.39 ± 1.74	.80
Walch-Duplay	53.6 ± 18.4	52.9 ± 15.1	.92	81.5 ± 15.5	83.3 ± 16.5	.69
Walch-Duplay, pain subscore	13.3 ± 8.6	16.1 ± 8.2	.15	17.9 ± 7.5	20.4 ± 7.3	.20

<sup>a</sup>Values are presented as mean ± SD. QuickDASH, Disability of the Arm, Shoulder, and Hand; SLAP+, patients were diagnosed as having a type IV superior labral anterior to posterior (SLAP) lesion at the time of arthroscopic Bankart surgery; SLAP-, patients who simply had a Bankart lesion; WOSI, Western Ontario Shoulder Instability Index.

<sup>b</sup>Mann-Whitney *U* test.

a debridement of the superior labral lesion performed, all in conjunction with their Bankart repairs.

We performed Mann-Whitney tests to compare the means of the various functional outcomes measures at the time of initial presentation (N = 103) between the SLAP+ (n = 23) and SLAP- (n = 80) groups (Table 2). Of these, the distribution for pain-related questions in the WOSI and the QuickDASH scores at baseline were significantly different for SLAP+ and SLAP- subjects (Mann-Whitney *U* = 658, *P* = .05 and Mann-Whitney *U* = 635.5, *P* = .05, respectively). Seeing as age was correlated with the presence of a SLAP tear, a Pearson correlation was performed to determine whether age correlated with the functional measures. A weak, positive correlation between age and the QuickDASH score at initial presentation was found (*r* = 0.252, *n* = 104, *P* = .10).

At 1-year follow-up (n = 56), the SLAP+ (n = 13) and SLAP- (n = 43) groups showed no statistically significant differences in any of the functional outcome measures.

Because the individual questions on the WOSI and QuickDASH have not been validated as stand-alone questions, we compared the results for each between SLAP+ and SLAP- groups both at baseline and at 1-year follow-up. This was performed to determine whether there would be multiple questions with statistically different values for the SLAP+ and SLAP- groups. Other than the previously mentioned questions pertaining to pain, there were no significant differences between the 2 groups other than for the question "How much fear do you have of falling on your shoulder?"

## DISCUSSION

Our principal finding is that patients with type IV SLAP lesions have more pain associated with their instability than patients without a SLAP lesion, as evidenced by their significantly worse scores on the pain-related questions on the WOSI and on their higher QuickDASH scores, prior to surgery. Moreover, this study shows that once treatment is provided, the functional results for these patients are similar to patients with anterior instability without a SLAP tear, according to our limited sample size.

The incidence of type IV SLAP lesions in our cohort was 22.3%. This is similar to the 25% seen by Cho et al<sup>4</sup> but higher than the 7% seen by Gobezie et al,<sup>6</sup> both of whom looked at the rates of SLAP lesions in patients with traumatic shoulder instability. One potential explanation for this difference is the delay to surgical treatment and the number of instability episodes encountered by the patient. It has been demonstrated that there is a correlation between the number of instability episodes and the degree of injury seen at arthroscopy.<sup>7</sup> Thus, as the majority of patients recruited for this study depend on publicly funded health care, the delay to treatment is substantial, and we would expect to see more pathology from an increased number of instability episodes.

The major strength of this study is that this is a multinational, multicenter study. Subjects were treated by various participating surgeons, each following similar but individualized protocols. The results thus present a real-world representation of what can be expected for patients presenting with SLAP lesions. Our study does have limitations. One is that although the WOSI and QuickDASH are both validated, their subsections are not. We attempted to circumvent this by looking at the differences between the 2 groups for each of the questions in the WOSI and QuickDASH to ensure that the difference we have shown was not due to chance. Additionally, there is an inherent variability in surgeon diagnosis of SLAP lesions.<sup>6</sup> We attempted to standardize the diagnosis as much as possible by providing criteria for the diagnosis, but this does not eliminate all the variability given that numerous surgeons were involved. This cohort also has a loss to follow-up rate of 30%, which is relatively high. However, for the most part, shoulder instability patients tend to be younger and tend to do well in the short-term, so would thus be disinclined to present for follow-up. Finally, as this cohort was designed to answer several research questions, no specific power calculation was performed for this study. This may thus lead to a type 2 statistical error.

## CONCLUSION

A patient with recurrent shoulder instability who presents with pain in between dislocations may represent a patient

with a concomitant SLAP lesion. However, at 1-year follow-up after shoulder stabilization surgery, this patient will achieve the same functional outcome as one who did not have a SLAP lesion. We thus recommend that patients with type IV SLAP lesions, even though they are worse off at baseline, be offered treatment for both their Bankart and SLAP lesions as they will do as well as patients without a SLAP lesion at 1-year follow-up.

## ACKNOWLEDGMENT

The authors thank Julie Fournier and Stéphanie Boisvert for their help in patient recruitment and database management. They also thank Amy Svotelis for her review of the article.

## REFERENCES

1. Amin MF, Youssef AO. The diagnostic value of magnetic resonance arthrography of the shoulder in detection and grading of SLAP lesions: comparison with arthroscopic findings. *Eur J Radiol.* 2012; 81:2343-2347.
2. Balg F, Boileau P. The instability severity index score. A simple pre-operative score to select patients for arthroscopic or open shoulder stabilization. *J Bone Joint Surg Br.* 2007;89:1470-1477.
3. Beaton DE, Wright JG, Katz JN; Upper Extremity Collaborative Group. Development of the QuickDASH: comparison of three item-reduction approaches. *J Bone Joint Surg Am.* 2005;87:1038-1046.
4. Cho HL, Lee CK, Hwang TH, Suh KT, Park JW. Arthroscopic repair of combined Bankart and SLAP lesions: operative techniques and clinical results. *Clin Orthop Surg.* 2010;2:39-46.
5. Cook C, Beaty S, Kissenberth MJ, Siffri P, Pill SG, Hawins RJ. Diagnostic accuracy of five orthopedic clinical tests for the diagnosis of superior labrum anterior posterior (SLAP) lesions. *J Shoulder Elbow Surg.* 2012;21:13-22.
6. Gobezie R, Zurakowski D, Lavery K, Millett PJ, Cole BJ, Warner JJ. Analysis of the interobserver variability in the diagnosis and treatment of SLAP tears using the Snyder classification. *Am J Sport Med.* 2008; 36:1373-1378.
7. Gutierrez V, Monckeberg JE, Pinedo M, Radice F. Arthroscopically determined degree of injury after shoulder dislocation relates to recurrence rate. *Clin Orthop Relat Res.* 2012;470:961-964.
8. Halma JJ, Eshuis R, Krebbers YM, Weits T, de Gast A. Interdisciplinary inter-observer agreement and accuracy of MR imaging of the shoulder with arthroscopic correlation. *Arch Orthop Trauma Surg.* 2012;132:311-320.
9. Holzapfel K, Waldt S, Bruegel M, et al. Inter- and intraobserver variability of MR arthrography in the detection and classification of superior labral anterior posterior (SLAP) lesions: evaluation in 78 cases with arthroscopic correlation. *Eur Radiol.* 2010;20:666-673.
10. Kim DS, Yi CH, Yoon YS. Arthroscopic repair for combined Bankart and superior labral anterior posterior lesions: a comparative study between primary and recurrent anterior dislocation in the shoulder. *Int Orthop.* 2011;35:1187-1195.
11. Kirkley A, Griffin S, McLintock H, Ng L. The development and evaluation of a disease-specific quality of life measurement tool for shoulder instability. The Western Ontario Shoulder Instability Index (WOSI). *Am J Sports Med.* 1998;26:764-772.
12. Maffet MW, Gartsman GM, Moseley B. Superior labrum-biceps tendon complex lesions of the shoulder. *Am J Sports Med.* 1995;23: 93-98.
13. Rouleau DM, Hebert-Davies J, Djahangiri A, Godbout V, Pelet S, Balg F. Validation of the instability shoulder index score in a multicenter reliability study in 114 consecutive cases. *Am J Sports Med.* 2013; 41:278-282.
14. Snyder SJ, Karzel RP, Del Pizzo W, Ferkel RD, Friedman MJ. SLAP lesions of the shoulder. *Arthroscopy.* 1990;6:274-279.
15. Walch G. The Walch-Duplay score for instability of the shoulder. Directions for use of the quotation of anterior stability of the shoulder. In: *Abstracts of the First Open Congress of the European Society of Surgery of the Shoulder and Elbow.* Paris, France; 1987: 51-55.